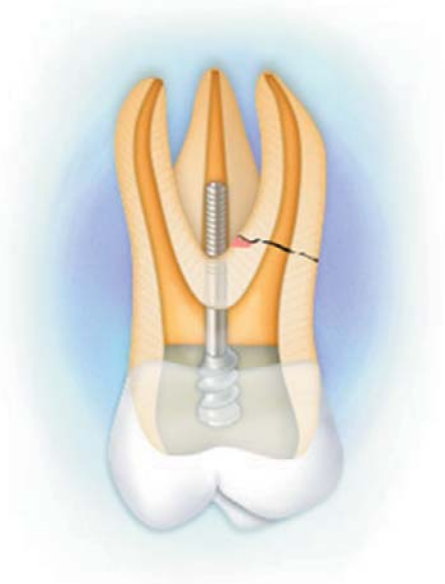


Intentional Dental Reimplantation: A Case Report

Emilio Nuzzolese, DDS; Nunzio Cirulli, DDS, PhD;
Maria M. Lepore; Addolorata D'Amore



Abstract

It is well known dental reimplantation is indicated following traumatic avulsion by the preservation of cellular vitality in the periodontal ligament and under conditions of asepsis. The rate of endodontic success at five years reported in the literature ranges between 70% and 91%. However, intentional dental reimplantation is an effective strategy for the treatment of teeth that would be difficult, if not impossible, to treat using traditional root canal therapy. Different prognoses exist for intentional dental reimplantation and trauma-related reimplantation. This is due to such important variables such as the level of cellular vitality in the periodontal ligament; the degree of trauma to surrounding tissues, and the degree of asepsis when a tooth is removed. Surgical extraction is more favorable in this regard compared to a traumatic avulsion scenario. This paper presents a report of an intentional dental reimplantation of a maxillary right firstmolar.

Keywords: Intentional dental reimplantation, endodontic therapy, retrograde filling

Citation: Nuzzolese E , Cirulli N, Lepore MM, et. al. Intentional Dental Reimplantation: A Case Report. J Contemp Dent Pract 2004 August;(5)3:121-130.

Introduction

Maintaining the integrity of the natural dentition is the central goal of dentistry. Both orthograde and retrograde endodontic treatment play a major role in achieving this goal. The presence of perforations or fractures of the endodontium drastically reduces the possibilities for treatment, except for repeat root canalization, where it is possible to close the perforation itself. In other cases, the prognosis is decidedly unfavorable and it is necessary to extract the tooth and provide the patient with a prosthesis.

However, it is possible to propose intentional dental reimplantation as an alternative treatment to the patient. It is well known dental reimplantation is indicated following traumatic avulsion by the preservation of cellular vitality in the periodontal ligament and under conditions of asepsis. The rate of endodontic success at five years reported in the literature ranges between 70%¹¹, 81%⁸, and 91%⁷. However, different prognoses exist for intentional dental reimplantation and trauma-related reimplantation.

The most important variables are the level of cellular vitality in the periodontal ligament and the extractive technique applied in the least traumatic manner possible. Use of a chlorhexidine mouthwash, disinfection of the surgical field, immersion of the extracted tooth in sterile saline solution, and irradiation of the alveolus with a neodymium laser constituted the asepsis parameters adopted in this clinical case. This procedure is recommended as the treatment of choice in the following instances:⁸

- For lower second molars, for single-rooted teeth, and lower first molars when there is difficulty in accessibility to perform apical surgery
- When the mental foramen is superimposed over the apex of the premolars
- When the molar apex is in proximity to the mandibular canal
- When patients object to periradicular surgery
- When failures occur after apical surgery
- When surgery would create a periodontal pocket as a result of extensive bone removal

Our approach includes extending reimplantation to the superior molars also through a deliberate, controlled extraction technique. The risk

of fracture during extraction represents the biggest problem for the technique, unless the tooth already presents a fractured root – as in our case. Since we were faced with a molar with three roots, we decided to resect the compromised root, adopting an apicectomy approach. In such cases it is better, on medico legal grounds, not to raise false hopes in the patient regarding the future success of the reimplantation. It is prudent not to begin treatment until patient has been fully informed of the possibility of failure.

Materials and Methods

The patient presented to us complaining of pain in the maxillary right first molar (Figure 1). The patient was a nonsmoker, and his previous history was noncontributory to the case; he was in good health. On internal examination of the mouth, the tooth was slightly painful to percussion. Intraoral radiographs did not show any periapical lesions (Figure 2).

Since the tooth was symptomatic and previously treated endodontically, we proposed to the patient to repeat the root canal therapy (under rubber

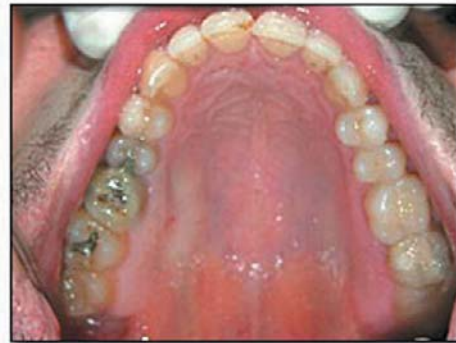

Figure 1.

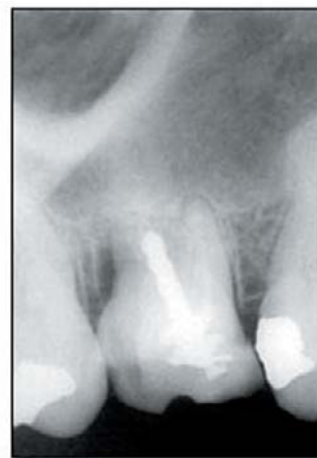

Figure 2.

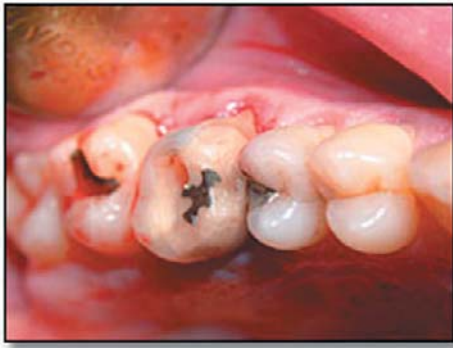

Figure 3.

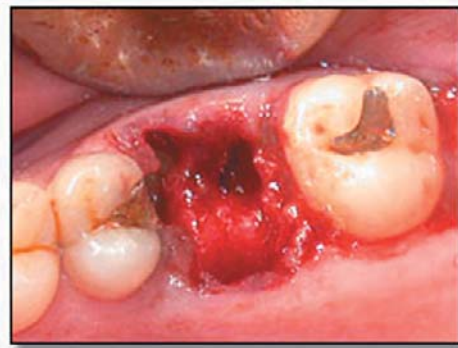

Figure 4.

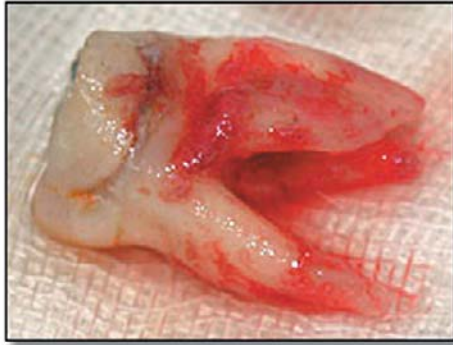


Figure 5.

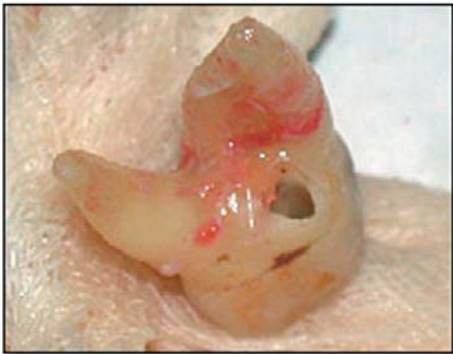
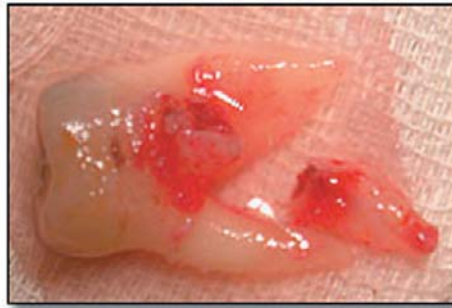
Figure 6.

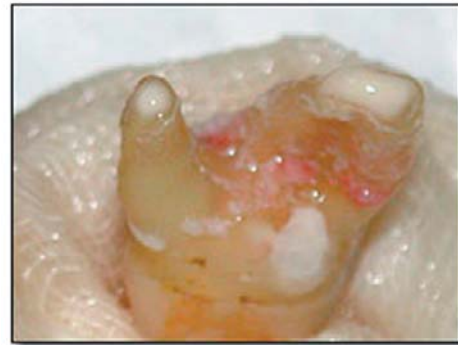

Figure 7.

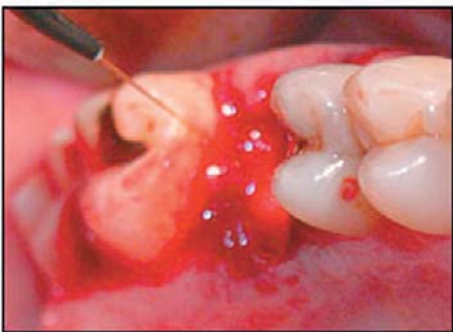


Figure 8.

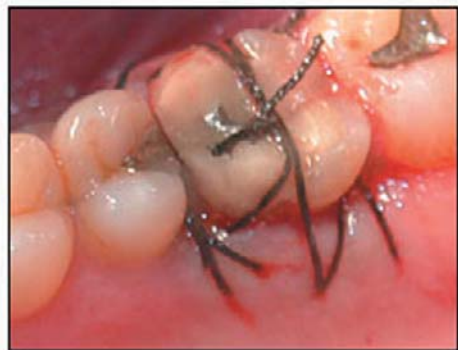

Figure 9.

dam and warm ipocloride), and if this failed, tooth extraction and insertion of a post-extraction, osseointegrated implant. Despite the proposed treatment plan, the patient requested extraction of the tooth. After cleaning the affected tooth rinsing for 60 seconds with chlorhexidine, and administration of local anesthesia, the tooth was extracted and evaluated for the possibility for dental reimplantation. (Figure 3, 4)

The extracted tooth was placed on sterile gauze immersed in a finger bowl of saline solution (Figure 5). Inspection of the tooth revealed the presence of a perforation in the dental floor secondary to fracture of the mesiovestibular root. It was invisible on radiography.

Since we wished to continue with the reimplantation, the other two roots were treated via the retrograde route using separate retrograde fillings, sealing the perforation, eliminating the fractured root, and restoring the void with glass ionomer resin.^{3,5} (Figures 6, 7)

The post extraction alveolus was cleansed with benzalkonium solution and then irradiated with a Nd:Yag laser (Figure 8) at 10 Hz and 100 mJ.

The alveolus was then thoroughly irrigated with saline solution. The extracted tooth was preserved under asepsis, reconstructed, filled with glass ionomer resin, and repositioned in the alveolus. Tooth stability was somewhat reinforced with horizontal mattress 3.0 silk sutures in the interproximal spaces and on the dental crown (Figures 9, 10).

The crown of the tooth had been already prepared for a fixed crown. The patient received postoperative and hygiene instructions. On

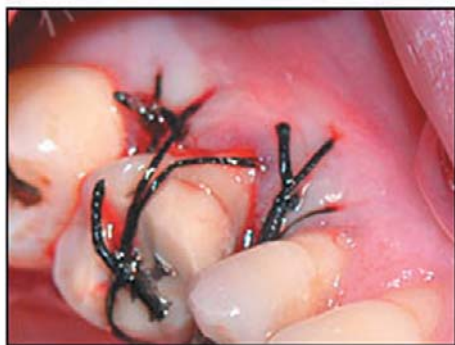

Figure 10.

postoperative day two a 0.2% chlorhexidine mouthwash was prescribed for 10 days. On postoperative day nine, the sutures were removed. Follow-up was scheduled for five months post surgery and for dental hygiene procedures (Figures 11, 12).

With no sign of inflammation, either clinical or on radiography (radiograph B), and no symptomatology, the prosthesis phase was started with taking of an impression and fabrication of a metal-ceramic crown (Figures 13, 14).

At 14 and 18 months post surgery, the patient was examined again. The physical examination did not demonstrate any signs of discomfort (Figures 15-17) apart from an accumulation of plaque.

On radiography, no signs of rhizolysis were evident (Figure 18). The patient did not complain of symptoms in the reimplantation area and had no problem with mastication on the right side.

Results

Intentional dental reimplantation seems to be a treatment alternative that should not be underrated. The data in the literature relating to intentional dental reimplantations support the idea of being able to propose this solution to the patient whenever conventional endodontic or surgical treatment is not applicable. The critical parameters to watch are the preservation of cellular vitality in the periodontal ligament, the duration and method of extra-alveolar preservation, and the status of asepsis. In intentional reimplantation, these variables are controlled by the treating dentist, who can perform all procedures under aseptic conditions and reimplant the tooth in a very brief period (about 15 minutes). Also the dental hygienist plays an important role in plaque control before

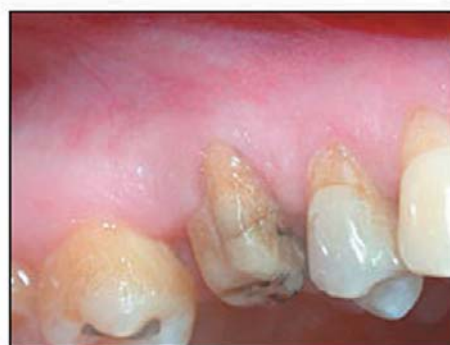

Figure 11.

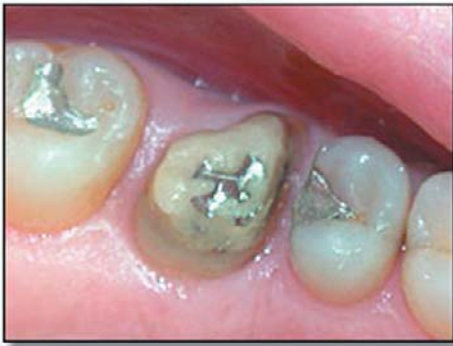

Figure 12.

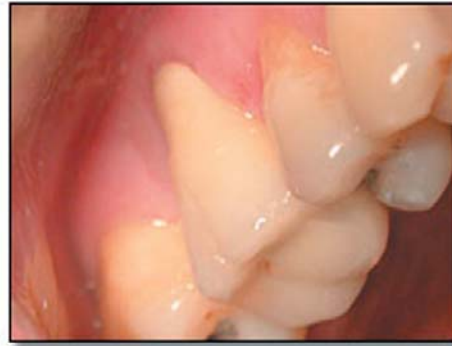

Figure 13.

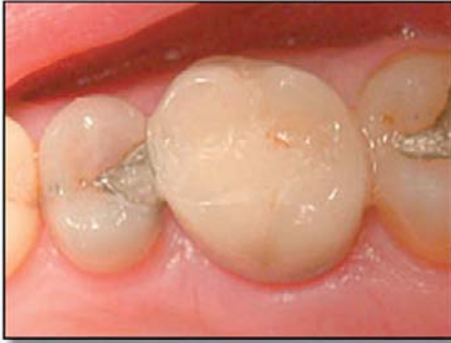

Figure 14.

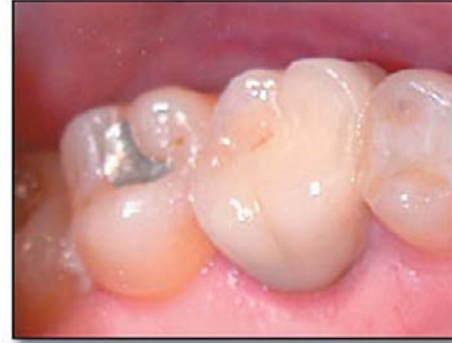

Figure 15.

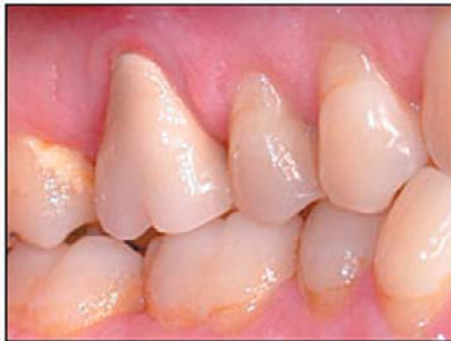

Figure 16.

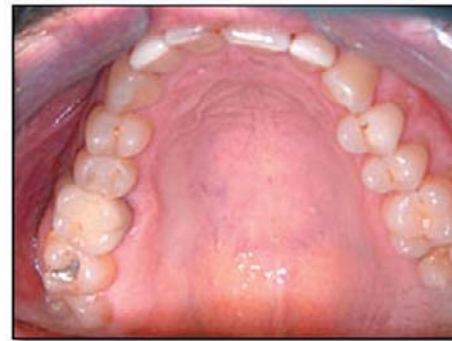

Figure 17.

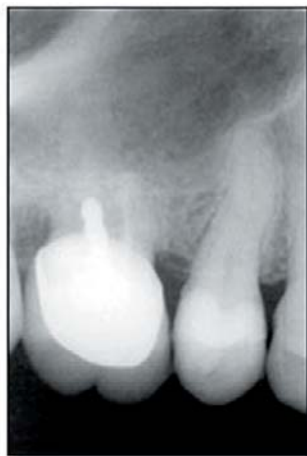

Figure 18.

and after surgery. Eighteen months post surgery, the patient demonstrated no signs of rhizolysis, while in cases of reimplantation in traumatic avulsion signs of rhizolysis usually are manifested within 12 months on average. The patient reports good mastication function and a complete absence of symptoms in this tooth.

Conclusion

Preservation of the tooth in the mouth for as long as possible is the major goal of any conservative treatment. Dental reimplantation is certainly not the primary therapy of choice in cases of

endodontic failure, but in situations where the patient will not accept other treatments (such as repeat root canal therapy, apicectomy, or post extraction implants) the technique described above should not be overlooked. Indeed, while allowing for the reimplantation prognosis, its permanence in the arch enhances conservation of the vertical dimension by impeding the migration of adjacent and antagonist teeth. In addition, reimplantation is a relatively low-cost treatment, enabling the patient to postpone – even for years – rehabilitative therapy that will cost more.

References

1. Niemczyk SP. Re-inventing intentional replantation: a modification of the technique. *Pract Proced Aesthet Dent*. 2001 Aug;13(6):433-9; quiz 440.
2. Aqrabawi J. Five-year follow-up of successful intentional replantation. *Dent Update*. 1999 Nov; 26(9): 388-90.
3. Shuman IE. Repair of a root perforation with a resin-ionomer using an intentional replantation technique. *Gen Dent*. 1999 Jul-Aug; 47(4): 392-5.
4. Poi WR, Sonoda CK, Salineiro SL, et. al. Treatment of root perforation by intentional replantation: a case report. *Endod Dent Traumatol*. 1999 Jun; 15(3): 132-4.
5. Dragoo MR. Resin-ionomer and hybrid-ionomer cements: part II, human clinical and histologic wound healing responses in specific periodontal lesions. *Int J Periodontics Restorative Dent*. 1997 Feb;17(1):75-87.
6. Tang PM, Chan CP, Huang SK, et. al. Intentional replantation for iatrogenic perforation of the furcation: a case report. *Quintessence Int*. 1996 Oct; 27(10): 691-6.
7. Andreasen JO, Borum MK, Jacobsen HL, et. al. Replantation of 400 avulsed permanent incisors. 4. Factors related to periodontal ligament healing. *Endod Dent Traumatol*. 1995 Apr;11(2):76-89.
8. Bender IB, Rossman LE. Intentional replantation of endodontically treated teeth. *Oral Surg Oral Med Oral Pathol*. 1993 Nov;76(5):623-30.
9. Keller U. A new method of tooth replantation and autotransplantation: aluminum oxide ceramic for extraoral retrograde root filling. *Oral Surg Oral Med Oral Pathol*. 1990 Sep;70(3):341-4.
10. Madison S. Intentional replantation. *Oral Surg Oral Med Oral Pathol*. 1986 Dec;62(6):707-9.
11. Dumsha TC, Gutmann JL. Clinical guidelines for intentional replantation. *Compend Contin Educ Dent*. 1985 Sep;6(8):604, 606-8. No abstract available.
12. Grossman LI, Chacker FM. Clinical evaluation and histologic study of intentionally replanted teeth. *Trans. 4th Int Conf Endo* 1968; 127-44.

About the Author

Emilio Nuzzolese, DDS



Dr. Nuzzolese graduated from the University of Bari (Italy) in 1994. He did his graduate work in Prosthetics at King's College School of Medicine and Dentistry, University of London in 1996. He is an active participant and lecturer in continuing dental education courses and at dental conferences in Italy and abroad, dealing with periodontology, implantology, and forensic odontology.

e-mail: info@ilvostrodentista.it

Nunzio Cirulli, DDS, PhD



Dr. Cirulli graduated from the University of Bari (Italy) in 1995. His post-graduate work was in Orthodontics and was presented as his Master thesis at the University of Insubria – Varese in 1999. He received his doctorate (PhD in Orthodontics) in 2004 discussing a thesis on Lingual Orthodontics. His practice is limited to orthodontics with a primary focus on esthetics and lingual orthodontics.

Maria M. Lepore



Ms. Maria M. Lepore was a graduate in Dental Hygiene from the University of Bari (Italy) in 2001. Her practice is focused on periodontal treatment using laser technology and magnifying appliances.

Addolorata D'Amore



Ms. Addolorata D'Amore has been a dental assistant since 1999. She attended courses on digital photography and patient communication and is currently a dental hygiene student at the University of Bari.

Acknowledgements

The authors would like to thank Mr. David Hargreaves for his translation assistance.