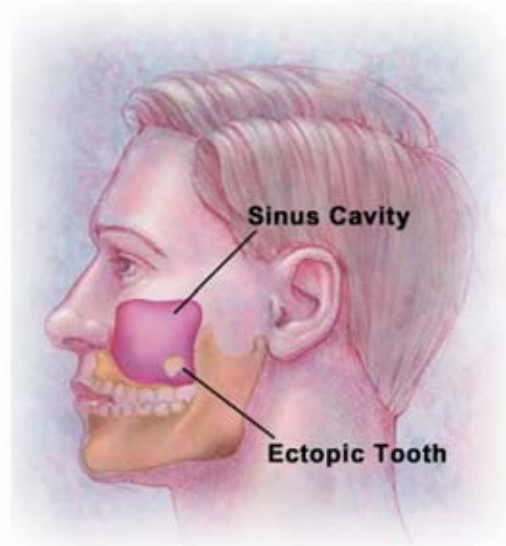


## Ectopic Eruption of a Maxillary Third Molar Tooth in the Maxillary Sinus: A Case Report

M. Cemil Büyükkurt, DDS, PhD; Sinan Tozoğlu, DDS, PhD;  
M. Hamdi Aras; Ümit Yolcu



### Abstract

Ectopic eruption of teeth into regions other than the oral cavity is rare although there have been reports of teeth in the nasal septum, mandibular condyle, coronoid process, palate, chin, and maxillary sinus. Occasionally, a tooth may erupt in the maxillary sinus and present with local sinonasal symptoms attributed to chronic sinusitis. We present a case of an ectopic maxillary third molar tooth that caused chronic sinusitis in the maxillary sinus.

**Keywords:** Ectopic teeth, third molar, maxillary sinus

**Citation:** Büyükkurt MC, Tozoglu S, Aras MH, Yolcu Ü. Ectopic Eruption of a Maxillary Third Molar Tooth in the Maxillary Sinus: A Case Report. J Contemp Dent Pract 2005 August;(6)3:104-110.

## Introduction

Tooth development results from a complicated multi-step interaction between the oral epithelium and the underlying mesenchymal tissue. A series of complex tissue interactions result in the formation of mature teeth. Abnormal tissue interaction during development may potentially result in ectopic tooth development and eruption.<sup>1</sup>

Ectopic eruption of a tooth into the dental environment is common, whereas ectopic eruption of a tooth in other sites is rare.<sup>2</sup> Diverse oral anatomical locations can infrequently be the site of an ectopic tooth eruption.<sup>3</sup> Such locations include the nasal cavity, chin, mandibular condyle, coronoid process, and palate. One of the sites for an ectopic tooth in a nondental location is the maxillary sinus.<sup>1-3</sup> Teeth in the maxillary sinus are rare.<sup>4,5</sup> Due to its rarity, the literature that deals with this entity is sparse.<sup>4</sup> Ectopic eruption may be associated with one of three distinct processes: developmental disturbances, pathological processes, and iatrogenic activity.<sup>4</sup> The etiology of ectopic teeth is not always known.<sup>6</sup>

Tooth development results from a complicated multi-step interaction between the oral epithelium and the underlying mesenchymal tissue. The series of complex tissue interactions that ensue result in the formation of mature teeth, each with a crown and root. Abnormal tissue interactions during development may potentially result in ectopic tooth development and eruption.<sup>1</sup>

Impaction of a tooth in the maxillary sinus can be asymptomatic. Such teeth are often discovered serendipitously on radiographs of the skull or teeth. In some cases, patients experience significant symptoms. Tooth eruption in the maxillary sinus may cause sinusitis.<sup>4</sup> The treatment of an ectopic maxillary tooth is surgical removal.<sup>1</sup> We present a case of an ectopic third molar which presented in the maxillary sinus and was removed via the Caldwell-Luc procedure.

## Case Report

A 31-year old, healthy and asymptomatic Caucasian man was referred to the Oral and Maxillofacial Surgery outpatient clinic for evaluation of oroantral fistula following the extraction of left first permanent molar tooth.

The intraoral examination revealed the maxillary left second and third molars were absent. The maxillary left first molar tooth was extracted one month previously. Purulent material from the oroantral fistula was observed. The extraoral examination revealed no signs or symptoms. The patient complained of a headache on the left side of his face for approximately 3-4 years. The panoramic radiograph showed a well-defined circular opacity surrounded by a soft tissue mass in the left maxillary sinus (Figure 1).

A computed tomography (CT) scan of the paranasal sinuses revealed this was a crown of a tooth (Figure 2).

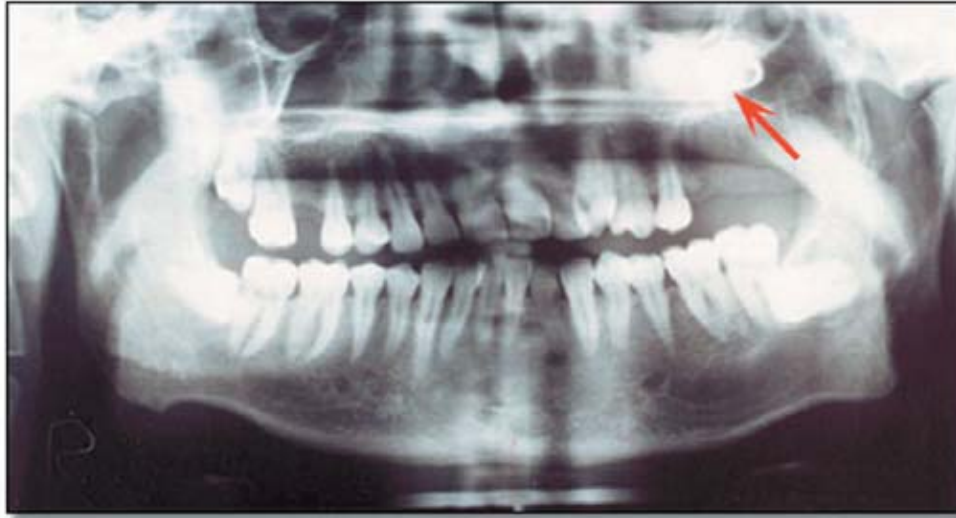A Caldwell-Luc operation was performed under local anesthesia. The ectopic tooth was removed and the left maxillary sinus was cleared of all diseased mucosa and purulent material. The patient's symptoms resolved completely after surgery.

## Discussion

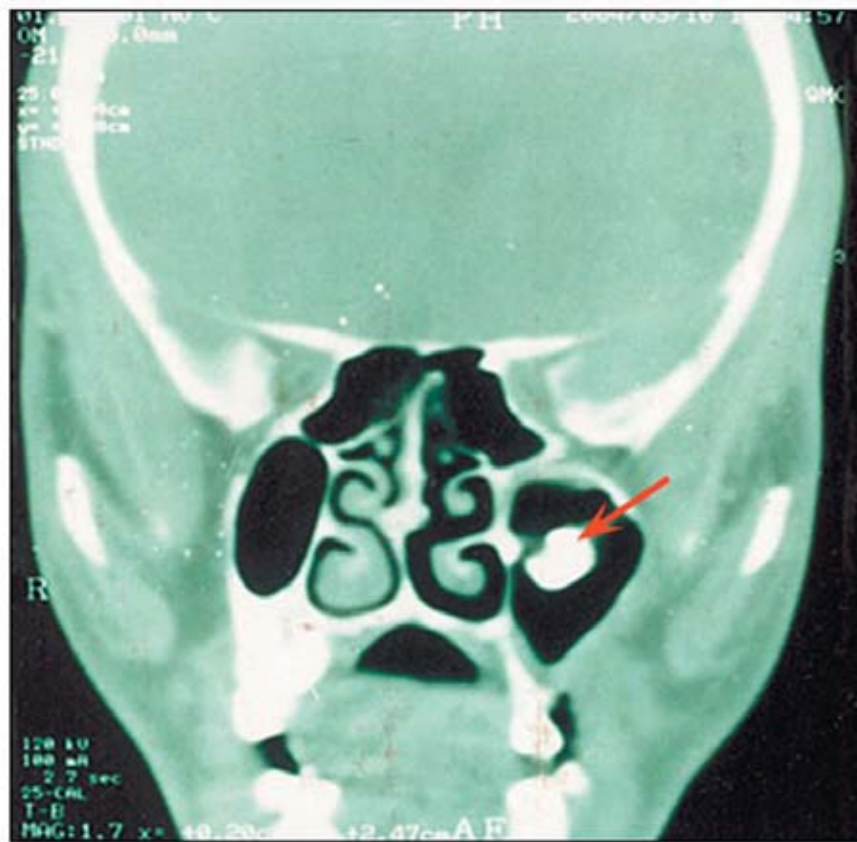
The etiology of ectopic eruption is still unclear and many theories have been suggested including trauma, infection, cyst, tumor, crowding, and developmental abnormalities.<sup>2,3,6</sup> In many cases, however, the etiology cannot be identified.<sup>1,8</sup> Presumably, the etiologic factor is related to the type of tooth and its immediate anatomic environment.<sup>6</sup> In the present case the left upper third molar was absent from its normal position and was found in the left maxillary sinus.

In such cases the teeth can migrate to various locations including the maxillary sinus, nose, and infraorbital area.<sup>6</sup> Ectopic eruption of teeth into regions other than the oral cavity is unusual although there have been reports of teeth in the nasal septum, mandibular condyle, coronoid process, palate, chin, and maxillary sinus.<sup>1-3,5-7</sup> Teeth developing in the maxillary sinus are rare.<sup>4,5</sup>

Patients with this rare dental abnormality are, therefore, more likely to be managed by medical practitioners than their dental counterparts.<sup>1</sup> The diagnosis of this condition can easily be made radiologically with panoramic and radiographs of the maxillary sinuses that demonstrate the



**Figure 1.** The panoramic radiograph revealed a radiopacity in the left maxillary sinus.



**Figure 2.** A computed tomography (CT) scan of the Paranasal sinuses revealed a crown of a tooth.

presence of the highly radiopaque tooth and unusual surrounding soft tissue which is a reaction seen commonly associated with in chronic sinus disease.<sup>1,6</sup> In the present case, the condition was detected using panoramic radiography. Ectopic teeth in the maxillary sinus are radiopaque and, therefore, easily diagnosed radiographically.<sup>3</sup>

Patients with an ectopic tooth impaction in the maxillary sinus can remain asymptomatic over the course of their lifetime.<sup>1,6</sup> Some authors report nasal obstruction, facial fullness, headache, and hyposmia.<sup>6</sup> In the present case the patient complained of a headache and sinusitis. Occasio

nally, a tooth may erupt in the maxillary sinus and present with local sinonasal symptoms attributed to chronic sinusitis.<sup>1</sup> The present case also was associated with sinusitis, confirming the earlier observations.<sup>3</sup>

### Summary

The treatment of an ectopic tooth in the maxillary sinus is usually surgically removed via the Caldwell-Luc procedure.<sup>1,2,4-6,8</sup> This approach gives excellent access for removing the tooth and adjacent pathological material.<sup>4</sup> If the tooth has not been removed, close radiographic follow up is prudent. Since the ectopic tooth was the cause of sinusitis, it was removed.

### References

1. Goh YH. Ectopic eruption of maxillary molar tooth--an unusual cause of recurrent sinusitis. *Singapore Med J.* 2001 Feb;42(2):80-1.
2. Elango S, Palaniappan SP. Ectopic tooth in the roof of the maxillary sinus. *Ear Nose Throat J.* 1991 Jun;70(6):365-6.
3. Di Felice R, Lombardi T. Ectopic eruption of maxillary molar tooth--an unusual cause of recurrent sinusitis. *Singapore Med J.* 2001 Feb;42(2):80-1.
4. Bodner L, Tovi F, Bar-Ziv J. Teeth in the maxillary sinus--imaging and management. *J Laryngol Otol.* 1997 Sep;111(9):820-4.
5. Alexandrakis G, Hubbell RN, Aitken PA. Nasolacrimal duct obstruction secondary to ectopic teeth. *Ophthalmology.* 2000 Jan;107(1):189-92.
6. Hasbini AS, Hadi U, Ghafari J. Endoscopic removal of an ectopic third molar obstructing the osteomeatal complex. *Ear Nose Throat J.* 2001 Sep;80(9):667-70.
7. Kim DH, Kim JM, Chae SW, et al. Endoscopic removal of an intranasal ectopic tooth. *Int J Pediatr Otorhinolaryngol.* 2003 Jan;67(1):79-81.
8. Altas E, Karasen MR, Yilmaz AB, et al. A case of a large dentigerous cyst containing a canine tooth in the maxillary antrum leading to epiphora. *J Laryngol Otol.* 1997 Jul;111(7):641-3.

## About the Authors

**M. Cemil Büyükkurt, DDS, PhD**



Dr Büyükkurt is an Assistant Professor in the Department of Oral and Maxillofacial Surgery in the Faculty of Dentistry at Ataturk University in Erzurum, Turkey.

e-mail: [mcbuyukkurt@yahoo.com](mailto:mcbuyukkurt@yahoo.com)

**Sinan Tozoğlu, DDS, PhD**



Dr Tozoglu is an Assistant Professor in the Department of Oral and Maxillofacial Surgery in the Faculty of Dentistry at Ataturk University in Erzurum, Turkey.

**M. Hamdi Aras**



Mr. Aras, is a researcher in the Department of Oral and Maxillofacial Surgery in the Faculty of Dentistry at Ataturk University in Erzurum, Turkey.

**Ümit Yolcu**



Mr. Yolcu is a researcher in the Department of Oral and Maxillofacial Surgery in the Faculty of Dentistry at Ataturk University in Erzurum, Turkey.