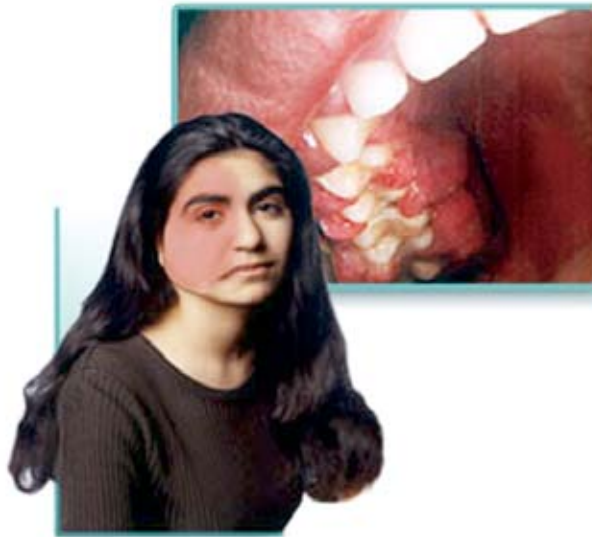

Rare Instance of Gingival Enlargement in Klippel-Trenaunay Syndrome: A Case Report

Pradeep S. Anand, MDS; T. Roshna, MDS



Abstract

Klippel-Trenaunay Syndrome is a rare congenital malformation that may include port-wine stain, soft tissue and bony hypertrophy, and venous malformations and lymphatic abnormalities. Although it usually involves the limbs, it may also rarely involve the head, neck, and orofacial regions. Despite its rarity, Klippel-Trenaunay Syndrome should be considered in the differential diagnosis of gingival enlargement. The condition can be easily recognized clinically, but further investigations including imaging studies have to be carried out in order to better understand the nature of the lesion. This report describes a case of gingival enlargement in Klippel-Trenaunay Syndrome in a 16-year-old female patient. The diagnosis of the condition was made based on the patient history, clinical and radiographic examination, computed tomography (CT), and angiogram.

Keywords: Gingival hyperplasia, Klippel Trenaunay disease

Citation: Anand PS, Roshna T. Rare Instance of Gingival Enlargement in Klippel-Trenaunay Syndrome: A Case Report. J Contemp Dent Pract 2006 July;(7)3:092-098.

Introduction

Klippel-Trenaunay Syndrome was first described by two French doctors, Klippel and Trenaunay, in 1900. The Klippel-Trenaunay Syndrome is a rare congenital malformation that may include the following, which are described as a triad of symptoms affecting one or more limbs:¹

- Port-wine stain or “birthmark” (cutaneous capillary malformations)
- Soft tissue and bony hypertrophy (excessive growth of the soft tissue and/or bones)
- Venous malformations and lymphatic abnormalities

The terms Klippel-Trenaunay Syndrome and Klippel-Trenaunay-Weber Syndrome have been used interchangeably. But at present, Klippel-Trenaunay Syndrome is described as hypertrophy and varicosity associated with port-wine staining; Klippel-Trenaunay-Weber Syndrome (more correctly called Parkes-Weber Syndrome) is similar but includes significant arteriovenous malformations with shunting. Klippel-Trenaunay Syndrome generally affects a single extremity, although cases of multiple affected limbs have been reported. The lower limb is the most common site, with involvement seen in about 95% of the patients^{2,3}, followed by the arms and the trunk. The condition rarely involves the head and the neck. All three signs of the clinical syndrome—port-wine stain, varicose veins, and bony and soft tissue hypertrophies are seen in most patients. There have been very few reports of Klippel-Trenaunay Syndrome involving the orofacial region.^{4,5} When the condition involves the oral cavity, the characteristic findings include an enlarged maxilla, displacement of teeth, and malocclusion.⁴ Premature tooth eruption has also been reported.⁵ There has been one earlier report of gingival enlargement occurring in Klippel-Trenaunay Syndrome.⁶ Another report described the occurrence of hereditary gingival fibromatosis in association with Klippel-Trenaunay-Weber Syndrome.⁷ Some authors suggest Sturge-Weber Syndrome and Klippel-Trenaunay-Weber Syndrome are two manifestations of one single entity.⁸ Patients with port-wine stain are said to have Sturge-Weber Syndrome if they also show “tram-line” calcifications on radiographs of the skull and the presence of angiomas along the distribution of the ophthalmic branch of the trigeminal nerve.⁹

Patients with Klippel-Trenaunay Syndrome show no intra-cranial calcifications, and hence, unlike Sturge-Weber syndrome patients, do not have a history of seizures. Although the two conditions rarely coexist, Reich and Wiatrak reported two patients with both of these angiomas.¹⁰

This report describes a case of gingival enlargement occurring in Klippel-Trenaunay Syndrome in a 16-year-old female patient.

Case Report

A 16-year-old female patient presented at the Department of Periodontics with the complaint of pain and swelling of the gingiva in relation to the right upper posterior teeth of two weeks duration. She had received antibiotics for the complaint from a general dentist. She had undergone extraction of the mandibular left first molar six months previously. Extra-orally, the patient had a diffuse port-wine staining on the right side of the face over the cheek extending from the midline to the external ear and from the forehead to the upper lip (Figure 1). The pigmentation was present from birth. The face showed asymmetry with the right side showing hypertrophy compared to the left side. There was no history of seizures, which suggested absence of intra-cranial calcifications seen in Sturge-Weber Syndrome.

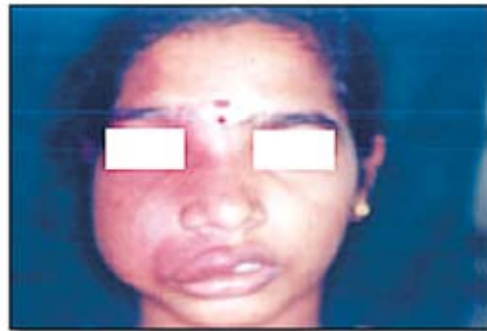

Figure 1. Port-wine staining and hypertrophy of right side of the face.

Intra-oral examination showed enlargement of the buccal and palatal gingiva in relation to the right maxilla (Figures 2 and 3). The enlargement extended from the maxillary right second molar up to the midline (Figure 4). The enlargement was diffuse, bright red in color, and pebbly in appearance. On gentle

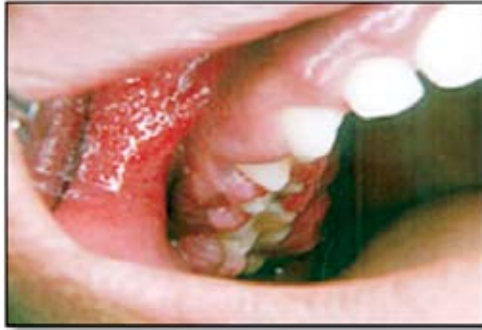

Figure 2. Gingival enlargement on the buccal aspect of the right maxillary teeth.

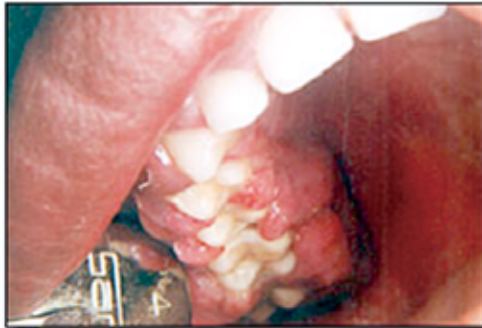

Figure 3. Gingival enlargement on the palatal aspect of the right maxillary teeth.

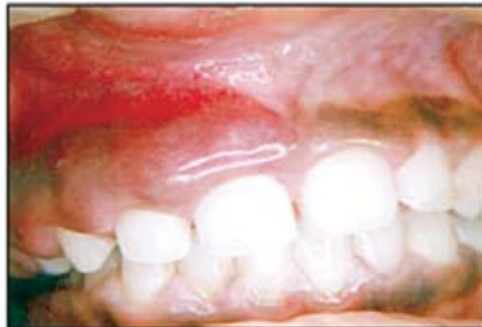

Figure 4. Gingival enlargement in relation to the right maxillary teeth extending up to the midline.

palpation, the tissue was found to be soft and edematous. The gingiva in relation to the right mandible appeared normal. The maxillary right first premolar exhibited grade I mobility, while the second premolar, first, and second molars exhibited grade II mobility. The mandibular right second molar showed caries with exposure of the pulp.

Intra-oral periapical and panoramic radiographs were taken which did not show significant changes in the bone structure. The patient was referred to Department of Radiodiagnosis for further investigation.

Computed tomography (CT) was done which showed enlargement of the soft tissues overlying the right maxilla (Figure 5). It also showed definite enlargement of the right maxilla (Figure 6).

The brain showed no evidence of involvement, and there was no evidence of intra-cranial calcifications (Figure 7). There was no evidence of Sturge-Weber Syndrome.

Later, an angiogram was performed at the Department of Radiology, Sri Chitra Thirunal Institute of Medical Sciences and Technology in Trivandrum, India. The angiogram showed there was no arteriovenous malformation. The aortogram showed the feeder vessel for the hemangioma was the right internal maxillary artery as evidenced by the “blush” seen in the view when the dye was injected into the artery (Figure 8). When the dye was injected into the facial and lingual arteries, there was no such “blush” indicating the blood vessels did not contribute to the hemangioma.

As the condition warranted surgical management under hospital facilities, the patient was then referred to the Department of Plastic Surgery, Government Medical College, in Trivandrum, India for further management. The surgical procedure was planned to be performed in multiple stages for both the treatment of gingival enlargement and for cosmetic reasons as well. The first stage surgery planned was a debulking procedure to remove the hemangioma on the right side of the face by an intra-oral approach with the incision placed on the upper labial mucosa. The surgical procedures for the management of the gingival enlargement were to be performed in subsequent stages. Prior to all the surgical procedures, the feeder vessel, the right internal maxillary artery, would be embolised with gel foam. The treatment plan and the surgical procedure were explained to the patient and the patient’s parents, and the patient opted not to undergo the surgical procedure.

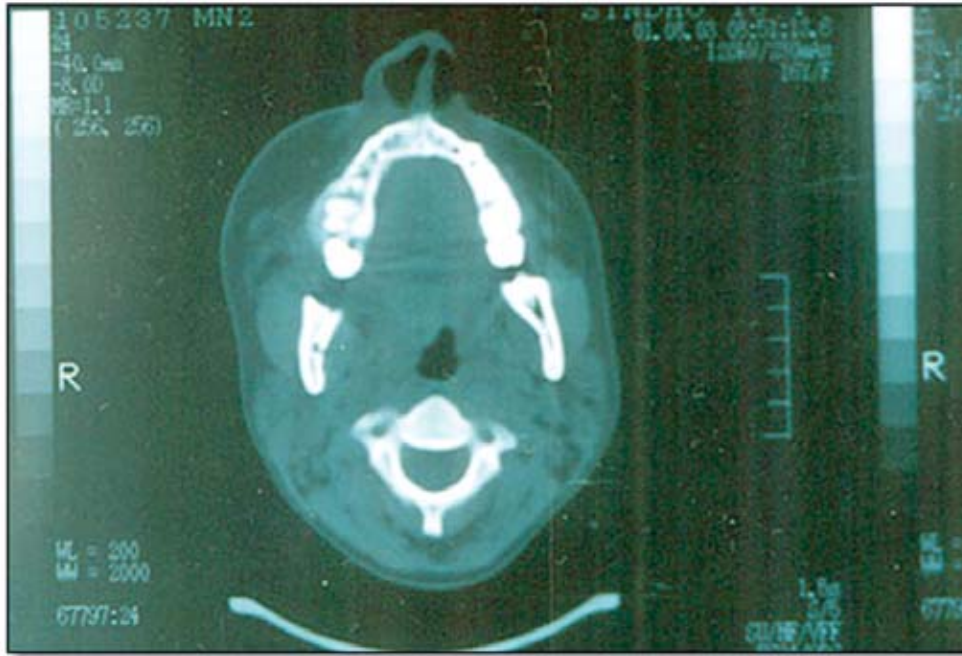


Figure 5. CT scan showing soft tissue hypertrophy over the right maxilla.

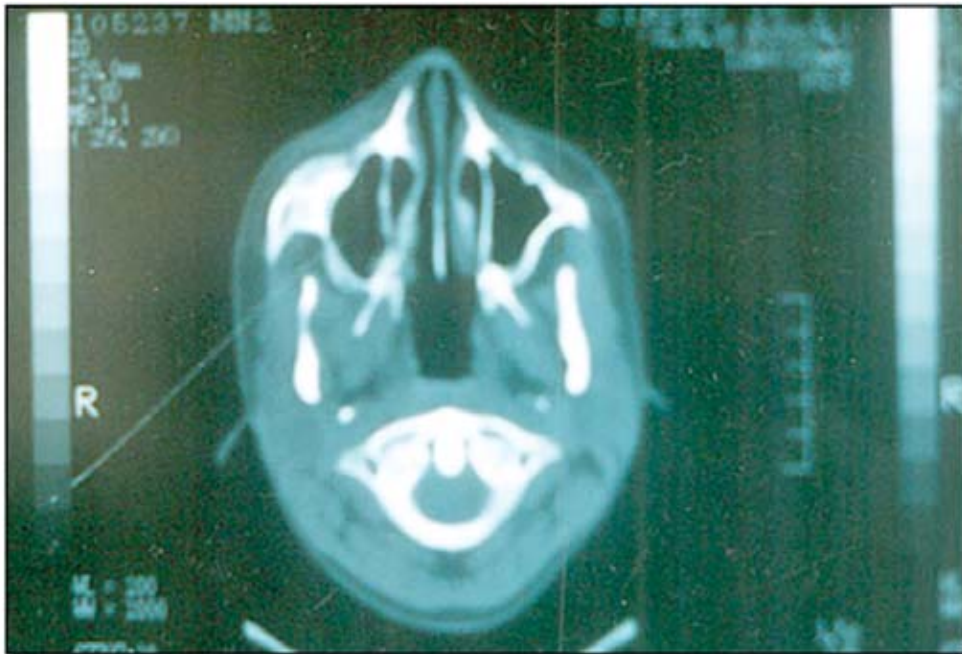


Figure 6. CT scan showing enlargement of the right maxilla.

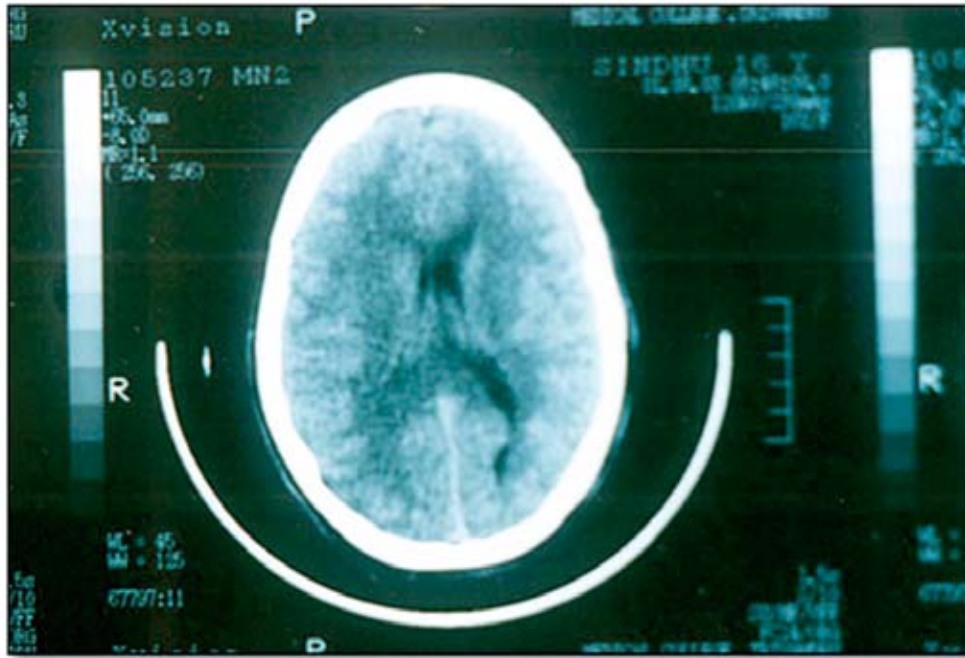


Figure 7. CT scan showing normal brain structure.

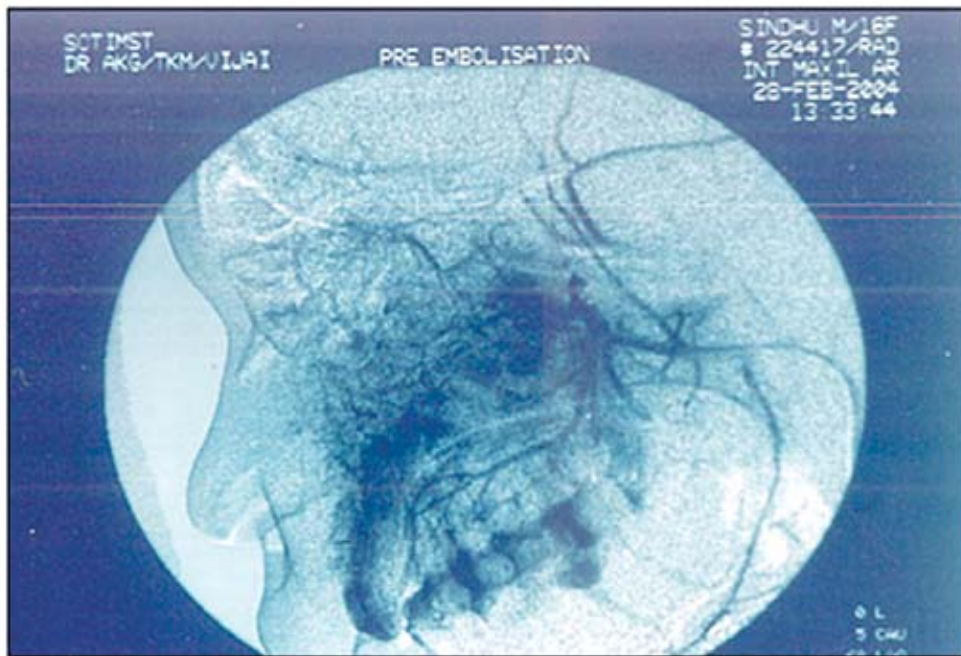


Figure 8. Aortogram with the catheter at the level of the internal maxillary artery showing the “blush” along the distribution of the artery.

Discussion

Klippel-Trenaunay Syndrome involving the orofacial tissues is rare. Involvement of the oral cavity can result in an enlarged maxilla, displacement of teeth, and malocclusion.⁴ Although the diagnosis can be made on clinical grounds, further investigations need to be carried out.

The exact cause of Klippel-Trenaunay Syndrome/Klippel-Trenaunay-Weber Syndrome remains to be elucidated, although several theories exist. Among the various theories, one suggests Klippel-Trenaunay Syndrome may be caused by mesodermal abnormalities during fetal development, while another medical opinion suggests the cause could be the result of a gene mutation. According to Bliznak and Staple, intrauterine damage to the sympathetic ganglia or intermediolateral tract leading to dilated microscopic arteriovenous anastomoses is the cause.¹¹ Servelle suggested deep vein abnormalities, with resultant obstruction of venous flow, lead to venous hypertension, the development of varices, and limb hypertrophy.¹² Baskerville et al. opined that a mesodermal defect during fetal development causes maintenance of microscopic arteriovenous communications.¹³ According to McGrory and Amadio, an underlying mixed mesodermal and ectodermal dysplasia is likely to be responsible for the development of Klippel-Trenaunay-Weber Syndrome.¹⁴ Most cases are sporadic, although a few cases in the literature report an autosomal dominant pattern of inheritance.¹⁵

Complications may arise either due to hemangiomas or due to varicosities. Complications of hemangiomas include skin breakdown and ulceration, bleeding, and secondary infection. Complications due to varicosities include thromboembolism¹⁶, paresthesia, stasis ulcers, pulmonary emboli, thrombophlebitis, stasis dermatitis, and hemorrhage.

When complications are present, imaging studies can be useful. A CT can be a useful diagnostic. Evaluation of the deep venous system can be completed with duplex scanning contrast venography, ultrasonography, contrast venography and arteriography, and nuclear magnetic resonance imaging (MRI) studies.¹⁷

Management of this syndrome can be divided into medical and surgical interventions.

Medical Care

Treatment is conservative and symptomatic. Complications such as cellulitis and thrombophlebitis can be managed with analgesics, elevation, antibiotics, and corticosteroids.¹⁸ Intermittent or prophylactic antibiotics can be considered for patients with a history of recurrent cellulitis. Anticoagulant therapy is indicated in acute thrombosis and prophylactically prior to surgical procedures. Given the risk of thrombotic events, women with Klippel-Trenaunay-Weber Syndrome should avoid using oral contraceptive pills.

When the condition involves the gingiva, as in the present case, care should be taken not to traumatize the gingival tissues during examination or treatment. Periodontal probing should not be done as even probing can result in uncontrolled bleeding. Non-surgical management includes oral hygiene instructions and plaque control with the aid of mouthwashes.

Surgical Care

Surgery should be considered in cases where skin ulcerations lead to persisting and recurrent bleeding or where significant deformities or overgrowth leads to both functional and psychological impairment.¹⁸ Laser treatment of the hemangioma can be effective in lightening the color of the port-wine stain.^{19,20} Laser treatment is also indicated in the case of ulceration. Ulceration of hemangiomas can be painful and can impair functional abilities. When treated with laser, ulcers often heal more quickly. Laser treatment is most effective when performed early, as it can improve the long-term appearance of the port-wine stain and, thereby, also improve function. Lasers have been used for gingivectomy in patients with Sturge-Weber Syndrome.²¹ Typically, several treatments are required to achieve the desired effect. Laser treatment only helps with the superficial component of the hemangioma.

Surgical procedures can be performed for the treatment of varicosities and venous malformations, but it is controversial. One might consider surgery for either significant

cosmetic deformity or the symptoms of pain, bleeding, or infectious complications. Venous stripping, ligation, excision, or sclerotherapy are contraindicated unless the surgery involves the superficial system and the underlying deep system is normal or demonstrates only mild-to-moderate reflux. Woods²² reported the sclerosing agent sodium tetradecyl sulfate, used appropriately, is a safe and frequently effective agent in the treatment of hemangiomas and a number of similar or related problems. It is especially useful in the management of cavernous hemangiomas where there are no arterio-venous malformations. Debulking procedures can be done but have limited use and may damage venous and lymphatic structures, leading to increased edema in the affected site. Symptomatic superficial varicosities can be removed without harm and with benefit to the patient when an adequate preoperative examination is performed. Although Baskerville et al.¹³ demonstrated that some 90% of treated varicosities redevelop, treatment can provide lasting improvement for years.

Although patients with severe chronic venous insufficiency, disturbing cosmetic appearance, or

complications of hemangioma may benefit from surgical treatment, detailed preoperative imaging to understand the nature of the vascular lesion is needed to decrease complications.²³ Inadequate evaluation prior to excision increases surgical complications. Embolisation of the hemangioma should be done. The agents used for embolisation include gelfoam and polyvinyl alcohol. The potential risks and benefits must be carefully weighed before attempting surgical intervention.

Conclusion

In conclusion, although it rarely involves the orofacial region, Klippel-Trenaunay Syndrome should be included in the differential diagnosis of severe gingival enlargement. In view of the potentially dangerous complications that can arise, it is imperative the dental surgeon has a thorough knowledge about the condition. Although the condition can be recognized clinically, further investigations including imaging studies have to be carried out in order to better understand the nature of the lesion. The condition can be managed in a conservative manner or by a surgical approach depending upon the nature of the patient's complaints.

References

1. Meine JG, Schwartz RA, Janniger CK. Klippel-Trenaunay-Weber syndrome. *Cutis* 1997; 60: 127-132.
2. Al-Salman MM. Klippel-Trenaunay syndrome: Clinical features, complications, and management. *Surg Today* 1997; 27: 735-740.
3. Berry SA, Peterson C, Mize W, Bloom K, Zachary C, Blasco P, Hunter D. Klippel-Trenaunay syndrome. *Am J Med Genet* 1998; 79: 319-326.
4. Steiner M, Gould AR, Graves SM, Kuerschner TW. Klippel-Trenaunay-Weber syndrome. *Oral Surg Oral Med Oral Pathol.* 1987; 63: 208-215.
5. Mueller-Lessmann V, Behrendt A, Wetzel WE, Petersen K, Anders D. Orofacial findings in the Klippel-Trenaunay syndrome. *Int J Paediatr Dent.* 2001; 11: 225-229.
6. Bathi RJ, Agarwal N, Burde KN. Klippel-Trenaunay syndrome (angio osteohypertrophy syndrome): a report of 3 cases. *Oral Surg Oral Med Oral Pathol Oral Radiol Endod.* 2002; 93: 276-280.
7. Hallett KB, Bankier A, Chow CW, Bateman J, Hall RK. Gingival fibromatosis and Klippel-Trenaunay-Weber syndrome. Case report. *Oral Surg Oral Med Oral Pathol Oral Radiol Endod.* 1995; 79: 578-582.
8. Happle R. Sturge-Weber-Klippel-Trenaunay syndrome: What's in a name? *Eur J Dermatol.* 2003; 13: 223.
9. Soft Tissue Tumors. In: Neville BW, Dam DD, Allen CM, Bouquot JE, eds. *Oral and Maxillofacial Pathology.* WB Saunders Company; 1995: 362-415.
10. Reich DS, Wiatrak BJ. Upper airway obstruction in Sturge-Weber and Klippel-Trenaunay-Weber syndromes. *Ann Otol Rhinol Laryngol.* 1995; 104: 364-368.
11. Bliznak J, Staple TW. Radiology of angiodysplasias of the limb. *Radiology* 1974; 110: 35-44.
12. Servelle M. Klippel and Trenaunay's syndrome. 768 operated cases. *Ann Surg* 1985; 201: 365-373.

13. Baskerville PA, Ackroyd JS, Browse NL. The etiology of the Klippel-Trenaunay syndrome. *Ann Surg* 1985; 202: 624-627.
14. McGrory BJ, Amadio PC. Klippel-Trenaunay syndrome: orthopaedic considerations. *Orthop Rev* 1993; 22: 41-50.
15. Aelvoet GE, Jorens PG, Roelen LM. Genetic aspects of the Klippel-Trenaunay syndrome. *Br J Dermatol* 1992; 126: 603-607.
16. Aggarwal K, Jain VK, Gupta S, Aggarwal HK, Sen J, Goyal V. Klippel-Trenaunay syndrome with a life-threatening thromboembolic event. *J Dermatol*. 2003; 30: 236-240.
17. Williams DW, Elster AD. Cranial CT and MR in the Klippel-Trenaunay-Weber syndrome. *AJNR Am J Neuroradiol*. 1992; 13: 291-294.
18. Capraro PA, Fisher J, Hammond DC, Grossman JA. Klippel-Trenaunay syndrome. *Plast Reconstr Surg*. 2002; 109: 2052-2060; quiz 2061-2062.
19. Spicer MS, Goldberg DJ, Janniger CK. Lasers in pediatric dermatology. *Cutis* 1995; 55: 270-272, 278-280.
20. Yamauchi PS, Soriano TT, Lask GP. Treatment of port wine stains using the pulsed-dye laser at 585 nm with the dynamic cooling device. *J Cutan Laser Ther* 2000; 2 : 33-36.
21. Hylton RP. Use of CO2 laser for gingivectomy in a patient with Sturge-Weber disease complicated by dilantin hyperplasia. *J Oral Maxillofac Surg*. 1986; 44: 646-648.
22. Woods JE. Extended use of sodium tetradecyl sulfate in treatment of hemangiomas and other related conditions. *Plast Reconstr Surg*. 1987; 79: 542-549.
23. Gloviczki P, Stanson AW, Stickler GB, Johnson CM, Toomey BJ, Meland NB, Rooke TW, Cherry KJ Jr. Klippel-Trenaunay syndrome: the risks and benefits of vascular interventions. *Surgery* 1991; 110: 469-479.

About the Authors

Pradeep S. Anand, MDS



Senior Lecturer in Periodontics at Sri Sankara Dental College, Varkala, Kerala State, India.

e-mail: pradeepsanand@rediffmail.com

T. Roshna, MDS



Senior Lecturer in Periodontics at Seema Dental College, Hrishikesh, Uttaranchal State, India.

e-mail: roshna_t@yahoo.com