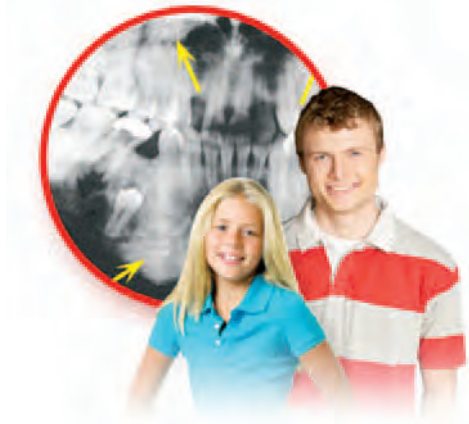

## Oral and Maxillofacial Manifestations of Familial Adenomatous Polyposis (Gardner's syndrome): A Report of Two Cases

Marina de Oliveira Ribas, DDS, MsC, PhD;  
Wilson Denis Martins, DDS, PhD;  
Maria Helena de Sousa, DDS, MsC;  
Ana Cláudia Galvão de Aguiar Koubik, DDS, MsC;  
Lucia Fátima Castro Ávila, DDS, MsC;  
Fernando Luis Zanferrari, DDS, MsC; Guilherme Martins



### Abstract

**Aim:** The aim of this case report is to emphasize the importance of an early diagnosis of Gardner's syndrome through the detection of lesions appearing in the oral and maxillofacial area as well as to present two cases of the disease.

**Background:** Gardner's syndrome is an autosomal dominant disease characterized by gastrointestinal polyps that develop in the colon as well as in the stomach and upper intestine, along with multiple osteomas, skin, and soft tissue tumors. Cutaneous findings may include desmoid tumors, epidermoid cysts, and other benign tumors. Early diagnosis and therapy of the disease are critical because polyps have a 100% risk of undergoing malignant transformation. Craniomaxillofacial manifestations (osteoma formation, tooth impaction, diffuse opacities in the skull, mandible and maxilla, scalp tumors) usually precede polyposis.

**Report: Case 1:** Gardner's syndrome was diagnosed in a 25-year-old Caucasian man who was referred by his endodontist for evaluation of an uncommon radiographic image in the mandibular molar area. Further investigation revealed a familial adenomatous polyposis (FAP) complicated by adenocarcinoma of the colon. A

colectomy and an ileorectal anastomosis were performed. **Case 2:** A 12-year-old Caucasian girl, who is a niece of the patient described in Case 1, presented with progressive difficulty with mouth opening but no complaints of digestive problems. Radiographic examination revealed multiple radiopacities in the maxilla, mandible left temporomandibular joint, and in the left mandibular angle. Multiple impacted teeth were present. A colonoscopy was suggested, but the patient's parents decided to continue the investigation and treatment with their own physician in their home town.

**Summary:** Since an early diagnosis is essential and general dental practitioners may be the first healthcare professionals to suspect the diagnosis, it is important for them to be familiar with the features of Gardner's syndrome.

**Keywords:** Gardner's syndrome, familia adenomatous polyposis, FAP, osteomas

**Citation:** de Oliveira Ribas M, Martins WD, de Sousa MH, de Aguiar Koubik ACG, Ávila LFC, Zanferrari FL, Martins G. Oral and Maxillofacial Manifestations of Familial Adenomatous Polyposis (Gardner's syndrome): A Report of Two Cases. *J Contemp Dent Pract* 2009 January; (10)1:082-090.

## Introduction

Originally described as two different syndromes, familial adenomatous polyposis (FAP) and Gardner's syndrome were later considered as a single condition and classified under a single OMIM number (OMIM 175000) which describes Gardner's syndrome as a variant of FAP.<sup>1-4</sup> The OMIM (Online Mendelian Inheritance in Man) is a unique six-digit number assigned to each entry listed in the catalog of human genes and genetic disorders. Gardner<sup>2</sup> described manifestations of FAP that extended beyond the colorectum. He described a family with intestinal polyposis and multiple bony and soft tissue tumors which were subsequently characterized as multiple osteomas, cutaneous and subcutaneous fibromas, and epidermoid cysts.<sup>3</sup>

The triad of osteomas, soft tissue lesions, and FAP has now been expanded to include other lesions, including desmoid tumors, retinal pigmentation, carcinomas, sebaceous cysts, gastric and upper intestinal adenomas, pancreaticobiliary adenomas, hepatoblastomas,<sup>5-10,13</sup> and dental abnormalities.<sup>11</sup>

Malignant central nervous system tumors were associated with FAP by Turcot et al.<sup>12</sup> Other lesions have been associated with FAP,<sup>14,15</sup> but it is unclear as to whether they are coincidental occurrences or part of the genetic defect itself.

Oral and maxillofacial symptoms of FAP include an increased risk of osteomas in the jaws,

odontomas, supernumerary, or unerupted teeth. The oral and maxillofacial hallmark of Gardner's syndrome is the osteoma. The most common location is the mandible, but they may occur in the skull, long bones, and paranasal sinus cavities.<sup>16,17</sup> Takeuchi et al.<sup>18</sup> found oral and maxillofacial lesions in 22 of 23 patients with Gardner's syndrome.

The objectives of this report are to present two cases of Gardner's syndrome and to highlight the importance of an early diagnosis of this pathology since the lesions that settle in the oral and maxillofacial area play an important diagnostic role as pointed out by Chimenos-Kustner et al.<sup>19</sup> and Wijn et al.<sup>20</sup>

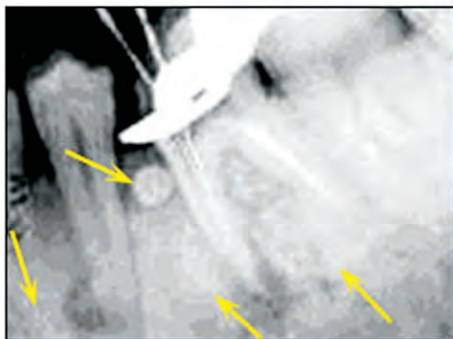
## Case Reports

### Case 1

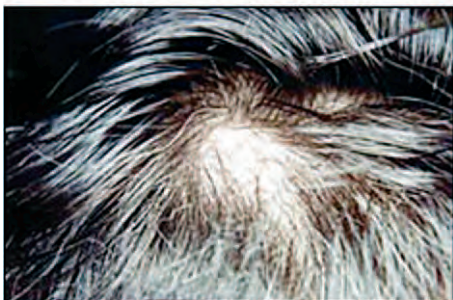A 25-year-old Caucasian man was referred by an endodontist for evaluation of a dental abscess in tooth #47 that had been treated. A periapical radiograph disclosed a diffuse radiopaque cotton wool-like image and a smaller well-defined round radiopaque image (Figure 1).

Prior to a recent endodontic problem the patient had no complaints with regard to his jaws. There were no problems with chewing or mouth opening. When asked directly about other diseases, he reported several previous surgeries for removal of "sebaceous cysts" in his body.

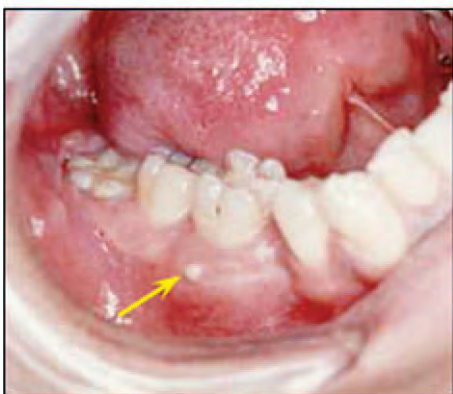The patient also suffered from occasional rectal bleeding and mucus discharge with defecation. When asked directly about his family history, he reported his father and his brother had died “with



**Figure 1.** Initial periapical radiograph provide by the referring endodontist showing diffuse radiopaque areas, altering the bony pattern of the region. A small rounded image is seen between the second premolar and the first molar in the crest of the septum.



**Figure 2.** A mobile subcutaneous nodule in the occipital region.



**Figure 3.** Submucosal round, hard nodules in the vestibule of the right molar region. Note the small round pearl like structure 3 mm above the gingival margin of the first molar.

bowel cancer.” Physical examination revealed a 3 cm mobile subcutaneous nodule on his scalp (Figure 2).

Multiple painless hard masses on the mandible and skull were present. The largest palpable hard mass was located on the left mandibular angle. Intraoral examination revealed various submucosal hard masses, mainly in the mandibular external cortex. A small round pearl-like structure was observed in the right molar region (Figure 3).

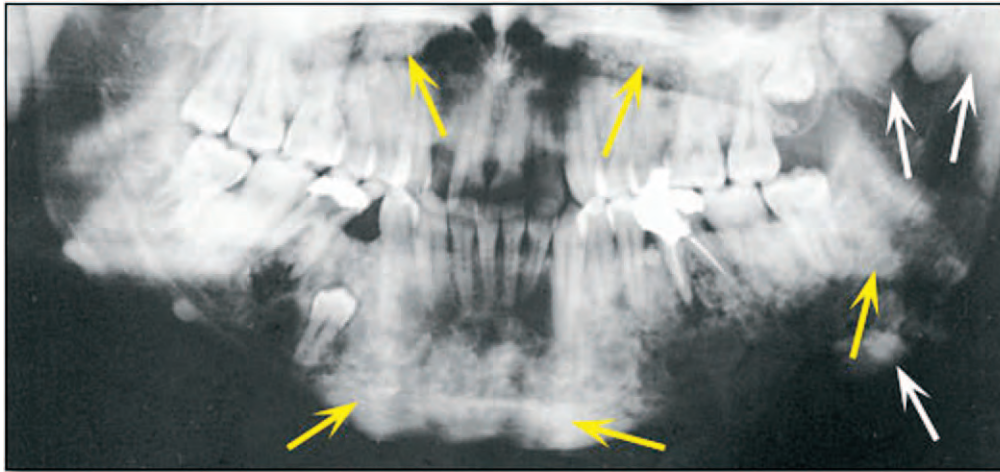
A panoramic radiograph revealed generalized, diffuse, cotton wool-like radiopaque images in both the maxilla and mandible and maxillary sinus. In addition, apical radiolucent areas suggestive of abscesses were evident near several teeth. Some round or ovoid dense radiopaque images were in the temporomandibular areas and in the left mandibular angle along with two impacted teeth (a left maxillary third molar and a second mandibular bicuspid) (Figure 4).

Computed tomography was used to detect extensive diffuse radiopacities (cotton-wool like images of both external and internal cortex) of the skull bones (Figure 5).

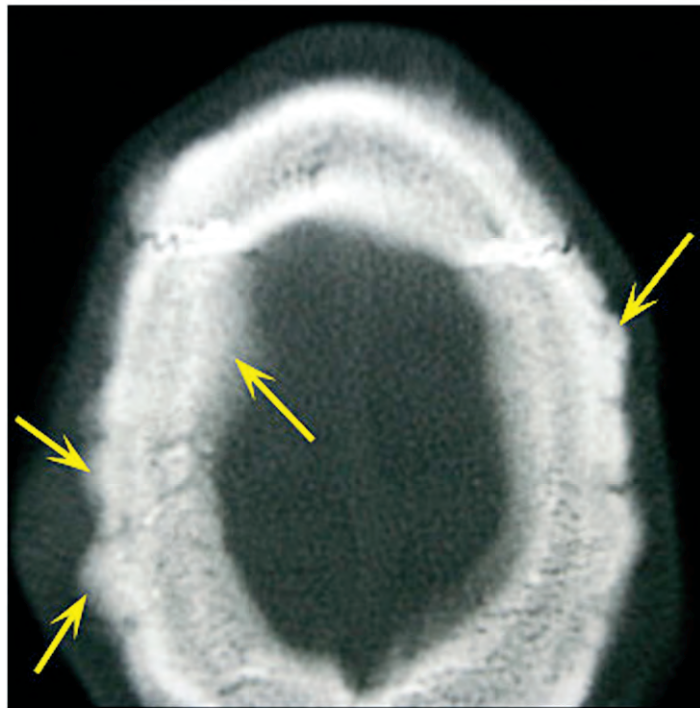
Several well circumscribed radiopaque areas were detected in the ethmoid region and in the nasal walls near the upper conchae and zygomatic areas, sphenoid bone, skull base, and bilateral temporomandibular joint condyles (Figures 6, 7, 8 and 9). Figure 9 shows details of the extensive lesions of the maxilla.

Based on these clinical and radiographic findings Gardner’s syndrome was suspected, and the patient was referred for an urgent colorectal evaluation.

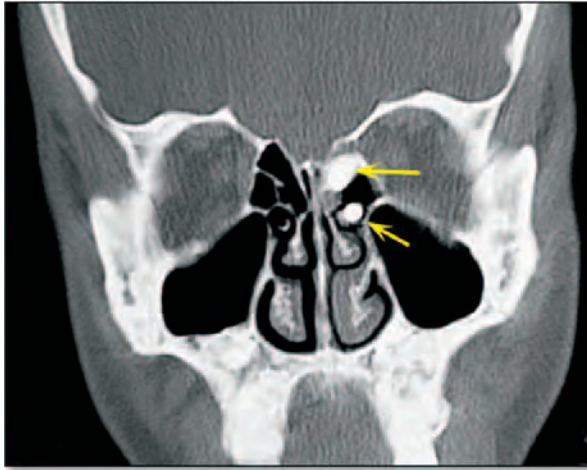
The colonoscopy examination revealed numerous polyps carpeting the colon but the rectum was relatively polyp free. A small ulcerating mass was found in the distal portion of the colon. Histologic examination of the specimen revealed it to be adenocarcinoma. A colectomy and an ileorectal anastomosis were performed by general surgeons.



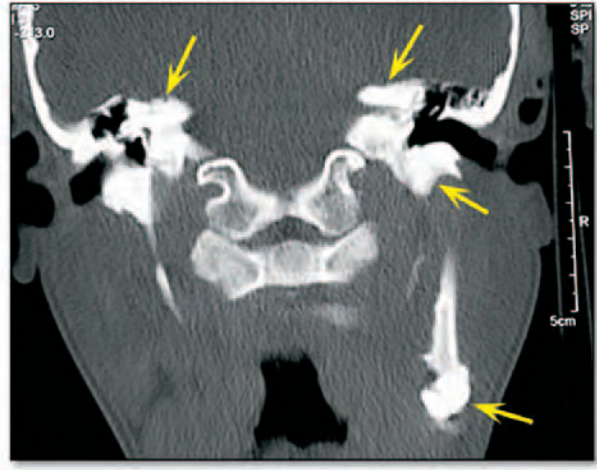
**Figure 4.** Cotton wool-like radiopaque images in both the maxilla and mandible and maxillary sinus (yellow arrows). Round or ovoid dense radiopaque images were in the temporomandibular areas and in the left mandibular angle (white arrows).



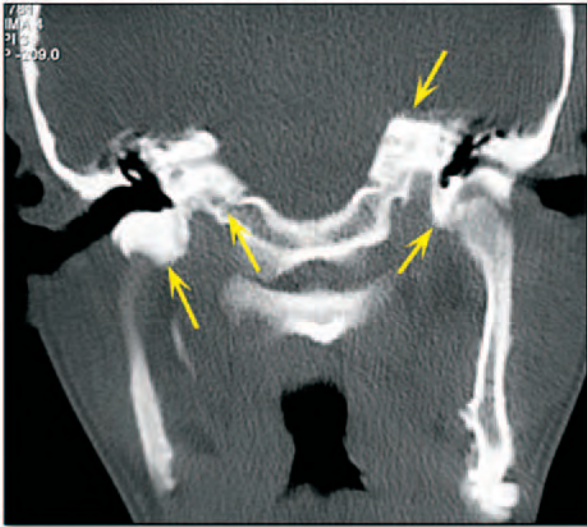
**Figure 5.** CT showing cotton-wool like images of the skull bones. (yellow arrows).



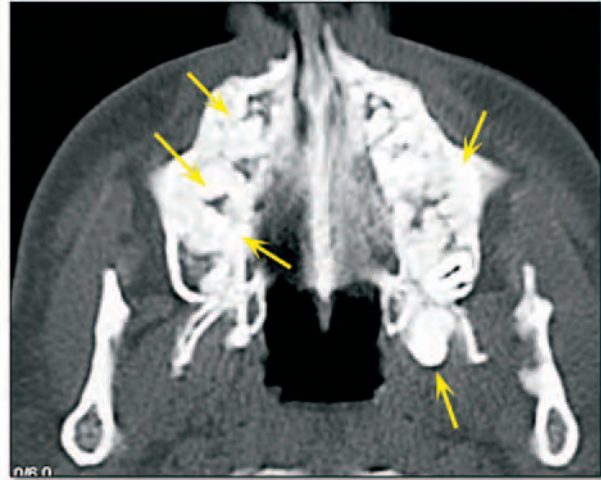**Figure 6.** Well circumscribed radiopaque areas in the ethmoid and nasal wall regions.



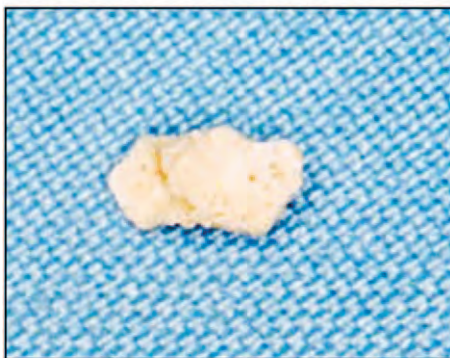**Figure 7.** Radiopaque areas in the sphenoid bone, skull base, and bilateral temporomandibular joint condyles.



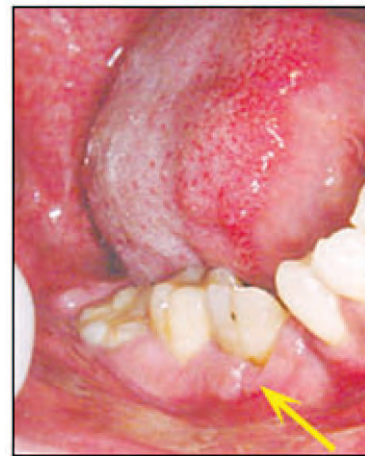**Figure 8.** Radiopaque areas in the condyles, temporomandibular fossa, and in the mandibular angle region.



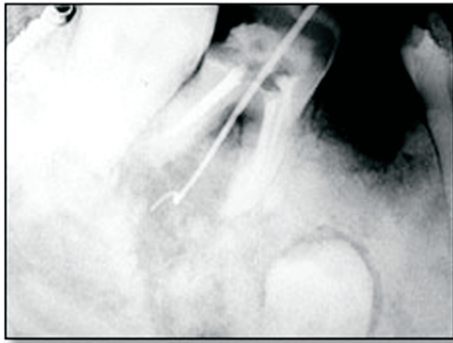**Figure 9.** Extensive compromise of the maxilla, presenting multiple radiopaque areas.



**Figure 10.** Bony fragment removed from the right molar region.



**Figure 11.** Clinical aspect of the periodontal pocket in the first molar, after elimination of the bony fragment.



**Figure 12.** Periapical image of the first molar, with a gutta percha probe in place, showing the extent of the periodontal pocket.

Microscopic examination of the colon confirmed more than 50 adenomatous polyps, none of which had undergone malignant change. The surgical option of performing the colectomy and ileorectal anastomosis spares the patient the morbidity associated with the more radical pelvic dissection to remove the rectum. The retained rectal mucosa remains susceptible to malignant change, and the patient is committed to annual endoscopic surveillance of the rectum.

After the patient was treated for the adenocarcinoma, it was proposed to surgically remove some of the bony masses of the mandible. However, the patient refused further treatment in the maxillofacial area.

A familial investigation was done. As reported in the initial consultation, his father and one brother died of "bowel cancer." His 12-year-old niece also presented for examination presenting several symptoms of Gardner's syndrome (Case 2 in this report).

Two years after the bowel surgery, the patient suffered a spontaneous elimination of a 3 x 5 mm bony fragment from the right mandibular molar region (Figure 10), resulting in a periodontal pocket in the first molar (Figures 11 and 12).

Histologically, the specimen showed trabeculae of lamellar bone with a fibrofatty marrow, confirming the diagnosis of peripheral osteoma.

## Case 2

A 12-year-old Caucasian girl, a niece of the patient described in Case 1, presented for consultation with a history of progressive difficulty with mouth opening but no complaints of digestive problems. A panoramic radiograph showed multiple radiopacities in the maxilla and mandible. Some were diffuse (right mandibular body, left and right maxillary tuberosities) with a cotton-wool appearance while others were well circumscribed (left mandibular angle). Multiple impacted teeth were also present (Figure 13). Figure 14 reveals the extensive tumor located in the left mandibular angle.

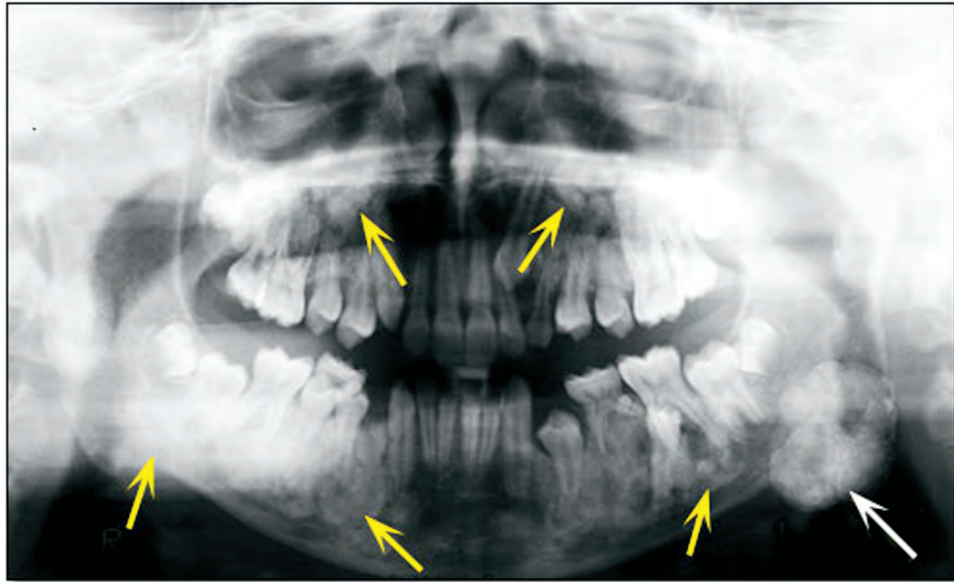
A colonoscopy was suggested, but the patient's parents decided to continue the investigation and treatment with their own physician in their home town.

## Discussion

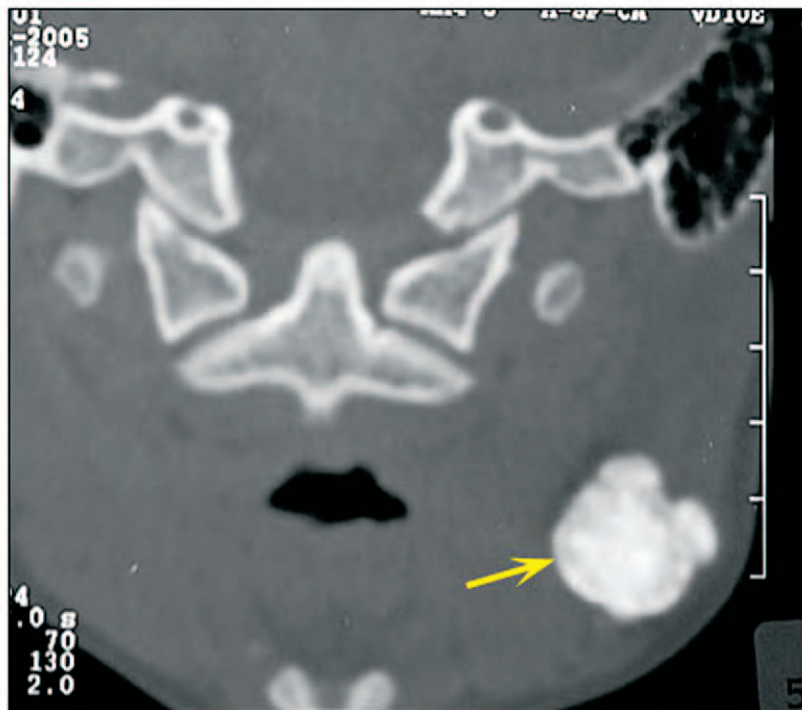
FAP is the most common polyposis syndrome with a prevalence of about 1 in 8,000.<sup>21</sup> In general, the cutaneous and bone abnormalities develop approximately 10 years prior to polyposis. Polyp formation starts at puberty but diagnosis is usually in the third decade.<sup>22</sup> Unless surgical transaction is performed, gastrointestinal polyps may progress to malignancy in almost 100% of patients (rates vary from 58%-100%).<sup>23,24</sup> Progression to malignancy is usually observed in patients aged 30 to 50 years. The average age by which malignancy is diagnosed is 39.2 years.<sup>25</sup>

## Summary

Since osteoma formation (the most common accompanying bone lesion seen in Gardner's syndrome) and other maxillofacial abnormalities usually precede polyposis, the general dental practitioner may be the first healthcare professional to suspect the diagnosis. Panoramic radiography is the most useful technique for screening patients and affected family members since it can demonstrate subtle opacities at an early age.<sup>26</sup> All first and second degree relatives of patients with FAP should be evaluated for the possibility of Gardner's syndrome because an early diagnosis of this disease can lead to a better prognosis for the patient.



**Figure 13.** Multiple radiopacities in the maxilla and mandible (yellow arrows). An extensive, well circumscribed, radiopaque area in the left mandibular angle (white arrow).



**Figure 14.** Coronal CT image showing the extensive radiopaque tumor in the left submandibular angle region.

## References

1. Lockhart-Mummery P. Cancer and heredity. *Lancet* 1925; 427-429.
2. Gardner EJ. A genetic and clinical study of intestinal polyposis, a predisposing factor for carcinoma of the colon and rectum. *Am J Hum Genet* 1951; 3:167-176.
3. Gardner EJ, Richards RC. Multiple cutaneous and subcutaneous lesions occurring simultaneously with hereditary polypoidosis and osteomatosis. *Am J Hum Genet* 1953; 5:139-148.
4. Bisgaard ML, Bulow S. Familial adenomatous polyposis (FAP): Genotype correlation to FAP phenotype with osteomas and sebaceous cysts. *Am J Med Genetics* 2006; 140A:200-204.
5. Traboulsi EI, Krush AJ, Gardner EJ, Booker BA, Offerhouse GJA, Yardley JH, Hamilton SR, Luk GD, Giardiello FM, Welsh SB. Prevalence and importance of pigmented ocular fundus lesions in Gardner's syndrome. *N Engl J Med* 1987; 316:661-667.
6. Jones IT, Fazio VW, Weakley FL, Jagelman DG, Lavery IC, McGannon E. Desmoid tumors in familial polyposis coli. *Ann Surg* 1986; 204:94-97.
7. Jarvinen HJ, Sipponen P. Gastroduodenal polyps in familial adenomatous and juvenile polyposis. *Endoscopy* 1986; 18:230-234.
8. Jagelman DG, DeCosse JJ, Bussey HJR and the Leeds Castle Polyposis Group. Upper gastrointestinal cancer in familial adenomatous polyposis. *Lancet* 1988; 1:1149-1151.
9. Walsh N, Quizbash A, Banergee R, Waugh GA. Biliary neoplasia in Gardner's syndrome. *Arch Patol Lab Med* 1987; 111:76-77.
10. Garber JE, Li FP, Kingston JE, Krush AJ, Strong LC, Finegold MJ, Bertario L, Bulow S, Filippone A Jr, Gedde-Dahl T Jr. Hepatoblastoma and familial adenomatous polyposis. *J Natl Cancer Inst* 1988; 80:1626-1628.
11. Sondergaard JO, Bulow S, Jarvinen H, Wolf J, Witt IN, Tetens G. Dental anomalies in familial polyposis coli. *Acta Odontol Scand* 1987, 45:61-63.
12. Turcot J, Dépres JP, Pierre F. Malignant tumors of the central nervous system associated with familial polyposis of the colon: report of two cases. *Dis Colon Rectum* 1959, 2:465-468.
13. Bell B, Mazzaferri EL. Familial adenomatous polyposis (Gardner's syndrome) and thyroid carcinoma: a case report and review of the literature. *Dis Colon Rectum* 1993; 38:185-190.
14. Bulow S. Familial adenomatous polyposis. *Ann Med* 1989; 21:299-307.
15. Nelson RL, Orsay CP, Pearl RK, Abcarian H. The protean manifestations of familial polyposis coli. *Dis Colon Rectum* 1988; 9:699-703.
16. Oner AY, Pöcan S. Gardner's syndrome: a case report. *Brit Dent J* 2006; 200:666-667.
17. Wijn MA, Keller JJ, Giardiello FM, Brand HS. Oral and maxillofacial manifestations of familial adenomatous polyposis. *Oral Dis* 2007; 13:360-365.
18. Takeuchi T, Takenoshita Y, Kubo K, Iida M. Natural course of jaw lesions in patients with familial adenomatous polyposis (Gardner's syndrome). *Int J Oral Maxillofac Surg* 1993; 22:226-30.
19. Clhimenos-Kustner E, Pascual M, Blanco J, Finestres F. Hereditary familial polyposis and Gardner's syndrome: contribution of the odonto-stomatology examination in its diagnosis and a case description. *Med Oral Patol Oral Cir Bucal* 2005; 10:402-429.
20. Wijn MA, Keller JJ, Brand HS. Oral and maxillofacial manifestations of familial adenomatous polyposis. Gardner's syndrome. *Ned Tijdschr Tandheelkd* 2005; 112:340-344.
21. Payne M, Anderson JA, Cook J. Gardner's syndrome – a case report. *Brit Dent J* 2002; 2002 193:383-384.
22. Fotiadis C, Tsekouras DK, Antonakis P, Sfiniadakis J, Genetzakis M, Zografos GC. Gardner's syndrome: a case report and review of the literature. *World J Gastroenterol* 2005; 11:5408-5411.
23. Ascari-Raccagni A, Baldari U, Righini MG. Cutaneous symptoms of Gardner's syndrome. *J Eur Acad Dermatol Venereol* 1999; 12:80-81.
24. Perniciaro C. Gardner's syndrome. *Dermatol Clin* 1995; 13:51-56.
25. Luk GD. Diagnosis and therapy of hereditary polyposis syndromes. *Gastroenterologist* 1995; 3:153-167.
26. Bilkay U, Erdem O, Ozek C, Helvacj E, Kilic K, Ertan Y, Gurler T. Benign osteoma with Gardner syndrome. Review of the literature and report of a case. *J Craniofac Surg* 2004; 15:506-509.



## About the Authors

**Marina de Oliveira Ribas, DDS, MsC, PhD**



Dr. Ribas is an Oral and Maxillofacial Surgeon and a Professor of Stomatology at the Pontifical University of Paraná (PUCPR) in Curitiba, Brazil.

e-mail: [marina.ribas@pucpr.br](mailto:marina.ribas@pucpr.br)

**Wilson Denis Martins, DDS, PhD**



Dr. Martins is an Oral and Maxillofacial Surgeon and a Professor of Stomatology at the Pontifical University of Paraná (PUCPR) in Curitiba, Brazil.

e-mail: [w.denis@pucpr.br](mailto:w.denis@pucpr.br)

**Maria Helena de Sousa, DDS, MsC**



Dr. Sousa is a Clinical Professor at the Pontifical Catholic University of Paraná (PUCPR) in Curitiba, Brazil.

e-mail: [lena@mais.sul.com.br](mailto:lena@mais.sul.com.br)

**Ana Claudia Galvão de Aguiar Koubik, DDS, MsC**

Dr. Koubik is in private practice in Curitiba, Brazil. Her clinical interest is in stomatology and general practice.

e-mail: [dra.ana\\_claudia@terra.com.br](mailto:dra.ana_claudia@terra.com.br)

Lucia Fátima Castro Ávila, DDS, MsC



Dr. Ávila is a PhD graduate student, Stomatology, at the Pontifical Catholic University of Paraná (PUCPR) in Curitiba, Brazil.

e-mail: [lfcavila@uol.com.br](mailto:lfcavila@uol.com.br)

Fernando Luis Zanferrari, DDS, MsC



Dr. Zanferrari is a PhD graduate student, Stomatology Program, at the Pontifical Catholic University of Paraná (PUCPR) in Curitiba, Brazil.

Guilherme Martins



Mr. Martins is a dental student at the Pontifical University of Paraná (PUCPR) in Curitiba, Brazil.