

Use of Ankaferd Blood Stopper™ as a Hemostatic Agent: A Clinical Experience

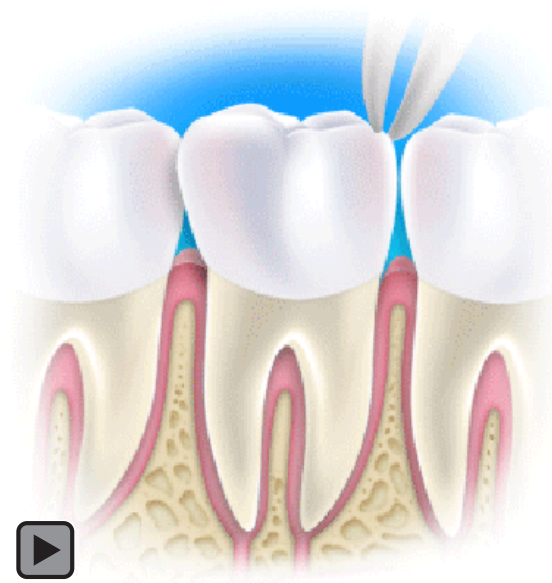
Timucin Baykul, DDS, PhD; E. Guchan Alanoglu, MD; Gulperi Kocer, DDS, PhD

Abstract

Aim: To determine the efficacy of the topical application of Ankaferd Blood Stopper™ (ABS) on hemorrhagic diathesis following dental procedures under different conditions.

Background: Some patients have a tendency to bleed excessively after dental surgery for a variety of reasons, making oral surgical procedures more risky for these patients.¹ Since hemorrhage can cause major morbidity and mortality, the identification of a novel, effective hemostatic agent could improve the management of excessive bleeding that occurs during dental procedures.

Case Descriptions: Four patients (3 females, 1 male) aged 28–45 with bleeding tendencies due to different presurgical conditions such as von Willebrand Disease, chronic liver failure, and mitral valve replacement presented for tooth extraction. Hematological consultations were obtained prior to surgical intervention and their international normalized (INR) ratio values were adjusted to less than 1.5; none received clotting factor replacement. All the extractions were performed under local anesthesia with and without epinephrine. In the presence of postsurgical bleeding, the efficacy of the ampule form of topical ABS was observed. Sex, age, anamnesis, von Willebrand Factor, activated partial thromboplastin time, factor VIII, and platelet counts of patients were recorded prior to the extractions.



Conclusions: ABS was found to be effective within 10 to 20 minutes in controlling bleeding in most of the patients after dental surgery. These observations suggest the use of ABS may be a beneficial hemostatic agent for use in patients with hemorrhagic diathesis following tooth extraction. Additional research is needed to clarify the role of this unique medicinal product in the surgical treatment of dental patients with bleeding tendency.

Clinical Significance: ABS has demonstrated potential for being an effective hemostatic agent for the treatment of excessive bleeding following dental surgery in four patients with hemorrhagic diathesis.

Keywords: Ankaferd Blood Stopper, oral surgery, bleeding

Citation: Baykul T, Alanoglu EG, Kocer G. Use of Ankaferd Blood Stopper™ as a Hemostatic Agent: A Clinical Experience. *J Contemp Dent Pract* [Internet]. 2010 Jan; 11(1):088-094. Available from: <http://www.thejcdp.com/journal/view/volume11-issue1-baykul>.

Background

Some patients have a tendency to bleed excessively after dental surgery for a variety of reasons, making oral surgical procedures more risky for these patients.¹ Since hemorrhage can cause major morbidity and mortality, the identification of a novel, effective hemostatic agent could improve the management of excessive bleeding that occurs during dental procedures.

The hemostatic action of ABS (Ankaferd Blood Stopper™, Mefar İlaç Sanayi A.S., Istanbul, Turkey) has been reported by Goker et al.² for the management of excessive hemorrhage during and after dental surgery. The ABS used in these cases was obtained from Trend Teknoloji İlaç AS, Istanbul, Turkey, as a solution for direct

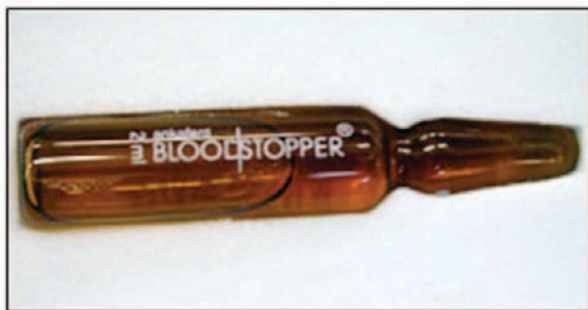

Figure 1. Ampule form of ABS.

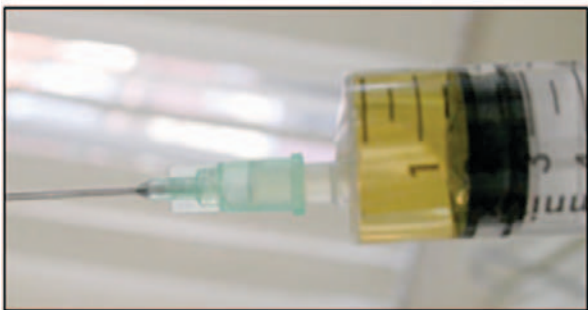
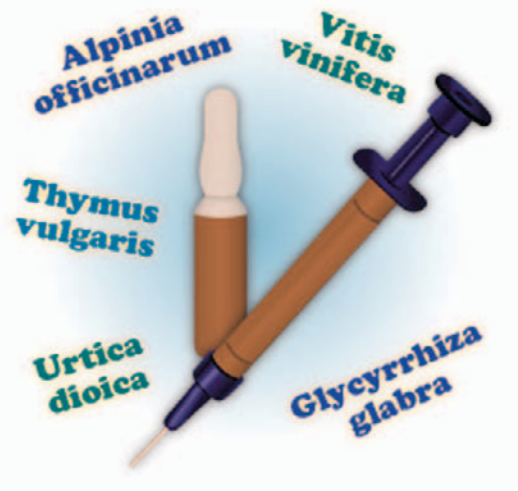
Figure 2. ABS in a syringe.



application, spraying, or incorporation in dressing material to injured skin or mucosa (Figures 1 and 2).

ABS is a unique medicinal plant extract that has been used historically in Turkish traditional medicine as a hemostatic agent. ABS consists of a standardized mixture of extracts from the following plants: *Thymus vulgaris*, *Glycyrrhiza glabra*, *Vitis vinifera*, *Alpinia officinarum*, and *Urtica dioica*.²⁻⁵ Each of these plants has some effect on the endothelium, blood cells, angiogenesis, cellular proliferation, vascular dynamics, and cell mediators. Although the basic mechanism of action for ABS remains unclear, it appears to cause the formation of an encapsulated protein network that provides focal points for vital erythrocyte aggregation. Ankaferd-induced protein network formation with blood cells, particularly erythrocytes, covers the primary and secondary hemostatic system without disturbing individual coagulation factors.² The findings of that study precipitated an interest in determining the clinical experience using ABS as a hemostatic agent following oral surgical procedures on four patients with bleeding tendencies for different medical reasons.

Case Descriptions

Four patients (3 females, 1 male) aged 28-45 with bleeding tendencies due to different presurgical conditions such as von Willebrand disease, chronic liver failure, and mitral valve replacement presented for tooth extraction. Hematological consultations were obtained prior to surgical intervention and their international normalized ratio values were adjusted to less than 1.5; none received clotting factor replacement. The extractions were done as

a consequence of severe periodontal disease or extensive caries. Although all the extractions did not require open surgery, dental curettage was applied only in one case. Flap reflection, bone removal, and suturing were not needed. The patients were advised to avoid smoking, sucking, alcohol, as well as traumatic or spicy foods.

All the extractions were performed under local anesthesia using 2% Ultracain-DS Ampule consisting of Articaine-HCl 40 mg and Epinephrine-HCl 0.006 mg/ml (Sanofi-Aventis Deutschland GmbH). In the presence of postsurgical bleeding, the efficacy of the ampule form of topical ABS was observed. Sex, age, anamnesis, von Willebrand Factor, activated partial thromboplastin time (aPTT), factor VIII, and platelet counts of patients were recorded prior to the extractions.

Case One

A 28-year-old female with von Willebrand Disease was referred from a hematologist for a tooth extraction. von Willebrand Disease is a bleeding

disorder caused by a defect or deficiency of a blood clotting protein, called the von Willebrand Factor (vWF). Her bleeding time was longer than normal following previous surgical procedures such as a tonsillectomy and dental extractions. In addition, she has a history of her menstrual bleeding being clotted and extending up to 10 days. Her hematologic findings before the extraction were as follows:

- vWF: 50.0 (56–150 normal value)
- Factor VIII: 43.1%
- aPTT: 35.58 seconds
- Platelet count: 325,000 mm³

Following the extraction of a mandibular first molar, an ampule form of ABS was placed into the empty alveolus until it was filled with the agent (Figure 3), then an ABS absorbed gauze (Figure 4) compress was placed over the extraction site (Figure 5) and held in place by biting force. Inspection of the extraction site revealed no evidence of bleeding at intervals of 10 (Figure 6) and 20 minutes following surgery and none at intervals of 1, 3, 6, and 24 hours.

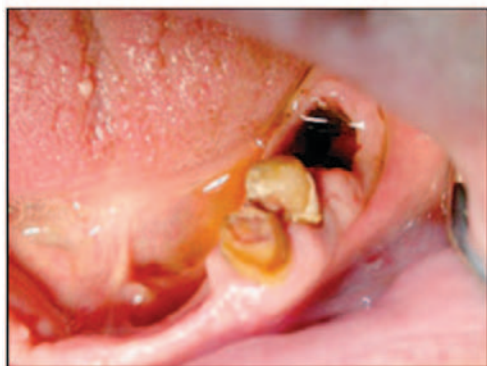

Figure 3. Extraction socket of a lower first molar after application of the ABS

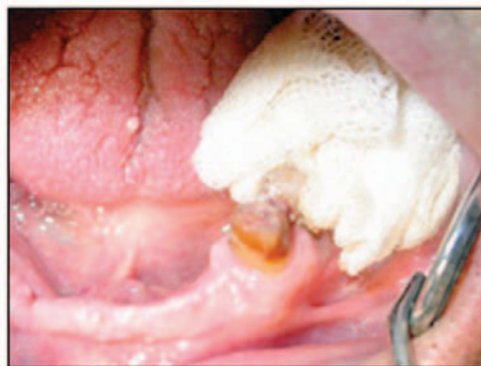

Figure 5. Gauze with ABS over the extraction socket.




Figure 4. ABS on the gauze.

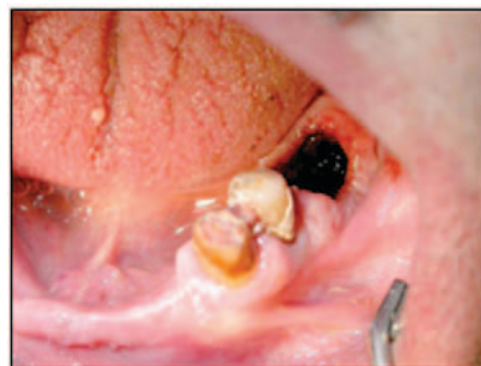

Figure 6. Extraction area appearance 10 minutes after the ABS application

Case Two

A 40-year-old female diagnosed with von Willebrand Disease was referred for the extraction of her left maxillary second premolar by a hematologist. The presurgical blood test indicated the following:

- vWF: 88.1
- aPTT: 27.2 seconds
- Prothrombin time: 12.5 seconds
- Platelet count: 215,000 mm³
- Platelet function tests: collagen/ADP: 135; collagen/EPI: 88; aggregation was normal

As was done in Case One, following the extraction an ampule form of ABS was placed into the empty alveolus until it was filled with the agent, then an ABS absorbed gauze compress was placed over the extraction site and held in place by biting force. Inspection of the extraction site revealed no evidence of bleeding at intervals of 10 and 20 minutes following surgery and none at intervals of 1, 3, 6, and 24 hours.

Case Three

A 42-year-old female suffering from chronic liver disease and taking warfarin (2.5 mg/day) was referred for the extraction of the right mandibular first molar by a hematologist. Her hematologic findings prior to the extraction were as follows:

- Prothrombin time: 15.1 seconds
- Platelet count: 55,000 mm³
- INR: 1.3

As in the other cases, following the extraction an ampule form of ABS was placed into the empty alveolus until it was filled with the agent, then an ABS absorbed gauze compress was placed over the extraction site and held in place by biting force. Mild bleeding was observed at the 10th minute after application of the ABS and another ABS gauze compress was placed. No bleeding was observed at 20 minutes, or at intervals of 1, 3, 6, and 24 hours.

Case Four

A 45-year-old male with a history of mitral valve replacement and taking warfarin (5 mg/day) was referred from a cardiology clinic for the extraction of his right maxillary second molar because of

destruction of periodontal tissues. His hematologic findings prior to the extraction were as follows:

- Platelet count: 261,000 mm³
- INR value: under 1.5

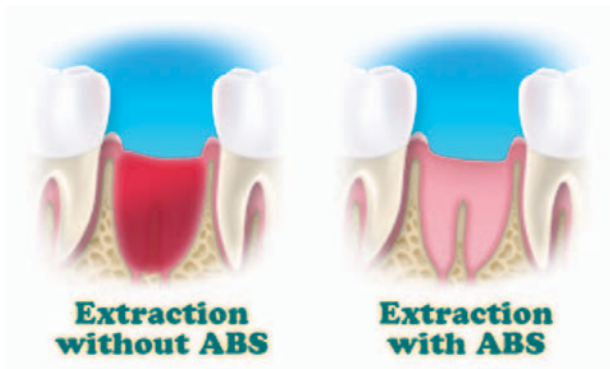
A thorough curettage was applied to the socket to eliminate the granulation tissues. As in the other cases, following the extraction an ampule form of ABS was placed into the empty alveolus until it was filled with the agent, then an ABS absorbed gauze compress was placed over the extraction site and held in place by biting force. Mild bleeding was observed at the 10th minute after application. Consequently, the same administration of ABS and application of an ABS-impregnated gauze compress was performed again. A week following the extraction, the patient returned with a complaint of mild bleeding. An oral examination revealed a huge coagulum at the extraction site. The ampule form of ABS absorbed gauze was applied to the site followed by an infusion of ABS with a syringe. No further bleeding problem was found at 1, 3, 6, and 24-hour intervals.

Discussion

Patients with hemorrhagic diathesis have a tendency to bleed excessively after dental surgery. This excessive bleeding may increase the risk of infection and also may cause delayed wound healing.⁶

Hemorrhagic diathesis is a result of congenital or acquired coagulation factor deficiencies such as the following:^{1,7,8}

- Hemophilia A and B
- von Willebrand's Disease
- Other clotting factor deficiencies
- Liver disease
- Vitamin K deficiency
- Use of anticoagulants such as warfarin that are usually prescribed to treat a number of cardiac or vascular disorders including atrial fibrillation, ischemic cardiac disease, cardiac valvular disease, prosthetic cardiac valves, postmyocardial infarction, deep venous thrombosis, pulmonary embolism, cerebrovascular accident, among others
- Disseminated intravascular coagulation



If a dental surgical procedure is for such patients, a consultation with a hematologist prior to surgery is strongly recommended to prevent uncontrolled postoperative bleeding. Surgery should be carried out with minimal trauma to both bone and soft tissues.¹ Postoperative bleeding after dental procedures can usually be controlled using one or more of the following local hemostatic methods:^{1,9}

- Compression of the surgical site with gauze pads
- Administration of a local anesthetic with a vasoconstrictor
- Placement of an absorbable hemostatic agent such as oxidized regenerated cellulose, a resorbable gelatin sponge, collagen (synthetic, microcrystalline, or porcine) cyanoacrylate, or fibrin glues in the extraction site

Although conventional agents are effective in controlling postoperative persistent bleeding,¹ they cannot control postoperative bleeding in patients with hemorrhagic diathesis. The observations of this case report suggest that topically administered ABS has a hemostatic effect on patients with serious bleeding tendency after dental surgery. ABS seems to be a promising therapeutic agent for the management of clinically evident coagulation disorders.

The possible effect of ABS on homeostasis has been previously reported by Goker et al.^{2,10} ABS is a unique medicinal plant extract that has been approved in the management of dental surgery bleeding and external hemorrhage in Turkey. It induces very rapid formation of a unique protein network in the plasma and serum samples.^{2,11} Neither any local adverse effect nor systemic toxicity has been observed following the topical application of ABS.^{6,11}

ABS is a new product without an adequate body of research to support its use in dental applications and more research is needed. It is available in three forms: tampons, spray, and an ampule. The best form for use in extraction sites is the 2 ml ampule. The spray form is too difficult to control due to the possibility of an overspray of the agent onto the tissues adjacent to the extraction socket. Use of the tampon form could inhibit wound healing in sockets and is not recommended.

The observations in the four patients in the present report support the recent *in vivo* and *in vitro* findings in previous studies,^{2,4} demonstrating the beneficial effect of ABS on hemostatic parameters. Taken together, ABS seems to be a promising therapeutic agent for the management of clinically evident coagulation disorders.² Ercetin et al.⁶ found ABS to be effective in shortening the duration of bleeding and decreasing the bleeding volume in extraction sites. In this clinical observation, which was designed observe the effects of ABS following dental extractions in patients with bleeding tendency, the beneficial effect of ABS was reported in four patients with hemorrhagic diathesis. The hematological data of the patients observed were examined prior to the surgical procedures. No bleeding was observed after 10 and 20 minutes postextraction in three patients, but there was mild bleeding in one case. The mild bleeding originated from the soft tissue around the socket that was not covered by the ABS.

Conclusions

ABS may be a beneficial topical hemostatic agent after tooth extraction in patients with hemorrhagic diathesis. More research is needed to clarify the role of this unique medicinal product in dental surgery in patients with hemorrhagic diathesis.

Clinical Significance

ABS is a new hemostatic agent that may be effective in controlling bleeding after dental surgery.

References

1. Scully C, Wolff A. Oral surgery in patients on anticoagulant therapy. *Oral Surg Oral Med Oral Pathol Oral Radiol Endod.* 2002; 94(1):57-64.
2. Goker H, Haznedaroglu IC, Ercetin S, Kirazli S, Akman U, Ozturk Y, Firat HC. Haemostatic actions of the folkloric medicinal plant extract Ankaferd Blood Stopper. *J Int Med Res.* 2008; 36(1):163-70.
3. Haznedaroglu BZ, Haznedaroglu IC, Walker SL, Bilgili H, Goker H, Kosar A, Aktas A, Captug O, Kurt M, Ozdemir O, Kirazli S, Firat HC. Ultrastructural and morphological analyses of the *in vitro* and *in vivo* hemostatic effects of Ankaferd Blood Stopper. *Clin Appl Thromb Hemost.* (Forthcoming 2009). Epub 2009 Oct 14.
4. Cipil HS, Kosar A, Kaya A, Uz B, Haznedaroglu IC, Goker H, Ozdemir O, Koroglu M, Kirazli S, Firat HC. *In vivo* hemostatic effect of the medicinal plant extract Ankaferd Blood Stopper in rats pretreated with warfarin. *Clin Appl Thromb Hemost.* 2009; 15(3):270-6.
5. Kosar A, Cipil HS, Kaya A, Uz B, Haznedaroglu IC, Goker H, Ozdemir O, Ercetin S, Kirazli S, Firat HC. The efficacy of Ankaferd Blood Stopper in antithrombotic drug-induced primary and secondary hemostatic abnormalities of a rat-bleeding model. *Blood Coagul Fibrinolysis.* 2009; 20(3):185-90.
6. Ercetin S, Haznedaroglu IC, Kurt M, Onal IK, Aktas A, Kekilli M, Goker H, Ozdemir O, Kirazli S, Firat HC. Safety and efficacy of Ankaferd Blood Stopper in dental surgery and bleeding. *Oral Surg Oral Med Oral Path Oral Radio Endod.* (submitted).
7. Gupta A, Epstein JB, Cabay RJ. Bleeding disorders of importance in dental care and related patient management. *J Can Dent Assoc.* 2007; 73(1):77-83.
8. Jeske AH, Suchko GD; ADA Council on Scientific Affairs and Division of Science; Journal of the American Dental Association. Lack of a scientific basis for routine discontinuation of oral anticoagulation therapy before dental treatment. *J Am Dent Assoc.* 2003; 134(11):1492-7.
9. Peterson LJ, Ellis E, Hupp JR, Tucker MR. Contemporary oral and maxillofacial surgery. 3rd ed. St. Louis, MO: C.V. Mosby; 1998. p. 270-4.
10. Tasdelen Fisgin N, Tanriverdi Cayci Y, Coban AY, Ozatli D, Tanyel E, Durupinar B, Tulek N. Antimicrobial activity of plant extract Ankaferd Blood Stopper. *Fitoterapia.* 2009; 80(1):48-50. Epub 2008 Oct 7.
11. Kurt M, Kacar S, Onal IK, Akdogan M, Haznedaroglu IC. Ankaferd Blood Stopper as an effective adjunctive hemostatic agent for the management of life-threatening arterial bleeding of the digestive tract. *Endoscopy.* 2008; 40 Suppl 2:E262. Epub 2008 Dec 17.

About the Authors

Timucin Baykul, DDS, PhD



Dr. Baykul is an associate professor in the Department of Oral and Maxillofacial Surgery of the School of Dentistry, at the University of Suleyman Demirel in Isparta, Turkey. His research interests include orthognatic surgery, temporomandibular joint disorders, head and neck cancer, and implantology. He is a member of the Turkish Association of Oral and Maxillofacial Surgeons and the Association of Oral and Maxillofacial Surgery (AÇBID).

e-mail: timucinbaykul@yahoo.com

Emine Guchan Alanoglu, MD



Dr. Alanoglu is an assistant professor in the Department of Hematology of the School of Medicine at the University of Suleyman Demirel in Isparta, Turkey. Her research interests include blood banking and hematologic malignities. She has numerous publications and presentations in different areas dealing with hematology. She is a member of the Turkish Hematology Association, the European Hematology Association, and the Turkish Blood Banking and Transfusion Association.

e-mail: alanoglu@gmail.com

Gulperi Kocer, DDS, PhD (Corresponding Author)



Dr. Kocer is an assistant professor in the Department of Oral and Maxillofacial Surgery of the School of Dentistry, at the University of Suleyman Demirel in Isparta, Turkey. Her research interests include oral surgery, implantology, oral cancer, and TMJ disorders. She is a member of the Turkish Association of Oral and Maxillofacial Surgeons and the Association of Oral and Maxillofacial Surgery (AÇBİD).

e-mail: gulperikocer@yahoo.com