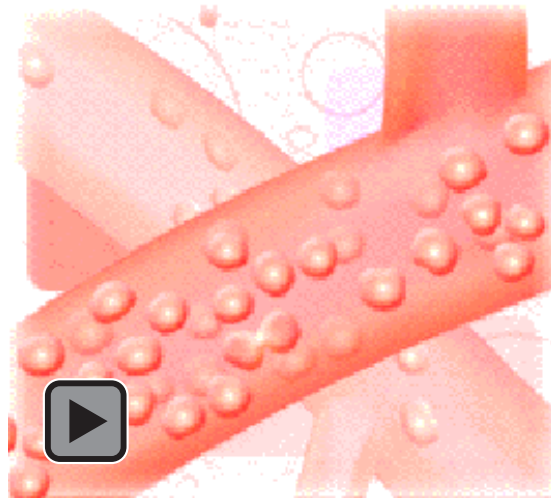

## Post-Surgical Hemorrhage: Formation of a "Liver Clot" Secondary to Periodontal Plastic Surgery

Richard F. Druckman, DDS; Edward B. Fowler, DDS, MS  
Lawrence G. Breault, DMD, MS



### Abstract

Bleeding is a common sequela of periodontal and oral surgery. Generally, bleeding is self-limiting. Special circumstances require additional procedures to reduce or eliminate active hemorrhage. Occasionally hemorrhage can be under control when a patient is dismissed from their surgical appointment and, subsequently, the patient will experience either slow seepage of blood or extravascular clot formation. This case report describes the unique formation of a "liver clot" or "currant jelly clot" following periodontal plastic surgery. The clotting cascade and common laboratory tests to evaluate bleeding disorders are also presented.

Keywords: Oral surgery, periodontal surgery, hemorrhage, "liver clot," "currant jelly clot"

## Introduction

Following traumatic injury or surgical procedures, hemorrhage can range from a minor leakage or oozing at the site to extensive bleeding leading to complete exsanguination. Periodontal surgical procedures are a common component of comprehensive dental and periodontal practices; significant post-surgical hemorrhage following periodontal surgery is very uncommon. The lack of significant hemorrhage following treatment is generally attributed to surgical procedures resulting in primary closure of the soft tissues. In contrast oral surgery, particularly tooth extractions, can be associated with a prolonged or lingering hemorrhage due to the nature of the procedure resulting in an "open wound."

The following report describes an unusual case of the formation of a "liver clot" or "currant jelly clot" after a periodontal soft tissue grafting procedure.

## Case Report

### History

A 32-year-old man was referred for a periodontal evaluation of generalized gingival recession on the facial of the right mandibular teeth. He reported a history of having a subepithelial connective tissue graft harvested from his palate approximately 6 months previously and placed in the lower left premolar canine area. The patient further reported an unexpected consequence of significance; a post-surgical hemorrhage from the donor site on the palate. There were no bleeding problems related to the recipient site in the, mandibular left premolar area.

The patient desired a periodontal plastic surgical procedure in the mandibular right region, but was reluctant to consent to a connective tissue graft harvested from the palate due to his previous negative experience with post-surgical bleeding. An acellular dermal matrix allograft was presented as an alternative to avoid harvesting tissue from his palate. The patient agreed to the root coverage procedure using AlloDerm.\*

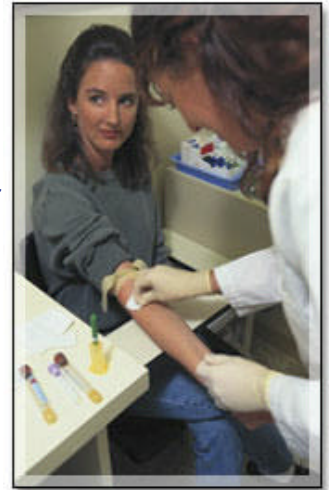*\*Lifecore Biomedical, Oral Restorative Division, Chaska, MN 55318*

### Surgical Procedure

Prior to any additional surgical procedures, the following routine blood tests were ordered:

Complete Blood Count including platelets (CBC), Activated Partial Thromboplastin (PTT), Prothrombin Time (PT), and Bleeding Time. All tests were noted within normal limits. The patient denied any history of aspirin or NSAID use during or prior to his surgical procedure. He also denied taking any over the counter (OTC) herbal medications. Furthermore, he reported no prolonged bleeding episodes associated with mechanical injury such as shaving.

Following a 60 second pre-surgical rinse with chlorhexidine and the administration of local anesthesia, the exposed roots of the mandibular right first premolar, canine, and lateral incisor were root planed. The teeth were then etched with citric acid for 3 minutes. A full thickness flap was reflected from the mesial of the right central incisor to the distal of the second premolar. The acellular dermal matrix allograft was sutured over the exposed roots and completely covered by the overlying full thickness flap. The connective tissue side of the graft was placed towards the gingival flap, while the basement membrane side was placed against the roots and bone.



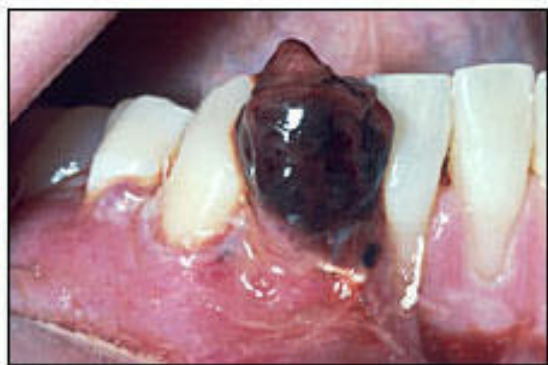### Post-operative Instructions

Hemostasis was obtained and the patient received home care/post-surgical instructions. These instructions included a warning not to manipulate the surgical site nor attempt to retract his lip to visualize the area. Analgesics consisted of acetaminophen and codeine. A chlorhexidine rinse was recommended to replace traditional mechanical oral hygiene home care procedures until the first post-surgical visit.

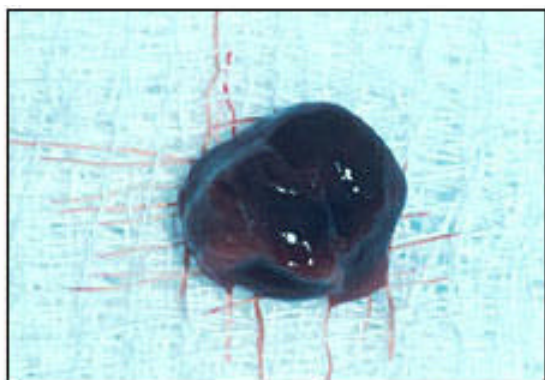### Post-operative Sequellae

The following morning the patient telephoned the clinic with a report that "part of the graft had come out." The patient was instructed to immediately return for a clinical evaluation of the surgical site. Upon clinical examination, a dark red, somewhat firm pedunculated mass was noted associated

with the surgical site in the area of the right lateral incisor. (Figure 1) The mass was removed with a curette in one piece. (Figure 2) No hemorrhage was apparent, and the patient had no further post-surgical complications. The mass was clinically determined to be a "liver clot" or "currant jelly clot."



**Figure 1.**  
Patient presents 24 hours post-periodontal surgery with fibrin-like "Liver clot".



**Figure 2.**  
Excised clot.

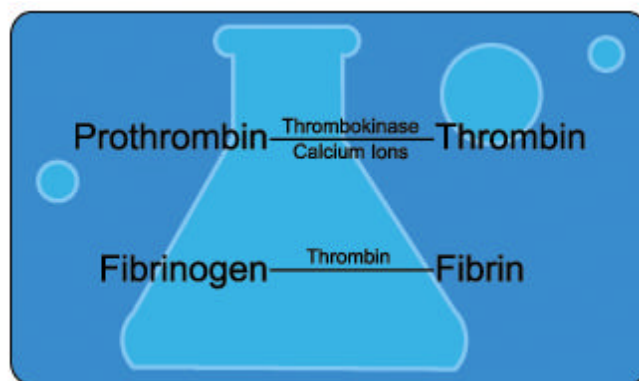
### Discussion

By definition hemostasis is "the arrest of bleeding" or "stagnation of blood."<sup>1</sup> Hemorrhage encountered in dental procedures is generally self-limiting and ceases spontaneously. In cases of continuous bleeding, the primary means of controlling hemorrhage include direct pressure, direct occlusion of blood vessels by suture ties, or by mechanically crushing open vessels. Various materials are used clinically to initiate clot formation such as astringents, oxidized cellulose, absorbable gelatin, and thrombin.<sup>2,4</sup> Other adjuncts that occlude vessels include cryotherapy, electrocoagulation, cyanoacrylate adhesives, and vasoconstrictors such as epinephrine.<sup>2,4</sup>

The mechanism of spontaneous hemostasis involves four steps:<sup>5</sup>

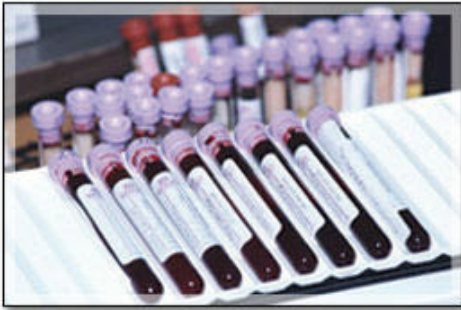1. Immediately after tissue trauma, blood vessels constrict. The constriction involves neuronal, local, and humoral mechanisms. As bleeding decreases, platelets adhere more effectively to damaged subendothelial tissues.
2. A hemostatic plug forms as platelets adhere to the injury site. Epinephrine, serotonin, and adenosine diphosphate (ADP) are released. Epinephrine and serotonin increase vasoconstriction, while ADP enhances platelet aggregation. This, in turn, initiates the mechanism of coagulation.
3. Coagulation begins with plasma Factor XII (intrinsic system). Exposed elastin and collagen combine with substances released by platelets and damaged tissues (extrinsic system). The consolidation of platelets forms a plug that becomes a fibrin clot. Factor XIII acts to make the fibrin clot more stable and secure as it seals the damaged vessel.
4. Fibrinolytic enzymes digest the hemostatic materials and the fibrin clot. The active form of plasminogen is plasmin, which breaks large fibrin molecules into smaller pieces that are then removed. This re-establishes the patency of the damaged vessel.

Paul Morawitz (1905) combined the works of earlier investigators to form the "classic theory" of coagulation.<sup>5</sup> The process of clot formation from fibrinogen consists of two primary reactions:



## Discussion

If blood is placed in a glass container, a clot will form in 15 to 20 minutes. The addition of tissue extracts that simulate tissue injury accelerates the formation of a clot. Two different pathways lead



to the formation of fibrin. The intrinsic system occurs without tissue substances. The extrinsic pathway involves tissue substances. Both systems share reaction steps in the sequence of

coagulation. This is seen in the "cascade" concept applied to formation of the clot. The term "cascade" suggests the mechanism is such that one factor will activate the following factor in a sequenced reaction resulting in formation of the clot.

"Liver clots" or "currant jelly clots" are defined as a red, jelly-like clot that is rich in hemoglobin from erythrocytes within the clot.<sup>6</sup> These clots can result with some frequency with oral surgical procedures, especially involving the removal of mandibular third molars.<sup>3,4,7,8</sup> Generally, this is the result of venous hemorrhage characterized by slow, oozing dark red blood.<sup>8</sup> Liver clots are generally removed by either high speed suction or a large curette. Following removal of the clot, saline irrigation and direct pressure is applied to the exposed area. Rarely are sutures required.

This case is believed to be the first report of a "liver clot" occurring secondarily to a periodontal plastic surgery utilizing an acellular dermal allograft and primary closure of the wound.

There are many causes of abnormal blood coagulation. These include<sup>2,10</sup>: liver disease, renal insufficiency, fibrinolysis, disseminated intravascular coagulopathy, leukemia, pharmaceutical agents, and genetic disorders that involve deficiencies of various clotting factors.

When a patient presents with a significant post-surgical hemorrhagic sequella or positive history for prolonged bleeding, laboratory blood studies are helpful in determining specific risks or contraindications to invasive dental procedures.<sup>4,10</sup>

## Conclusion

1. Prothrombin time (PT) is used to evaluate the extrinsic and common coagulation system as well as to monitor response to oral anticoagulant therapy such as coumarin.

2. Partial thromboplastin time (PTT) is used primarily for discovering deficiencies in the intrinsic system of congenital deficiencies.

3. Template bleeding time (TT) measures the ability of fibrin to form an initial clot and is relatively sensitive for fibrinolysis disorders.

4. Bleeding Time (BT) tests platelet and vascular changes.

5. Platelet counts are used as quantitative measures of a patient's ability to clot.

Although a "liver clot" or "currant jelly clot" is not an uncommon post-surgical sequella of surgical extractions of third molars or with multiple extractions, this is believed to be the first reported case following a periodontal grafting procedure utilizing an acellular dermal matrix allograft.

Patients that have potential problems with hemostasis should be managed as gently during surgery as possible. Primary closure of surgical wounds should be maximized using extra sutures to insure close adaptation of wound margins. Following the surgical procedure, moist gauze should be placed over the surgical site with moderate pressure for 5 to 10 minutes. If bleeding persists, vasoconstrictive substances such as epinephrine or procoagulants such as thrombin or collagen may be employed. Finally, home instructions (both verbal and written) should be provided to the patient.<sup>3,4</sup>

## References

1. Illustrated Stedman's Medical Dictionary, 24th edition. Williams & Wilkins, Baltimore. 1982.
2. Kruger GO (editor). Textbook of Oral and Maxillofacial Surgery, 6th edition. The C.V. Mosby Company, St. Louis. Chapter 12 "Hemorrhage and shock"; Alling CC III, Alling RD. 1984;229,236-9.
3. Hardin JF (editor). Clark's Clinical Dentistry, Vol 3. J. B. Lippincott Company, Philadelphia. Chapter 21 "Single simple extractions"; Upton LG. 1987;14-15.
4. Pertson L. J. (editor). Contemporary Oral and Maxillofacial Surgery, 3rd edition. C.V. Mosby Company, St. Louis. Chapter 3 "Principles of surgery"; Hupp JR. 1998; 48-49. Chapter 11 "Prevention and management of surgical complications"; Peterson LJ. 1998;270-273.
5. Seiverd CE. Hematology for Medical Technologists. 5th edition, Philadelphia: Lea & Febiger, 1983:378-380.
6. Anderson, KN, Anderson LE. Mosby's Pocket Dictionary of Medicine, Nursing & Allied Health. St. Louis: Mosby Inc.; 1998:311.
7. Lapeyrolerie F. Management of dentoalveolar hemorrhage. Dent Clin North Am. 1973 Jul;17(3):523-32. No abstract available.
8. Weinberg S. Oral surgery complications in general practice. J Can Dent Assoc. 1975 May;41(5):288-94, 299. No abstract available.
9. Bhaskar SN. Synopsis of Oral Pathology, 6th edition. St. Louis. C.V. Mosby Company; 1981:648-649.
10. Little JW, Falace DA, Miller CS, Rhodus NL. Dental Management of the medically compromised patient, 5th edition. St. Louis: Mosby Inc., 1997:484-485.



## About the Author

### Richard F. Druckman, DDS



Lieutenant Colonel Richard F. Druckman, DDS is a Prosthodontic Mentor in the AGD (12-Month) Program, Schofield Barracks, Hawaii. Diplomate, the American College of Prosthodontics, member, American Dental Association.

e-mail: [Richard.Druckman@haw.tamc.amedd.army.mil](mailto:Richard.Druckman@haw.tamc.amedd.army.mil).



### Edward B. Fowler, DDS, MS



Lieutenant Colonel Edward B. Fowler, DDS, MS, Chief, Periodontics and AGD (12-Month) Program Mentor, Fort Lewis, Us Army Dental Activity, Fort Lewis, Washington. Diplomate, the American Board of Periodontology, member, American Academy of Periodontology, member American Dental Association.

e-mail: [fowlered@worldnet.att.net](mailto:fowlered@worldnet.att.net)



### Lawrence G. Breault, DMD, MS



Lieutenant Colonel Lawrence G. Breault, DMD, MS, Chief, Periodontics and AGD (12-Month) Program Mentor, Schofield Barracks, Us Army Dental Activity, Hawaii, Diplomate, the American Board of Periodontology, member, American Academy of Periodontology, member American Dental Association.

e-mail: [breault@mail.aloha.net](mailto:breault@mail.aloha.net)



## Acknowledgements

The authors would like to thank Mrs. Dayna B. Breault for assistance with manuscript preparation. The authors would also like to thank Mrs. Lisa Bell, Dental Assistant and Colonel Steven Wonderlich, AGD Program Director for help in photographic documentation.