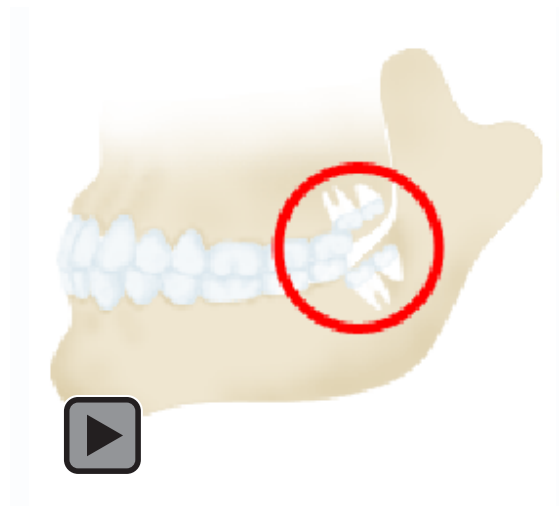


Supernumerary Fourth and Fifth Molars: A Report of Two Cases

Gulseren Kokten, DDS, PhD; Huseyin Balcioglu, DDS;
Mete Buyukertan, DDS, PhD



Abstract

Panoramic radiographs of two female patients ages 22 and 21 revealed the presence of two impacted bilateral upper fourth molars and unilateral (right) upper fourth and fifth molars. All of the teeth were distomolars. The supernumerary teeth had normal tooth morphology with regard to their crowns and roots but were slightly smaller than the existing third molars. Their crowns were either two or three tuberculated and they all had single roots.

Keywords: Fourth molars, fifth molars, distomolars, supernumerary molars, dental anthropology

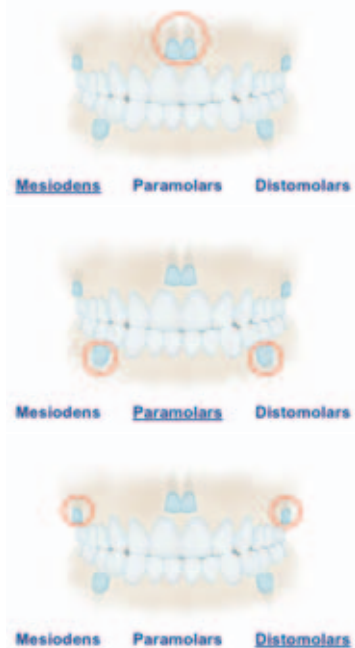
Citation: Kokten G, Balcioglu H, Buyukertan M. Supernumerary Fourth and Fifth Molars: A Report of Two Cases. J Contemp Dent Pract 2003 November;(4)4:067-076.

Introduction

Teeth serve an important role in chewing, phonetics, and the morphological make-up of the face. The normal number of 32 permanent teeth consists of 1 central incisor, 1 lateral incisor, 1 canine, 2 premolars, and 3 molars in each quadrant of the dentition.¹

Teeth in excess of the normal number are referred to as “supernumerary teeth.” The majority of supernumerary teeth are considered to develop as a result of horizontal proliferation or a hyperactivity of the permanent or deciduous dental lamina.^{2,3}

Supernumerary teeth are most frequently seen in the maxillary anterior and molar regions.⁴ The supernumerary teeth that occur between or just posterior to the central incisors are referred to as “mesiodens”^{2,5}; those in the molar area are called “paramolar” teeth^{5,6}; and, more specifically, those that erupt distally to the third molar are “distomolar” teeth.⁵ Supernumerary teeth may occur in both dentitions, but they are more frequently seen in the permanent dentition.^{2,7} The prevalence ranges from 0.1% to 3.4%.⁴



Supernumerary teeth can have normal morphology and are referred to as “supplementary teeth”. On the other hand, supernumerary teeth may be rudimentary in shape and smaller in size.⁴ The

cases having normal morphology are more frequently seen among the distomolars found in the mandible.⁸

Authors agree supernumerary teeth occur more frequently in the maxilla than in the mandible.^{4,9} Few authors feel supernumerary teeth are found more often in the mandible than in the maxilla.^{5,10} Supernumerary teeth may or may not be erupted. They are radiologically evaluated when impacted. If they erupt, they may cause malalignment of the dentition.

Case Report 1

A 22-year old, healthy Caucasian female was referred to the acupuncture clinic of the Department of Anatomy, in the Faculty of Dentistry at Istanbul University due to the chief complaint of temporomandibular joint disease. The patient had been managed orthodontically due to malocclusion and the first premolars had been extracted in each quadrant. Following a clinical examination, panoramic and periapical radiographs were taken. The radiographs revealed the presence of impacted bilateral maxillary fourth molars. They were distomolars located just posterior to the upper third molar (Figure 1).

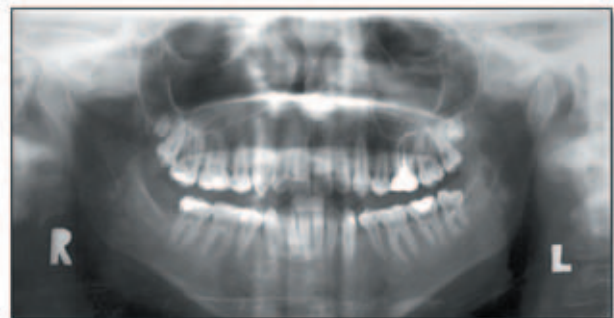

Figure 1.

The teeth had normal morphology; crowns and roots were significantly developed but smaller in size. The fourth left molar had three significant tubercles and the length of the root was normal relative to its crown. The root apex was completely developed. The right fourth molar had two tubercles and it had a short root. It was smaller when compared to the left fourth molar.

In order to calculate the real size of the impacted teeth, the size of the central incisor was

Table 1. Comparison of the real values between the fourth and third molars for Case 1.

	Width of the crown (mm)	Length of the crown (mm)	Length of the root (mm)
Fourth right molar	6	6.5	3.5
Third right molar	10	8	9
Fourth left molar	8.5	7	6
Third left molar	9.5	7.5	8.5

Table 2. Comparison of the real values between third, fourth, and fifth molars for Case 2.

	Width of the crown (mm)	Length of the crown (mm)	Length of the root (mm)
Third right molar	9.96	5.97	9.8
Fourth right molar	5.22	6.48	7.16 (fused)
Fifth left molar	5.6	5.8	7.16 (fused)

measured intraorally with a caliper. The measurement was repeated on the same tooth using the panoramic radiograph. By comparing these measurements, the actual sizes of the fourth molars were determined. The width of the crown of the fourth left molar was 8.5 mm, the length of the crown was 7 mm, and the length of the root was 6 mm. The width of the crown of the fourth right molar was 6 mm, the length of the crown was 6.5 mm, and the length of the root was 3.5 mm (Table 1).

The size of the third molars was also compared with the fourth molars. The morphometric measures displayed the fourth left molar had very close values relative to the third molar. The measures revealed the length of the root of the fourth right molar was nearly half of the length of the third molar's root. The patient's TMJ syndrome is being managed in the acupuncture clinic.

Case Report 2

A 20-year old, healthy Caucasian female was referred to the acupuncture clinic of the Department of Anatomy in the Faculty of Dentistry at Istanbul University for treatment of temporomandibular joint disease. After a clinical examination, panoramic and periapical radiographs were obtained. The radiographs revealed the presence of impacted upper right fourth and fifth molars. The third molar was also impacted. The fourth and fifth molars were distomolars (Figure 2).

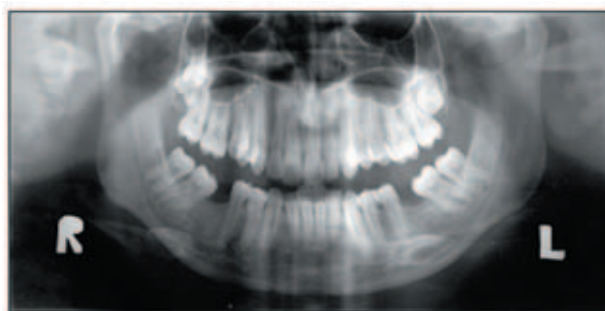

Figure 2.

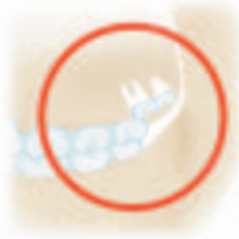The actual size of the teeth was determined after extraction. The crowns were significantly developed, while the roots of the fourth and fifth molars were fused. The fourth molar had two tubercles and the fifth molar had three tubercles. The third molar was multi-cusped and had only one root. The width of the fourth molar's crown was 5.22 mm and the length of the crown was 6.48 mm. Its root was fused with the root of the fifth molar and the length of the fused roots was 7.16 mm. The width of the crown of the fifth molar was 5.60 mm and the length of the crown was 5.82 mm. The width of the crown of the third molar was 9.96 mm, the length of the crown was 5.97 mm, and the length of the root was 9.80 mm. (Table 2).

Discussion

The prevalence of supernumerary molars is reported as 1% by Stafne⁶, as 2% by Luten¹¹, and as 1.9% by Backmann.² It is reported in the literature that fourth, fifth, sixth, and seventh molars were seen^{10,13,14}; however, fourth molars are seen

much more frequently.¹⁵ Our findings described in this paper found two fourth molars in one case and one fourth and one fifth molar in the second case.

Stafne⁶ reports most of the upper fourth molars are blunt, multicuspid, and much smaller than the third molars. They may be conical or equally as large as the normal molars. Dubuk¹⁶ has reported a paramolar case of 4 mm in length. It had a ball-shaped crown and a relatively normal crown/root length ratio. Cassetta¹⁷ reported 8 of the 13 supernumerary molars were tuberculated and 5 of them were conical in shape. In Sugimara's¹⁸ series of 20 distomolar cases, the distomolars resembled a molar or premolar; in his series of 13 paramolars: 8 resembled a premolar, 3 were conical, and 2 were bizarre in shape.



In Case 1, the fourth molars had a normal morphology but they were a little smaller. Their crowns and roots were significant; especially the fourth left molar which had 3 tubercles and a normal crown/root ratio. The right fourth molar had 2 tubercles; it was smaller and the root was short.

In Case 2, the fourth molar had two tubercles. The fifth molar had 3 tubercles. The roots of the fourth and fifth molars were fused. In both cases, crowns of the distomolars had normal morphology, but they were smaller than the third molar.

In Cassetta's¹⁷ case series of 23 supernumerary molars, 13 were distomolars and 10 were paramolars. Our cases included all distomolars.

Supernumerary molars are found more frequently in the maxilla than in the mandible. Grimanis¹⁹ reported supernumerary molars are found with a percentage of 79% in the maxilla. Menardia et al.⁹ stated this percentage is 86.8%, Spauge³ 91%, while Stafne⁷ reported it as 88.9%. Cassetta¹⁷ claims the incidence of supernumerary molars among all supernumerary teeth found in the maxilla is 75%. In our cases all distomolars were in the maxilla.

Supernumerary teeth are more often found in males than females.⁴ Goaz and White⁵ say it occurs twice as often in males. Timocin et al.²⁰ concluded males are much more affected than females. Yusuf¹⁰ stated a 9:2 male-female ratio in the occurrence of supernumerary teeth while Liu²¹ claims a 3:1 ratio. ElNassry⁸ reported 300 cases of hyperdontia indicated a predominancy in males at 83%. Our cases were both females.

Authors have discussed the effect of supernumerary teeth on occlusion.^{5,14,22} Our patients had presented with malocclusion and the first case had orthodontic management. Other detailed studies are needed to understand how the fourth molars affected their occlusion.

Some hyperdontia may be familial and some may be syndrome associated (Gardner's syndrome, Cleidocranial dysplasia).² Our patients had no syndrome.

References

1. Sicher H, DuBrul E.L, Oral Anatomy, The C.V. Mosby Company Saint Louis 1970.
2. Regezi & Sciubb, Oral Pathology, W.B. Saunders Co.2nd edit. 1993.
3. Spauge JD. Oral Pathology. St. Louis: Mosby Co, 1973.
4. Pindborg JJ, Pathology of the Dental Hard Tissues, Munksgaard, Copenhagen, 1970.
5. Goaz-White. Oral Radiology. 2nd ed. NY: The C.V Mosby Co, 1987.
6. Stafne EC. Supernumerary teeth. Dent cosmos. 1935;74:653-9.
7. Stafne's Oral Radiografic Diagnosis. 5th Ed. Philadelphia:WB. Saunders Co, 1985.
8. El Nassry, Charecteristics of Hyperdontia in Premaxillary region: A Survey of 300 Cases. Dent Res 75(5)-1279 May 1996.
9. Menardia-Pejuan V, Berini-Aytes L. Supernumerary molars. A review of 53 cases. Int Res Sci Stomatol. 2000;402(2-3):101-5.
10. Yusuf WZ. Non-syndrome multiple supernumerary teeth. Literature review. J. Can.
11. Luten JR. The prevalance of supernunerary teeth in primary and mixed dentitions.J Dent Child. 1967;34:346-53.

12. Backman B, Wahlin YB. Variations in number and morphology of permanent teeth in 7- year old Swedish children. *Int J Paediatric Dent* 2001 Jan;11(1):11-7.
13. Anemone, Robert L., Elizabeth S. Watts 1992. Dental development in apes and humans. *Journal Human Evolution* 22:149-153.
14. Nordendram A. 4th and 5th molars in ramus mandibula: casa report. *Odont T.* 1968;76:23-25.
15. Tochichara Y: Studies of Supernumerary Teeth in Japanese I-IV (in Japanese), *J. Tokyo Dent. Coll. Soc* 40:651-664, 760-781, 841-857;41:24-37,1935-1936 *Dent. Assoc.*56. 147-149, 1990.
16. Dubuk AN, Selvig KA, Tellefsen G, et. al. Atypically located paramolar. Report of a rare case. *Eur J Oral Sci* 1996 Apr;104(2(pt1)):138-40.
17. Casetta M, Pompa G, Stella R, et. al. Hyperdontia: an epidemiological survey, *J Dent Res* 80 (4) 1295 Apr 2001.
18. Sugimura M, Tsuji Y, Yamaguchi K, , et. al. Mandibular distomolars. *Oral Surg*, September 1975. 341-345.
19. Grimanis GA, Kyriakides AT, Spyropoulos ND. A survey an supernumerary molars, *Quintessence Int* 1991 Dec; 22(12):989-95.
20. Timocin N, Yalcin S, Ozgen M, et. al. Supernumerary Molars and Paramolars, A Case Report, *J. Nihon Univ. Sch. Dent.*, Vol. 36. No.2.145-150.1994.
21. Liu JF. Characteristics of premaxillary supernumerary teeth: a survey of 112 cases.
22. Zvolanek JW, Spotts TM. *J Am Dent Assoc* 1985 May;110(5):721-3.

About the Author

Gulsaren Kokten, DDS, PhD



Dr. Kokten is a Professor and Head of the Department of Anatomy in the Faculty of Dentistry at Istanbul University, Istanbul, Turkey. Her primary research interests include anatomy and MRI studies of the temporomandibular joint, acupuncture, trigeminal neuralgia, disorders of the temporomandibular joint, dental, and oral pain.

e-mail: gkokten@hotmail.com

Huseyin Balcioglu, DDS



Dr. Balcioglu is a PhD candidate for a dissertation degree and is serving as a research and teaching assistant in the Department of Anatomy in the Faculty of Dentistry at Istanbul University, Istanbul, Turkey. His primary research interests are related to the temporomandibular joint, evolutionary anatomy and anthropology, MRI studies, and the philosophy of biology.

e-mail: huseyinbalcioglu@yahoo.com

Meteb Buyukertan, DDS, PhD

Dr. Buyukertan is a research fellow in the in the Department of Anatomy in Faculty of Dentistry at Istanbul University, Istanbul, Turkey. His main interests are radiological anatomy, oral histology and the temporomandibular joint.

e-mail: metebuyukertan@hotmail.com