


Geographic Tongue: Clinical Characteristics of 188 Cases

Aree Jaikittivong, BSc, DDS, MS;
Robert P. Langlais, DDS, MS, FRCD



Abstract

The purpose of this study was to investigate the clinical characteristics and assess other factors associated with geographic tongue in Thailand. One hundred and eighty-eight Thais with geographic tongue and 188 controls were interviewed regarding their medical history, symptoms, and the nature and migratory pattern of their lesions. Variations in the clinical appearance, lesion location, and any associated tongue fissures were recorded. The age range for the 188 subjects was 9 to 79 years. The highest incidence (39.4%) occurred in the 20-29 age group. Women were affected more than men (1.5:1). The leading group of medical conditions consisted of allergy-related disorders; however, the incidence of these problems among both subjects and controls was not significantly different (55.2% vs. 44.8%). Our results demonstrated a significant co-existence of geographic tongue and fissured tongue. Most of the geographic tongue lesions manifested a typical appearance consisting of a central atrophic area bounded by a raised white circinate line (69.1%) with multiple tongue sites affected (62.8%). The most common locations were at the lateral margins and tip of the tongue. The majority of our subjects (75.5%) were asymptomatic. The results of this study correspond with the findings of previous geographic tongue studies in other populations.

Keywords: Geographic tongue, characteristics, fissured tongue, medical conditions

Citation: Jaikittivong A, Langlais RP. Geographic Tongue: Clinical Characteristics of 188 Cases. J Contemp Dent Pract 2005 February;(6)1:123-135.

Introduction

Geographic tongue is a condition referred to by a variety of terms such as: benign migratory glossitis, erythema migrans, annulus migrans, or wandering rash of the tongue. It is a benign condition commonly occurring on the tip, lateral borders, and dorsum of the tongue; lesions sometimes extend to the ventral portion as well. The appearance is of multifocal, circinate, irregular erythematous patches bounded by a slightly elevated, white or cream colored keratotic band or line. The central erythematous patch represents atrophy of the filiform papillae. The white border is composed of regenerating filiform papillae and a mixture of keratin and neutrophils.¹

Most patients manifested one or more lesional areas as previously described (Figure 1). In some cases, when the zones of papillary atrophy are prominent and the keratotic margins relatively subdued, the lesions present as red patches.²

Geographic tongue is usually asymptomatic, however, a burning sensation or sensitivity to hot or spicy foods may be noted (Figure 2). Only rarely does significant pain develop and persist.

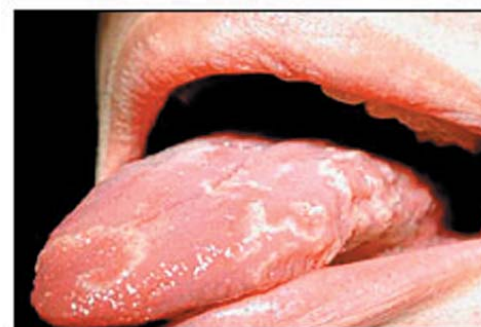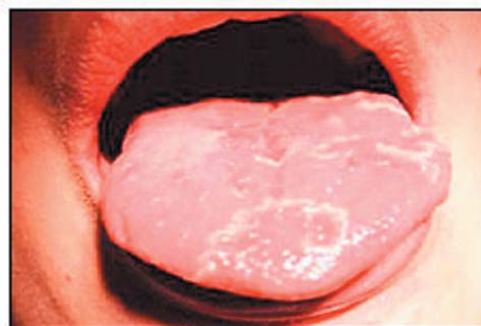
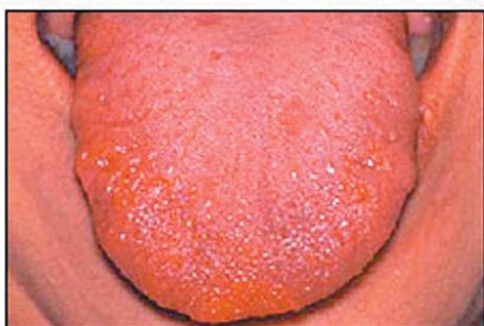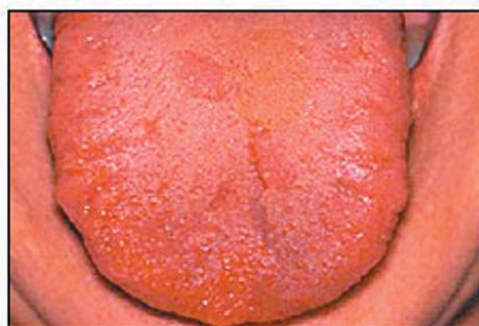


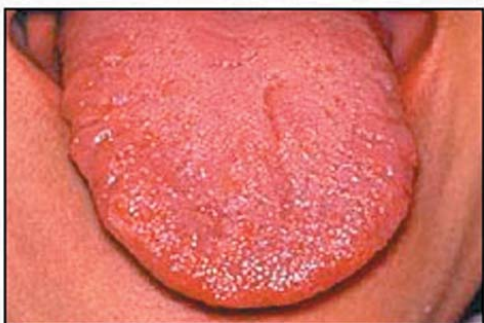Figure 1. Geographic tongue in an 18-year old man. The lesions manifest as multiple atrophic patches bounded by raised white circinate bands.



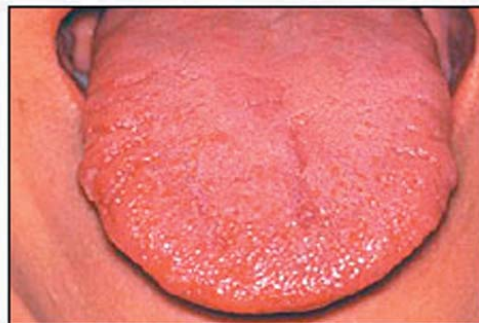
A. Day 1



B. Day 3



C. Day 4



D. Day 7

Figure 2. Changes in geographic tongue lesions of one-week duration in a 35-year old woman. The recurrence of lesions was triggered by spicy foods.

Geographic tongue is characterized by periods of remission and exacerbation of varying duration. During remission, the condition resolves without residual scar formation. When lesions recur, they tend to occur in new locations, thus, producing the migratory pattern (Figure 3).

When the condition includes lesions at extraglossal oral sites, different terms like geographic stomatitis, erythema migrans, erythema areata migrans, and stomatitis areata migrans have been used.³⁻⁷ The reported extraglossal sites include the labial mucosa, buccal mucosa, gingiva, floor of mouth, soft palate, and uvula.⁸⁻¹¹ Geographic tongue may occur at any age with no apparent racial predilection.¹² According to some investigators, the condition is more prevalent in younger individuals¹³⁻¹⁶, however, others have found most cases are noted in patients over 40 years of age.¹⁷ The sex of affected individuals varies with different studies. Geographic tongue was noted more in women than in men.^{12, 15} On the contrary, some authors reported this condition occurs more frequently in boys.^{18, 19} Other authors observed no definitive sex predilection.^{13, 20-22}

The etiology of geographic tongue remains unknown. Several related etiologic factors have been proposed, however, none of the suggested causes provide clear-cut evidence of a causal relationship. Some investigators have classified this condition as a congenital anomaly; other researchers have discussed the role of heredity in its development. Eidelman et al.²³ reported the prevalence of geographic tongue in parent and sibling combinations was significantly higher than in the general population and concluded it was familial and that heredity plays a significant etiologic role. Other authors have also postulated that a positive family history suggests the possible implication of genetic factors.^{24, 25} A study of Greek subjects with geographic tongue indicated an increased frequency of both DR5 and DRW6 antigens when compared to controls. These findings support the theory genetic factors participate in the pathogenesis of geographic tongue.²⁶

Attempts have been made to demonstrate an association between geographic tongue and various systemic and/or psychological conditions. These conditions include

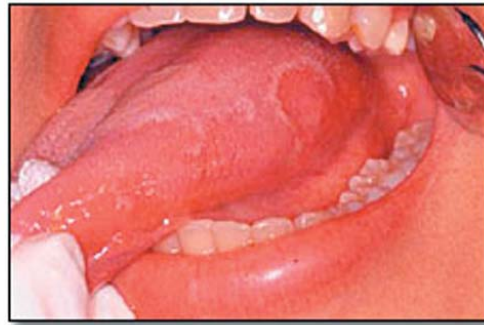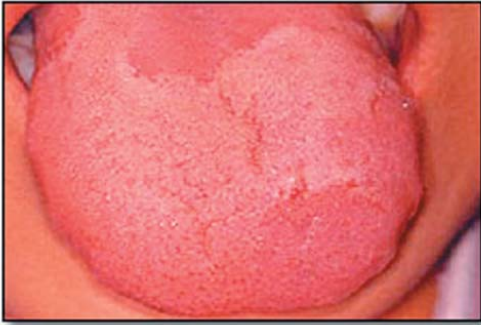gastrointestinal disorders associated with anemia¹⁷, Reiter's syndrome²⁷, psoriasis^{27, 28}, emotional stress²⁹, allergies^{30, 31}, diabetes³², and hormonal disturbances.³³ However, a definitive causal relationship has not yet been established. A significant increased frequency of geographic tongue was reported in atopic patients.^{31, 34} Marks et al.^{31, 34} concluded a positive association between geographic tongue and atopy exists, and further postulated that geographic tongue and asthma/rhinitis may have a similar pathogenesis. Marks et al.³⁵ provided additional support for a genetic basis for geographic tongue by demonstrating an increased incidence of tissue type HLA-B15 in atopic patients with geographic tongue.

Some investigators have suggested geographic tongue is an oral manifestation of psoriasis.^{27, 28, 36, 37} Because of the similarities in the clinical, histologic, and immunohistochemical findings, those researchers considered psoriasis and geographic stomatitis as related lesions. However, Espelid et al.¹⁰ failed to show a connection between geographic tongue and psoriasis since HLA-DR was not strongly expressed on the keratinocytes in their samples. van der Wal et al.⁵ stated an incidentally reported association of geographic stomatitis with psoriasis in a patient did not provide sufficient proof of a common etiologic basis for the two conditions. Raghoobar et al.⁶ concluded geographic tongue and psoriasis occur coincidentally rather than sharing an etiologic relationship.

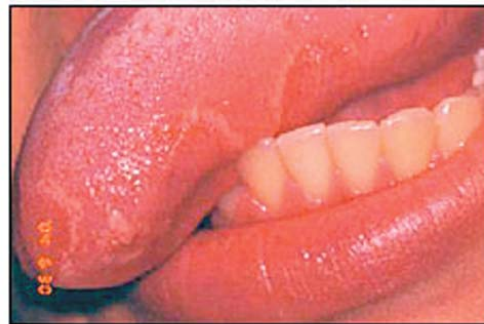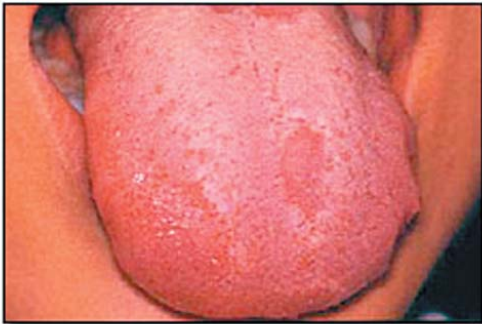Psychosomatic factors appear to play a significant role in the etiology of geographic tongue.^{7, 29} It has been reported lesions arise in connection with pronounced emotional stress. Redman et al.²⁹ found a higher prevalence of geographic tongue in mentally ill patients than in university students. They also noted that when under emotional stress the student group with geographic tongue tended to have more severe lesions. Findings such as these support the possible role of psychological factors in the etiology of geographic tongue.

Wysocky et al.³² studied the relationship between geographic tongue and diabetes and found a fourfold increase in the prevalence of geographic

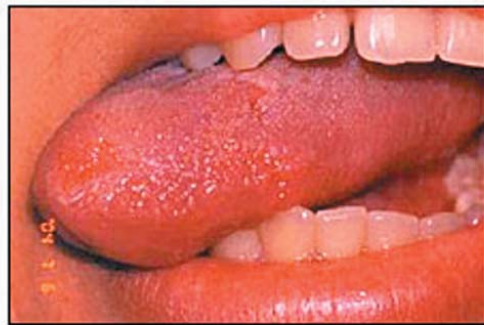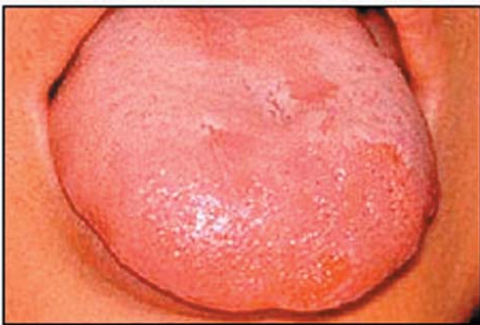Figure 3. Migratory changes of geographic tongue lesions in a 19-year old woman.



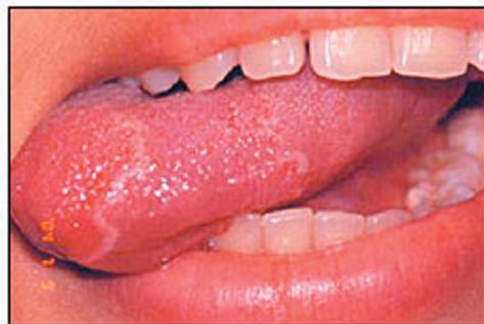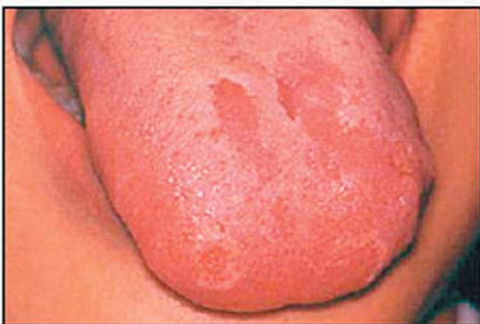A. November 2003



B. June 2004



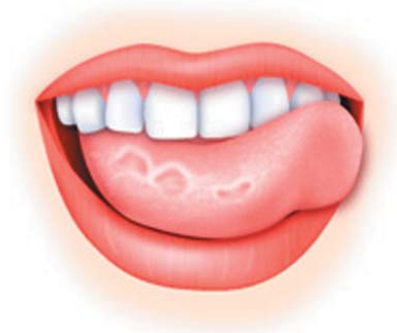C. July 2004



D. July 2004

tongue in the diabetic group. However, a recent study by Guggenheimer et al.³⁸ reported no significant correlation between geographic tongue and insulin-dependent diabetes mellitus.

An association between geographic tongue and fissured tongue has been documented^{13, 16, 18-20, 39, 40}, and a genetic linkage between the two conditions in males has been suggested.²¹ The same genes may be responsible for both conditions.^{3, 23}



The diagnosis of geographic tongue is based on its characteristic history of migration, its circinate appearance, and a lack of significant pain (as opposed to burning) as a subjective complaint.^{1, 6, 11} Histopathologic studies have produced no specific microscopic features. Histologically, it is characterized by the loss of filiform papillae leaving a flattened mucosal surface with irregular rete pegs. The white circinate lines show peripheral hyperkeratosis and acanthosis. The central erythematous areas reveal desquamation of parakeratin and exocytosis of polymorphonuclear leukocytes and lymphocytes into the epithelium, degeneration of epithelial cells, and the formation of microabscesses near the surface. There is supra-papillary thinning. A mixed inflammatory infiltrate of lymphocytes, plasma cells, and neutrophils is seen in the underlying connective tissue.^{2, 9}

There is little information on geographic tongue in Asian populations living in Asia. Thus, our analysis of the clinical data on this condition as it occurs in a Thai population could be a useful addition to the literature. The aims of this study were to investigate the medical history; record the clinical characteristics; and assess possible causative factors in an affected group of the Thai population.

Subjects and Methods

The sample consisted of 188 Thais with geographic tongue lesions and a control group consisting of 188 sex- and age-matched Thais who did not have geographic tongue or any other oral lesions. The study groups were divided into 6 age ranges: 1-19, 20-29, 30-39, 40-49, 50-59, and 60 years and older. Only one examiner, an expert in Oral Medicine, performed all of the clinical examinations. These evaluations were part of the routine oral examination and dental treatment planning procedures performed on all patients selected for dental treatment in the Chulalongkorn University Dental School. All participants were interviewed for their medical history, symptoms, and the nature and migratory pattern regarding the lesions. In this study the diagnosis of geographic tongue and fissured tongue was based solely on the history and clinical features^{41, 42}, and no biopsies or cytology were performed. This is consistent with the method of diagnosis in other studies.^{9, 15} The clinical features of geographic tongue were recorded as a typical form (atrophic patch bounded by a circinate line) or as an atypical form (atrophic patch without a circinate line). The variations in clinical appearance, location of the lesions, associated tongue fissures, and symptoms were recorded. The Pearson chi-square test was used to compare the differences between the geographic tongue and control groups. Significance for the differences between groups was set at $P < 0.05$.



Results

Figure 4 shows the age and sex distribution in geographic tongue subjects. There were 114 women and 74 men, a ratio of 1.5:1. The ages ranged from 9-79 years. Most subjects' age ranged from 9-39 years (78.3%). The highest incidence of geographic tongue in women (22.9%) and in men (16.5%) occurred in the 20-29 year age group. Our data indicates a decline in the incidence of geographic tongue after the age of 39 years in both sexes.

Table 1 shows the distribution of medical conditions among our study groups. Fifty-eight (30.8%) subjects and 46 (24.5%) controls reported at least one medical condition; there were no differences in the incidence of medical conditions between the two groups ($P = 0.167$). The leading medical problems were allergy-related conditions, followed by hypertension, bone and joint disorders, recurrent aphthous ulceration, gastrointestinal disorders, dyslipidemia, thyroid diseases, and hepatic diseases. With respect to allergy-related conditions, the incidence among the subjects and controls was not significantly different (55.2% versus 44.8%, $P = 0.382$). These conditions included drug, food and nonspecific allergies, asthma, rhinitis, and sinusitis. There was one female subject with psoriasis.

Table 2 lists the locations of geographic tongue in our subjects. No extraglossal lesions were detected. Most manifestations of geographic

tongue consisted of lesions at multiple tongue sites (62.8%). The distribution of affected areas was as follows: lateral tongue (68.6%), anterior tongue (58.5%), dorsal tongue (42%), and ventral tongue (10.6%).

Table 3 shows the incidence of clinical features and the association of the variations in the clinical features of geographic tongue and symptoms. Most lesions (69.1%) manifested a typical appearance consisting of a central atrophic area bounded by a raised white circinate line; the remaining lesions were characterized as solely atrophic patches. There were 46 (24.5%) subjects who reported a burning sensation, especially to spicy and/or sour foods. Most subjects did not require any treatment except three individuals whose pain was the major complaint and topical antihistamines were prescribed. There was no association between symptoms and variations in the clinical features in our study sample ($P = 0.124$).

Table 4 shows the incidence of fissures in the geographic tongue subjects and controls. The incidence of fissures was higher in the geographic tongue subjects than in the controls (60.1% versus 27.6%; $P < 0.001$). These differences indicate a significant concurrence between fissures and geographic tongue. We observed a slightly higher concurrence of fissures with the typical form of geographic tongue than with the atypical

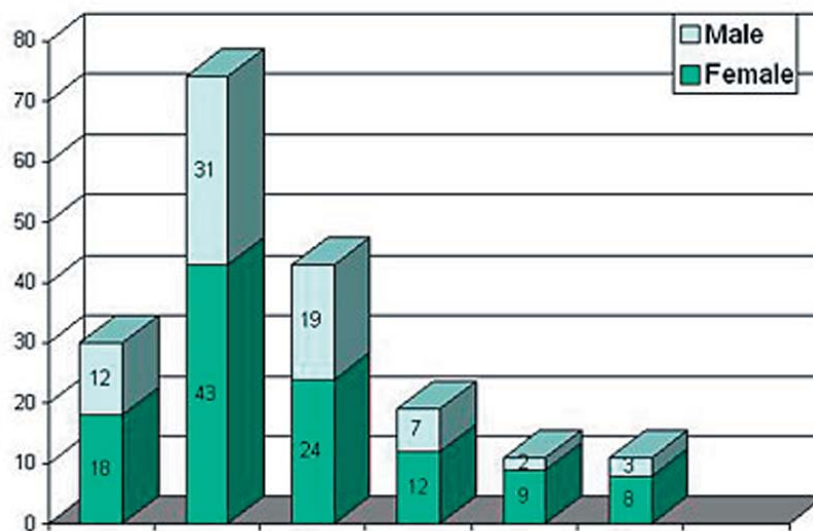


Figure 4. Distribution of geographic tongue subjects in relation to age and sex.

Table 1. Medical conditions in geographic tongue subjects and controls.

Medical conditions	Geographic tongue n (%)	Controls n (%)
Allergy (drugs, food, others)	23 (12.2)	14 (7.4)
Asthma/rhinitis/sinusitis	14 (7.4)	17 (9.0)
Hypertension	9 (4.8)	7 (3.7)
Recurrent aphthous ulcer	7 (3.7)	0 (0.0)
GI disorders	4 (2.1)	2 (1.1)
Dyslipidemia	3 (1.6)	4 (2.1)
Thyroid disease	3 (1.6)	2 (1.1)
Blood disorders	2 (1.1)	1 (0.5)
Cardiovascular diseases	2 (1.1)	2 (1.1)
Hepatic disease	2 (1.1)	3 (1.6)
Stress	2 (1.1)	0 (0.0)
Diabetes	2 (1.1)	1 (0.5)
Bone and joint disorders	2 (1.1)	4 (2.1)
Migraine	1 (0.5)	1 (0.5)
Cerebrovascular diseases	1 (0.5)	0 (0.0)
Psoriasis	1 (0.5)	0 (0.0)
Renal disease	1 (0.5)	0 (0.0)
Lichen planus	1 (0.5)	0 (0.0)
Bell's palsy	1 (0.5)	0 (0.0)
Epilepsy	1 (0.5)	0 (0.0)
Vertigo	0 (0.0)	1 (0.5)

Some patients exhibited more than one medical condition.

Table 2. Distribution of geographic tongue at different locations. (62.8% of the patients exhibited lesions at multiple sites.)

Locations	n (%)
Lateral tongue	129 (68.6)
Anterior tongue	110 (58.5)
Dorsal tongue	79 (42.0)
Ventral tongue	20 (10.6)

Table 3. Clinical features and symptom in geographic tongue.

Clinical features	Burning/pain n (%)	No symptom n (%)	Total n (%)
Atrophic patches with circinate lines	36 (27.7)	94 (72.3)	130 (69.1)
Atrophic patches only	10 (17.2)	48 (82.8)	58 (30.9)
Total	46 (24.5)	142 (75.5)	188 (100)

$\chi^2 = 2.370$, $P = 0.124$

Table 4. Incidence of fissures in geographic tongue and controls.

	With fissures n (%)	No fissures n (%)
Geographic tongue*	113 (60.1)	75 (39.9)
Controls*	52 (27.6)	136 (72.4)
Atrophic patches with circinate lines**	84 (64.6)	46 (35.4)
Atrophic patches only**	29 (50)	29 (50)

* $\chi^2 = 40.187$, $P < 0.001$; ** $\chi^2 = 3.573$, $P = 0.059$

form (64.6% versus 50%, $P = 0.059$). The concurrence of geographic tongue and fissures in women (61.4%) versus men (58.1%) was tested and no association was found ($P = 0.652$).

Discussion

The findings of our study were, in several aspects, consistent with those of earlier reports from other western world investigations. Our results showed the highest incidence of geographic tongue occurred in persons aged 20-29 years. This finding corresponds with those studies reporting the highest incidence of geographic tongue in persons below 29 years of age.¹³⁻¹⁵ In our sample of geographic tongue women were also affected more than men (1.5:1). This finding agrees with most studies. We found no significant difference in the incidence of medical problems between the geographic tongue subjects and controls. Allergy-related conditions were the leading problems, and the incidence of these conditions in the subject group was not significantly higher than those of the control group. Thus, our results do not support previous theories postulating an association between geographic tongue and allergy. We confirmed the finding geographic tongue lesions commonly appear on the lateral margins and tip of the tongue.^{22, 26} The concurrence of geographic tongue and fissures in our study (60.1%) is higher than the 6-45% reported by others.^{13, 19-21,}

²³ One explanation for these discrepancies may be due to differences in the recorded depth of the fissures. For example, in some studies a positive finding was recorded only when the fissures were 2 mm or more in depth and extended over a third or more of the dorsum and/or lateral borders of tongue. We recorded a positive finding when fissures were observed, no matter how deep or how extensive they were. Further, when we excluded geographic tongue subjects with fissures shallower than 2 mm, the concurrence of geographic tongue and fissures in our study was in the same range as other reports (33.5%). In addition we found a much higher incidence of deeper fissures (3 mm or more) in geographic tongue subjects than in the controls (28.2% versus 1.6%). Thus, our results confirmed a significant concurrence of geographic and fissured tongue. These findings agree with the data reported on population samples elsewhere and support the hypothesis that geographic and fissured tongue share the



same etiologic and possibly genetic influences in their development.^{13, 16, 20} Ghose et al.²¹ found a significant association between geographic and fissured tongue in schoolboys and stated this may indicate a genetic linkage between the two conditions in males. In contrast, and in agreement with other reports^{13, 18}, our study showed no sex difference in the association of the two conditions between sexes. We observed a slightly higher incidence of fissures with the typical form of geographic tongue than the atypical form (64.6% versus 50%); this observation was also reported by Aboyan et al.³⁹ The majority of our subjects (75.5%) were asymptomatic; this finding is consistent with the reports of other investigators. However, some of our patients reported sour juices or spicy foods did trigger recurrence of the lesions and burning sensation. Regezi et al.² stated symptoms might be more common when fissures were present and infected with candida organisms. In the present study the occurrence of symptomatic geographic tongue did not differ either with the presence or absence of fissures. Also, there was no association between the burning sensation and the depth of fissures. Candida identification was not performed in our study. Whether or not symptomatic geographic tongue is associated with candidal infection in fissures needs further investigation. Most authors do not consider treatment necessary but deem it important to reassure patients of the innocent nature of the lesions in order to save them from further worry and/or continuous and ineffective therapeutic measures. In symptomatic cases successful management was achieved with topical or systemic antihistamines.^{1, 43} Only three patients in our study required palliative treatment, and a successful symptomatic relief was achieved by antihistaminics due to their local anesthetic effect. In our study there was only one psoriasis patient with geographic tongue, thus, it was not possible to investigate or conclude any associa-

tion between the two conditions. Based on our study sample, the incidence of coexistent psoriasis was less than one percent.

Conclusion

The results of this study correspond with the findings reported in western populations. Our results showed a significant co-existence of

geographic tongue and fissured tongue. We observed a higher concurrence of fissures with the typical appearance of a central atrophic area bounded by a raised circinate line. We did not find any association between geographic tongue and any systemic disease. Also, there was no correlation between geographic tongue and a history of allergy.

References

1. Sigal MJ, Mock D. Symptomatic benign migratory glossitis: report of two cases and literature review. *Pediatr Dent* 1992; 14: 392-396.
2. Regezi JA, Sciubba JJ. Oral pathology. Clinical-pathologic correlations. Philadelphia: WB Saunders; 1993: 150-151.
3. Hume WJ. Geographic stomatitis: A critical review. *J Dent* 1975; 3: 25-43.
4. Brooks JK, Balciunas BA. Geographic stomatitis: review of the literature and report of five cases. *J Am Dent Assoc* 1987; 115: 421-424.
5. van der Wal N, van der Kwast WA, van Dijk E, et. al. Geographic stomatitis and psoriasis. *Int J Oral Maxillofac Surg* 1988; 17: 106-109.
6. Raghoobar GM, de Bont LG, Schoots CJ. Erythema migrans of the oral mucosa. Reported of two cases. *Quintessence Int* 1988; 19: 809-811.
7. Saprio SM, Shklar G. Stomatitis areata migrans. *Oral Surg Oral Med Oral Pathol* 1973; 36: 28-33.
8. Warnock GR, Correll RW, Pierce GL. Multiple, shallow, circinate mucosal erosions on the soft palate and base of uvula. *J Am Dent Assoc* 1986; 112: 523-524.
9. Rhyne TR, Smith SW, Minier AL. Multiple, annular, erythematous lesions of the oral mucosa. *J Am Dent Assoc* 1988; 116: 217-218.
10. Espelid M, Bang G, Johannessen AC, et. al. Geographic stomatitis: report of 6 cases. *J Oral Pathol Med* 1991; 20: 425-428.
11. Lucas VS, Challacombe SJ, Morgan PR. Erythema migrans: an unusual presentation. *Br Dent J* 1993; 175: 258-259.
12. Halperin V, Kolas S, Jefferis KR, et. al. The occurrence of fordyce spots, benign migratory glossitis, median rhomboid glossitis, and fissured tongue in 2,478 dental patients. *Oral Surg Oral Med Oral Pathol* 1953; 6: 1072-1077.
13. Sedano HO, Carreon Freyre I, Garza de la Garza ML, et. al. Clinical orodental abnormalities in Mexican children. *Oral Surg Oral Med Oral Pathol* 1989; 68: 300-311.
14. Kleinman DV, Swango PA, Niessen LC. Epidemiologic studies of oral mucosal conditions - methodologic issues. *Community Dent Oral Epidemiol* 1991; 19: 129-140.
15. Banoczy J, Rigo O, Albrecht M. Prevalence study of tongue lesions in a Hungarian population sample. *Community Dent Oral Epidemiol* 1993; 21: 224-226.
16. Darwazeh AM, Pillai K. Prevalence of tongue lesions in 1013 Jordanian dental outpatients. *Community Dent Oral Epidemiol* 1993; 21: 323-324.
17. Banoczy J, Szabo L, Csiba A. Migratory glossitis: A clinical-histologic review of seventy cases. *Oral Surg Oral Med Oral Pathol* 1975; 39: 113-121.
18. Chosack A, Zadik D, Eidelman E. The prevalence of scrotal tongue and geographic tongue in 70,359 Israeli schoolchildren. *Community Dent Oral Epidemiol* 1974; 2: 253-257.
19. Voros-Balog T, Vincze N, Banoczy J. Prevalence of tongue lesions in Hungarian children. *Oral Dis* 2003; 9: 84-89.
20. Redman RS. Prevalence of geographic tongue, fissured tongue, median rhomboid glossitis, and hairy tongue among 3,611 Minnesota school children. *Oral Surg Oral Med Oral Pathol* 1970; 30: 390-395.

21. Ghose LJ, Baghdady VS. Prevalence of geographic tongue and plicated tongue in 6090 Iraqi schoolchildren. *Community Dent Oral Epidemiol* 1982; 10: 214-216.
22. Konis AB. Geographic tongue. A case report. *N Y State Dent J* 1992; 58: 28-29.
23. Eidelman E, Chosack A, Cohen T. Scrotal tongue and geographic tongue: polygenic and associated traits. *Oral Surg Oral Med Oral Pathol* 1976; 42: 591-596.
24. Dawson TA, Pielou WD. Geographical tongue in three generations. *Br J Dermatol* 1967; 79: 678-681.
25. Kuramoto Y, Tadaki T, Hatchome N, et. al. Geographic tongue in two siblings. *Dermatologica* 1987; 174: 298-302.
26. Fenerli A, Papanicolaou S, Papanicolaou M, et. al. Histocompatibility antigens and geographic tongue. *Oral Surg Oral Med Oral Pathol* 1993; 76: 476-479.
27. Weathers DR, Baker G, Archard HO. Psoriasiform lesions of the oral mucosa (with emphasis on "ectopic geographic tongue"). *Oral Surg Oral Med Oral Pathol* 1974; 37: 872-888.
28. Pogrel MA, Cram D. Intraoral findings in patients with psoriasis with special reference to ectopic geographic tongue (erythema circinata). *Oral Surg Oral Med Oral Pathol* 1988; 66: 184-189.
29. Redman RS, Vance FL, Gorlin RJ, et. al. Psychological component in the etiology of geographic tongue. *J Dent Res* 1966; 45: 1403-1408.
30. Barton DH, Spier SK, Crovello TJ. Benign migratory glossitis and allergy. *Pediatr Dent* 1982; 4: 249-250.
31. Marks R, Czarny D. Geographic tongue: sensitivity to the environment. *Oral Surg Oral Med Oral Pathol* 1984; 58: 156-159.
32. Wysocki GP, Daley TD. Benign migratory glossitis in patients with juvenile diabetes. *Oral Surg Oral Med Oral Pathol* 1987; 63: 68-70.
33. Waltimo J. Geographic tongue during a year of oral contraceptive cycles. *Br Dent J* 1991; 171: 94-96.
34. Marks R, Simons MJ. Geographic tongue - a manifestation of atopy. *Br J Dermatol* 1979; 101: 159-162.
35. Marks R, Taitt B. HLA antigens in geographic tongue. *Tissue Antigens* 1980; 15: 60-62.
36. Dawson TA. Tongue lesions in generalized pustular psoriasis. *Br J Dermatol* 1974; 91: 419-424.
37. Ulmanky M, Michelle R, Azaz B. Oral psoriasis: report of six new cases. *J Oral Pathol Med* 1995; 24: 42-45.
38. Guggenheimer J, Moore PA, Rossie K, et. al. Insulin-dependent diabetes mellitus and oral soft tissue pathologies. I. Prevalence and characteristics of non-candidal lesions. *Oral Surg Oral Med Oral Pathol Oral Radiol Endod* 2000 ; 89 : 563-569.
39. Aboyans V, Ghaemmaghami A. The incidence of fissured tongue among 4,009 Iranian dental outpatients. *Oral Surg Oral Med Oral Pathol* 1973; 36: 34-38.
40. Correll RW, Wescott WB, Jensen JL. Nonpainful, erythematous, circinate lesions of a protean nature on a fissure tongue. *J Am Dent Assoc* 1984; 109: 90-91.
41. van der Waal I, Pindborg J. Diseases of the tongue. Chicago: Quintessence Publishing: 1986; 43-46.
42. World Health Organization. Guide to epidemiology and diagnosis of oral mucosal disease and conditions. *Community Dent Oral Epidemiol* 1980; 8: 1-26.
43. Assimakopulos D, Patrikakos G, Fotika C, et. al. Benign migratory glossitis or geographic tongue: An enigmatic oral lesion. *Am J Med* 2002; 113: 751-755.

About the Authors

Aree Jainkittivong, BSc, DDS, MS



Dr. Jainkittivong is an Associate Professor in the Department of Oral Medicine, of the Faculty of Dentistry, at Chulalongkorn University in Bangkok, Thailand.

e-mail: Aree.J@chula.ac.th

Robert P. Langlais, DDS, MS, FRCD



Dr. Langlais is a Professor in the Department of Dental Diagnostic Science, the University of Texas Health Science Center at San Antonio Dental School, TX, USA.

e-mail: Langlais@uthscsa.edu

Acknowledgement

The authors thank Dr. Vilaiwan for her effort in extracting some of the geographics tongue subjects for our study.