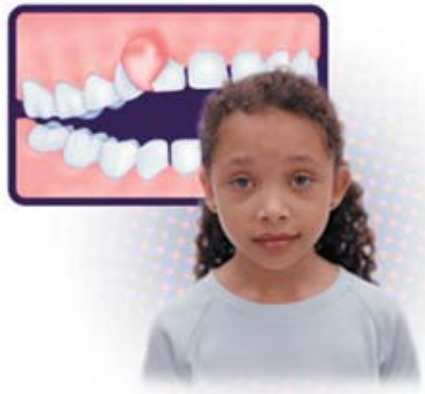

## Odontogenic Myxoma – A Case Report and Clinico-Radiographic Study of Seven Tumors

Mariela Siqueira Gião Dezotti, DDS, PhD;  
Luciana Reis Azevedo, DDS, PhD;  
Flávia Noemi Gasparini Kiatake Fontão, DDS, PhD;  
Ana Lúcia Álvares Capelozza, DDS, PhD;  
Eduardo Sant'ana, DDS, PhD



### Abstract

The primary aim of this paper is to present clinical and radiographic aspects of odontogenic myxomas diagnosed at the Stomatology Clinic of Bauru School of Dentistry, University of São Paulo, Brazil and to compare them with data reported in a series published in the literature. A second objective is to report a clinical case of odontogenic myxoma in a 9-year-old patient in whom the lesion involved the anterior region of the maxilla. Dental records between 1975 and 2000 were reviewed and seven cases diagnosed as odontogenic myxoma were found in individuals aged from nine to 60 years. Of these, four occurred in women and three in men. The mandible was affected in five cases and the maxilla in two. All patients presented with asymptomatic swelling in the affected area. A mixed radiographic result was observed in five patients, while in two patients the lesion was completely radiolucent. The borders of the lesion were well-defined in six patients. In four cases there was dental displacement, although root resorption was not observed in any of these. The treatment of choice was surgical excision. Four cases did not recur during the period of follow-up, which varied from nine months to 19 years. It was concluded the clinico-radiographic study of odontogenic myxomas should be continually refined with the aim of offering the patient an appropriate treatment, since the lesion presents a high potential for recurrence.

**Keywords:** Odontogenic myxoma, oral tumors, odontogenic tumors

**Citation:** Dezotti MSG, Azevedo LR, Fontão FNGK, Capelozza ALA, Sant'ana E. Odontogenic Myxoma – A Case Report and Clinico-Radiographic Study of Seven Tumors. J Contemp Dent Pract 2006 February;(7) 1:117-124.

## Introduction

According to the World Health Organization (WHO), the odontogenic myxoma is classified as an odontogenic tumor of ectomesenchymal origin. It appears to originate from the dental papilla, follicle, or periodontal ligament.<sup>1,2</sup>

Odontogenic myxoma is a locally invasive lesion that does not metastasize and exhibits slow and asymptomatic growth, sometimes resulting in expansion or even perforation of the corticals of the involved bone.<sup>3</sup> Radiographically, the tumor presents itself as a radiolucent uni- or multilocular image with well-defined borders and a fine, bony trabeculae within its interior expressing a “honey combed,” “soap bubble,” or “tennis racket” appearance.<sup>4,5</sup> Dental displacement is a relatively common finding, although root resorption is rarely seen.<sup>6</sup>

Microscopically, the tumor consists of rounded, spindle, and stellate cells arranged in a loose, myxoid stroma with few collagen fibrils. Small islands of apparently inactive epithelial odontogenic rests may be scattered through the myxoid substance.<sup>7,8</sup> There is a microscopic resemblance between odontogenic myxoma and dental papilla.<sup>2,9</sup> According to some authors,<sup>9</sup> myxomas lack the epithelial lining found in many dental follicles. A microscopic resemblance can also be noticed between odontogenic myxoma and odontogenic fibroma. Handlers et al. observed, in the latter, the presence of a spectrum of fibrous connective tissue stroma varying from myxoid to densely hyalinized and from acellular to cellular. Ultrastructural findings indicate odontogenic myxoma and central odontogenic fibroma share many common morphologic features and have an apparently similar histogenesis.<sup>11</sup>

Recommended therapy varies from curettage to radical excision. Complete surgical removal can be difficult as the lesion is not encapsulated and because the myxomatous tissue infiltrates adjacent bone tissue. These characteristics may explain the high rate of recurrence of myxomas, which ranges from 10 to 33% with an average of 25%.<sup>3-6,12</sup>

The first aim of this article was to catalogue the clinical cases diagnosed microscopically as odontogenic myxoma and to describe their clinical

and radiographic characteristics, comparing these to the data found in the current literature. A second objective was to report a clinical case of odontogenic myxoma in the anterior region of the maxilla in a nine-year-old patient.

## Material and Methods

The dental records of the Stomatology Clinic at the Bauru School of Dentistry, University of São Paulo, Brazil, between 1975 and 2000, were reviewed. After consulting the records, seven patients were identified with a microscopic diagnosis of odontogenic myxoma. Identifying data (age, sex), clinical characteristics (location, symptomatology), and therapeutic decision (treatment and follow-up) were obtained from the case notes. Radiographic characteristics, such as root resorption and dental displacement, were analyzed. The radiographic assessment was carried out by means of a panoramic radiograph available in all the cases. Periapical and occlusal intraoral radiographs were taken at the time of diagnosis in accordance with the clinical instructions. Occlusal radiographs were used for the observation of expansion and/or perforation of the bony corticals. Dental relationships with the lesions and their limits were assessed in periapical radiographs. Radiographically, the lesions were classified as radiolucent when their content was completely radiolucent, radiopaque when they were uniformly radiopaque, and mixed when the lesion was radiolucent and contained in its interior residual bony trabeculae or septa dividing the lesion in various compartments. The borders of the lesion were considered well-defined if they were clearly defined and corticated; poorly defined when they were identified, but not corticated; and diffuse in those cases in which the borders could not be visualised on the radiograph and the zone



of transition between the lesion and the normal bone was indistinct. The data were recorded on a custom-made form and analyzed at a later date.

One case involving the anterior region of the maxilla is described with a discussion of its clinical, radiographic, and microscopic aspects. This case was part of the clinico-radiographic study carried out.

### Results

The clinical and radiographic characteristics and the therapeutic decision for the seven patients with a diagnosis of odontogenic myxoma are given in Table 1.

The age of the patients with lesions diagnosed as odontogenic myxomas varied from nine to 60 years, with an average of 25.4 years. In five cases (71.4%) the patients were between the second and third decades of life; one patient was less than ten and another was over 50 years of age. Of the seven cases of odontogenic myxoma, four (57.1%) occurred in females and three (42.9%) in males. Five lesions (71.4%) were located in the mandible and two (28.6%) in the maxilla. Of the five mandibular lesions three (42.9%) were located in the posterior region, one (14.3%) in the anterior region, and one (14.3%) extended from the left premolars to the right molars. The two cases (28.6%) in the maxilla had an anterior location extending as far as the region of the premolars.

In four cases (57.1%) the lesion caused displacement of the teeth involved by the lesion. Root resorption was not seen in any case. The tumor caused expansion of vestibular and/or lingual corticals of the base of the mandible in 57.1% of cases. Clinical presentation in all of the cases was one of asymptomatic swelling.

Radiographic findings showed five patients (71.4%) presented with a mixed lesion, i.e., with fine bony trabeculae or septa intermingled with a radiolucent area (Figures 2, 3, and 4). Two lesions (28.6%) were completely radiolucent, and none of them presented radiopacity. Six cases (85.7%) exhibited well-defined borders, and in one case (14.3%) the borders were poorly defined.

All of the patients were treated by surgical excision of the lesion. Four cases (57.1%) did not recur during the period of follow-up, which varied from nine months to 19 years. In three cases (42.9%) recurrence could not be determined due to a lack of information in the medical records.

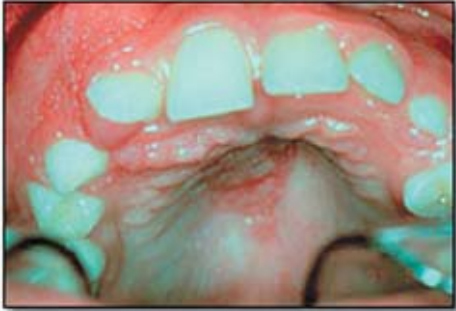### Case Report

A 9-year-old female patient was referred for treatment. She gave a four year history of an enlargement in the upper right alveolar ridge. Extraoral clinical examination revealed discreet facial asymmetry. Intraoral examination revealed a swelling sensitive to palpation, covered by

**Table 1. Clinical and radiographic findings and treatment in the cases of odontogenic myxomas diagnosed at the Stomatology Clinic of the Bauru School of Dentistry, University of São Paulo.**

Case	Year	Age	Sex	Location	Symptomatology	Radiographic aspect	Borders	Treatment
1	1975	27	M	Maxilla	Painless swelling	Mixed	Well-defined	Surgical excision
2	1976	28	F	Mandible	Painless swelling	Radiolucent	Well-defined	Surgical excision
3	1979	14	F	Mandible	Painless swelling	Mixed	Well-defined	Surgical excision
4	1984	16	F	Mandible	Painless swelling	Mixed	Well-defined	Surgical excision
5	1993	25	M	Mandible	Painless swelling	Radiolucent	Well-defined	Surgical excision
6	1999	9	F	Maxilla	Painless swelling	Mixed		Surgical excision
7	2000	60	M	Mandible	Painless swelling	Mixed	Well-defined	Surgical excision

erythematous mucosa, which was painless and with small nodules, in the region including teeth 11, 12, 53, 54, 55, and 16 (Figure 1). Furthermore, the non-eruption of teeth 13, 14, and 15 was noted, while tooth 12 was erupted with lateroersion.



**Figure 1.** Intraoral examination revealing a buccal swelling covered by erythematous mucosa involving teeth 11, 12, 53, 54, 55, and 16.

A panoramic radiograph showed a mixture of radiolucent and radiopaque areas of approximately 5 cm in diameter. Borders were found to be sometimes well- and sometimes poorly-defined (Figure 2).

The lesion displaced tooth 13 to the orbital floor and the premolars distally. An occlusal radiograph detailed the extent of the lesion and the fine trabeculae within it, resembling the appearance of a “tennis racket” (Figure 3).

Periapicals of the region showed absence of root resorption in the teeth involved by the lesion (Figure 4). The diagnosis hypothesis was a odontogenic adenomatoid tumor.

An incisional biopsy revealed fragments of myxomatous tissue consisting of fine collagen fibres, rich in spindled and polyhedral cells. Microscopic opinion was odontogenic myxoma (Figures 5a and 5b).

The patient underwent partial resection of the right maxilla, with only tooth 11 being preserved. A removable partial prosthesis was indicated for temporary use until the patient reached an age at which time it was possible to carry out a definitive treatment with a bone graft and osteointegrated implants. The patient reported satisfaction with the results and showed no signs of recurrence up to December 2002 (Figure 6).

## Discussion

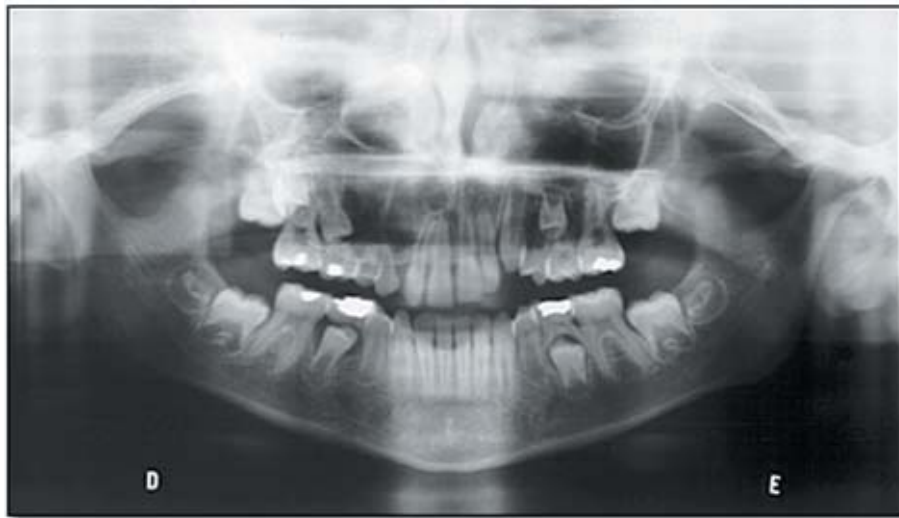
The odontogenic myxoma is a rare tumor of the bone, and almost exclusively of the jaws, comprising around 3 to 6% of all odontogenic tumors.<sup>2,13</sup> Its clinical, radiographic, and therapeutic aspects have been documented by various case reports as well as a few studies in series.<sup>1-9,12-18</sup> These studies indicate the tumor occurs across an age group that varies from 22.7 to 36.9 years. It is rarely seen in patients younger than ten years of age or older than 50. The cases in the present paper presented an average age of 25.4 years, which is in agreement with the literature, while two cases occurred in age groups of lower prevalence (cases 6 and 7). Kaffe et al.<sup>13</sup> reported out of 96 lesions 7% occurred in patients of less than ten years of age.

The majority of studies show the tumor is slightly more common among females<sup>3,5,6,13,16,17</sup>, while others indicate a greater prevalence in males<sup>18</sup> or an equal distribution.<sup>2,8,15,17</sup> Our findings support the latter position.

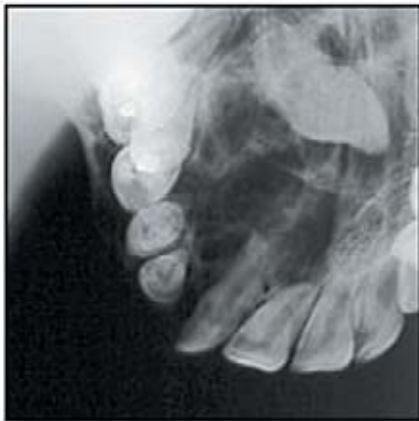The mandible appears to be more frequently affected than the maxilla<sup>13,15-18</sup>, especially in the posterior region<sup>3</sup> this was also supported by our findings.

The majority of myxomas are almost always asymptomatic, although some patients present progressive pain in lesions involving maxilla and maxillary sinus with eventual neurological disturbance. All of the cases reported here exhibited asymptomatic swelling on first consultation and did not develop painful symptomatology over the period of treatment and follow-up, which is in agreement with Ghosh et al.<sup>18</sup> this differs from the findings of MacDonald-Jankowski et al.<sup>16</sup> who observed painful symptomatology in 50% of patients.

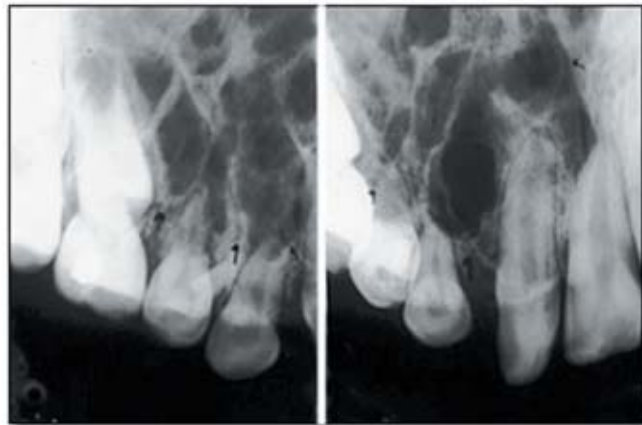In this series a mixed radiographic appearance was observed in five cases (71.4%) and a radiolucent aspect in two (28.6%). Borders were well-defined in six cases (85.7%) and poorly-defined in one (14.3%). On analyzing radiographic aspects of 96 lesions, Kaffe et al.<sup>13</sup> found a radiolucent appearance in 80% of the cases, radiopaque in 7.5%, and mixed in 12.5%. Well-defined borders also were observed in the majority of cases. White et al.<sup>15</sup> observed that out of nine lesions, five



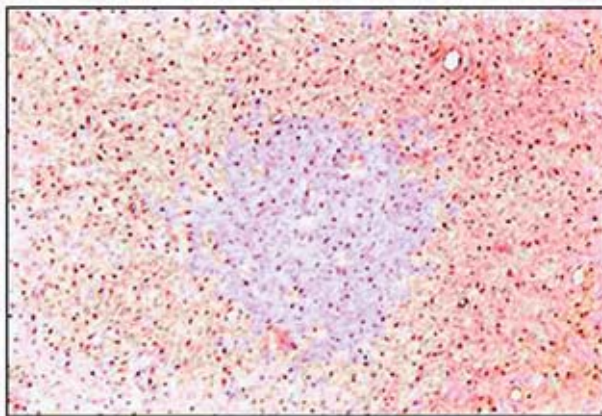
**Figure 2.** Panoramic radiograph showing a multilocular radiolucent area from the right central incisor to the mesial aspect of the upper right first molar. Note tooth 13 displaced to the floor of the orbit and the upper premolars distally.



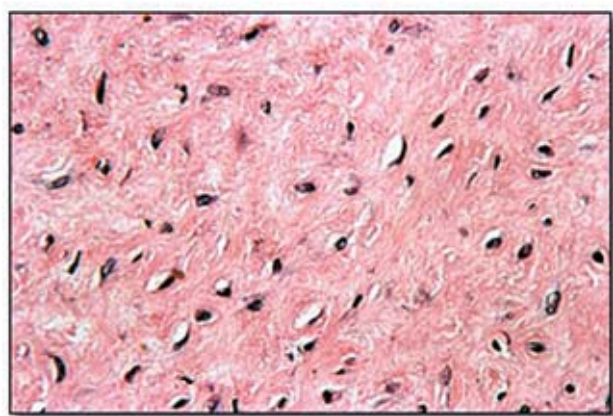
**Figure 3.** Occlusal radiograph showing the extent of the lesion and the fine trabeculae within it.



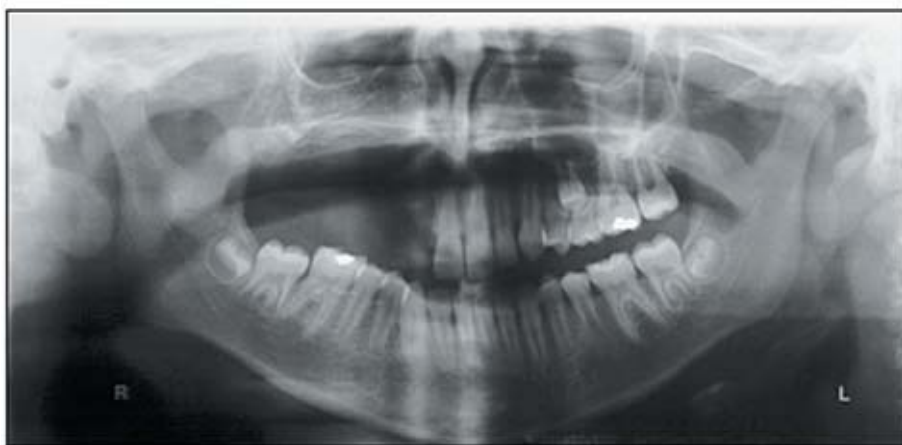**Figure 4.** Periapicals revealed the multilocular appearance of the lesion.



**Figure 5a.** Myxomatous tissue showing fine collagen fibers.



**Figure 5b.** Collagen fibers and spindle and polyhedral cells dispersed in myxomatous tissue.



**Figure 6.** Three year follow-up. Panoramic radiograph showing no signs of recurrence.

odontogenic myxomas presented radiographically as multilocular radiolucent areas and four as unilocular radiolucencies. Peltola et al.<sup>6</sup> carried out a radiographic study of 21 odontogenic myxomas. Unilocular myxomas were more frequently found in the anterior region of the jaws, while multilocular lesions occurred mainly in the posterior region. Our findings did not agree with this last observation. The two cases that occurred in the maxilla exhibited a mixed aspect despite involving the anterior region.

In four cases occlusal radiographs revealed bulging of vestibular and/or lingual cortical bone and/or base of the mandible. Three cases involved the posterior region of the mandible and one the anterior region of the maxilla. Some authors<sup>19</sup> assert odontogenic myxomas in the maxilla are more invasive and destructive than in other locations because they can infiltrate maxillary sinuses. The two cases that occurred in the maxilla involved the anterior region; one of these presented well-defined borders, although these were irregular in some areas, which caused bulging of the vestibular cortical bone and did not displace teeth. The other case corresponded to a lesion with limits that were well-defined in places and poorly-defined in others, which lead to dental displacement but did not expand cortical bone. It remains difficult, therefore, to reach a conclusion regarding the proposed greater invasiveness and destructive capacity of tumors in this location.

In a recent publication MacDonald-Jankowski et al.<sup>20</sup> compared the radiographic aspect of seven odontogenic myxomas in conventional radiographs with computed tomography (CT)

image. The CT image revealed bony cortical and its eventual perforations with greater fidelity. All lesions had cortical perforation and exhibited soft tissue beyond bony borders. Both CT and conventional radiographs showed bony peripheral septa. Dental displacement and root resorption were more clearly seen in conventional radiographs. The authors concluded conventional radiographs allowed a better assessment of the extent and definition of the borders of the lesion with the adjacent bone, and both CT and conventional radiographs can be used to investigate odontogenic myxomas.

Odontogenic myxomas should be included in the differential diagnosis of both radiolucent and mixed lesions, in both of the jaws, for individuals of every age group.<sup>13,14</sup> When unilocular and without trabeculae, the tumor closely resembles periapical, lateral periodontal, and osseous traumatic cysts.<sup>6</sup> When multilocular, it must be distinguished from ameloblastoma, intra-osseous hemangioma, odontogenic keratocyst, and others. In the case reported here the first diagnostic hypothesis was adenomatoid odontogenic tumor (AOT) due to its tendency to be restricted to young patients, its greater frequency in young females, and for being more prevalent in the anterior region of maxilla.<sup>21</sup> As a result of tooth 13 being displaced to the orbital floor (Figure 2), we believe we were facing an AOT of greater proportions. Among the myxomas, a mixed appearance may result from the presence of residual bone. The AOT may contain fine calcifications within its mass, also taking on a mixed radiographic aspect.<sup>21</sup>

The choice of an aggressive treatment for the case described was based on its reported high rate of recurrence.<sup>3-6,12</sup> Ghosh et al.<sup>18</sup> examined ten cases of odontogenic myxomas covering a period of 50 years. Nine of the ten cases were treated by surgical resection and one by local excision. The latter recurred five years after treatment.

Finally, it is concluded clinico-radiographic study of odontogenic myxomas needs to be continually refined with the aim of making professionals better informed regarding the profile of the disease and, in this way, offer the patient an appropriate treatment since the lesion presents a high potential for recurrence.

## References

1. Harrison MG, O'Neill ID, Chadwick BL. Odontogenic myxoma in an adolescent with tuberous sclerosis. *J Oral Pathol Med* 1997;26:339-41.
2. Ward TO, Rooney GE. Asymptomatic expansion of the mandible. *J Am Dent Assoc* 1989;119:169-70.
3. Abiose BO, Ajagbe HA, Thomas O. Fibromyxomas of the jawbones – a study of ten cases. *Br J Oral Maxillofac Surg* 1987;25:415-21.
4. Hendler BH, Abaza NA, Quinn P. Odontogenic myxoma. Surgical management and an ultrastructural study. *Oral Surg Oral Med Oral Pathol* 1979;47:203-17.
5. Lo Muzio L, Nocini P, Favia G, et al. Odontogenic myxoma of the jaws. A clinical, radiologic, immunohistochemical, and ultrastructural study. *Oral Surg Oral Med Oral Pathol Oral Radiol Endod* 1996;82:426-33.
6. Peltola J, Magnusson B, Happonen R-P, et al. Odontogenic myxoma – a radiographic study of 21 tumors. *Br J Oral Maxillofac Surg* 1994;32:298-302.
7. Katz JO, Underhill TE. Multilocular radiolucencies. *Dent Clin North Am* 1984;38:63-81.
8. McLoughlin PM. Odontogenic myxoma: an orthodontic presentation. *Br Dent J* 1991;171:212-3.
9. Kim J, Ellis GL. Dental follicular tissue: misinterpretation as odontogenic tumors. *J Oral Maxillofac Surg* 1993;51:762-7.
10. Handlers JP, Abrams AM, Melrose RJ, et al. Central odontogenic fibroma: clinicopathologic features of 19 cases and review of the literature. *J Oral Maxillofac Surg*. 1991;49:46-54.
11. Wesley RK, Wysocki GP, Mintz SM. The central odontogenic fibroma. Clinical and morphologic studies. *Oral Surg Oral Med Oral Pathol*. 1975;40:235-45.
12. Spencer KR, Smith A. Odontogenic myxoma: case report with reconstructive considerations. *Aust Dent J* 1998;43:209-12.
13. Kaffe I, Naor H, Buchner A. Clinical and radiological features of odontogenic myxoma of the jaws. *Dentomaxillofac Radiol* 1997;26:299-303.
14. Azevedo LR, Sant'Ana E, Dezotti MSG, et al. Mixoma odontogênico: relato de caso e revisão da literatura. *Rev. ABRO* 2000;1:21-5.
15. White DK, Chen S-Y, Mohnac AM, et al. Odontogenic myxoma. A clinical and ultrastructural study. *Oral Surg Oral Med Oral Pathol* 1975;39:901-17.
16. MacDonald-Jankowski DS, Yeung R, Lee KM, et al. Odontogenic myxomas in the Hong Kong Chinese: clinico-radiological presentation and systematic review. *Dentomaxillofac Radiol* 2002;31:71-83.
17. Mosqueda-Taylor A, Ledesma-Montes C, Caballero-Sandoval S, et al. Odontogenic tumors in Mexico – a collaborative retrospective study of 349 cases. *Oral Surg Oral Med Oral Pathol Oral Radiol Endod* 1997;84:672-5.
18. Ghosh BC, Huvos AG, Gerold FP, et al. Myxoma of the jaw bones. *Cancer* 1973;31:237-40.
19. Kumar N, Jain S, Gupta S. Maxillary odontogenic myxoma: a diagnostic pitfall on aspiration cytology. *Diagn Cytopathol* 2002;27:111-4.
20. MacDonald-Jankowski DS, Yeung RW, Li T, et al. Computed tomography of odontogenic myxoma. *Clin Radiol* 2004;59:281-7.
21. Neville BW, Damm DD, Allen CM, et al. *Oral & Maxillofacial Pathology*. Philadelphia:W.B. Saunders, 1998.

## About the Authors

### **Mariela Siqueira Glão Dezotti, DDS, MSc, PhD**

Dr. Dezotti received her PhD in Stomatology from the Bauru School of Dentistry, University of São Paulo, Bauru, São Paulo, Brazil.  
e-mail: [bamb.blv@terra.com.br](mailto:bamb.blv@terra.com.br)

### **Luciana Reis Azevedo, DDS, MSc, PhD**

Dr. Azevedo is an Associate Professor in the School of Dentistry at Pontifical Catholic University of Paraná, Curitiba, Paraná, Brazil.  
e-mail: [l.azevedo@pucpr.br](mailto:l.azevedo@pucpr.br)

### **Flávia Noemi Gasparini Kiatake Fontão, DDS, MSc, PhD**

Dr. Fontão is an Associate Professor in the Department of Radiology of the School of Dentistry at the Universidade do Sagrado Coração, Bauru, São Paulo, Brazil.

### **Ana Lúcia Álvares Capelozza, DDS, MSc, PhD**

Dr. Capelozza is an Associate Professor in the Department of Stomatology of the School of Dentistry at the University of São Paulo, Bauru, São Paulo, Brazil.

### **Eduardo Sant'Ana, DDS, MSc, PhD**

Dr. Sant'Ana is an Associate Professor in the Department of Stomatology (Surgery) of the School of Dentistry at the University of São Paulo, Bauru, São Paulo, Brazil.