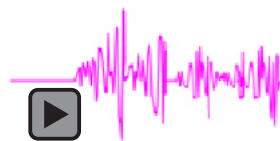
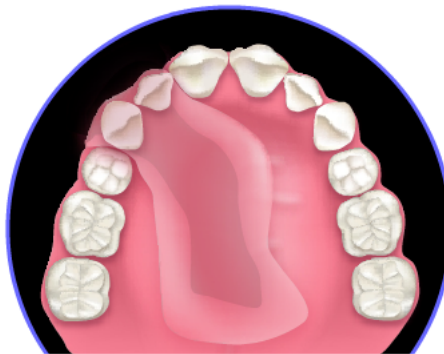
## Evaluation of Speech in Patients with Partial Surgically Acquired Defects: Pre and Post Prosthetic Obturation

A. O. Arigbade, BDS, FWACS, FMCDS;  
O. O. Dosumu, BDS, FWACS, FMCDS; O. P. Shaba, BDS, FWACS;  
T. A. Esan, B.ChD, FMCDS



### Abstract

**Aim:** Maxillectomy often results in a high level of morbidity with significant psychological and functional implications for the patient. Such disabilities include inability to masticate, deglutition, and speech disturbance. Unfortunately, little is known about the nature of the speech disturbance and the influence of the class of surgical defects in this group of patients. The aims of the present study were to assess the effectiveness of the maxillary obturator as a speech rehabilitation aid and to examine the influence of the classes of surgical defects on speech intelligibility (SI).

**Materials and Methods:** Twelve patients aged between 18 and 60 years with surgically acquired partial maxillary defects were included in this study. The patients were given immediate surgical obturators six to ten days after surgery, which were then converted to interim obturators by relining with tissue conditioner. Interim prostheses were used for two to three months until healing and resorption were found satisfactory after which the definitive obturators were fabricated. The SI test described by Plank et al.<sup>1</sup> and Wheeler et al.<sup>8</sup> was employed in this study. There were significant improvements in the mean SI score from 59.8% without prosthetic obturation, to 89.2% following interim obturation, and 94.7% following definitive obturation ( $p < 0.005$ ).

© Seer Publishing

Nine patients (75%) had class I surgical defects, two patients (16.67%) had class II defects, while only one patient (8.33%) had a class VI surgical defect. None of the patients had class III, IV, or class V surgical defects. There was an improvement in the SI score from class I to class VI without obturation, after insertion of interim obturator, and after insertion of the definitive obturator.

**Conclusion:** Results support the widely held view that the maxillary obturator is a useful speech rehabilitation aid. It also shows immediate, interim, and definitive obturators are all important in the speech rehabilitation of patients with surgically acquired maxillary defects. Moreover SI is affected by the class of defect.

**Keywords:** Obturator, maxillectomy, speech intelligibility, SI

**Citation:** Arigbede AO, Dosumu OO, Shaba OP, Esan TA. Evaluation of Speech in Patients with Partial Surgically Acquired Defects: Pre and Post Prosthetic Obturation. J Contemp Dent Pract 2006 February;(7) 1:089-096.

## Introduction

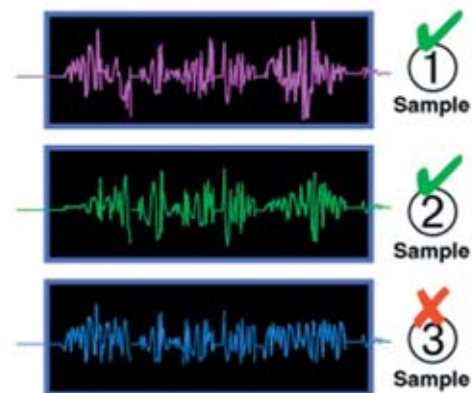
The maxillofacial prosthodontist often receives referred patients who have experienced partial surgical resection of the maxilla (maxillectomy) as a part of cancer therapy.<sup>1</sup> Maxillectomy often results in a high level of morbidity with significant psychological and functional implications for the patient.<sup>2,3</sup> Such disabilities include inability to masticate and disturbances of deglutition and speech.<sup>4,18</sup> Unfortunately, little is known about the nature of the speech disturbance in this group of patients.<sup>1</sup>

Although studies had been done to document the effects of surgery and subsequent prosthetic treatment on the speech of patients undergoing maxillary resection,<sup>1,4,5,6,7,8</sup> literature is scarce on this subject in Africa.

Aramany and Drane<sup>5</sup> published the results of a study assessing the effects on voice quality of extending the nasal portion of the maxillary prostheses in six patients. Each patient recorded a connected speech sample under three conditions: (1) speaking with a low nasal extension prosthesis, (2) speaking with a high nasal extension prosthesis, and (3) speaking without a maxillary prosthesis. As expected, the listeners preferred the voice quality of speech produced with prosthetic obturation to that produced without obturation.

Kipfmüller and Lang<sup>6</sup> evaluated changes in intelligibility occurring in six patients as a function of the treatment stage. Comparisons were made of each patient's speech, which was recorded

prior to and following surgery, both with and without prosthetic obturation of their maxillary defects. Their study showed prosthetic obturation improved speech intelligibility (SI).



Three Connected Speech Sample Conditions

Mahid et al.<sup>7</sup> also reported on SI of post surgical maxillectomy patients with and without a prosthesis in the mouth. Their study showed better SI with prosthetic obturation.

However, in the study done by Plank et al.<sup>1</sup> they found no significant loss in intelligibility across the three stages of treatment.

Various techniques have been used in investigating SI. Wheeler et al.<sup>8</sup> used video and audio recordings of conversational speech in a study of ten patients to define each patient's SI. The conversational speech was played for five untrained listeners seated in a quiet and well

lighted room. Each listener was asked to write, as accurately as possible, the exact words said by the patient. The listener's transcription was then compared with the therapist's transcription made during the recording and verified by the patient. A percent correct score was assigned to each listener's judgment of each patient's speech according to the percentage of words in the patient's discourses correctly identified. Mean percent intelligibility was determined for the patients by averaging each patient's scores recorded by the five listeners.

A similar technique was employed by Plank et al.<sup>1</sup> except no speech therapists were involved and video recordings were not included in the assessments.

Some authors<sup>9</sup> have classified surgical defects based on location and size; previous studies have not been able to show any effect of location and size of surgical defect on SI. However, studies have shown larger defects with few teeth remaining are difficult to obturate and, hence, may present with greater disability than smaller defects.

The aims of the present study were to assess the effectiveness of maxillary obturator as a speech rehabilitation aid in a group of patients with partial surgically acquired maxillary defects from South Western Nigeria and to examine the influence of their surgical defect classes on their SI.

### Materials and Methods

Twelve patients aged between 18 and 60 years with surgically acquired partial maxillary defects were included in this study. The consent of the patient and the ethical clearance was sought and obtained. All the patients were managed following the traditional three distinct phases of rehabilitation of maxillectomy patients (surgical, interim, and definitive phases).<sup>10</sup>

Immediate or surgical phase refers to immediate or early coverage of a palatal defect with an obturator which provides a matrix upon which the surgical packing can be placed, minimizes wound contamination, and enables the patient to speak and swallow effectively immediately after surgery. At the interim phase, initial wound healing would have occurred, thus, necessitating the conversion of the surgical obturator into an interim one for

approximately three months until the tissues are stabilized.

At the definitive phase, wound contracture and healing would have been essentially completed. The definitive prosthesis is, therefore, fabricated to greatly improve speech, swallowing, and appearance.

The patients were immediately given a surgical obturator, which was inserted at the time of surgery and used for six to ten days after surgery.

The surgical obturators were converted to interim obturators in all cases by relining with tissue conditioner, which was modified weekly by addition to or replacement of the existing tissue conditioner. The interim prostheses were used for two to three months until healing and resorption was found satisfactory. The SI test described by Plank et al.<sup>1</sup> and Wheeler et al.<sup>9</sup> was employed in this study. Each subject's response to the question "how can I get to your house" was tape recorded on three occasions:

1. After the removal of the surgical pack and the immediate obturator on the seventh day post operative (i.e., without obturator).
2. After the insertion of the interim obturator (the immediate obturator was converted to an interim obturator by relining with tissue conditioner) on the seventh day post operative.
3. Following delivery of the definitive obturator two to three months post operation.

Recordings were made with subjects seated comfortably in a quiet room facing a tape recorder placed approximately six inches from each speaker's lips. Each of the speech recordings outlined above was presented to a group of ten listeners through earphones one after the other. A group of ten listeners evaluated the speech recorded without an obturator, while a different group of ten listeners evaluated the speech recorded with interim, and another group of ten listeners evaluated the speech recorded with definitive obturators. The listeners were (1) untrained (listeners with no prior experience of speech assessment), (2) not familiar with the surgical procedures that had been performed, and (3) with no prior exposure to the message being evaluated.

Listeners were instructed to write down what each patient said. The response of each listener was evaluated by counting the number of words spoken and intended by the speaker and those correctly understood by each listener and then finding the percentage. Each patient was then given an articulation or intelligibility score as recorded by the listener. An articulation score represents the percentage of items (in these cases, words) correctly identified or understood.

After the evaluation of the responses to the ten listeners, an average score which represents the SI of the patient is then calculated.

Data was analyzed using SPSS version 11(Inc Standard version 2001). Analysis included frequency, calculation of mean values, and standard deviations. Differences between means were tested using student t test and ANOVA. The level of significance of differences was set at 5%.

## Results

Twelve patients who consented were recruited for the study. Six (50%) were males, while six (50%) were females. Their age ranged from 10 to 68 years. The lowest percentage mean SI score of 59.8% was recorded without prosthetic obturation, while this mean value increased to 89.2% following interim obturation. The highest percentage mean SI score of 94.7% was, however, recorded following definitive obturation (Table 1).

Analysis of variant procedures was used to determine whether there were significant differences in the mean SI of the study group at various stages of treatment. The results showed a significant difference in the mean SI across the three stages of treatment ( $p=0.00$ ) (Table 2).

There was a statistically significant difference in the percentage mean intelligibility score between the interim obturation and without prosthetic obturation ( $p=0.000$ ) (Table 3).

**Table 1. Distribution of patents according to SI scores.**

Subjects	Postoperative without Obturation % Score	Interim Obturation % Score	Definitive Obturation % Score	Class of Surgical Defect
1	65.0	95.0	99.0	VI
2	66.4	93.0	94.0	II
3	35.0	75.0	88.2	I
4	68.0	95.0	98.1	I
5	37.0	90.0	93.2	I
6	66.3	95.0	98.0	I
7	32.0	85.0	95.0	I
8	40.0	90.0	95.5	II
9	32.0	86.5	94.0	I
10	30.6	82.0	90.0	I
11	34.0	93.0	97.8	I
12	34.0	91.0	94.0	I
<b>% Mean SI Score</b>	<b>59.8</b>	<b>89.2</b>	<b>94.7</b>	

**Table 2. Multiple comparisons of mean intelligibility scores across the stages of treatment.**

Source of Validation	Sum of Squares	df	Mean Square	F	P Value
Between conditions	17137.662	2	8568.831	149.996	0.000
Within groups	1256.792	22	57.127		

Table 3. Comparison of mean intelligibility scores between interim obturation and without obturation.

Stage of Treatment	No. of Sample	Mean	Std. Deviation	t	df	P value
No obturation	12	59.8	11.96258	-12.534	11	.000
Interim obturation	12	89.2				

Table 4. Comparison of mean intelligibility score between definitive obturation and interim obturation.

Stage of Treatment	No. of Sample	Mean	Std. Deviation	t	df	P value
Interim obturation	12	89.2	3.52870	-5.407	11	.000
Definitve obturation	12	94.7				

Table 5. Distribution of patients according to surgical defect.

Class of Surgical Defect	No.	%
Class I	9	75.00
Class II	2	16.67
Class III	0	0.00
Class IV	0	0.00
Class V	0	0.00
Class VI	1	8.33
<b>Total</b>	<b>12</b>	<b>100.00</b>

Table 6. Percentage mean SI score according to surgical defect.

Class of Surgical Defect	No	Mean SI score without Obturation (%)	Mean SI score with Interim Obturation (%)	Mean SI Score with Definitvie Obturation (%)
Class I	9	42.21±14.7608	88.06±6.6353	94.26±3.4854
Class II	2	53.20±18.6676	91.5±2.1213	94.75±1.0607
Class VI	1	65.2± 0.00	95.0± 0.00	99.0± 0.00

Also, a statistically significant difference was found between interim obturation and definitive obturation ( $P=0.00$ ) (Table 4).

Nine patients (75%) had a class I surgical defect, two (16.67%) had a class II defect, while only one patient (8.33%) had a class VI surgical defect. None of the patients had a class III, class IV, or class V surgical defect (Table 5).

There was an improvement in the SI score as the class of the defect increases without obturation, after insertion of the interim obturator, and after insertion of the definitive obturator (Table 6).

However, this improvement was not statistically significant between a class 1 surgical defect and a class II surgical defect at the no obturation stage ( $p=0.380$ ), interim obturation stage ( $p=0.502$ ), and definitive obturation stage ( $p=0.854$ ).

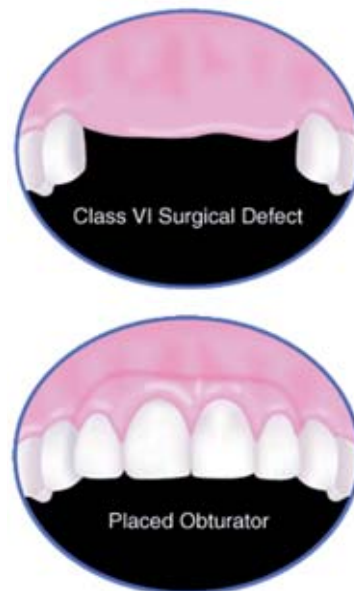Also, there was a further improvement in the mean SI score in class VI compared to class II but no significant difference was found between the two classes at no obturation stage ( $p=0.697$ ), interim obturation stage ( $p=0.390$ ), and at the definitive obturation stage ( $p=0.189$ ).

## Discussion

Restoring the patient to normal function and satisfactory facial appearance (aesthetics) is the mainstay of prosthetic rehabilitation. Loss of sound articulation as a result of surgical defect may probably be the first problem to be encountered by patients following maxillectomy.

In a study done by Umino et al.<sup>11</sup> the lowest mean SI score of 35.7% was recorded without obturation. Also, Sullivan et al.<sup>12</sup> reported the lowest mean SI score of 61% among patients without obturation. In our study the lowest mean intelligibility score of 59.8% was recorded before obturation.

McGregor<sup>13</sup> attributed the low mean intelligibility score without obturation to the oro-antral communication that ensues following maxillary resection. He stated the presence of oro-antral communication eliminates or impairs the ability to seal off the nose, thus, forcing the air to



proceed through the mouth so as to pronounce all vowels and most consonant sounds. Following obturation, however, the impairment is eliminated and the SI improves.

The mean score 59.8% recorded without obturation in this study increased to 89.2% following interim obturation. This is similar to the one reported by Umino et al.<sup>11</sup> This improvement is due to the sealing off of the oro-antral communication, the ability of the tongue to articulate sounds by the seal produced by the tip of the tongue, and the interim obturator.<sup>13</sup>

The highest mean intelligibility score (94.7%) was recorded in this study following definitive obturation. This value is comparable to the mean score of 94% recorded by Sullivan et al.<sup>12</sup> and 97.3% recorded by Plank et al.<sup>1</sup> This improvement may be a result of the addition of teeth to the obturator, a proper seal produced by the definitive obturator after complete healing, and resonance of sounds produced by the hollow design of the obturator.<sup>19</sup>

Lawson<sup>14</sup> explained in order to pronounce certain consonants clearly, a lateral seal produced by the sides of the dorsum of the tongue making contact with the upper posterior teeth is necessary. Similarly, McGregor<sup>13</sup> and Kornblith et al.<sup>15</sup> explained to pronounce consonants like F, V (labiodental sound), and Th (dental sound), the presence of teeth is required. Therefore, when the oral cavity is altered as a result of loss

of teeth and the supporting maxilla, difficulty may be experienced in making the necessary contacts required to produce various speech sounds. Addition of prosthetic teeth to an obturator, therefore, caused less difficulty in pronouncing words and less change in voice quality after surgery in patients with surgically acquired maxillary defects.

The slight variations observed in the mean SI in these studies might not be unconnected with the different number of patients employed by the investigators. Plank et al.<sup>1</sup> employed ten patients, while 34 patients were employed by Sullivan et al.<sup>12</sup>

There were significant differences in the mean SI scores across the three stages of prosthetic treatment ( $P < 0.05$ ). There was also a highly significant difference between the mean SI score recorded without obturation and following interim obturation  $P < 0.05$  and between definitive obturation and interim obturation ( $P < 0.05$ ). These findings were similar to the results recorded by Umino et al.<sup>11</sup> and Sullivan et al.<sup>12</sup> This shows the three types of obturators namely: surgical, interim, and definitive are indeed beneficial to the patient. Hence, prosthetic intervention should start at the time of surgical resection.<sup>16</sup>

Studies have been silent on the effects of location and size of defects on SI; we found in our studies class I had the lowest mean SI score across the various stages of treatment (without obturation  $42.21\% \pm 14.76$ , with interim obturation  $88.06\% \pm 6.6353$ , and with definitive obturator  $94.26\% \pm 3.4854$ ). This might not be unconnected with the

fact half of the palate is resected with remaining teeth on one side of the jaw. This may result in instability in the obturator due to lack of cross arch support and may make sound articulation difficult for the patient.

There was an improvement in the mean SI score in class II compared with class I ( $53.20\% \pm 18.667$  without obturation,  $91.0\% \pm 2.1213$  with interim obturation, and  $94.75\% \pm 1.0607$  with a definitive obturator). This is because the resection allows teeth to be present on the same side of the jaw as the surgical defect. This could lead to improved stability and retention of the obturators.

Although no patient belonged to classes III, IV, and V in our study, further studies should be carried out to evaluate their effect on SI and other oral functions.

The patient with a class VI surgical defect in our study had the highest mean SI score in all stages of the treatment (without obturation  $65.0\%$ , interim  $95.0\%$ , and definitive  $99.0\%$ ). The reason for this good result may be due to a characteristic in this class of defect where only the anterior teeth are lost, thereby, leaving the posteriors for rigid support and good retention. This will ultimately result in good oral function.

### Conclusion

The results of the present study support the widely held view the maxillary obturator is a useful speech rehabilitation aid.<sup>17</sup> It also shows immediate, interim, and definitive obturators are all important in the speech rehabilitation of patients with surgically acquired maxillary defects. Moreover, SI is affected by the class of defect.

## References

1. Plank DM, Weinberg B, Chalian VA. Evaluation of speech following prosthetic obturation of surgically acquired maxillary defects. *J Prosth. Dent.* 1981;45: 626 – 638.
2. Lang BR, Bruce RA. Presurgical maxillectomy prosthesis. *J. Prosthet Dent* 1967;17: 613-619.
3. Piff C. *Let's face it*. London: Victor Gollanz Ltd, 1985
4. Morton M. Oral cancer and precancer: after –care and terminal care. *Br. Dent. J.* 1990; 168: 283 – 286.
5. Aramany MA, Drane JB. Effect of nasal extensions on the voice quality of acquired cleft palate patients. *J. Prosth. Dent.* 1972; 27: 194 – 195.
6. Kipfmüller LS, Lang BR. Pre-surgical maxillary prosthesis. An analysis of speech intelligibility. *J. Prosth. Dent.* 1972; 28: 620 – 621.
7. Majid AA, Weinberg B, Chalian VA. Evaluation of speech following prosthetic obturation of surgically acquired maxillary defects. *J. Prosth. Dent.* 1974; 32: 87-88.
8. Wheeler RL, Logemann JA, Morton SR. Maxillary reshaping prosthesis: Effectiveness in improving speech and swallowing of post-surgical oral cancer patients. *J. Prosth. Dent.* 1980;43: 313 – 319.
9. Aramany MA. Basic principles of obturator design for partially edentulous patients. Part I: classification *J. Prosth. Dent.* 2001; 86: 559 – 561
10. Wolfaardt JF. Modifying a surgical obturator prosthesis into an interim obturator prosthesis. A clinical report. *J. Prosth. Dent.* 1989; 62: 619 – 621.
11. Umino S, Masunda G, Ono S, et al. Speech intelligibility following maxillectomy with and without a prosthesis: an analysis of 54 cases *J. Oral Rehab.* 1998;25: 153- 158.
12. Sullivan M, Gaebler C, Beukelman D, et al. Impact of palatal prosthodontic intervention on communication performance of patients maxillectomy defects: a multilevel outcome study. *Head and Neck.* 2002; 24: 530 – 538.
13. McGregor AR. Fenn, Liddelow and Gimson's *Clinical Dental prosthetics*. Third Ed. Butterworths, London, 1989; pp 136 – 137, 315 – 316.
14. Lawson MA. Speech and its relation to dentistry: The influence of oral structures on speech. *The Dental Practitioner and Dental Record* 1968;19:112 – 118.
15. Kornblith AB, Zlotolow IM, Gooen J, et al. Quality of life of maxillectomy patients using an obturator prosthesis. *Head and Neck* 1996;18: 323 – 334.
16. Jacob RF. *Clinical management of the edentulous maxillectomy patient in Clinical Maxillofacial Prosthetics*. First ed. Quintessence Publishing Co, Illinois, 2000; pp 85.
17. Groetsema WR. An overview of the maxillofacial prosthesis as a speech rehabilitation aid. *J. Prosth. Dent.* 1987;57: 204- 208.
18. Freidline CW. Immediate prosthetic obturation of the partially resected maxilla in edentulous patients. *J prosthet Dent* 1980; 44:72-73.
19. Blair FM, Hunter NR. The hollow box maxillary obturator. *Brit. Dent J* 1998; 184(10):484-487.



## About the Authors

**A. O. Arigbede, BDS, FWACS, FMCDS**



Dr. Arigbede is the former Senior Registrar in the Department of Restorative Dentistry of the Faculty of Dentistry at the University of Ibadan in Ibadan, Nigeria.

e-mail [ayo672002@yahoo.com](mailto:ayo672002@yahoo.com)

**O. O. Dosumu, BDS, FWACS, FMCDS**



Dr. Dosumu is a Senior Lecturer/Consultant in the Department of Restorative Dentistry of the Faculty of Dentistry at the University of Ibadan in Ibadan, Nigeria.

**O. P. Shaba, BDS, FWACS**



Dr. Shaba is a Senior Lecturer/Consultant in the Department of Restorative Dentistry of the College of Medicine at the University of Lagos in Lagos, Nigeria.

**T. A. Esan, B.ChD, FMCDS**



Dr. Esan is a Lecturer/Consultant in the Department of Restorative Dentistry of the Faculty of Dentistry at Obafemi Awolowo University in Ile-Ife, Nigeria.