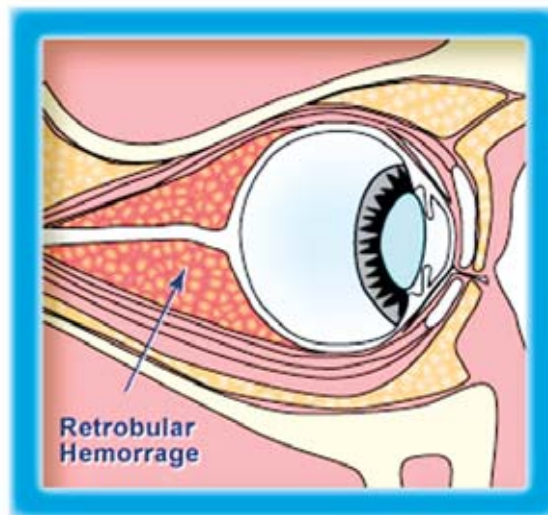


## Retrobulbar Hemorrhage: A Case Report

R. A. Machado, DDS, MS, PhD Student;  
R. Lanes Silveira, DDS, MS, PhD student;  
H. O. I. Borges, DDS, MS, PhD student;  
A. M. Bourguignon Filho, DDS, MS;  
M. Gerhardt de Oliveira, DDS, PhD



### Abstract

Retrobulbar hemorrhage is a rare complication that may occur after mid-face injuries or following soft and hard tissue surgery around the eyes. The cardinal signs and symptoms of retrobulbar hemorrhage are pain, diplopia, ophthalmoplegia, a progression of increasing proptosis, and decreasing visual acuity leading to blindness. The diagnosis can be confirmed with computed tomography (CT) of the orbit or with ocular ultrasound. These diagnostic images are also important to define the size of the hematoma. This report describes a traumatic retrobulbar hemorrhage. In this case there were no signs of acute visual loss, and conservative treatment was possible without surgical intervention.

**Keywords:** Retrobulbar hemorrhage, eye injuries, maxillofacial injuries

**Citation:** Machado RA, Silveira RL, Borges HOI, Filho AMB, de Oliveira G. Retrobulbar Hemorrhage: A Case Report. J Contemp Dent Pract 2006 May;(7)2:130-136.

© Seer Publishing

## Introduction

Retrobulbar hemorrhage is a rare complication that may occur after mid-face injuries<sup>1,2</sup> or following soft or hard tissue surgery around the eyes.<sup>3</sup> If left untreated, blindness can result.<sup>4</sup> Retrobulbar hemorrhage can also develop after peribulbar local anesthesia associated with chronic ingestion of *Gingko biloba*.<sup>5</sup> The most feared complication resulting from blepharoplasty is vision loss due to retrobulbar hematoma; fortunately, the occurrence is rare.<sup>6</sup> It is mandatory to have a detailed eye examination performed by an ophthalmological colleague.<sup>7</sup> Hatton et al.<sup>8</sup> observed the most common injuries in patients with orbital trauma were periocular lacerations (96.1%), orbital fracture (15.6%), and retrobulbar hemorrhage (7.8%).

The cardinal signs and symptoms of retrobulbar hemorrhage are pain, diplopia, ophthalmoplegia, a progression of increasing proptosis, and decreasing visual acuity leading to blindness.<sup>1,5</sup> Bleeding into the intraorbital space may cause acute visual loss by compressing the optic nerve and its vascular supply.<sup>9</sup>

The diagnosis can be confirmed with computed tomography (CT) of the orbit or with ocular ultrasound. These diagnostic images are also important in defining the size of the hematoma.<sup>5,7</sup>

The initial management of retrobulbar hemorrhage includes regular and careful monitoring for any signs of visual deterioration, which would require emergency surgery (optic nerve decompression). Non-operative treatments include bed rest with the head of the patient's bed elevated, ice packs, analgesia, and sedatives to lower the blood pressure and abate further hemorrhage. Some pharmacological therapies may include administration of mannitol, acetazolamide, topical timolol as eye drops, corticosteroids, and possibly inhaled carbon dioxide.<sup>2,5,7</sup>

This report describes a traumatic retrobulbar hemorrhage. There were no signs of acute visual loss, and conservative treatment was performed without surgical intervention.

## Case Report

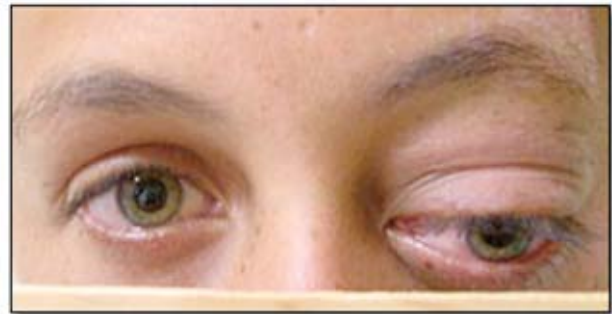A 14-year-old male patient presented to the Oral and Maxillofacial Surgery Service at Cristo Redentor Hospital in Porto Alegre, Brazil with pain

and very large swelling in the left orbital region. He was involved in a bicycle accident 12 days earlier. Immediately following the accident the teenager was treated in another service, where no facial fracture was diagnosed.


Physical examination revealed several dermal abrasions, edema in mid-face and left-orbit regions, enormous exophthalmia (Figure 1), diplopia, epiphora in the left eye, and pain. Due to swelling, it was not possible to use palpation to evaluate the patient for any possible fractures.

No orbital fractures were detected in the facial CT image. Coronal, axial, and sagittal CT images were compatible with hematoma (Figures 2 and 3). A 3D reconstruction image showed intact orbital walls leading to a diagnosis of retrobulbar hematoma.

The patient was referred to an ophthalmologist who confirmed the diagnosis and provided treatment. The recommended treatment was



**Figure 1.** Clinical condition of the patient showing proptosis, periorbital edema, and ecchymosis.



**Figure 2.** Sagittal CT showing retrobulbar hemorrhage (arrow).

conservative, using medications (corticosteroids eye drops, antibiotic ointment, and patching). The pupils and proptosis were carefully monitored. Orbital exploration and a needle biopsy were contemplated but planned only if a proptosis increased or an afferent pupillary defect occurred. The patient was admitted to the hospital, and improvement was evident by the third post-admission day (Figure 4). He was discharged on the eighth day with normal eye findings.

The last follow-up examination, three months after the trauma, demonstrated no recurrence or complications, and the patient had normal visual acuity.

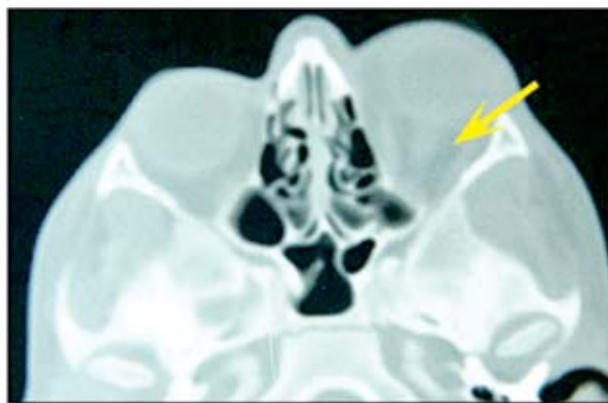
### Discussion

There is a strong association between mid-facial or frontal fractures and eye injuries. Retrobulbar hemorrhage is uncommon after injury and more frequent after surgical reduction of malar fractures. It is also a rare complication of orbital fractures<sup>7</sup> and even hair pulling.<sup>10</sup> Visual outcome after traumatic globe injuries is highly variable, ranging from normal acuity to complete loss of vision.<sup>8</sup>

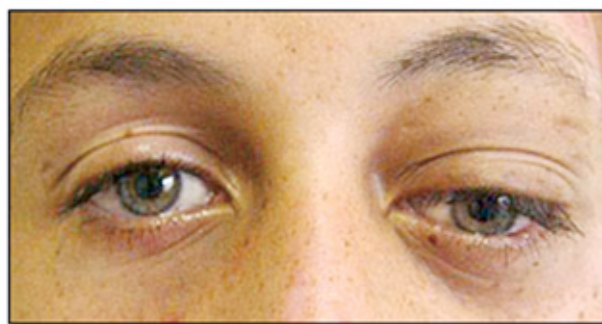When bleeding occurs within the orbit, there is little room to accommodate the increase in volume. The globe and septum are displaced anteriorly causing proptosis and increased pressure and compression of the orbit-contained structures. This can result in a compromise of the vascular supply and compression of the optic nerve.<sup>11</sup>

Patients with periorbital trauma are often best evaluated radiographically with CT of the orbit, preferably with 3 mm axial and coronal sections. Three-dimensional reconstructions are not routinely required.<sup>5</sup> Early diagnosis is crucial for preservation of vision. Most cases of visual loss from retrobulbar hematoma occur when the diagnosis and treatment are delayed.<sup>2,5</sup>

Retrobulbar hemorrhage can be treated with medications such as acetazolamide, mannitol, and steroids or treated with surgical intervention if



**Figure 3.** An axial CT image demonstrating hematoma (arrow).



**Figure 4.** Third post-admission day.

medical management fails to reverse the condition quickly.<sup>1</sup> Emergency orbital decompression is reserved for patients with a history of trauma who have severe proptosis, diffuse subconjunctival hemorrhage, marked periorbital edema, and visual loss.<sup>10</sup> Vassallo et al.<sup>9</sup> treated a retrobulbar hemorrhage caused by orbital trauma with decompression of the orbital space via lateral canthotomy and cantholysis to prevent acute visual loss.

### Summary

In the case reported here the patient displayed pain, proptosis, periorbital edema, and ecchymosis, and there were no signs of acute visual loss in the primary evaluation and during the follow-up period. The conservative treatment performed was sufficient to preserve the vision of the patient.

## References

1. Hislop WS, Dutton GN, Douglas PS. Treatment of retrobulbar hemorrhage in accident and emergency departments. *British J Oral Maxillofac Surg* 1996; 34: 289-292.
2. Li KK, Meara JG, Joseph MP. Reversal of blindness after facial fracture repaired by prompt optic nerve decompression. *J Oral Maxillofac Surg* 1997; 55: 648-650.
3. Ord RA. Post-operative retrobulbar hemorrhage and blindness complicating trauma surgery. *Br J Oral Surg* 1981; 19: 202-207.
4. Ghufoor K, Sandhu G, Sutcliffe J. Delayed onset of retrobulbar hemorrhage following severe head injury: a case report and review. *Injury* 1998; 29(2): 139-141.
5. Fong KC, Kinnear PE. Retrobulbar haemorrhage associated with chronic Ginko biloba ingestion. *Postgrad Med J* 2003; 79 (935):531-2.
6. Rohrich RJ, Coberly DM, Fagien S, Stuzin JM. Current concepts in aesthetic upper blepharoplasty. *Plast Reconstr Surg* 2004; 113:32e-42e.
7. Rosdeutscher JD, Stadelmann WK. Diagnosis and treatment of retrobulbar hematoma resulting from blunt periorbital trauma. *Ann Plast Surg* 1998; 41: 618-622.
8. Hatton MP, Thakker MM, Ray S. Orbital and adnexal trauma associated with open-globe injuries. *Ophthal Plast Reconstr Surg* 2002; 18(6): 458-461.
9. Vassallo S, Hartstein M, Howard D, Stetz J. Traumatic retrobulbar hemorrhage: emergent decompression by lateral canthotomy and cantholysis. *J Emerg Med* 2002; 22 (3): 251-256.
10. Yip CC, McCulley TJ, Kersten RC, Kulwin DR. Proptosis after hair pulling. *Ophtal Plast Reconstr Surg* 2003; 19(2):154-5.
11. Katz B, Herschler J, Brick DC. Orbital hemorrhage and prolonged blindness: a treatable posterior optic neuropathy. *Br J Ophthalmol* 1983; 67: 549-53.

## About the Authors

### R. A. Machado DDS, MS, PhD student



Dr. Machado is a PhD student in the Oral and Maxillofacial surgery post graduation program of the School of Dentistry at Pontifícia Universidade Católica do Rio Grande do Sul in Porto Alegre, RS, Brazil.

### R. Lanes Silveira DDS, MS, PhD student



Dr. Silveira is a PhD student in the Oral and Maxillofacial surgery post graduation program of the School of Dentistry at the Pontifícia Universidade Católica do Rio Grande do Sul in Porto Alegre, RS, Brazil.

H.O.I.Borges DDS, MS, PhD student



Dr. Borges is a PhD student in the Oral and Maxillofacial surgery post graduation program of the School of Dentistry at the Pontifícia Universidade Católica do Rio Grande do Sul in Porto Alegre, RS, Brazil. He is also a Oral Surgery Professor in the graduation program of School of Dentistry at Uningá, in Maringá, state of Paraná, Brazil.

A.M.Bourguignon Filho DDS, MS



Dr. Bourguignon Filho is a Master in Oral and Maxillofacial Surgery graduated at Pontifícia Universidade Católica do Rio Grande do Sul in Porto Alegre, RS, Brazil

M. Gerhardt de Oliveira, DDS, PhD



Dr. de Oliveira is a Head Professor of graduation and post graduation programs of School of Dentistry at Pontifícia Universidade Católica do Rio Grande do Sul in Porto Alegre, RS, Brazil.

e-mail: [mogerhardt@pucrs.br](mailto:mogerhardt@pucrs.br)