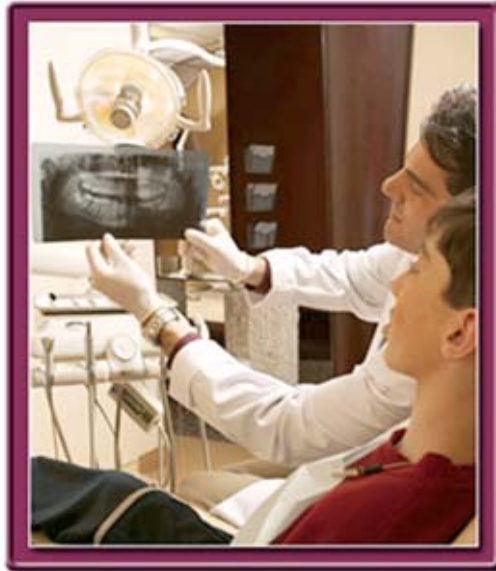


## Traumatic Pseudolipoma of the Oral Cavity: Report of a Case

Marina de Oliveira Ribas, PhD, DDS, OMFS;  
Wilson Denis Martins, PhD, DDS, OMFS;  
Maria Helena de Sousa, MsC, DDS; Ana Maria Braga, MsC, DDS



### Abstract

An uncommon traumatic pseudolipoma of the oral cavity is presented. In this particular case there was evidence of previous trauma to the buccal fat pad during a difficult extraction of a maxillary premolar. Evidence is presented that iatrogenic trauma resulting in foreign body introduction might produce traumatic pseudolipoma in the oral cavity. The morphology of the buccal fat pad, the possible pathogenesis of the condition, as well as the diagnostic and the management of the case are presented.

**Keywords:** Traumatic pseudolipoma, buccal fat pad, trauma

**Citation:** de Oliveira Ribas M, Martins WD, de Sousa MH, Braga AM. Traumatic Pseudolipoma of the Oral Cavity: Report of a Case. J Contemp Dent Pract 2006 September;(7)4:089-097.

© Seer Publishing

## Introduction

The term *traumatic pseudolipoma* was proposed by Brooke and MacGregor<sup>1</sup> in their report of the occurrence of a traumatic lesion in a child that had fallen and suffered blunt facial trauma. Subsequently, she developed a swelling on the buccal mucosa. The lesion was excised and consisted of adipose tissue. Several reports of similar cases, all subsequent to trauma, gave evidence for the acceptance of the term *traumatic pseudolipoma*.<sup>2-8</sup> Most cases occur in infants or young children subsequent to a fall causing penetrating or blunt trauma to the mouth. Young children have a relatively large buccal fat pad, an anatomical condition that is considered to be a factor in these injuries.<sup>9</sup> In adults a post-traumatic herniation of the buccal fat pad into the maxillary sinus associated with a maxillary fracture has been reported.<sup>10</sup>

The lesion is not restricted to the maxillofacial complex. Traumatic pseudolipomas arising in other sites were reported.<sup>11-15</sup> A series of 12 cases of "battered buttock syndrome - fat fractures" was presented.<sup>11</sup> The authors discuss the possible cause of these lipomas, suggesting the body fat is contained under pressure by fibrous capsules and septa. After sudden blunt force trauma, the fat compartment opens producing the traumatic lipoma.

The buccal fat pad is surrounded by a thin but distinctive connective tissue capsule.<sup>16</sup> In cases of penetrating trauma to the cheek the mechanism of injury is different. When the capsule ruptures, the fatty tissue herniates to the oral cavity. Penetration of a foreign body can also penetrate into the fatty tissue. Both scenarios can occur concomitantly.

To our knowledge, this is the first case of a traumatic pseudolipoma concomitant with an odontogenic cyst. Evidence is presented that iatrogenic trauma resulting in foreign body introduction might produce traumatic pseudolipoma in the oral cavity.

## Report of a Case

### Clinical and Radiographic Findings

A 25-year-old woman presented for treatment to the Stomatology and Maxillofacial Surgery clinics at the Pontifical Catholic University of

Paraná, Curitiba, Brazil. She complained of recurrent swelling and pain in the premolar region of the left cheek. The patient reported a history of a difficult extraction of the maxillary left first premolar eight months previously. At the time of the surgery, she was not adequately informed by her clinician regarding the possible risk of displaced root fragments but she had the feeling that "something was wrong." Clinical examination revealed a tumor located into the cheek beneath the zygomatic process of the left maxilla. The tumor was approximately 2 cm long, firm, sessile, and non-ulcerated. The color and consistency of the mucosa was normal.

A panoramic radiograph revealed an empty alveolus of the maxillary first premolar; an endodontically treated second bicuspid; a mesioclusal cavity in the first molar; absence of the second molar; an erupted third molar; and a radiopaque image over the roots of the second bicuspid in the left maxilla. This radiopaque image was consistent with a root fragment (Figure 1).

An orthoradial periapical projection showed details of the root fragment of the missing first bicuspid, superior to the image of the second bicuspid (Figure 2). A distoradial periapical projection disclosed an inverted root fragment (Figure 3) suggestive of an extra-osseous buccal location. A provisional diagnosis of foreign body in the soft tissues was based on these findings.

### Treatment

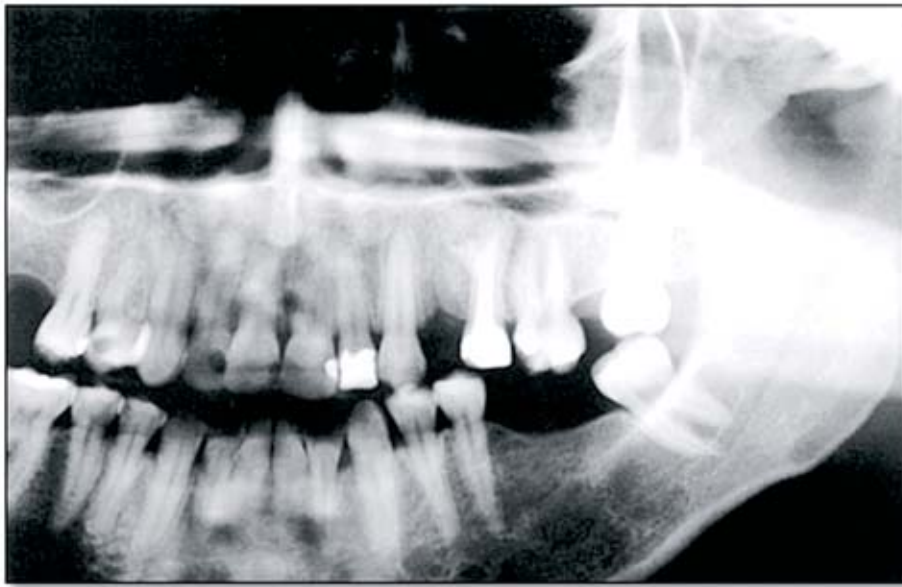
With the patient under local anesthesia, a yellow encapsulated tumor was enucleated (Figures 4 and 5).

The displaced tooth root was found externally to the cortical bone and periosteum, between the tumor and the bone surface (Figure 6). Healing was normal and there has been no evidence of recurrence after two years.

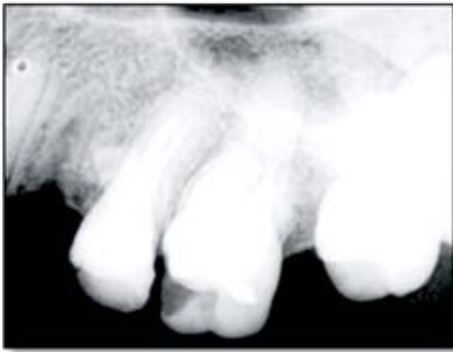### Pathology

The specimen consisted of a soft tumor, 3 cm diameter at its largest dimension. The cut surface revealed a yellow, greasy, and homogeneous substance.

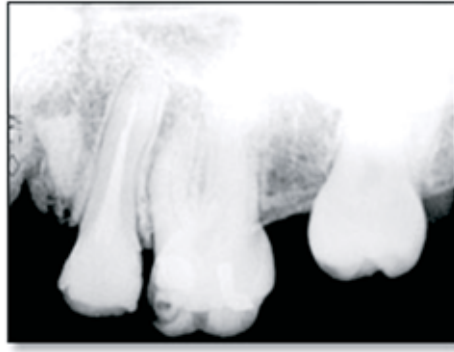
The wall of the cyst consisted of dense fibrous connective tissue with inflammatory infiltrate



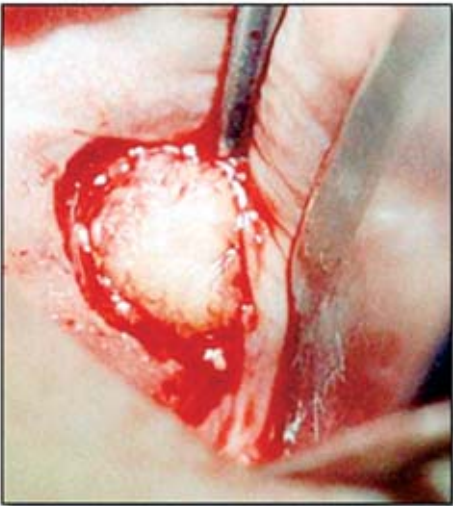**Figure 1.** Panoramic radiograph showing the patient's left side.



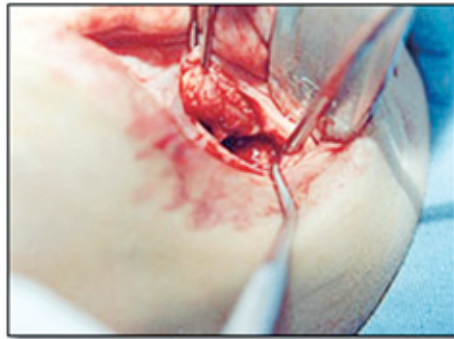
**Figure 2.** Orthoradial periapical radiograph.



**Figure 3.** Distoradial periapical radiograph.

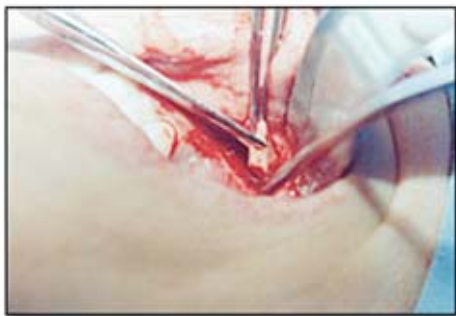

**Figure 4.** Surgical exposure of a yellow mass.

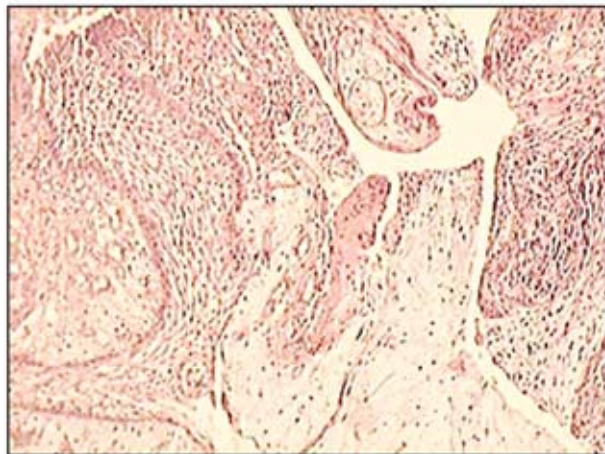


**Figure 5.** Enucleation of the yellow mass.

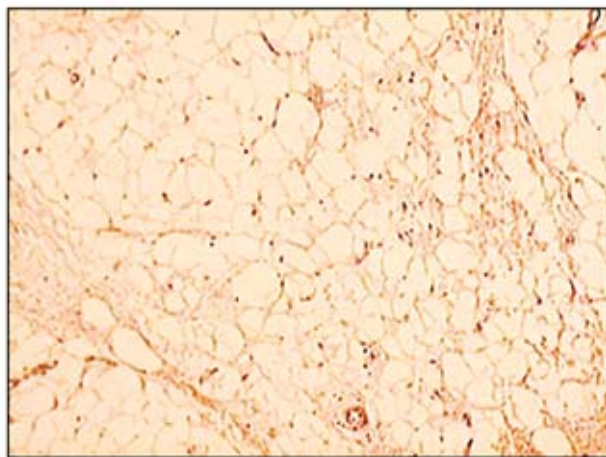
containing lymphocytes, macrophages, plasmocytes, and some neutrophils. The cyst lesion was lined by stratified squamous epithelium demonstrating spongiosis and



**Figure 6.** Removal of the displaced root fragment.



**Figure 7.** Cystic wall, showing spongiosis and exocytosis, surrounded by estratified epithelium. (HE 40 X)



**Figure 8.** Great number of fat cells surrounding the cystic lesion. (HE 40 X)

exocytosis. Many fat cells, some skeletal muscle tissue, and sparse nerve fibers were observed around the cystic lesion (Figures 7 and 8).

### Discussion

The buccal fat pad is an encapsulated mass of adipose tissue located between the buccinator and masseter muscles. Anteriorly, it extends mesial to the masseter muscle. It was suggested this pad of fat may be a possible source of confusion in the diagnosis of lipoma.<sup>16</sup> It was described firstly by Bichat, in 1802, as been truly fatty in nature; in non-English speaking countries it is commonly referred as the *Bichat's ball*.<sup>9</sup>

As the anterior part of the buccal fat pad protrudes in front of the anterior border of the masseter, it is assumed rupture of the capsule occurred during the upper bicuspid extraction and the dental root was pushed into the adipose tissue. The existing periapical cyst was displaced along with the tooth.

The origin of these tumors, whether hamartomas or neoplasms, is subject to question as is aberrant tissue growth in general. This is not to suggest this deformity is an aberration of growth at the genetic level. The difficulty in distinguishing between true benign fatty tumors of the mouth (lipomas) and the hamartoma of fatty tissue was pointed out.<sup>17</sup> Local inflammation secondary to fat necrosis may affect adipocytes and promote new formation of lipoma.<sup>17</sup> One of the factors mentioned with some reservation is physical trauma.<sup>18</sup>

Some speculate traumas that serve as a cause of fat necrosis may trigger the formation of lipomas.<sup>8</sup>

### Summary

This case presents dramatic evidence of how trauma might produce an appearance similar to lipoma, lending additional credence to the traumatic pseudolipoma hypothesis, as suggested by Brooke and MacGregor.<sup>1</sup> The clinical aspect of the lesion is related to the time of occurrence of the trauma.

More recent lesions present yellowish, red, or bluish masses.<sup>2,3,5,6</sup> Older lesions, as in the present case, may present as a tumoral mass recovered by normal epithelium.

## References

1. Brooke RI, MacGregor AJ. Traumatic pseudolipoma of the buccal mucosa. *Oral Surg* 1969;28: 223-225.
2. Clawson RJ, Kline KK, Armbrecht EC. Trauma-induced avulsion of the buccal fat pad into the mouth. *J Oral Surg* 1968;26:546-547.
3. Browne WG. Herniation of buccal fat pad. *Oral Surg* 1970;29:181-183.
4. Cavina RA. Herniation of buccal fat pad. *Br Dent J* 1972;132:272.
5. Messenger KL, Cloyd W. Traumatic herniation of buccal fat pad. *Oral Surg* 1977;43:41-43.
6. Wolford DG, Stapleford RG, Forte RA, Heath M. Traumatic herniation of the buccal fat pad: report of case. *J Am Dent Assoc* 1981;103:593.
7. Judah MW, Bach DE. Buccal fat pad herniation in an infant. *Gen Dent* 1984;32:300.
8. Berk CW, Gibson WS Jr. Pathologic quiz case 1. Traumatic herniated gangrenous buccal fat pad (traumatic pseudolipoma). *Arch Otolaryngol Head Neck Surg* 1994;120:340-342.
9. Dubin B, Jackson IT, Halim A, Triplett WW, Ferreira M. Anatomy of the buccal fat pad and its clinical significance. *Plast Reconstr Surg* 1989;83:257-264.
10. Marano PD, Smart EA, Kolodny SC. Traumatic herniation of buccal fat pad into maxillary sinus:report of case. *J Oral Surg* 1970;28:531.
11. Meggit BF, Wilson JN. The battered buttock syndrome - fat fractures: a report on a group of traumatic lipomata. *Br J Surg* 1972;59:165-169.
12. Herbert DC, DeGeus J. Post-traumatic lipomas of the abdominal wall. *Br J Plast Surg* 1975;28: 303-306.
13. Rozner L, Isaacs GW. The traumatic pseudolipoma. *Aust N Z J Surg* 1977;47:779-782.
14. David LR, DeFranzo A, Marks M, Argenta LC. Posttraumatic pseudolipoma. *J Trauma* 1996;40: 396-400.
15. Copcu E, Sivrioglu NS. Posttraumatic lipoma: analysis of 10 cases and explanation of possible mechanisms. *Dermatol Surg* 2003;29:215-220.
16. DuBrul EI. *Sicher's Oral Anatomy*, 7th Ed. St. Louis: Mosby, 1980. p. 213.
17. Copcu E, Sivrioglu NS. Posttraumatic lipoma: analysis of 10 cases and explanation of possible mechanisms. *Dermatol Surg* 2003;29:215-220.
18. Willis RA. *Pathology of Tumours*, ed. 4, London: Butterworth, p.672.

## About the Authors

**Marina de Oliveira Ribas, PhD, DDS, OMFS**



Dr. de Oliveira Ribas is a Professor of Oral and Maxillofacial Surgery and Stomatology at the Pontifical Catholic University of Paraná in Curitiba, Brazil.

**Wilson Denis Martins, PhD, DDS, OMFS**



Dr. Martins is an Oral and Maxillofacial Surgeon and a Professor of Stomatology at the Pontifical University of Paraná (PUCPR) in Curitiba, Brazil.

e-mail: [w.denis@pucpr.br](mailto:w.denis@pucpr.br)

**Maria Helena de Sousa, MsC, DDS**



Dr. de Sousa, DDS, MsC is a Clinical Professor and Specialist in Stomatology, Pontifical Catholic University of Paraná in Curitiba, Brazil.

**Ana Maria Braga, MsC, DDS**



Dr. Braga is a Clinical Professor and Specialist in Stomatology at the Pontifical Catholic University of Paraná in Curitiba, Brazil.