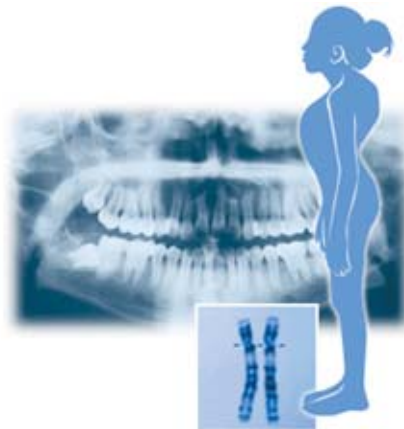


Giant Cell Lesions with a Noonan-like Phenotype: A Case Report

Claudia Marcela H. Cancino, DDS, MSc, PhD;
Léonilson Gaião, DDS, MSc;
Manoel Sant'Ana Filho, DDS, MSc, PhD;
Flavio Augusto Marslaj Oliveira, DDS, MSc, PhD



Abstract

Aim: The purpose of this article is to describe a case of multiple giant cell lesions of the mandible that occurred in a 14-year-old girl with phenotypic characteristics associated with Noonan Syndrome (NS).

Background: NS is a dysmorphic disorder characterized by hypertelorism, short stature, congenital heart defects, short and webbed neck, skeletal anomalies, and bleeding diathesis.

Report: A 14-year-old girl with a previous diagnosis of NS (sporadic case) presented with multiple radiolucent lesions in the body and ramus of her mandible.

Summary: In terms of clinical behavior and the described radiographic characteristics, giant cells lesions with Noonan-like phenotype can be considered a form of cherubism. Therefore, surgical intervention is not necessary, but radiographic follow-up and observation is very important during the control and gradual regression of the lesions.

Keywords: Noonan Syndrome, NS, giant cell lesions

Citation: Cancino CMH, Gaião L, Sant'Ana Filho M, Oliveira FAM. Giant Cell Lesions with a Noonan-like Phenotype: A Case Report. J Contemp Dent Pract 2007 May;(8)4:067-073.

© Seer Publishing

Introduction

Noonan Syndrome (NS) is a dysmorphic disorder described by Noonan and Ehmke in 1963⁸ when they reported nine cases of children who presented with the following characteristics: hypertelorism, webbed neck, eyelid ptosis, pulmonary stenosis, and multiple cardiovascular and skeleton malformations.¹⁻³

This is a condition of dominant autosomal character, but it is considered to have varied expression in which there are reports of sporadic cases. The incidence rate varies from 1:1000 to 1:2500 among live births with no preference for gender. The responsible gene for NS was mapped out in the long arm of chromosome 12.⁴⁻⁶

The diagnosis of NS is made by observations of the previously mentioned physical characteristics, being confirmed by the echocardiogram (abnormal in 50-80% of cases), pulmonary stenosis with or without valvular dysplasia (20-50%), platelet count, coagulation profile, and measurement of coagulation factor XI. Tests of DNA have been applied to verify mutations in the gene Protein-tyrosine phosphatase, non-receptor type 11 (PTPN11) located in the long arm chromosome 12.⁷

Case Reports

A 14-year-old girl with a previous diagnosis of NS (sporadic case) was referred to the Service of Oral and Maxillofacial Surgery and Traumatology of the Pontifical Catholic University of Rio Grande do Sul (PUCRS) by her orthodontist who detected multiple radiolucent lesions in the body and ramus of her mandible.

Diagnosis

Clinically, the patient presented with some physical and skeletal characteristics related with the syndrome such as low stature, short and webbed neck, eyelid ptosis, *pectus carinatum*, hyperkeratosis, mental retardation, vertebral anomalies, and a synovial cyst in her right wrist (Figure 1).

Upon oral examination an Angle Class II malocclusion with dental malpositioning was verified. There were no other signs or symptoms such as facial asymmetry, painful symptomatology, or tumefaction observed.

Panoramic radiographs revealed multiple, ill-defined, radiolucent, multilocular, bilateral images extending over the body and angle of the mandible, however, the mandibular cortical bone was unaffected (Figure 2).

Treatment

Such images had been considered giant cell lesions by observation of clinical and radiographic characteristics. As a result, no surgical intervention was implemented and treatment was limited to radiographic evaluation three times in the first year and then twice yearly in subsequent years (Figure 3).

During that observation period there were no alterations in the clinical behavior of the condition, but a slow regression of the radiographic characteristics was observed indicating and confirming the diagnosis of giant cell lesions (Figure 4).

Discussion

The first case of NS described by Noonan and Ehmke (1963)⁸ did not include lesions of giant cells in its list of characteristics. Later reports on the syndrome associated giant cell lesions with the condition. If the lesions occurred in the mandible, they were called NS associated and were associated with cherubism or with the

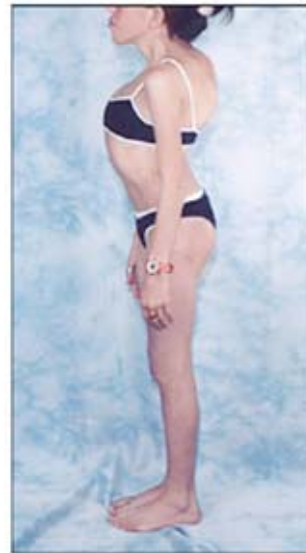

Figure 1. Physical and skeletal characteristics of a 14-year-old girl with a giant cell, Noonan-like phenotype.

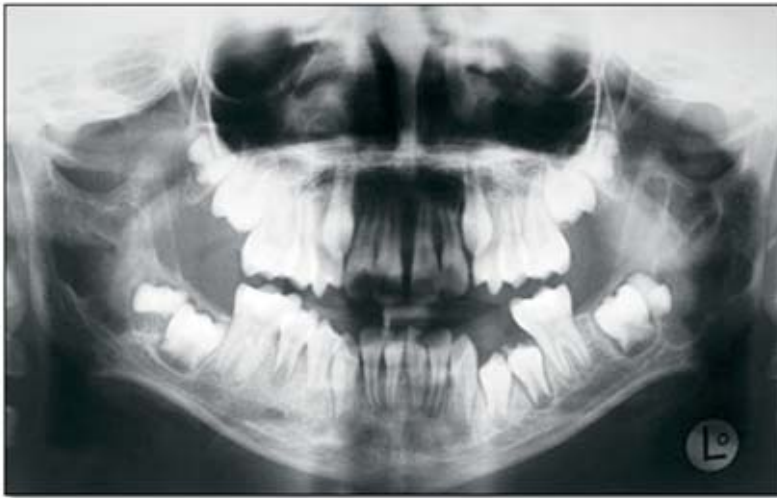


Figure 2. Multiple radiolucent, multilocular, and bilateral giant-cell-like lesions in the body and angle of the mandible.

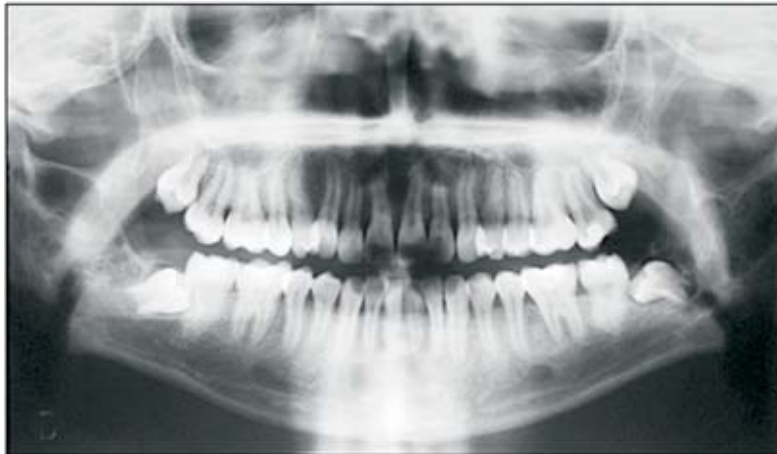

Figure 3. Radiographic follow-up at six years showing a slow regression of the lesions.

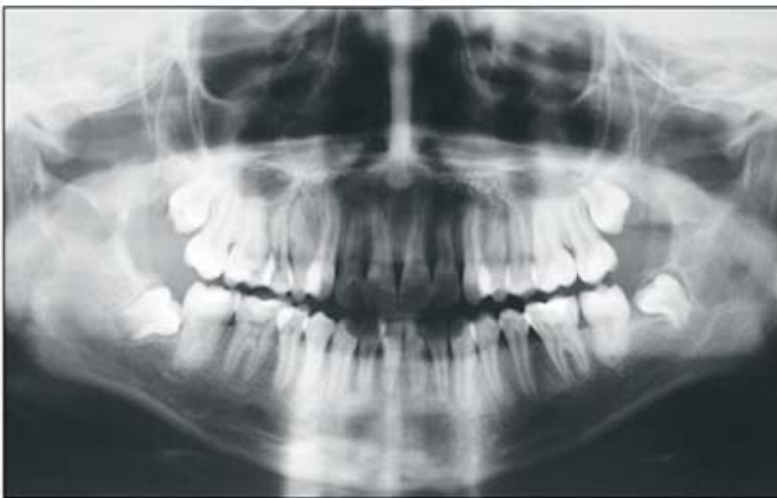

Figure 4. Radiographic follow-up at seven years.

lesions of giant cells. If the temporomandibular joints were compromised, NS was considered associated with pigmented villonodular synovitis.^{9,10}

This condition must be called a syndrome of giant cells with Noonan-like phenotype for the following reasons:⁹

1. The lesions of giant cells can appear in the mandible, the maxilla, or both.
2. When in the temporomandibular joints, they can reach soft tissues and produce alterations in the adjacent bones.
3. Extragnathic lesions are similar to cysts.
4. When in soft tissues, the lesions can compromise synovial regions.

The following characteristics are part of the description of this syndrome: low stature; compromised intellectual performance; hypertelorism; prominent ears which later become implanted; lesions of giant cells in the gnathic bones, joints, and/or soft tissues; *pectus excavatum*; *pectus carinatum*; and pulmonary stenosis with or without valvular dysplasia.⁹ The case related here is compatible with this description⁹ since the patient presented the same phenotype as well as lesions of giant cells in the mandible and in the wrist.

There are some studies that report the occurrence of multiple lesions of giant cells in the mandible associated with the Noonan-like phenotype. In 1986, Choung et al.¹¹ described 17 such cases, among them were two that presented with NS and bilateral lesions in the maxilla and the mandible that were histologically identified as lesions of giant cells. Since these patients also presented with a skeletal extragnathic disturbance the authors had not considered such lesions as cherubism.

Cherubism is a benign condition of autosomal dominant inheritance that affects the maxilla and the mandible. These slow progressing lesions are located in the body and ramus of the mandible

and are bilateral, symmetrical, and asymptomatic. The radiolucid images are multilocular, frequently diagnosed between 14 months and 12-years-of-age. The lesions generally regress after puberty with variable restoration of the facial contour.¹²

In 1989, Dunlap et al.¹² reported four cases which presented the phenotypic characteristics of NS and lesions of giant cells. In the panoramic radiographs taken of all the patients they had observed multiple radiolucid multilocular images, bilaterally located in the body and ramus of the mandible. This was similar to the observations in the case presented in this article and interpreted by these authors as cherubism.

Histologically, cherubism presents innumerable multinucleolus giant cells in the stroma of connective tissue which are identical to lesions of giant cells. Despite the aggressive appearance, surgical intervention is not necessary because the growth of these cells tend to regress.¹³

Bilateral lesions in the mandible with appearance of multiple lesions of giant cells are considered characteristic of cherubism;¹²⁻¹⁴ therefore, the lesions radiographically observed in this related case can be considered a cherubism form. Moreover, this affirmation is supported by the fact extragnathic lesions can also occur in cherubism.^{15,16}

Summary

For the reasons stated previously, no surgical intervention was pursued in this case and treatment was limited to periodic radiographic evaluation which revealed a slow regression of the lesions.

In terms of clinical behavior and the described radiographic characteristics, giant cell lesions with Noonan-like phenotype can be considered a form of cherubism. Therefore, surgical intervention is not necessary, but radiographic follow-up and observation is very important during the control and gradual regression of the lesions.

References

1. Graham JM. Aspects of Noonan Syndrome. Cedars-Sinai Medical Center: Information Sheet. 2002; <http://www.noonansyndrome.org/graham.html>.
2. Noonan JA. Noonan Syndrome revisited. *J Pediatr*. 1999; 135(6): 667-8.
3. Mendez HMM, Opitz JM. Noonan Syndrome: a review. *Am J Med Genet*. 1985; 21: 493-506.
4. Nora JJ, Nora AH, Sinha AK, Spangler RD, Lubs Jr. HA. The Ullrich-Noonan syndrome (Turner Phenotype). *Am J Dis Child*. 1974; 127: 48-55.
5. Jamieson CR, van der Burgt I, Brady AF, van Reen M, Elsawi MM, Hol F, Jeffery S, Patton MA, Mariman E. Mapping a gene for Noonan syndrome to the long arm of chromosome 12. *Nat Genet*. 1994; 8: 357-60.
6. Ibrahim J, McGovern M. Noonan Syndrome. *eMedicine Journal*. 2001; 2 (10): <http://www.emedicine.com/ped/topic1616.htm>.
7. Allanson JE. The first Noonan Syndrome gene: PTPN11, which encodes the protein tyrosine phosphatase SHP-2. *Pediatric Res*. 2002; 52(4): 471.
8. Noonan JA, Ehmke DA. Associated noncardiac malformations in children with congenital heart disease. *J Pediatr*. 1963; 63: 468-70.
9. Cohen MM, Gorlin RJ. Noonan-Like/Multiple giant cell lesion syndrome. *Am J Med Genet*. 1991; 40: 159-66.
10. Wagner ML, Harlan JS, Dutton RV, Glassman AL, Askew JB. Polyarticular pigmented villonodular synovitis. *Am J Roentgenol*. 1981; 136: 821-3.
11. Chuong R, Kaban LB, Kozakevick H, Perez-Atayde A. Central Giant Cell lesions of the jaws: a clinicopathologic study. *J Oral Maxillofac Surg*. 1986; 44: 708-13.
12. Dunlap C, Neville B, Vickers RA, O'Neil D, Barker B. The Noonan syndrome/cherubism association. *Oral Surg Oral Med Oral Pathol*. 1989; 67: 698-705.
13. Levine B, Skope L, Parker R. Cherubism in a patient with Noonan Syndrome: Report of a case. *J Oral Maxillofac Surg*. 1991; 49: 1014-18.
14. Betts NJ, Stewart JCB, Fonseca RJ, Scott RF. Multiple central giant cell lesions with a Noonan-like phenotype. *Oral Surg Oral Med Oral Pathol*. 1993; 76: 601-7.
15. Neville BW, Damm DD, Allen CM, Bouquot, JE. *Patologia oral e maxilofacial*. 2 ed. Guanabara Koogan: Rio de Janeiro; 2004.
16. Wayman JB. Cherubism: a report on three cases. *Br J Oral Surg*. 1978; 16 (1): 47-56.

About the Authors

Claudia Marcela H. Cancino, DDS, MSc, PhD



Dr. Cancino received her Master of Dental Science degree in Oral and Maxillofacial Surgery and a PhD degree from the Pontifical Catholic University of Rio Grande do Sul, Brazil. She is in private practice in Porto Alegre, RS, Brazil. Her research interests include maxillofacial surgery.

e-mail: marcelaforerocancino@hotmail.com

Léonilson Gaião, DDS, MSc



Dr. Gaião is a Doctoral student in the Department of Oral and Maxillofacial Surgery in the School of Dentistry at the Pontifical Catholic University of Rio Grande do Sul, Brazil. His research interests include Maxillofacial Surgery.

Manoel Sant'Ana Filho, DDS, MSc, PhD



Dr. Sant'Ana Filho is a Professor and Chair of the Post Graduation Program in Oral and Maxillofacial Surgery at the Pontifical Catholic University of Rio Grande do Sul, Brazil where he received his Masters in Dental Science in Oral and Maxillofacial Surgery and PhD degrees. He has been involved in research activities focusing on oral and maxillofacial pathology.

Flavio Augusto Marsiaj Oliveira, DDS, MSc, PhD



Dr. Oliveira is a Professor and Chair of the Preventive Dentistry Department at the Pontifical Catholic University of Rio Grande do Sul, Brazil where he received his Master in Dental Science in Stomatology and PhD degrees. He has been involved in research activities focusing on oral pathology and pediatric dentistry.