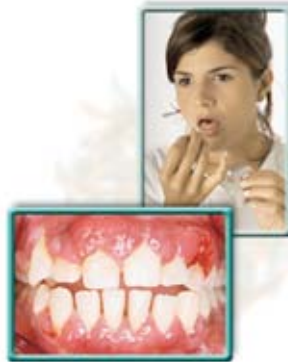

Clinical Management of an Unusual Case of Gingival Enlargement

S. Sumanth, BDS; K. Mahalinga Bhat, B.Sc, MDS;
G. Subraya Bhat, MDS, MFGDP



Abstract

Aim: The purpose of this article is to report a case of conditioned gingival enlargement managed by non-surgical periodontal therapy.

Background: Hormones are specific regulatory molecules that modulate a host of body functions. Hormonal effects reflect physiologic and pathologic changes in almost all tissues of the body with the periodontium being no exception. Physiologic changes like puberty, the menstrual cycle, and pregnancy cause hormonal variations that may cause inflammation of the gingiva. Oral contraceptives that contain estrogen and/or progesterone are associated with gingival enlargement.

Report: A 28-year-old female presented with a complaint of swelling of the gingiva with spontaneous bleeding in the maxillary anterior region for a period of one year. The health history documented the use of contraceptives for one year, and a clinical examination revealed the existence of poor oral hygiene and enlarged painful gingival tissues that bled when touched.

Summary: This case reaffirms the fact plaque control is the most important procedure in any periodontal therapy. Another factor contributing to the excellent response to therapy is patient compliance. The patient followed home care instructions well and was effective in personal oral hygiene measures.

Keywords: Gingival enlargement, sex hormones, oral contraceptives

Citation: Sumanth S, Bhat KM, Bhat GS. Clinical Management of an Unusual Case of Gingival Enlargement. J Contemp Dent Pract 2007 May;(8)4:088-094.

Introduction

Bacterial plaque has been established as the primary etiological factor for the initiation of periodontal diseases.¹ However, periodontal pathogens are not sufficient for the disease to occur without a susceptible host. Sex hormones are important modifying factors that may influence the pathogenesis of periodontal diseases.² Recent classification of periodontal diseases has included puberty-associated gingivitis, menstrual cycle-associated gingivitis, pregnancy-associated gingivitis, and oral contraceptive-associated gingivitis.³ Thus, there is a recognized association between sex hormonal level changes and periodontal conditions.

Case Report

Diagnosis

A 28-year-old female was referred to the Department of Periodontics from the Department of Oral Medicine and Radiology at Manipal College of Dental Sciences in Karnataka, India. The patient presented with a complaint of swelling of the gingiva with spontaneous bleeding in the maxillary anterior region for a period of one year. It started as an enlargement in the interdental areas and gradually covered the entire maxillary anterior region.

The patient had not visited a dentist during the past three years. She brushed her teeth twice daily but had reduced the frequency of brushing in the upper anterior region during the last year due to pain and bleeding upon brushing. Following the application of a disclosing solution, large amounts of plaque accumulation was observed (Figure 1).

A detailed family history was obtained and was not contributory. The patient had no systemic

problems that could have contributed to the gingival enlargement.

A drug history revealed the patient was not on any medication such as phenytoin, cyclosporine, or nifedipine that could have induced gingival enlargement. However, the patient revealed she had been taking oral contraceptives but had stopped four months earlier. The patient previously took a 21-tablet packet monthly, one tablet each day for 21 days and none for the next seven days. She continued this regimen for a period of one year. The drug taken was a combination of progestrogen and oestrogen (Levonorgestrel 0.25 mg, Ethinyl estradiol 0.05 mg). Gingival bleeding on brushing started within two months, and she reported her gingiva enlarged at around three months after starting the medication.

A gingival examination was completed. A diffuse gingival enlargement covering most of the anterior segment involving the interdental, marginal, and attached gingiva was observed. The gingiva appeared bright red, friable, and edematous with a shiny surface. Gingival bleeding occurred on slightest provocation. Clefting of the gingiva was seen between the upper right central and lateral incisors (Figure 2).

The upper right canine was mobile (Grade 2), and the upper right lateral incisor was also mobile (Grade 1). Attachment loss of ≥ 5 mm was seen in relation to the upper anterior teeth. Pocket probing depth was ≥ 7 mm in relation to the upper anterior teeth.

Intraoral periapical radiographs showed a combination of horizontal and vertical bone loss (Figure 3).

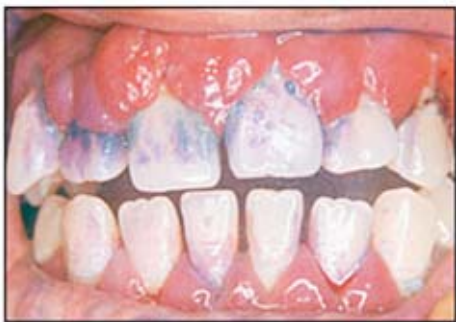

Figure 1. Anterior view following application of plaque disclosing dye.

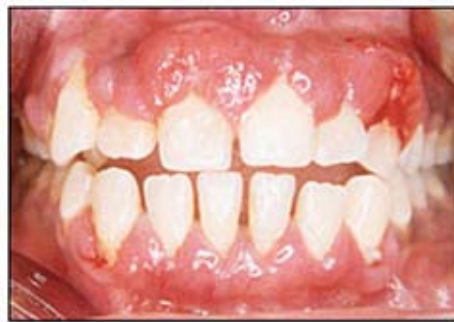

Figure 2. Anterior view at the second examination.

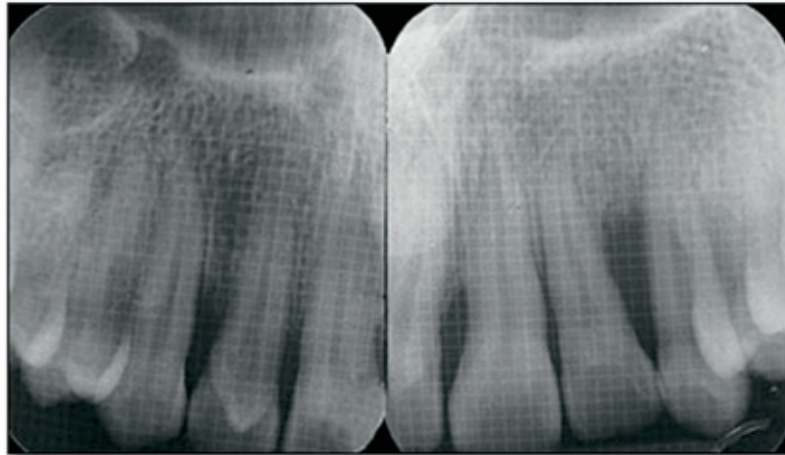


Figure 3. Periapical radiographs showing vertical and horizontal bone loss.

Laboratory investigations did not reveal any abnormalities. Histological examination was not done as the patient responded to mechanical therapy. Excisional biopsy was indicated but was not conducted as the conditions were resolving nicely with ideal oral hygiene. Epulis and pyogenic granuloma were ruled out as they are localized enlargements. Leukemic gingival enlargement was ruled out as the hemogram failed to indicate any abnormalities. Based on the clinical picture and the case history, a provisional diagnosis of “conditioned gingival enlargement” was made.

Treatment

A clinical decision was made to institute a proper oral hygiene program for the patient as the first phase of treatment. The patient was advised to disclose the area and use an ultra-soft toothbrush with a proper brushing method that was explained and demonstrated. The patient was required to brush in the clinical setting under supervision. The patient was advised to perform warm saline rinses 3-4 times a day and 0.2% chlorhexidine mouthwash was prescribed for use twice daily.

The patient was recalled periodically for evaluation, and the findings were as follows:

One Week: Brushing method was evaluated during this visit. The patient was following the given instructions. The patient was appointed for a recall examination in one month.

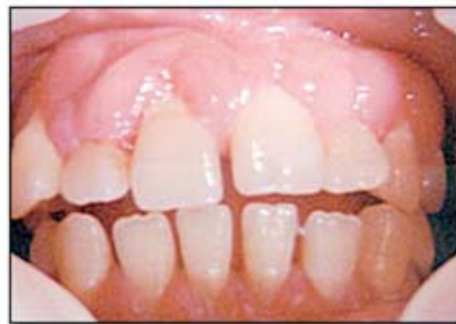

Figure 4. Anterior view at the recall one month examination.

One Month: Gingival examination revealed the condition had improved. Compared to the initial visit, the gingival size was reduced and the gingiva had become firm. An oral prophylaxis consisting of a professional dental cleaning along with supragingival scaling was also carried out to remove calculus and debris. Oral hygiene instructions were reinforced, and the patient was appointed for a recall examination in one month (Figure 4).

Two Months: Gingival condition had not improved compared to the previous visit. It was decided to wait for one more month before any surgical procedure was carried out. Subgingival scaling and root planing was repeated.

Three Months: Overall the gingiva appeared firm and healthy, and the size had regressed significantly from the

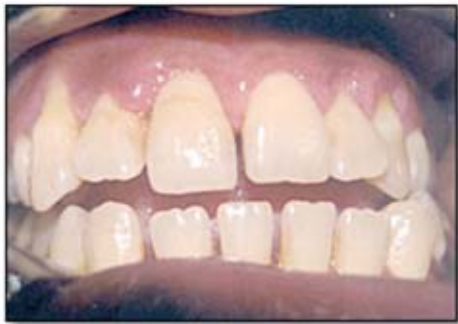

Figure 5. Anterior view at the three month examination.

previous visit. The interdental papillae were mildly inflamed. The mobility in the upper right canine had reduced to Grade 1, and the upper right lateral incisor had become firm. The patient revealed she no longer experienced discomfort when brushing and gingival bleeding had completely stopped. The patient was advised to continue the maintenance regimen and to report for another examination in two months (Figure 5).

Five Months: The gingiva appeared healthy apart from mild inflammation of the papillae. The patient did not have any discomfort when brushing. The patient was also advised to return to the clinic every three months for a period of one year for follow up (Figure 6).

Discussion

Systemic medications are the most common causes of gingival enlargement. Phenytoin, cyclosporine, and nifedipine have been shown to cause disfiguring enlargement of the gingiva. Oral contraceptives have also been shown to cause gingival enlargement.^{4,6} It is well documented sex hormones may alter the female's periodontium and reduce resistance to dental plaque. Oral contraceptives act by elevating the hormonal levels to simulate pregnancy and prevent ovulation, but oral contraceptives containing both estrogen and progesterone are more likely to cause gingival enlargement than individual hormones alone.⁷

Both estrogen and progesterone used in oral contraceptives are known to cause increased gingival exudate, edema, and inflammation.² It has been shown women who take oral

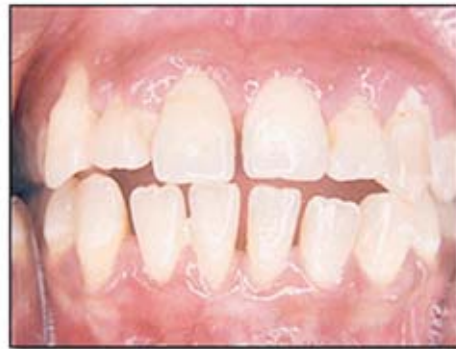


Figure 6. Anterior view at five month visit showing less plaque accumulation and healthier gingival tissues.

contraceptives exhibit greater periodontal destruction than a control group of comparable age and oral hygiene.⁶ A recent Sri Lankan study confirms these findings in which levels of gingivitis and periodontal breakdown were significantly higher in contraceptive users when compared to non users.⁸

The resultant gingivitis in oral contraceptive users can be minimized by establishing low plaque levels during or at the beginning of the therapy.⁹ In this patient optimal oral hygiene was not observed as the patient had not visited a dentist for three years. This may have been the reason for the initiation of gingivitis after oral contraceptives were started. Gradually, as the gingiva enlarged, the patient reduced the frequency of oral hygiene measures in the affected region due to pain on touching and gingival bleeding. This led to more plaque accumulation and may have had a role in the development of gingivitis which then progressed to periodontitis.

It is generally accepted once the patient discontinues the oral contraceptive the gingival condition will be reversed. This situation was not seen in our patient. The enlargement persisted even after discontinuation of the contraceptive. This can be attributed to two reasons. First, the amount of plaque and calculus that was present interfered with the reparative process, thus, preventing the gingiva from returning to normal. Second, it has been reported the hormonal changes induced by oral contraceptives are not immediately reversible after discontinuation of their use. In one study the levels of sex hormone-binding globulin remained elevated for up to one year in oral contraceptive users.¹⁰

It is remarkable the enlarged gingiva returned to normal with routine non-surgical periodontal therapy. Plaque control measures instituted along with mechanical instrumentation reduced the amounts of plaque and calculus. Once the local irritating factors were eliminated, the gingiva began responding to therapy.

Summary

This case reaffirms the fact plaque control is the most important procedure in any periodontal therapy. Another factor contributing

to the excellent response to therapy is patient compliance. The patient followed home care instructions well and was effective in personal oral hygiene measures.

Proper diagnosis, professional intervention, and patient compliance have resulted in the complete remission of the gingival disease. Even though the clinical picture during the initial examination raised the possibility of surgical periodontal treatment, the clinical problems were resolved with a non-surgical approach.

References

1. Loe H, Theilade E, Jensen B. Experimental gingivitis in man. *J Periodontol* 1965; 36: 177-187.
2. Mariotti A. Sex steroid hormones and cell dynamics in the periodontium. *Crit Rev Oral Biol Med* 1994; 5: 27-53.
3. Armitage GC. Development of classification system for periodontal diseases and conditions. *Ann Periodontol* 1999; 4: 1-6.
4. Lindhe J, Bjorn AL. Influence of hormonal contraceptives on the gingiva of women. *J Periodont Res* 1967; 2: 1-6.
5. Lynn BD. The "pill" as an etiologic agent in hypertrophic gingivitis. *Oral Surg Oral Med Oral Pathol* 1967; 24: 333-334.
6. Knight GM, Wade AB. The effects of hormonal contraceptives on the human periodontium. *J Periodontol* 1974; 9: 18-22.
7. Soory M. Hormonal factors in periodontal disease. *Dent Update* 2000; 27: 380-383.
8. Tilakaratne A, Soory M, Ranasinghe AW, Corea SMX, Ekanayake SL, De Silva M. Effects of hormonal contraceptives on the periodontium in a population of rural Sri-Lankan women. *J Clin Periodontol* 2000; 27: 753-757.
9. Mascarenhas P, Gapski R, Al-Shammari K, Wang HL. Influence of sex hormones on the periodontium. *J Clin Periodontol* 2003; 30: 671-681.
10. American Association of Clinical Endocrinologists. Androgen insufficiency and oral contraceptives: A Pathophysiologic mechanism. *AACE* 2005: 728.

About the Authors

S. Sumanth, BDS



Dr. Sumanth is a postgraduate student in the Department of Periodontics of the Manipal College of Dental Sciences in Manipal, Karnataka, India.

e-mail: drsumanths@gmail.com

K. Mahalinga Bhat, B.Sc, MDS



Dr. Bhat is a Professor and Head of the Department of Periodontics, Manipal College of Dental Sciences in Manipal, Karnataka, India.

e-mail: kmbhatcods@yahoo.com

G. Subraya Bhat, MDS, MFGDP



Dr. Bhat is a Professor in the Department of Periodontics of the Manipal College of Dental Sciences in Manipal, Karnataka, India.

e-mail: subraya68@yahoo.com