

## Oral Paracoccidioidomycosis: A Case without Lung Manifestations

Miguel Gustavo Setúbal Andrade, MD, DS;  
Alena Peixoto Medrado, MS, DS; Igor Costa de Brito, BS;  
Sílvia Regina de Almeida Reis, MD, DDS, PhD



### Abstract

**Aim:** The aim of this article is to present a case of Paracoccidioidomycosis with involvement of the oral cavity but without pulmonary manifestations.

**Background:** Paracoccidioidomycosis is a fungal infection caused by *Paracoccidioides brasiliensis*. It is an endemic disease representing a serious health problem for Latin American countries, especially Brazil. This infection primarily affects the lungs of adult men and is acquired through inhalation or accidental inoculation of the fungus. It can spread to other organs and tissues, mainly the oral cavity. Administration of antifungal medication always resolves the disease.

**Report:** A 58-year-old black male presented with three painless, ulcerated, mulberry-like granulomatous lesions located in the floor of the mouth, on the superior alveolar ridge, and on the hard palate, which had evolved over a period of two years. Facial asymmetry was observed due to edema in the lower lip and lymphadenopathy. He had smoked for more than six years but showed no evidence of lung alterations, productive cough, or fever. Panoramic radiography showed no signs of a bone lesion in the jaws. Both a radiograph and a CT scan of the thorax showed no areas of nodular infiltration. Fibrobronchoscopic examination of the entire respiratory tract was normal. Biopsies of the oral lesions were performed, and tissue sections exhibited oral mucosa coated with non-keratinized stratified squamous epithelium with acanthosis and focal areas of exocytosis. The underlying connective tissue showed an intense lymphocytic

© Seer Publishing

and polymorphonuclear infiltrate in addition to multinuclear giant cells and coagulation necrosis. A special stain used for fungus (the Grocott-Gomori method) was positive. Pulmonary biopsy exhibited aerial spaces containing macrophages, dark granular hemosiderin, and absence of fungus. This was considered normal. In agreement with the recommendation of pneumologists 400 mg/day of ketoconazole was prescribed for the patient. After two months of treatment, even though the oral lesions had resolved completely, the therapy was maintained for six months more. One year after following treatment the patient was in good health and free of any signs of a recurrent infection.

**Summary:** Based on clinical, radiographic, and histologic findings the differential diagnosis included paracoccidioidomycosis and squamous cell carcinoma. Following clinical and biopsy examinations of the oral lesions and the lungs a final diagnosis of paracoccidioidomycosis was made. This is a prime example of oral manifestations of a systemic disease in which the dentist is the initial health care professional to evaluate the patient due to the location of the lesions.

**Keywords:** Paracoccidioidomycosis, *Paracoccidioides brasiliensis*, mycosis, oral mycosis

**Citation:** Andrade MGS, Medrado AP, de Brito IC, de Almeida Reis SR. Oral Paracoccidioidomycosis: A Case without Lung Manifestations. J Contemp Dent Pract 2007 July;(8)5:092-098.

## Introduction

Paracoccidioidomycosis is a deep granulomatous systemic mycosis, whose etiological agent is a dimorphic fungus denominated *Paracoccidioides brasiliensis*.<sup>1-3</sup> The main antigen of this fungus is glycoprotein 43 (gp43)<sup>1,2</sup> and the immunologic response is primarily cellular.<sup>4,5</sup> Macrophages are responsible for primary cellular mechanisms that can prevent parasitic invasion of host tissues.<sup>6</sup> The lung is the primary site of infection, and the fungus is able to disseminate to many organs, spawning secondary lesions that frequently occur in mucous membranes, lymph nodes, and skin.<sup>3</sup> However, these sites can be affected without any previous lung infection. In such cases it has been postulated *Paracoccidioides brasiliensis* was inoculated directly into tissue. Oral infection exhibits ulcers with a granular appearance similar to the surface of a mulberry.<sup>7</sup> The main symptoms associated with oral infection are itching, pain, and burning.<sup>3</sup> Cervical lymphadenopathy is also reported. The present work reports a case of paracoccidioidomycosis in the oral cavity with no evidence of lung involvement.

## Case Report

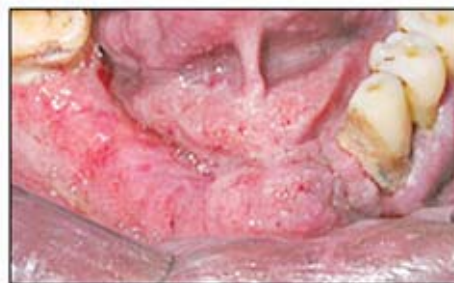### Diagnosis

A 58-year-old black male presented for care at the Oral Medicine Service of the Dental School at the Foundation for the Development of Science.

He complained of diffuse lesions in the oral cavity that had evolved over a period of two years. The man had been a resident in Salvador, Bahia, Brazil for over 20 years.

During anamnesis, the patient denied painful symptoms and revealed he had been a smoker for more than six years. No lung alterations, productive cough, or fever were observed. During the extraoral examination some facial asymmetry was observed as a result of edema in the lower lip and lymphadenopathy.

Upon intraoral examination three ulcerated, mulberry-like granulomatous lesions were found. The largest lesion was in the floor of the mouth and extended onto the inferior alveolar edge and to the inferior oral vestibule (Figure 1).



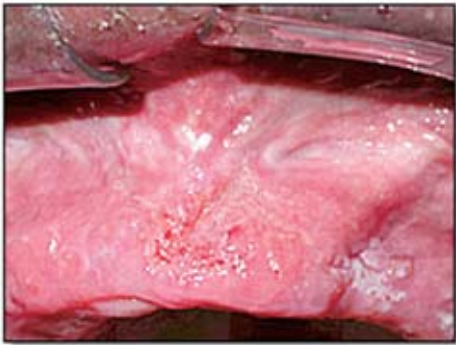**Figure 1.** Lesion in the floor of the mouth extending toward the inferior alveolar ridge and buccal vestibule.

The other lesions were on the superior alveolar edge and hard palate, respectively (Figures 2 and 3). In addition, there was evidence of poor oral hygiene. The diagnostic hypotheses were paracoccidioidomycosis and squamous cell carcinoma.

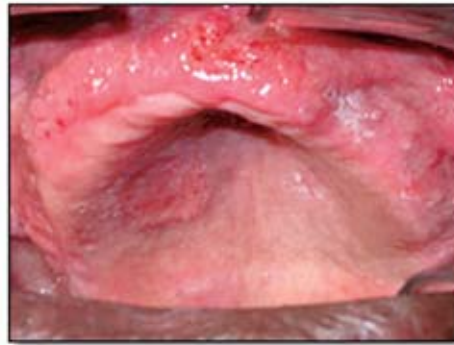A panoramic radiograph showed no signs of bone lesions in the jaws, and a radiograph of the thorax showed no areas of nodular infiltration. This was confirmed using computerized tomography (Figures 4 and 5). An anti-HIV serology and

Mantoux reaction were requested to evaluate the presence of co-infections but both tests were negative.

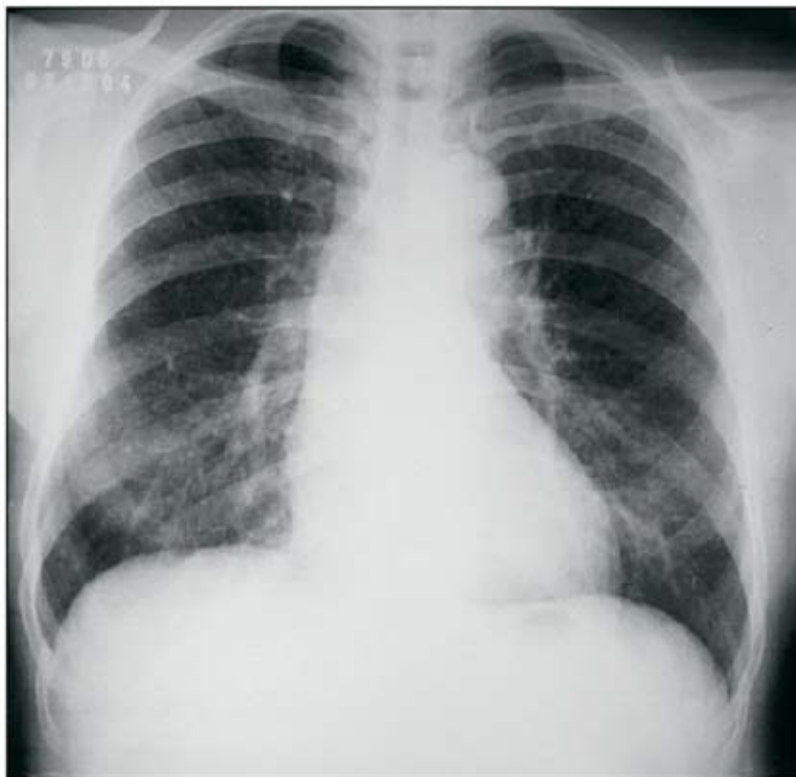
Biopsies were performed in the region of the superior alveolar edge, floor of the mouth, and hard palate. Tissue sections exhibited oral mucosa coated by non-keratinized stratified squamous epithelium with acanthosis and focal areas of exocytosis. The underlying connective tissue showed an intense lymphocytic and polymorphonuclear infiltrate in addition to



**Figure 2.** Ulcer on the anterior aspect maxillary alveolar ridge.



**Figure 3.** Ulcer on the hard palate.



**Figure 4.** Radiograph of the thorax showing nodular infiltration.

multinuclear giant cells and coagulation necrosis. A special stain for fungus, using the Grocott-Gomori method, was positive (Figure 6).

The patient was then referred to a local pneumology center for evaluation of the lungs. A fibrobronchoscopic examination was performed, and the entire respiratory tract was

normal. Pulmonary biopsy exhibited aerial spaces containing macrophages, dark granular hemosiderin, and absence of fungus.

#### Treatment

In agreement with pneumologists 400 mg/day of ketoconazole was prescribed for the patient. After two months of treatment, even though

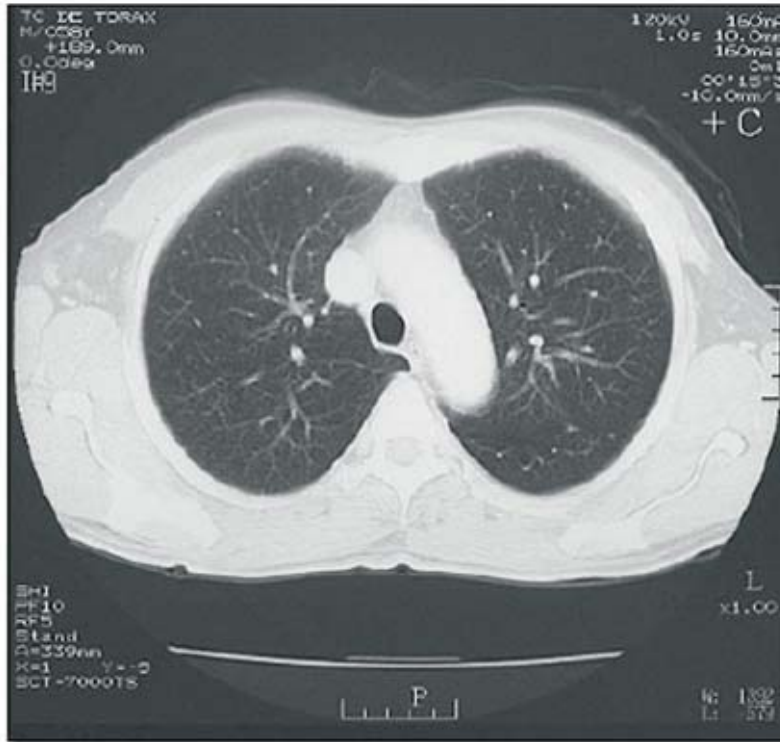


Figure 5. Computed tomographic image of the middle portion of the lungs.

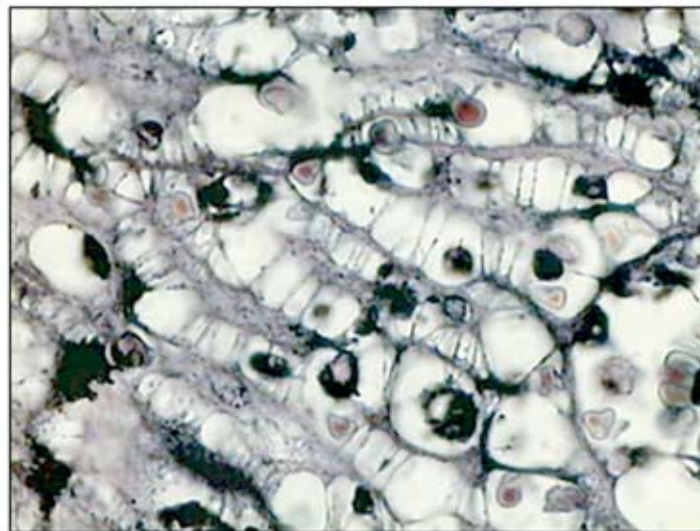


Figure 6. *Paracoccidioides brasiliensis* in the oral tissue obtained through biopsy. (Grocott-Gomori, 400 X)

the oral lesions had resolved completely, the therapy was continued for six months.<sup>8,9</sup> One year following treatment the patient was in good health and free of any signs of recurrent infection.

This paper is in accordance with bioethical concerns. Informed consent was obtained from the patient for all image exams performed, for the surgical procedures, and for the publication of the data given in this report.

## Discussion

*Paracoccidioides brasiliensis* inhabits humid soil and land surrounded by rivers and lakes rich in proteins.<sup>10</sup> The fungus takes the form of yeast or mycelium according to temperature variations. When it appears as a filamentous mycelium, it will penetrate into the organism through the respiratory-digestive tract by inhalation.<sup>11</sup> It grows at 37°C in the form of a yeast, and at room temperature it appears in the form of fine separate filaments creating the mycelium.<sup>2</sup> At this stage, the fungus grows and produces conidia.

Infection starts after inhalation or accidental inoculation of *Paracoccidioides brasiliensis*. However, inter-human transmission has not yet been proven.<sup>12</sup> McEween et al.<sup>13</sup> infected mice with conidia through inhalation and reported these biologic agents reached the lung alveoli in 12 hours and became yeast. This transformation is induced *in vitro* by temperature changes resulting in modulation of the cell wall where the polymeric links change from beta-glucan to alfa-glucan, possibly to prevent beta-glucan from setting off an inflammatory response.<sup>2</sup>

Macrophages are activated by components of the *Paracoccidioides brasiliensis* cell wall to produce TNF-alfa, IL6, and IL10.<sup>14</sup> The IL6 acts to reduce the poisonous effect of TNF-alfa and stimulate the synthesis of antibodies by B lymphocytes. The IL10 also acts to reduce the effectiveness of pro-inflammatory cytokines. The balance of these cytokines makes the disease persist in a chronic form for a long period without systemic symptoms, such as fever and anorexia.<sup>14</sup>

In Latin America the infection is a great endemic problem, especially in Brazil.<sup>3,10</sup> Its geographic distribution is probably due to climatic conditions demanded by the fungus. In the endemic regions approximately 10% of people are considered to

be exposed.<sup>15</sup> The majority of those affected are alcoholics, smokers, immunosuppressed patients, and adult men.<sup>10,16</sup> The predilection for men seems to be the result of protective action of beta-estradiol female hormone that prevents the fungus from being transformed from yeast into the hypha pathogenic form.<sup>17</sup>

The profile of the patient in this report coincided with the one expected in cases of this infection. He was a smoker, a relevant factor for decreasing local tissue resistance, thus, facilitating fungus penetration into the tissues. The patient in this report is from a non-endemic area for the disease, which is more evident in the South and South East regions of Brazil.

Clinically, the disease may exhibit acute, sub-acute, and chronic patterns; the latter being the most prevalent. The acute form progresses rapidly with intense involvement of the reticuloendothelial system and affects young individuals, whereas the chronic pattern predominates in adult men and can take years to develop.<sup>2</sup> Lung damage may be asymptomatic even when extensive lesions are revealed by radiographs of the thorax. Lung infection can progress and simulate tuberculosis.<sup>2</sup> *Paracoccidioides brasiliensis* spreads via both the lymphatic and hematogenic systems.

Ulcerated lesions of the oral mucosa with a granular appearance are indicative of paracoccidioidomycosis.<sup>3,7</sup> Other clinical characteristics include punctiform, hemorrhagic erosions that spread involving a large area of mucous membrane and ulcerate.<sup>10,18</sup> These oral lesions may be similar to other infections and neoplastic diseases including squamous cell carcinoma.<sup>19</sup>

These signs were observed in the case reported here where the floor of the mouth, alveolar edge, and hard palate were affected by lesions similar to malignant neoplasia. Thus, one of the diagnostic hypotheses in this case was squamous cell carcinoma because the patient was a smoker and tobacco has an effective carcinogenic potential.<sup>20</sup> However, the fact the lesions were distributed in more than one anatomic site in the mouth represented a strong indication of paracoccidioidomycosis.

Histopathological features of tissue sections obtained by incisional biopsy confirmed the diagnosis of this infection. The microscopic analysis using the Grocott-Gomori stain technique exhibited fungus in the oral tissue with multiple offshoots, resulting in a steering-wheel appearance.

An unexpected finding in this case was the lack of lung lesions using either fibrobronchoscopy or radiographic exams. Almeida and Scully<sup>21</sup> argue the lung is not frequently compromised in the acute form of the disease. This was a chronic form of the disease as the lesions were of longstanding duration. A cross sectional study<sup>22</sup> of 173 patients described pulmonary lesions in 74% of the individuals with the chronic form of the disease, and the study showed involvement may occur in an isolated manner in tissues other than the lungs in some cases. Nevertheless, even in individuals without signs of infection in the respiratory tract as was observed in the present patient, a lung evaluation should be performed as the fungus could colonize lung septa without causing an evident lesion.<sup>21</sup>

In the present report even a biopsy of lung parenchyma failed to exhibit *Paracoccidioides brasiliensis*. Some authors admit this infection can result from the inoculation of *Paracoccidioides brasiliensis* directly into the oral mucous membrane,<sup>19</sup> because fungus colonization in the tissues occurs after microorganisms adhere to laminin, which is an important component of oral mucosa basal lamina.<sup>28</sup> Other authors also recorded cases of this mycosis in the oral cavity<sup>23-25</sup> or in other sites<sup>26</sup> without lung damage. Burnier and Santanna<sup>27</sup> also reported a case of Paracoccidioidomycosis in the upper eyelid without lung disease and

attributed the colonization of this tissue by direct inoculation of fungus in the eyelid while recognizing it was rare to contract the conidium this way.

Sulfonamides, itraconazole, and ketoconazole are suitable for the treatment of paracoccidioidomycosis. Choice of the best therapeutic schedule should not only be based on the effectiveness and safety of the antifungal drug but also by the individual's access to medication during the entire treatment. This patient in the present report received ketoconazole because it was the only antifungal drug available in the public health service. Therapy for paracoccidioidomycosis always involves treatment protocols of long duration, and periodic follow up of ambulatory patients is necessary.<sup>8,9</sup> Due to the long period that had elapsed from the time the disease was detected until a cure was obtained, the patient was kept under treatment with the medication for six months. Follow-up of the patient and assessment of hepatic function, which presented normal results, demonstrated the drug was effective and showed no harmful side effects on the liver.

### Summary

Based on clinical, radiographic, and histologic findings, the differential diagnosis included paracoccidioidomycosis and squamous cell carcinoma. Fibrobronchoscopic examination of the entire respiratory tract was normal. Pulmonary biopsy exhibited an absence of fungus. A final diagnosis of paracoccidioidomycosis was made and the treatment was successful. This is a prime example of oral manifestations of a systemic disease in which the dentist is the initial health care professional to evaluate the patient due to the location of the lesions.

## References

1. Romano CC, Mendes-Giannini MJS, Duarte AJS, Bernard G. IL-12 and Neutralization of endogenous IL-10 revert the in vitro antigen specific cellular immunosuppression of paracoccidioidomycosis patients. *Cytokine* 2002; 18(3): 149-57.
2. Borges-Walmsley MI, Daliang C, Shu X, Wamsley R. The pathobiology of *Paracoccidioides brasiliensis*. *Trends Microbiol* 2002; 10(2): 80-7.
3. Bisinelli JC, Marzola C, Ferreira MLS, Toledo-Filho, JL, Pastori CM, Zorzetto, DLG. Manifestações estomatológicas das paracoccidioidomicoses (*Paracoccidioides brasiliensis* ou Enfermidade de Lutz-Splendore-Almeida). *Rev FOB* 1998; 6(1): 1-11.
4. Brummer E, Hanson LH, Stevens DA. Gamma-Interferon activation of macrophage for killing of *paracoccidioides brasiliensis* and evidence for nonoxidative mechanisms. *Int J Immunopharmac* 1998; 10(8): 945-52.
5. Finamor LP, Muccioli C, Martins, MC, Rizzo LV, Belfort Jr R. Ocular and Central nervous system paracoccidioidomycosis in a pregnant woman with acquired immunodeficiency syndrome. *Am J Ophthalmol* 2002; 134(3): 456-9.
6. Popi AF, Lopes JD, Mariano M. GP43 from *Paracoccidioides brasiliensis* inhibits macrophage functions. An evasion mechanism of the fungus. *Cell Immunol* 2002; 218: 87-94.
7. Sposto MR, Mendes-Giannini MJ, Moraes RA, Branco FC, Scully C. Paracoccidioidomycosis manifesting as oral lesions: clinical, cytological and serological investigation. *J Oral Pathol Med* 1994; 23: 85-7.
8. Restrepo A, Gomez I, Cano LA, Arango MD, Gutierrez A, Sanín A, Robledo MA. Post-Therapy Status of Paracoccidioidomycosis Treated with Ketoconazole. *Am J Med* 1983; 24;74(1B): 53-7.
9. Restrepo A, Gomez I, Cano LE, Arango MD, Gutierrez F, Sanin A. Robledo MA. Treatment of paracoccidioidomycosis with ketoconazole: A three-year experience. *Am J Med* 1983; 24;74(1B): 48-52.
10. Pagliare AV, Arce GAT, Piazzeta CM. Aspectos clínicos das lesões de paracoccidioidomicose na mucosa bucal. *Dens* 1995; 11: 41-8.
11. Ortega KL, Oliveira PT, Magalhães MHCG, Araújo NS. A citologia esfoliativa no diagnóstico da paracoccidioidomicose. Relato de Caso. *Rev Pós-Grad Fac Odontol Univ São Paulo* 1996; 32(2): 148-54.
12. Pontes FSC, Pontes HAR, Moreira CR, Danin GA, Pereira EM. Paracoccidioidomicose – aspectos gerais e relatos de caso. *BCI* 2000; 7(28): 73-7.
13. McEween JG, Bedoya V, Patino MM, Salazar MF, Restrepo A. Experimental murine paracoccidioidomycosis induced by inhalation of conidia. *J Med Vet Mycol* 1987; 25(3): 165-75.
14. Peraçoli MTS, Kurokawa S, Calvi SA, Mendes RP, Pereira PCM, Marques AS, Soares AM. Production of pro-and anti-inflammatory cytokines by monocytes from patients with paracoccidioidomycosis. *Microbes Infect* 2003; 5(5): 413-8.
15. Restrepo A, Mc Ewen JG, Castaneda E. The habitat of *Paracoccidioides brasiliensis*: how far from solving the riddle? *Med Mycol* 2001; 39 (3): 233-41.
16. Uribe F, Zuluaga AI, Leon W, Restrepo A. Histopathology of cutaneous and mucosal lesions in human paracoccidioidomycosis. *Rev Inst Med Trop São Paulo* 1987; 29(2): 90-6.
17. Aristizabal BH, Clemons KV, Stevens DA, Restrepo A. Morphological transition of *Paracoccidioides brasiliensis* conidia to yeast: *in vivo* inhibition in females. *Infect Immun* 1998; 66(11): 5587-91.
18. Marinho AS, Pereira AAC. Paracoccidioidomicose em Mulher. *Rev Assoc Paul Cir Dent* 2004; 58(3): 185-7.
19. Meneses-Garcia A, Mosqueda-Taylor A, Morales-de la Luz R, Rivera LM. Paracoccidioidomycosis: Report of 2 cases mimicking squamous cell carcinoma. *Oral Surg Oral Med Oral Pathol Oral Radiol Endod* 2002; 94(5): 609-13.
20. Andrade MGS, Reis SRA, Marchionni AMT, Almeida TA, Costa CO, Jesus RP. Fatores de risco do câncer na cavidade oral e da orofaringe. I Fumo, álcool e outros determinantes. *Rev Pós-Grad Fac Odontol Univ São Paulo* 1997; 4(2): 127-32.

21. Almeida OP, Junior JJ, Scully C Paracoccidioidomycosis of the mouth: an emerging deep mycosis. *Crit Rev Oral Biol Med.* 2003; 14(5): 377-83.
22. Franco MF, Mendes RP, Moscardi-Bachi M, Reskallah-Iwasso MT, Montenegro MR. Paracoccidioidomycosis. *Baillière's Clin Trop Med Commun Dis* 1989; 4: 185–220.
23. Sposto MR, Scully C, de Almeida OP, Jorge J, Graner E, Bozzo L. Oral Paracoccidioidomycosis. A study of 36 South-American patients. *Oral Surg Oral Med Oral Pathol* 1993; 75(4): 461–5.
24. Godoy H, Reichart PA. Oral manifestations of paracoccidioidomycosis. Report of 21 cases from Argentina. *Mycoses* 2003; 46(9-10): 412-7.
25. Roldan CJ, Tabares AM, Gómez, BL, Aristizabál BE, Coch AM, Restrepo A. The oral route in the pathogenesis of paracoccidioidomycosis: an experimental study in BALB/c mice infected with *P. brasiliensis* conidia. *Mycopathologia* 2001; 151(2): 57-62.
26. dos Santos JWA, Severo LC, Porto NS, Moreira JS, Silva LCC, Camargo JJP. Chronic pulmonary paracoccidioidomycosis in the state of Rio Grande do Sul, Brazil. *Mycopathologia* 1999; 145(2): 63–7.
27. Burnier SV, Sant'Anna AE. Palpebral paracoccidioidomycosis. *Mycopathologia* 1997; 140(1): 29–33.
28. André DC, Lopes JD, Franco MF, Váz, CAC, Calich, VLG. Binding of laminin to *Paracoccidioides brasiliensis* induces a less severe pulmonary paracoccidioidomycosis caused by virulent and low-virulence isolates. *Microbes Infect* 2004; 6(6): 549–58.



## About the Authors

**Miguel Gustavo Setúbal Andrade, MD, DS**



Dr. Andrade is a Professor of Maxillofacial Surgery and Pathology in the Department of Basic Sciences of the School of Dentistry at the Bahia Foundation for the Development of Science in Salvador-BA, Brazil.

e-mail: [miguelssetubal@hotmail.com](mailto:miguelssetubal@hotmail.com)

**Alena Pelxoto Medrado, MS, DS**



Dr. Medrado is a Professor of Oral Pathology in the Department of Basic Sciences of the School of Dentistry at the Bahia Foundation for the Development of Science in Salvador-BA, Brazil.

e-mail: [alena@cpogm.flocruz.br](mailto:alena@cpogm.flocruz.br)

**Igor Costa de Brito, BS**



Mr. de Brito is graduate student in the Department of Basic Sciences of the School of Dentistry at the Bahia Foundation for the Development of Science in Salvador-BA, Brazil.

e-mail: [igor.cb@hotmail.com](mailto:igor.cb@hotmail.com)

**Silvia Regina de Almeida Reis, MD, DDS, PhD**



Dr. Reis is a Professor of Oral Pathology in the Department of Basic Sciences of the School of Dentistry at the Bahia Foundation for the Development of Science in Salvador-BA, Brazil.

e-mail: [srareis@ud.com.br](mailto:srareis@ud.com.br)