

A Comparative Evaluation of the Effectiveness of an Anorganic Bone Matrix/Cell Binding Peptide with an Open Flap Debridement in Human Infrabony Defects: A Clinical and Radiographic Study

Manohar L. Bhongade, MDS, BSc; Ishan R. Tiwari, BDS, MDS



Abstract

Aim: The development of biologic modalities designed to enhance bone regeneration and wound healing of specific periodontal sites continues to unfold. This is accomplished through the cell binding activity of Type-I collagen provided by a synthetic cell binding peptide (P-15) which is incorporated in a scaffold of anorganic bovine matrix (ABM). This combination is designed to facilitate the attachment, migration, and differentiation of cells. The objective of this study is to clinically and radiographically evaluate the effectiveness of the combination of ABM and P-15 (ABM/P-15) 'putty' during regenerative periodontal procedures.

Methods and Materials: A total of 20 interproximal intraosseous defects in 16 patients, (8 males, 8 females), age 22-48 years (mean 34.45) were recruited and divided equally into two experimental groups. Following open flap debridement (OFD), the defect sites in a test group were grafted with a bovine-derived xenograft enriched with a cell binding peptide. The defect sites in a control group were treated with only OFD. Appropriate periodontal maintenance schedules were followed; at six months, clinical and radiographic assessments for soft tissue and hard tissue were performed for documentation and finalization of results.

Results: Statistical analysis using student paired 't' test analyses of the patient mean value from the 16 patients revealed the ABM/P-15 'putty' graft group demonstrated significantly better mean defect fill of 3.4 + 0.7 mm (70.5%) versus mean defect fill of 0.9 mm (17.33%) for defects treated with only OFD. Soft tissue findings showed significant differences among treatment with ABM/P-15 compared to OFD.

© Seer Publishing

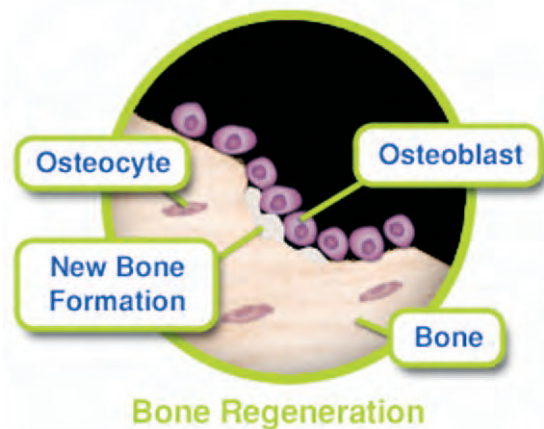
Conclusions: These results indicate the use of P-15 synthetic cell binding peptide combined with ABM yields better clinical results in conjunction with OFD than with OFD alone.

Keywords: Anorganic bone matrix, cell binding peptide, open flap debridement, infrabony defects

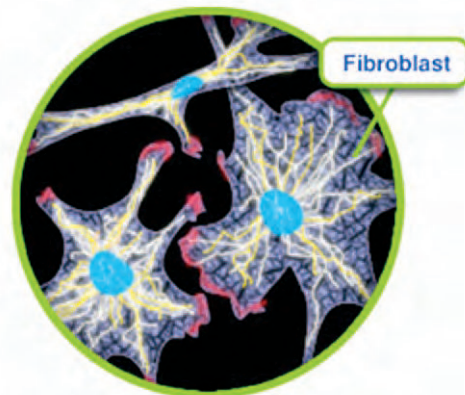
Citation: Bhongade ML, Tiwari IR. A Comparative Evaluation of the Effectiveness of an Anorganic Bone Matrix/ Cell Binding Peptide with an Open Flap Debridement in Human Infrabony Defects: A Clinical and Radiographic Study. *J Contemp Dent Pract* 2007 September; (8)6:025-034.

Introduction

Complete regeneration of destroyed periodontal tissues is the ultimate goal of periodontal therapy. Several bone graft materials have been used in an attempt to regenerate lost bone as a result of periodontal disease. Although these materials have demonstrated clinical effectiveness in terms of functional periodontal repair, defect fill, and the reduction of periodontal pockets at a manageable level, a predictable high rate of success in terms of regeneration has not yet been achieved.¹ Autogenous bone grafts; allografts, such as non-decalcified freeze-dried bone allograft (FDBA);² decalcified freeze-dried bone allograft (DFDBA);^{3,4} synthetic or natural hydroxyapatite;⁵ and bioactive glasses,^{6,7} acting as a scaffold, have been evaluated in human infrabony defects, but they have not always induced bone formation.



Intense research is currently underway in a number of laboratories to identify, characterize, purify, and synthesize a variety of biologic modulators that may enhance wound healing and regeneration of lost tissues in periodontal therapy.^{8,9,10} Recently, investigators have focused on the cell binding aspect of this process. The P-15 peptide is a synthetic clone of the 15-amino acid sequence Type-I collagen which plays an

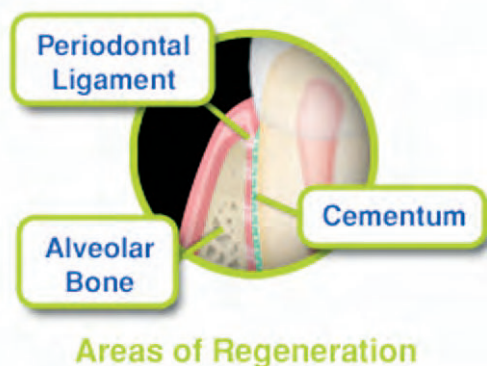


Connective Tissue Cells

important role in the binding of cells, particularly fibroblasts and osteoblasts,^{8,10} and the initiation of other cellular events like migration, proliferation, and differentiation necessary for bone repair.^{11,12}

Recently, the use of a new combination (ABM/P-15) of a natural bovine-derived hydroxyapatite bone matrix (ABM) coupled with a cell binding peptide (P-15) in human infrabony defects in conjunction with periodontal surgery demonstrated true regeneration of the periodontium including the cementum, periodontal ligament, and alveolar bone on contaminated areas of the root in a human histological case report.¹³ The mechanism of action of ABM/P-15 is believed to enhance collagen and bone formation by facilitating cellular attachment to fibroblasts and osteoblasts with a subsequent increase in cell binding, proliferation, and differentiation of cells increasing Tgf- β 1, BMP-2, and BMP-7 levels that could positively influence the process of periodontal regeneration.¹⁴

ABM/P-15 has been shown to be clinically effective and superior to other bone graft materials in two multicenter clinical trials.^{15,16} The present clinical and radiographic study was an



attempt to evaluate treatment response following the placement of ABM/P-15 material in human infrabony defects, using the clinical change in clinical attachment level, probing depth, and radiographic bone fill over the six month period as measures of outcome.

Methods and Materials

A total of 16 patients (8 males and 8 females) in the age range of 22-48 years (mean age- 34.45 \pm 12.32 years) with chronic periodontitis were included in the study. The patient inclusion criteria were as follows:

- Subjects were systemically healthy.
- There was a presence of at least one or two radiographically detectable interproximal osseous defects with a probing depth \geq 5 mm and clinical attachment loss \geq 5 mm following initial therapy.
- The depth of the intraosseous component of the defect estimated as \geq 3 mm by clinical and radiographic means.
- There was a presence of at least \geq 2 mm band of keratinized tissue around the test teeth.

The exclusion criteria included:

- Patients with unacceptable oral hygiene (Plaque Index $>$ 1).
- Smokers or use of any tobacco products.
- Third molars and teeth with inadequate endodontic/restorative treatments or defects extending into furcations.
- Teeth exceeding Class II mobility.
- Patients previously treated by periodontal surgical therapy.
- Any pregnant females or lactating mothers.

Initial therapy consisted of oral hygiene instructions, supragingival and subgingival scaling along with root planing under local anesthesia.

Plaque control instructions were repeated until patients achieved Silness and Loe¹⁷ plaque scores of \leq 1. A re-evaluation examination was performed after six weeks following completion of initial therapy to determine the patients' responses to therapy and to confirm the need for periodontal surgery.

Prior to initiating the study, the purpose and design of the clinical trial was explained and informed consent was conveyed by every participating patient. The study protocol was approved by the ethical committee of Datta Meghe Institute of Medical Sciences, Deemed University, Sawangi (Meghe), Wardha, India.

Study Design and Randomization

A total of 20 interproximal defects in 16 patients were found to be suitable after initial therapy. Prior to surgery selected defects were randomly assigned by a coin flip to test and control groups with each consisting of ten defects in accordance with a randomized parallel design. The test group was treated using open flap debridement (OFD) in conjunction with PepGen P-15 putty, (Dentsply Friadent CeraMed, Lakewood, CO, USA) which is a commercial brand of ABM/P-15. The control group was treated using OFD alone.

Clinical Measurements

On the day of surgery and at six months post surgery, patient's oral hygiene status was evaluated using the Plaque Index (PI)¹⁷ as an expression of the level of complete-mouth supragingival plaque accumulation. Gingival inflammation was assessed using the Gingival Index (GI).¹⁸ The probing pocket depth (PPD), clinical attachment level (CAL), and gingival recession (REC) were determined with a Florida probe and recorded for assessment of the results. All measurements were recorded at six sites per tooth. During later calculations only the sites representing the deepest point of the defect were used.

A periapical radiograph (PA) with Kodak D-speed film (Carestream Health, Inc., Rochester, NY, USA) was taken of each selected site using the long-cone paralleling technique at baseline and after six months following surgery to measure the radiographic defect depth (DD) and to calculate the percentage of bone defect fill. Radiographic measurement was obtained utilizing a film mount

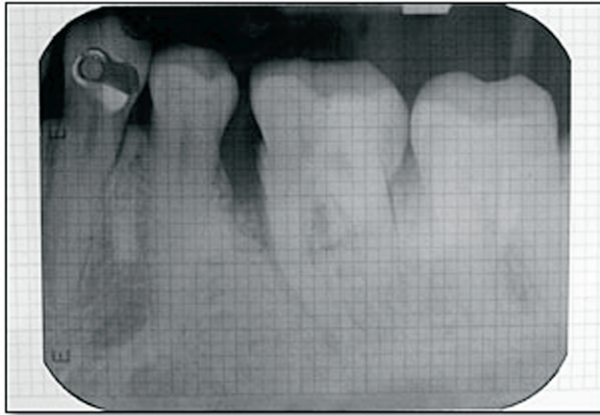


Figure 1. A preoperative periapical radiograph of a vertical defect near tooth #19 in a film mount with a millimeter grid scale.

with millimeter grid scale (Nix Company Ltd., Tokyo, Japan). These are pocket-mount type grids for intraoral-size films. Grid scale lines are printed vertically and horizontally at 1 mm intervals with bolder lines at 5 mm intervals.

The developed films were inserted in the pocket mount grid to measure the radiographic DD at baseline and at six months post-surgery. Vertical linear distances between the most coronal interproximal extension of the bone crest and the most apical part of the defect were determined with the measuring grid. The radiographic DD reduction (defect fill in mm) was calculated by subtracting post surgical radiographic DD at six months from the baseline radiographic DD. Radiographic defect fill in terms of percentage was then obtained by comparing the DD reduction (defect fill) at six months with the radiographic DD at baseline in both groups.

Surgical Procedure

Immediately before surgery, patients rinsed with 0.2% chlorhexidine gluconate solution for one minute. Asepsis was maintained throughout the entire surgical procedure. The area to be subjected to surgery was verified using a Florida probe then anesthetized either by nerve block or infiltration anesthesia, depending on the surgical site (Figure 2).

A conventional surgical approach consisting of a periodontal access flap was initiated with intracrevicular (sulcular) incisions on the buccal and lingual aspects of the involved tooth. The

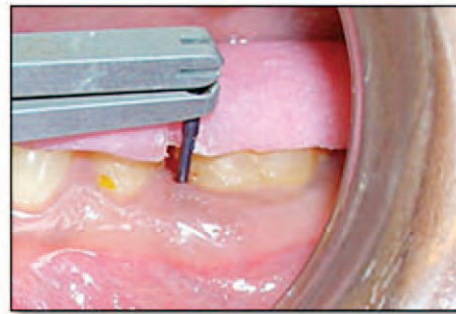


Figure 2. Preoperative view of the Florida probe in position.

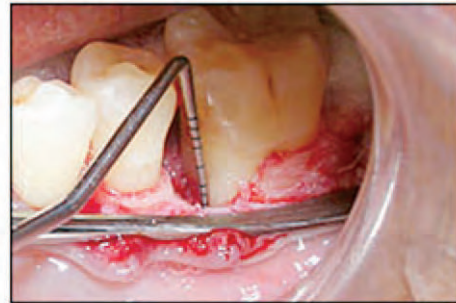

Figure 3. Configuration and depth of an intrabony defect adjacent to tooth #19.

incisions were carried as far interproximally as possible to preserve the entire interdental papilla in order to achieve favorable primary wound closure. The flap was extended to include a tooth mesial and distal to the defect-associated tooth. When necessary, divergent vertical relieving incisions were made one tooth away from the defect if additional access was required. Full-thickness (mucoperiosteal) flaps were reflected to expose alveolar bone in the area of osseous defect (Figure 3).

Extreme care was taken to avoid flap perforation or the loss of papillae due to granulosomatous tissue from the lesion adhering to the inner aspect of the flap. Any granulosomatous tissue or epithelium adherent to the inner surface of the flap or papillae was judiciously removed with care to not overly thin the flap. The osseous defect was debrided of granulation tissue using hand and ultrasonic instruments to expose the root surface, alveolar bone, and periodontal ligament. The root surfaces were planed to remove plaque and calculus using ultrasonic and hand instrumentation. The root surfaces were planed until a smooth hard consistency was obtained.

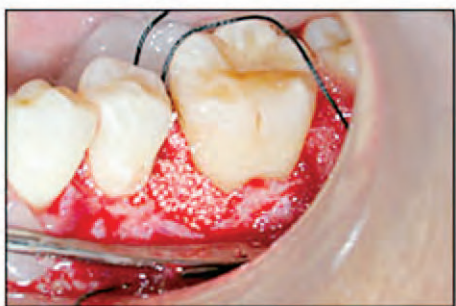

Figure 4. Post-treatment facial photographs of Case #1.

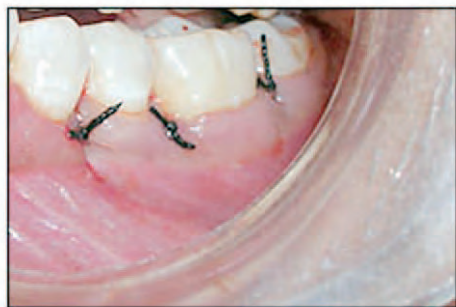

Figure 5. Post-treatment intraoral photographs of Case #1.

At this stage, the depth of the interproximal osseous defect was measured and classified depending on the number of bony walls present. Intramarrow penetration was performed with a half-round bur if there was insufficient bleeding from the walls of the lesion. According to manufacturer's directions, the ABM/P-15 peptide-enhanced bone graft material in particulate form was mixed thoroughly with sodium hyaluronate in phosphate buffered saline in a sterile mixing container using a sterile spatula until the mixture was a homogenous and a putty-like consistency.

In test sites ABM/P-15 (PepGen P-15 putty) material was placed and packed into the defect up to adjacent alveolar crest walls to fill but not to overfill the defect (Figure 4).

The mucoperiosteal flaps were then sutured in their original position using interdental interrupted 4-0 non-absorbable Mersilk braided black silk surgical suture (Ethicon, Johnson and Johnson Ltd, Somerville, NJ, USA). Primary tension-free wound closure was achieved to avoid contamination of the wound with oral debris.

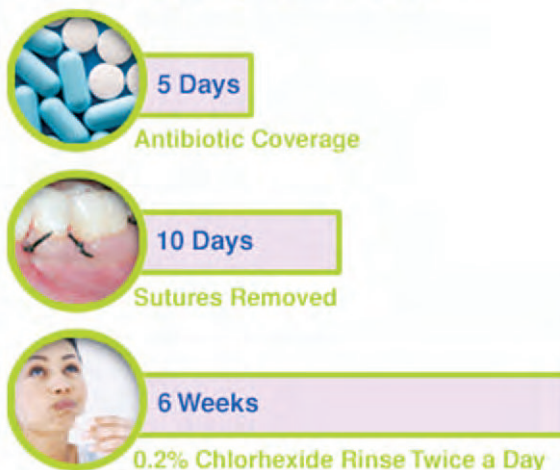The surgical site was dressed with Coe-Pak TM® periodontal dressing (GC, Inc, Alsip, IL, USA). The surgical procedure for control sites was identical

to the test sites except for the omission of the placement of ABM/P-15 material into the osseous defects.

Post-Operative Care

Antibiotic coverage consisting of 500 mg of amoxicillin three times a day and analgesics consisting of a combination of Ibuprofen (325 mg) and Paracetamol (400 mg) were prescribed for five days. Patients were instructed to rinse twice daily with 0.2% chlorhexidine gluconate for six weeks. The periodontal dressing and sutures were removed at eight to ten days post surgery. No mechanical oral hygiene procedures or chewing in the treated area was allowed for six weeks. After this period, the chlorhexidine was discontinued and patients were instructed to resume mechanical oral hygiene measures including careful brushing with an ultra soft toothbrush and interdental cleaning with an interdental brush. The patients were recalled at one, three, and six months post surgery at which time all patients received oral hygiene instructions and full mouth professional prophylaxis in the form of a supragingival scaling with ultrasonic instruments at each follow up visit. Neither probing nor subgingival instrumentation was performed during the first six months post surgical period.

Post-Operative Care



Statistical Analysis¹⁹

The means and standard deviations of PPD, CAL, REC, and radiographic DD at baseline and at six months post-surgery were calculated for both groups. The Student's Paired t-test was used to compare the data from the baseline to those at six months for each treatment group. Comparisons

between treatment groups at baseline and six months post-surgery were accomplished with the Student's Unpaired t-test. If the probability value (p) was more than 0.05, the difference observed was considered non-significant; if less than 0.05, it was considered significant.

Results

Wound healing was uneventful during the course of the study. There were no untoward effects, allergic reactions, infections, or patient complaints related to the graft material. The ABM/P-15 appeared to be clinically well tolerated by the periodontal tissues, and exfoliation of particles was not noted. None of the selected

patients dropped out before the termination of the study and in general showed good oral hygiene throughout the study. The mean PI score during the six month period remained low (< 1). There was a statistically significant reduction in GI scores at six months (p<0.05), indicating satisfactory improvement in gingival condition throughout the study. Tables 1 and 2 demonstrates in detail regarding patient's age, sex, location of tooth, defect type, and comparison of all clinical parameters at baseline and at six months follow-up in the test group and control group respectively. At baseline, no statistically significant differences in any of the investigated parameters were observed between

Table 1. Patient's age, sex, location of tooth, defect type, and comparison of clinical parameters at baseline and at six months follow-up in the test group.

Pt	Age	Sex	Tooth	Defect Type	Baseline				Six Months				PPD Reduction	CAL Gain	REC Increase	Defect Fill %
					PPD	CAL	REC	DD	PPD	CAL	REC	DD				
1	23	F	# 19	2 wall	6.6	6.6	0.0	4	3.4	3.6	0.2	1.5	3.2	3.0	0.2	62.5%
2	28	M	# 14	1 ½ wall	6.6	6.6	0.0	4	4.4	4.4	0.0	1.5	2.2	2.2	0.0	62.5%
3	35	F	# 30	3 wall	7.0	7.0	0.0	5	3.8	4.0	0.2	1.5	3.2	3.0	0.2	70%
4	40	F	# 19	2 wall	7.0	7.0	0.0	5	4.0	4.2	0.2	1.5	3.0	2.8	0.2	70%
5	35	F	# 30	1 ½ wall	6.6	6.8	0.2	5	4.0	4.2	0.2	1.5	2.6	2.6	0.0	70%
6	24	M	# 31	1 ½ wall	7.2	7.2	0.0	5	3.8	3.8	0.0	2.5	3.4	3.4	0.0	50%
7	33	F	# 14	3 wall	6.8	7.0	0.2	5	3.6	3.8	0.2	0	3.2	3.2	0.0	100%
8	45	M	# 11	2 wall	6.6	6.6	0.0	5	3.6	3.8	0.2	1.5	3.0	2.8	0.2	70%
9	33	F	# 14	3 wall	6.8	7.0	0.2	5	3.6	3.8	0.2	1.0	3.2	3.2	0.0	80%
10	30	F	#30	2 wall	6.6	6.6	0.0	5	3.8	4.2	0.4	1.5	2.8	2.4	0.4	70%
Mean SD	32.6 ± 6.14				6.78 ± 0.22	6.84 ± 0.28	0.06 ± 0.09	4.8 ± 0.42	3.8 ± 0.28	3.98 ± 0.25	0.18 ± 0.11	1.4 ± 0.61	2.98 ± 0.35	2.86 ± 0.37	0.12 ± 0.13	70.5% ± 12.95

(MV±SD in mm)

Table 2. Patient's age, sex, location of tooth, defect type, and comparison of clinical parameters at baseline and at six months follow-up in the control group.

Pt	Age	Sex	Tooth	Defect type	Baseline				Six Months				PPD Red	CAL Gain	REC Increase	Defect Fill %
					PPD	CAL	REC	DD	PPD	CAL	REC	DD				
1	44	F	# 18	1 ½ wall	7.0	7.2	0.2	5.0	5.0	5.6	0.6	4.5	2	1.6	0.4	10%
2	45	M	# 14	2 wall	7.2	7.4	0.2	5.0	5.6	6.8	1.2	4.0	1.6	0.6	1.0	20%
3	35	F	# 30	2 wall	6.8	7.4	0.6	6.0	4.6	5.4	0.8	4.5	2.2	2	0.2	25%
4	35	M	# 19	3 wall	6.8	6.8	0.0	5.0	5.6	5.8	0.2	4.0	1.2	1	0.2	20%
5	35	M	# 18	2 wall	7.0	7.2	0.2	5.0	5.2	5.4	0.2	3.0	1.8	1.8	0.0	40%
6	28	M	# 19	1 ½ wall	6.8	6.8	0.0	4.0	5.0	5.2	0.2	4.0	1.8	1.6	0.2	0%
7	48	M	# 5	1 ½ wall	6.6	6.8	0.2	4.5	5.4	5.6	0.2	4.0	1.2	1.2	0.0	11.11%
8	28	M	# 30	2 wall	6.8	6.8	0.0	5.0	5.0	5.4	0.4	4.5	1.8	1.4	0.4	10%
9	35	M	# 19	1 ½ wall	6.4	6.6	0.2	5.0	5.8	6.0	0.2	4.5	0.6	0.6	0.0	10%
10	30	F	# 18	2 wall	7.8	7.8	0.0	5.5	5.2	5.4	0.2	4.0	2.6	2.4	0.2	27.27%
Mean SD	36.3 ± 7.11				6.92 ± 0.37	7.08 ± 0.31	0.16 ± 0.18	5.0 ± 0.52	5.24 ± 0.36	5.66 ± 0.46	0.42 ± 0.34	4.1 ± 0.45	1.68 ± 0.56	1.42 ± 0.48	0.26 ± 0.29	17.33 ± 11.47

(MV±SD in mm)

the test and control groups ($p > 0.05$), indicating the randomization process was effective (Table 3).

Clinical Outcomes at Six Months

In the test group the mean PPD at baseline was 6.78 ± 0.22 mm and at six months was 3.8 ± 0.28 mm. In the control group the mean PPD at baseline was 6.92 ± 0.37 mm and at six months was 5.24 ± 0.36 mm. At six months, the mean PPD reduction was 2.98 ± 0.35 mm for the test group and 1.68 ± 0.56 mm for the control group. The Student's Paired t-test indicated both the test (ABM/P-15) and control (OFD) groups showed a significantly greater mean PPD reduction at six

months compared to baseline ($p < 0.05$). When the differences in mean PPD reductions for the test group (2.98 mm) versus control group (1.68 mm) were analyzed, a greater reduction in mean PPD was demonstrated in the test (ABM/P-15) group. Of all surgical sites 80% of those treated with ABM/P-15 showed pocket depth reduction of more than 2.5 mm, while only 10% of OFD sites showed a PPD reduction of more than 2.5 mm.

Clinical Attachment Level (CAL)

In the test group the mean CAL at baseline was 6.84 ± 0.28 mm and at six months was 3.98 ± 0.25 mm. In the control group the mean CAL at baseline was 7.08 ± 0.31 mm and at six months

Table 3. Baseline defect characteristics for the test (ABM/P-15) and control (OFD) groups (mean ± SD; in mm).

Parameters (at site)	Test group (ABM/P-15)	Control (OFD)	p-value
Probing Pocket Depth (PPD)	6.78 ± 0.22	6.92 ± 0.37	NS
Clinical Attachment Level (CAL)	6.84 ± 0.28	7.08 ± 0.31	NS
Gingival Recession (REC)	0.06 ± 0.09	0.16 ± 0.18	NS
Radiographic defect depth (DD)	4.8 ± 0.42	5.0 ± 0.52	NS

was 5.66 ± 0.46 mm (Tables 4 and 5). The mean CAL gains of 2.86 ± 0.37 mm was observed in the test (ABM/P-15) group, while the control (OFD) group displayed mean CAL gains of 1.42 ± 0.48 mm. The observed differences between baseline CAL and at six months were found to be statistically significant in both the groups (p<0.05).

The Student's Unpaired t-test revealed significantly greater CAL gains for the test group (2.86 mm) than the control group (1.42 mm). The magnitude of the observed additional benefit was 1.44 mm in the test group. The ABM/P-15 treatment resulted in 80% of the defect sites gaining 2.5 mm or more CAL, whereas none of the sites with OFD treatment resulted in a CAL gain of more than 2.5 mm.

Gingival Recession (REC)

At six months, the mean increase in REC was 0.12 ± 0.13 mm in the test group and 0.26 ± 0.29 mm in the control group (Table 6). Although a statistically significant increase in REC was found in both the groups (Table 6), there was no statistically significant difference found in the increase in REC between the test and control groups (p>0.05). None of the sites having the ABM/P-15 treatment resulted in an increase in REC of 1 mm or more. However, 10% of the sites treated with OFD alone resulted in an increase in REC of 1 mm or more.

Radiographic Analysis of Defect Depth (DD)

At six months, the mean radiographic DD was reduced from 4.8 ± 0.42 mm to 1.4 ± 0.61 mm in the test group and from 5.0 ± 0.52 mm to

Table 4. Clinical and radiographic parameters at baseline and at six months post-surgery for the test (ABM/P-15) group (mean ± SD; in mm).

Parameters (at site)	Baseline	Six months	Difference	p-value
PPD	6.78 ± 0.22	3.8 ± 0.28	PPD reduction 2.98 ± 0.35	S
CAL	6.84 ± 0.28	3.98 ± 0.25	CAL gain 2.86 ± 0.37	S
REC	0.06 ± 0.09	0.18 ± 0.11	REC increase 0.12 ± 0.13	S
DD	4.8 ± 0.42	1.4 ± 0.61	Decrease in DD 3.4 ± 0.70	S

S; Significant (p<0.05)

Table 5. Clinical and radiographic parameters at baseline and at six months post-surgery for the control (OFD) group (mean ± SD in mm).

Parameters (at site)	Baseline	Six months	Difference	p-value
PPD	6.92 ± 0.37	5.24 ± 0.36	PPD reduction 1.68 ± 0.56	S
CAL	7.08 ± 0.31	5.66 ± 0.46	CAL gain 1.42 ± 0.48	S
REC	0.16 ± 0.18	0.42 ± 0.34	REC increase 0.26 ± 0.29	S
DD	5.0 ± 0.52	4.1 ± 0.45	Decrease in DD 0.9 ± 0.61	S

S; Significant (p<0.05)

Table 6. Comparison of clinical and radiographic parameters between the test groups (ABM / P-15) and the control groups (OFD) at six months post-surgery. (Mean ± SD in mm)

Parameters (at site)	Test Group (ABM/ P-15)	Control Group (OFD)	Difference	p-value	
PPD Reduction	2.98 ± 0.35	1.68 ± 0.56	1.3 ± 0.91	S	
CAL Gain	2.86 ± 0.37	1.42 ± 0.48	1.44 ± 1.01	S	
REC increase	0.12 ± 0.13	0.26 ± 0.29	0.14 ± 0.09	NS	
Defect fill	(mm)	3.4 ± 0.70	0.9 ± 0.61	2.5 ± 1.76	S
	%	70.5 %	17.33 %	53.17 %	-

S; Significant (p<0.05)

NS; Non Significant (p>0.05)

4.1 ± 0.45 mm in the control group (Tables 4 and 5). The mean radiographic DD reduction of 3.4 ± 0.70 mm (70.5%) was observed in the test (ABM/P-15) group, while the control (OFD) group displayed a mean reduction of the DD of 0.90 ± 0.61 mm (17.33%). Statistically significant reductions of radiographic DD were recorded for the test group as well as for the control group (p<0.05). When a comparison was done between the test and control groups, a statistically significant greater reduction of radiographic DD was observed in test group (p<0.05) (Table 6).

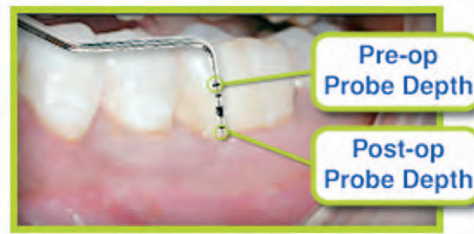
There was also an additional 2.5 mm (53.17%) of reduction in radiographic DD reduction in the test (ABM/P-15) group.

Discussion

Change in the CAL following regenerative therapy is the single most commonly used clinical outcome variable in regenerative studies. In the present study, the mean CAL gain obtained was 2.86 ± 0.37 mm in the test group and 1.42 ± 0.48 mm in the control group at six months. A statistically significant greater amount of mean CAL gain

(1.44 mm) was observed in the test group when compared with the control group. The gain in CAL observed in the test group compares well with those reported in other clinical trials.^{15,16,20} Radhakrishnan et al.²⁰ in a six month study reported a similar mean CAL gain of 2.8 ± 0.92 mm in a ABM/P-15 group and 1.3 ± 0.68 mm in an OFD group. Yukna et al.¹⁵ compared ABM/P-15 with demineralized freeze-dried bovine allograft (DFDBA) and OFD alone and reported a mean CAL gain of 1.3 ± 1.9 mm in an ABM/P-15 group, 0.5 ± 1.8 mm in a DFDBA group, and 0.1 ± 2.4 mm in an OFD group at the six month follow-up visit. Yukna et al.¹⁶ observed a mean CAL gain of 2.2 ± 2.0 mm in ABM/P-15 treated sites and 2.1 ± 1.8 mm in ABM treated sites at the six month follow-up visit. Yukna et al.¹ reported a mean CAL gain of 3.8 ± 1.6 mm in a 36 month follow-up of 25 patients after treatment with ABM/P-15 which was higher than the gain obtained in the present and previous studies. The differences in the CAL gains reported in these studies might be explained by the difference in the initial DD. Clinical studies²¹ have demonstrated the CAL gain following regenerative periodontal surgery is strongly dependent on the initial DD. The greater the initial DD, the greater the amount of CAL gain.

From the clinical standpoint, it is more important to remember 80% of the sites experienced a CAL gain of 2.5 mm or more when treated with ABM/P-15, while none of the sites treated with OFD were able to achieve such a gain (Table 7).



Pocket Depth Reduction

In the present study pocket depth reduction was significant in both test and control groups. A statistically significant greater reduction of PPD (1.3 ± 0.91 mm) was observed in the test group compared to the control group (Table 6). The mean PPD reduction observed in the present study was comparable with the other reported ABM/P-15 studies. Radhakrishnan et al.²⁰ reported a mean pocket depth reduction of 3 ± 0.94 mm in test sites compared to control sites, with 1.4 ± 0.70 mm in depth reduction. Similarly, a mean PPD reduction of 2.9 ± 1.2 mm was observed by Yukna et al.¹ in 25 patients treated with ABM/P-15. Whereas Yukna et al.¹⁵ observed a mean pocket depth reduction of 2.4 ± 1.5 mm in sites treated with ABM/P-15 which is less than the present study. This could be due to the inclusion of periodontal pockets of variable depth, which may possibly have influenced their treatment outcome.

Periodontal surgeries are frequently associated with REC. This is an adverse effect of concern to both patients and clinicians. However,

Table 7. Frequency distribution of clinical characteristics after six months at the test and control sites.

Parameters		Test Group (ABM/P-15)	Control Group (OFD)
CAL Gain (mm)	≥ 2.5	80%	0%
	< 2.5	20%	100%
PPD Red (mm)	≥ 2.5	80%	10%
	< 2.5	20%	90%
REC Increase (mm)	≥ 1	0%	10%
	< 1	100%	90%

regenerative approaches have the potential to minimize this unwanted side effect. In the present study an increase in REC was observed to a limited extent in both the test (0.12 mm) and control (0.26 mm) groups at the end of six months. However, a lack of statistically significant difference in increase in REC was noted when both the groups were compared at six months (Table 6).

Radiographic bone measurement is a non-invasive, painless alternative to direct bone measurement and was used in the present study to monitor alveolar bone changes and to measure the outcome. In the present study reduction in radiographic DD was obtained by subtracting post-surgical DD from the initial DD (Tables 4 and 5). At six months, there was 70.5% defect fill in the test group and 17.33% defect fill in the control group with a statistically significantly greater amount of defect fill (53.17%) in the test group (Table 6). These findings are in accordance with previous studies.^{15,16,20} Yukna et al.^{15,16} reported defect fills of 72.3% and 72.9%, respectively, in two previous studies in ABM/P-15 treated groups when they clinically compared the use of ABM/P-15 to other therapies in human periodontal osseous defects. Radhakrishnan et al.²⁰ also observed a 73.2% defect fill at test sites and a 15.8% defect fill in OFD sites. Thus, the results of this study are highly constant with the literature and closely reflect what has been shown in previous studies.

The most reliable outcome variable for assessing periodontal regeneration is human histology. Due to ethical considerations and patient management limitations, no histological evidence was obtained to establish proof of periodontal regeneration. Based on the histological evidence from human material,^{13,22,23} it may be assumed to some extent the clinical improvements following ABM/P-15 treatment may represent true periodontal regeneration characterized by the formation of new cementum, periodontal ligament, and alveolar bone.

A six month period may be considered too short to evaluate the effect of grafting techniques, biomaterials, or other periodontal therapy. Yukna et al.¹ stated in their long-term study the majority of clinical changes were previously achieved at the time of clinical evaluation at six to seven months, with no real further change from evaluation up to three years. Therefore, a six month time period in the present study could be considered adequate.

Conclusions

Within the limitation of the study of using non-standardized radiographs to measure defect fill, it is reasonable to conclude the regenerative surgical approach using ABM/P-15 in conjunction with OFD for the treatment of infrabony defects resulted in significant added benefit in terms of CAL gains, PPD reductions, and the amount of radiographic defect fill compared to OFD alone.

References

1. Yukna RA, Krauser JT, Callan DP, Evans GH, Cruz R, Martin M. Thirty-six months follow-up of 25 patients treated with combination anorganic bovine-derived hydroxyapatite matrix (ABM)/cell binding peptide (P-15) bone replacement grafts in human intrabony defects. I. Clinical findings. *J Periodontol* 2002; 73: 123-128.
2. Aukhil I, Simpson DM, Schaberg TV. An experimental study of new attachment procedure in beagle dogs. *J Periodontol Res* 1983; 18: 643-654.
3. Quintero G, Mellonig JT, Gambill VM, Pelleu GB. A six month clinical evaluation of decalcified freeze-dried bone allograft in periodontal osseous defects. *J Periodontol* 1982; 53: 726-730.
4. Rummelhart JM, Mellonig JT, Gray JL, Towle HJ. A comparison of freeze-dried bone allograft and decalcified freeze-dried bone allograft in human periodontal osseous defects. *J Periodontol* 1989; 60: 665-663.
5. Yukna RA. Osseous defect responses to hydroxyapatite grafting versus open flap debridement. *J Clin Periodontol* 1989; 16: 398-402.
6. Froum S, Cho SC, Rosenberg E, Rohrer M, Tarnow D. Histological comparison of healing extraction sockets implanted with bioactive glass or demineralized freeze-dried bone allograft: A pilot study. *J Periodontol* 2002; 73: 94-102.
7. Lovelace TB, Mellonig JT, Meffert RM, Jones AA, Nummikoski PV, Cochran DL. Clinical evaluation of bioactive glass in the treatment of periodontal defects in humans. *J Periodontol* 1998; 69: 027-1035.
8. Hagel-Bradway S, Dziak R. Regulation of bone cell metabolism. *J Oral Pathol Med* 1989; 18:344-351.
9. Lynch SE, Williams RC, Polson AM, Howell TH, Reddy MS, Zappa UE, Antoniadis HN. A combination of platelet-derived and insulin-like growth factors enhances periodontal regeneration. *J Clin Periodontol* 1989; 16: 545-548.
10. Seyedin SM. Osteoinduction: A report on the discovery and research of unique protein growth factors mediating bone development. *Oral Surg Oral Med Oral Pathol* 1989; 68: 527-530.
11. Bhatnagar RS, Qian J, Wedrychowska, Smith N. Design of biomimetic habitats for tissue engineering with P-15, a synthetic peptide analog of collagen. *Tissue Eng* 1999; 5: 53 -65.
12. Lallier TE, Yukna RA, Marie SS, Moses R. The putative collagen binding peptide hastens periodontal ligament cell attachment to bone replacement graft materials. *J Periodontol* 2001; 72: 990-997.
13. Yukna RA, Salinas TJ, Carr RF. Periodontal regeneration following use of ABM/P-15: A case report. *Int J Periodontics Restorative Dent* 2002; 22: 146-155.
14. Guerra FA, Krauser JT, Cabrita AM, Matos SM, Marcelino JP, Brites CC. Small Peptide (P-15) bone substitute efficacy in a rabbit cancellous bone model. 2005: Paper # 0212, 51 st Annual Meeting of Orthopaedic Research Society.
15. Yukna RA, Callan DP, Krauser JT, Evans GH, Aichelmann-Reidy ME, Moore K, Cruz R, Scott JB. Multi-center clinical evaluation of combination anorganic bovine-derived hydroxyapatite matrix (ABM)/cell binding peptide (P-15) as a bone replacement graft material in human periodontal osseous defects. 6-month results. *J Periodontol* 1998; 69: 655-663.
16. Yukna RA, Krauser JT, Callan DP, Evans GH, Cruz R, Martin M. Multi-center clinical comparison of combination anorganic bovine-derived hydroxyapatite matrix (ABM)/cell binding peptide (P-15) and ABM in human periodontal osseous defects. 6-month results. *J Periodontol* 2000; 71: 1671-1679.
17. Silness J, Loe H. Periodontal disease in pregnancy (II). Correlation between oral hygiene and periodontal condition. *Acta Odontologica Scandinavica* 1964; 22: 121-135.
18. Loe H, Silness J. Periodontal disease in pregnancy (I). Prevalence and severity. *Acta Odontologica Scandinavica* 1963; 21: 533-551.
19. Mahajan BK. *Methods in Biostatistics*. Ed 5. New Delhi, Jaypee Brothers. 1991: 128-153.
20. Radhakrishnan S, Anusuya CN. Comparative clinical evaluation of combination anorganic bovine-derived hydroxyapatite matrix (ABM)/cell binding peptide (P-15) and open flap debridement (DEBR) in human periodontal osseous defects: A 6-month pilot study. *J Int Acad Periodontol* 2004; 6/3: 101-107.
21. Cortellini P, Pini Prato G, Tonetti MS. Periodontal regeneration of human intrabony defects. (V) Effects of oral hygiene on long term stability. *J Clin Periodontol* 1994; 21:606-610.

22. Barboza EP, de Souza RO, Caula AL, Neto LG, de Oliveira FC, Durate MEL. Bone regeneration of localized chronic alveolar defects utilizing cell binding peptide associated with anorganic bovine-derived bone mineral: a clinical and histological study. J Periodontol 2002; 73: 1153-1159.
23. Vastardis S, Yukna RA, Mayer ET, Atkinson BL. Periodontal regeneration with peptide-enhanced anorganic bone matrix in particulate and putty form in dogs. J Periodontol 2005; 76: 1690-1696.

About the Authors

Manohar L. Bhongade, MDS, BSc



Dr. Bhongade serves as a Professor and Head of the Department of Periodontics and Implant Dentistry in the Sharad Pawar Dental College and Hospital of Deemed University in Sawangi (Meghe), Wardha, Maharashtra State, India.

Ishan R. Tiwari, BDS, MDS



Dr. Tiwari currently serves as a Lecturer in the Department of Periodontics and Implant Dentistry in the Sharad Pawar Dental College and Hospital of Deemed University in Sawangi (Meghe), Wardha, Maharashtra State, India.

e-mail: dr_irt@yahoo.com