

Phenobarbital-induced Gingival Hyperplasia

Ardeshir Lafzi, DDS, MSc; Ramin Mostofi Zadeh Farahani, DDS;
Mohammad Ali Mohajjel Shoja, MD



Abstract

Aim: The aim of this article is to present a case of a phenobarbital-induced gingival hyperplasia (GH), discuss possible etiological mechanisms of drug-induced GH, and to present a concise review of the literature.

Background: GH is a well-known complication associated with anticonvulsant phenytoin, antihypertensive calcium channel blockers, and immunosuppressant cyclosporine therapy. Sodium valproate and primidone has very rarely been found to cause GH.

Report: An extremely rare case of phenobarbital-induced GH in a 28-year-old male patient who had received this drug for three years is presented. The histological examination of the lesion revealed a hyperplastic epithelium, epithelial acanthosis, and elongated rete ridges as well as obviously enhanced dense collagenous fibers and proliferation of fibroblasts.

Summary: Phenobarbital-induced GH is a rare clinical entity which necessitates meticulous evaluation. However, it seems to show a benign behavior with reference to recurrence after surgical excision.

Keywords: hyperplasia, phenobarbital, pseudoepitheliomatous hyperplasia

Citation: Lafzi A, Farahani RMZ, Shoja MAM. Phenobarbital-induced Gingival Hyperplasia. J Contemp Dent Pract 2007 September; (8)6:050-056.

© Seer Publishing

Introduction

Gingival hyperplasia (GH) has an unpleasant appearance and renders a patient susceptible to periodontal disease due to the inhabitation of gingival sulcus with periopathogenic bacteria.¹ GH can be the result of a serious adverse drug reaction with potential clinical implications. Histologically, this lesion consists of dense collagenous fibers, acanthosis of the epithelial lining, elongated rete ridges, and sparse fibroblasts. Three main classes of drugs known to cause GH are anticonvulsants, antihypertensive calcium antagonists, and the immunosuppressant, cyclosporine. Phenytoin, primidone, and, very rarely, sodium valproate are among the potential inducers of GH. Phenobarbital-induced GH is an exceedingly rare condition; to our knowledge only one report exists in the literature to date.²

Case Report

Diagnosis

A 28-year-old male patient with epilepsy who had been treated successfully with phenobarbital (120 mg/day) for the past three years presented to the Department of Periodontics at the Tabriz University of Medical Sciences in Tabriz, Iran with a chief complaint of “enlarging gums.” The initial physical examination revealed a generalized and firm overgrowth of the gingiva throughout the maxillary and mandibular alveolar ridges. The overgrowth was more prominent on the buccal aspect of the maxillary arch with mild gingival inflammation present throughout the enlarged tissue (Figure 1).

General physical examination was otherwise unremarkable and hematological investigations were normal.

Gram staining of the gingival biopsy specimens showed several gram-positive cocci and bacilli. However, the culture was negative for any bacterial growth. Histological examination of the gingival biopsy revealed a hyperplastic epithelium (pseudoepitheliomatous hyperplasia), epithelial acanthosis, and elongated rete ridges. Obviously, enhanced dense collagenous fibers and a proliferation of fibroblasts were also present (Figure 2).

Given the history and histological findings, the gingival lesion was diagnosed as phenobarbital-induced gingival hyperplasia.

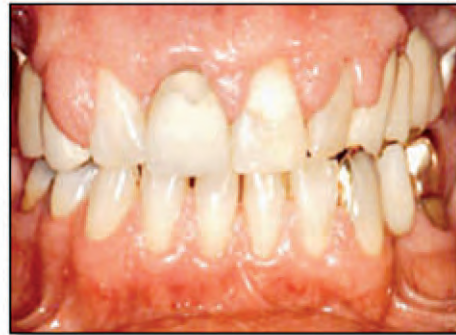

Figure 1. Clinical presentation of gingival hyperplasia.

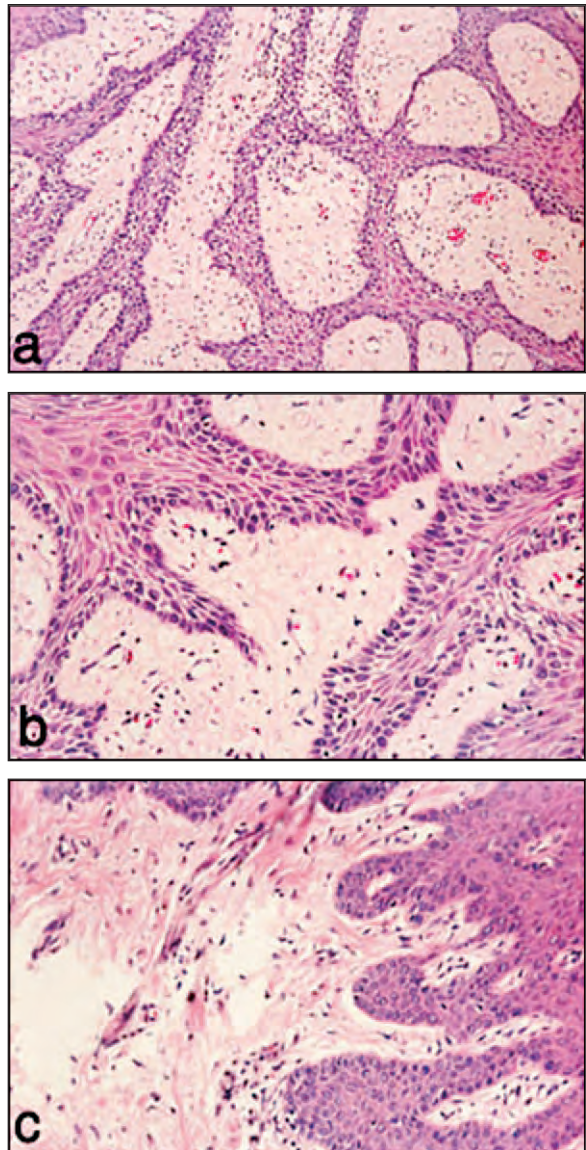


Figure 2. Photomicrographs of the hyperplastic lesion. Note the pseudoepitheliomatous hyperplasia and the nests of epithelium invaginating the underlying connective tissue.

Treatment

The patient underwent surgical excision of the hyperplastic gingiva and was trained in the use of vigorous oral hygiene measures. Despite the continued use of a low-dose phenobarbital regimen (100 mg/day), no recurrence of the gingival lesion was observed at a six-year follow-up examination.

Discussion

The present case is believed to be one of the two reports of phenobarbital-induced gingival hyperplasia. Sinha et al.² reported a case involving a young man who had developed progressive GH following an 11-year administration of phenobarbital (60-100 mg/day).² However, the patient had intermittently used several other drugs during that time period making the condition more complex.

GH has several adverse consequences. Cosmetic problems related to GH are a potential concern both for the patient and the clinician. The gross enlargement of gingiva may lead to the formation of new habitats due to the development of pocket/pseudopocket configurations of the tissue. This results in the formation of new habitats with a different gas phase (oxygen saturation),¹ fluid phase (gingival crevicular fluid characteristics),³ and solid phase (gingival tissue) characteristics, considered a favorable environment for certain periopathogenic bacteria.¹ An increase in the accumulation of bacterial plaque, infection, and bleeding are other probable consequences of GH.

Several mechanisms have been proposed for anticonvulsant-induced GH. The presence of phenytoin-sensitive or phenytoin-stable subpopulations of gingival fibroblasts may play a role in this phenomenon.^{4,5} Given the effect of phenytoin on the immune system, immunological reactions mediated by T-cells may be involved in the pathogenesis of anticonvulsant-induced GH.⁵ Also, drug-induced immunosuppression may be a contributing factor in the development of GH.⁶

Finally, the decrease in sodium flux and cellular folic acid uptake leading to a localized folate deficiency have been suggested as the underlying mechanisms.^{5,7} Dental plaque has also been heavily incriminated as a causative cofactor.⁵

The pseudoepitheliomatous hyperplasia (PEH) of the present lesion was an interesting finding. The epidermal growth factor (EGF) and transforming growth factor- α (TGF- α) are both the ligands of the EGF receptor (EGFR).⁸ Phenobarbital inhibits EGF binding to its receptor.⁹ This would lead to the increased binding of TGF- α which has a lower affinity than EGF to the EGFR. Furthermore, it has been shown the TGF- α is associated with the development of PEH.¹⁰ Taken together, we hypothesized phenobarbital induced the PEH through alteration of EGF/TGF- α ratio.

Summary

Phenobarbital-induced gingival hyperplasia is a quite rare clinical entity which necessitates meticulous evaluation. However, it seems to show a benign behavior with reference to recurrence after surgical excision.

References

1. Takada K, Sugiyama H, Umezawa K, Mega J, Hirasawa M. The subgingival microflora in phenytoin-induced gingival hyperplasia. *J Periodontol Res.* 2003;38(5):477-81.
2. Sinha S, Kamath V, Arunodaya GR, Taly AB. Phenobarbitone induced gingival hyperplasia. *J Neurol Neurosurg Psychiatry.* 2002;73(5):601.
3. Kuru L, Yilmaz S, Kuru B, Kose KN, Noyan U. Expression of growth factors in the gingival crevice fluid of patients with phenytoin-induced gingival enlargement. *Arch Oral Biol.* 2004;49(11):945-50.
4. Hassell T, Gilbert G. Phenytoin sensitivity of fibroblasts as the basis for susceptibility to gingival enlargement. *Am J Pathol* 1983;112:218-223.
5. Brown RS, Beaver WT, Bottomley WK. On the mechanism of drug-induced gingival hyperplasia. *J Oral Pathol Med* 1991;20:201-209.
6. Bardana EJ Jr, Gabourel JD, Davies GH, Craig S. Effects of phenytoin on man's immunity. Evaluation of changes in serum immunoglobulins, complement, and antinuclear antibody. *Am J Med* 1983;74:289-296.
7. Drew H, Vogel R, Molofsky W, Baker H, Frank O. Effect of folate on phenytoin hyperplasia. *J Clin Periodontol.* 1987;14:350-356.
8. Resat H, Ewald JA, Dixon DA, Wiley HS. An integrated model of epidermal growth factor receptor trafficking and signal transduction. *Biophys J.* 2003;85(2):730-43.
9. Jirtle RL, Meyer SA. Liver tumor promotion: effect of phenobarbital on EGF and protein kinase C signal transduction and transforming growth factor-beta 1 expression. *Dig Dis Sci.* 1991; 36(5):659-68.
10. Barkan GA, Paulino AF. Are epidermal growth factor and transforming growth factor responsible for pseudoepitheliomatous hyperplasia associated with granular cell tumors? *Ann Diagn Pathol.* 2003;7(2):73-7.

About the Authors

Ardeshir Lafzi, DDS, MSc

Dr. Lafzi is an Associate Professor in the Department of Periodontics of the School of Dentistry at the Tabriz University of Medical Sciences in Tabriz, Iran. His research interest is in periodontal tissue regeneration.

e-mail: ardeshir.lafzi@gmail.com

Mohammad Ali Mohajjel Shoja, MD

Dr. Shoja is a Research Assistant in the School of Medicine at the Tabriz University of Medical Sciences in Tabriz, Iran. His research interest is in microanatomical investigation of various tissues and neuroanatomy.

Ramin Mostofi Zadeh Farahani, DDS

Dr. Farahani is a Research Assistant in the School of Dentistry at the Tabriz University of Medical Sciences in Tabriz, Iran. His research interest is in the molecular and biological aspects of wound healing with reference to hard and soft tissues.