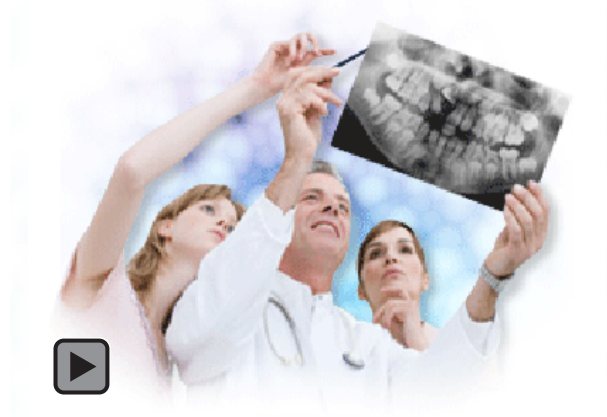

Maxillary Canine Impactions Related to Impacted Central Incisors: Two Case Reports

Mehmet Bayram, DDS, PhD; Mete Özer, DDS, PhD;
Ismail Sener, DDS, PhD



Abstract

Aim: The purpose of this case report is to describe the combined surgical and orthodontic treatment of two cases with an impacted maxillary central incisor and canine in the same quadrant and to discuss the causal relationship between them.

Background: The most common causes of canine impactions are usually the result of one or more factors such as a long path of eruption, tooth size-arch length discrepancies, abnormal position of the tooth bud, prolonged retention or early loss of the deciduous canine, trauma, the presence of an alveolar cleft, ankylosis, cystic or neoplastic formation, dilaceration of the root, supernumerary teeth, and odontomas. Although impaction of the maxillary central incisor is almost as prevalent as impacted canines its etiology is different. The principal factors involved in causing the anomaly are supernumerary teeth, odontomas, and trauma.

Reports: Case #1: A 10.5-year-old girl in the early mixed dentition stage presented with a chief complaint of the appearance of her anterior teeth. She had a Class I skeletal pattern and a history of trauma to the maxillary central incisors at age five with premature exfoliation. Radiographs revealed an impacted upper right central incisor in the region of the nasal floor, delayed eruption of the maxillary permanent central incisor, and the adjacent lateral incisor was inclined toward the edentulous space. Treatment was done in two stages consisting of surgical exposure and traction of the impacted central incisor and fixed orthodontic treatment.

Case #2: An 11.5-year-old girl presented for orthodontic treatment with the chief complaint of an unerupted tooth and the appearance of her upper anterior teeth. She was in the late mixed dentition period with a Class III

© Seer Publishing

skeletal pattern along with an anterior cross-bite with some maxillary transverse deficiency. The maxillary right canine and central incisor were absent, but the maxillary right deciduous canine was still present. Treatment included arch expansion followed by surgical exposure and traction of the impacted teeth and fixed orthodontic treatment.

Summary: This case report provides some evidence of a significant environmental influence of an impacted maxillary central incisor on the path of eruption of the ipsilateral maxillary canine. When an impacted maxillary central incisor exists, the maxillary lateral incisor's root might be positioned distally into the path of eruption of the maxillary canine preventing its normal eruption. Ongoing assessment and early intervention might help to prevent such adverse situations from occurring.

Keywords: Impacted central incisor, impacted canine, surgical exposure, orthodontic treatment

Citation: Bayram M, Özer M, Sener I. Maxillary Canine Impactions Related to Impacted Central Incisors: Two Case Reports. *J Contemp Dent Pract* 2007 September; (8)6:072-081.

Introduction

The causes of eruption disturbance and impaction of maxillary permanent canines have been of interest to researchers for many years. Maxillary canines require the longest period to develop, and they have the most difficult path of eruption compared to all of the other teeth.¹ The etiology of ectopic canines is obscure but probably multifactorial in nature. Both genetic²⁻⁷ and local factors⁸⁻¹³ have been shown to be intimately associated with this phenomenon which occurs in a small but significant percentage of most populations.^{9,14-16} The most common causes for canine impactions are usually localized and are the result of one or a combination of the factors listed in Table 1.

Although impaction of the maxillary central incisors is almost as prevalent^{17,18} in the general

population as impacted canines the etiology is quite different. The principal factors involved in causing the incisor anomaly include the presence of supernumerary teeth, odontomas, and dental trauma.¹⁹⁻²³

In impacted maxillary central incisor cases Chaushu et al.²⁴ observed distal displacement of the long axis of the lateral incisor on the radiographs of these patients which might have a secondary influence on the eruption pattern of the adjacent unerupted canine.

Maxillary canines and central incisors are the teeth most commonly requiring surgical exposure and orthodontic guidance during eruption. The diagnosis and treatment of this problem usually requires the expertise of a treatment team

Table 1. Common factors related to the cause of impaction of the maxillary permanent canines.

- Long path of eruption
- Discrepancies in tooth size-arch length ratio
- An abnormal position of the tooth bud
- Either the prolonged retention or early loss of the deciduous canine
- Local trauma
- The presence of an alveolar cleft
- Ankylosis
- Cystic or neoplastic formation
- Dilaceration of the root
- Presence of supernumerary teeth
- Presence of odontomas

including a general practitioner, pediatric dentist, oral surgeon, periodontist, and an orthodontist.

This report describes the combined surgical and orthodontic treatment of two cases with an impacted maxillary central incisor and a canine on the same side of the arch and provides a discussion of the causal relationship between these teeth.

Case #1

Diagnosis

A 10.5-year-old girl presented to a private orthodontic office with a history of trauma to the maxillary central incisors at age five reported by her parents. This was followed by premature exfoliation. The patient's chief complaint was the appearance of her anterior teeth.

The clinical and radiological examinations (Figures 1, 2, and 3) revealed she was in the early mixed dentition period with poor oral health along with a maxillary right impacted central incisor in the region of the nasal floor. The crown tip of the tooth was located palatally, and the apex of the root was located near the anterior nasal spine.

Eruption of the maxillary permanent central incisor was delayed, and the adjacent lateral incisor was inclined toward the edentulous space. Cephalometric evaluation confirmed a skeletal Class I malocclusion with 2 mm of overjet and a 25% overbite.

Treatment

The treatment plan consisted of surgical exposure and traction of the impacted central

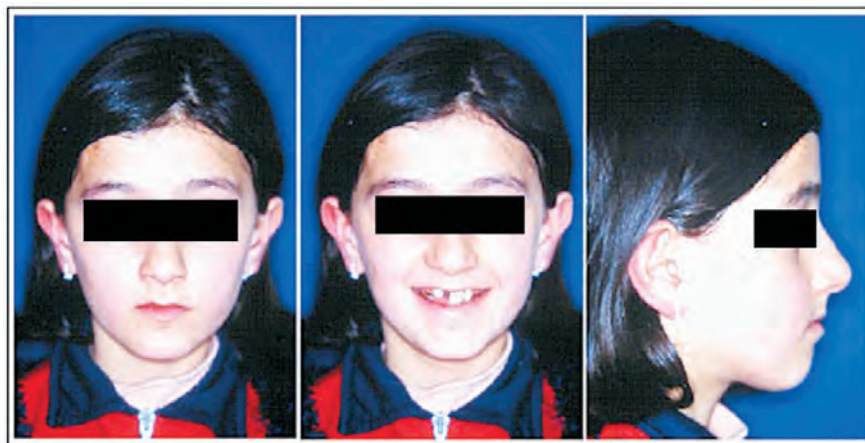

Figure 1. Pre-treatment facial photographs of Case #1.

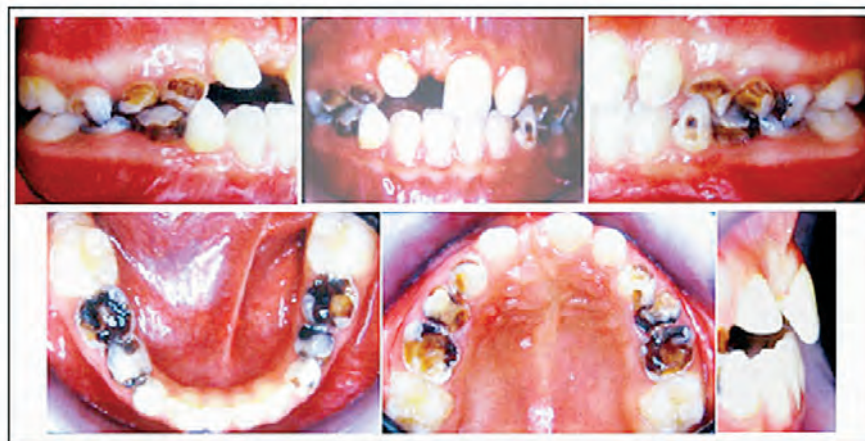

Figure 2. Pre-treatment intraoral photographs of Case #1.

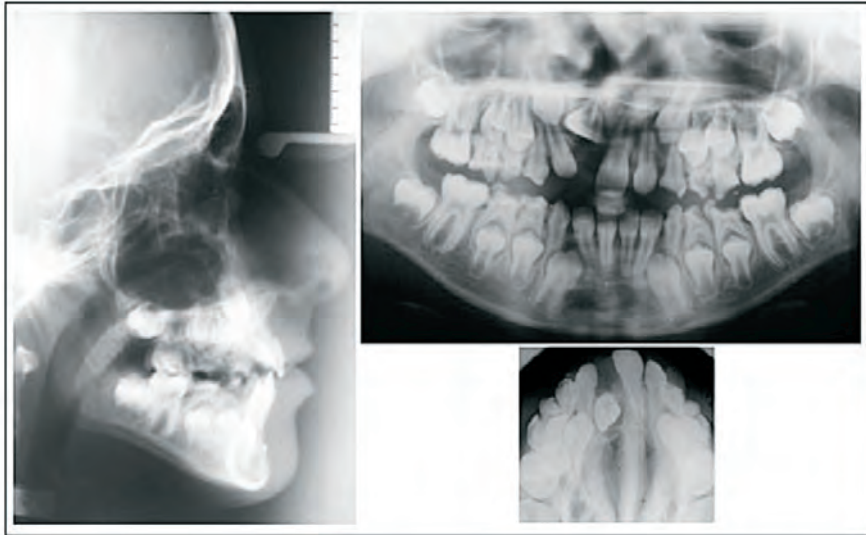

Figure 3. Pre-treatment panoramic, lateral cephalometric , and upper occlusal radiographs of Case #1.

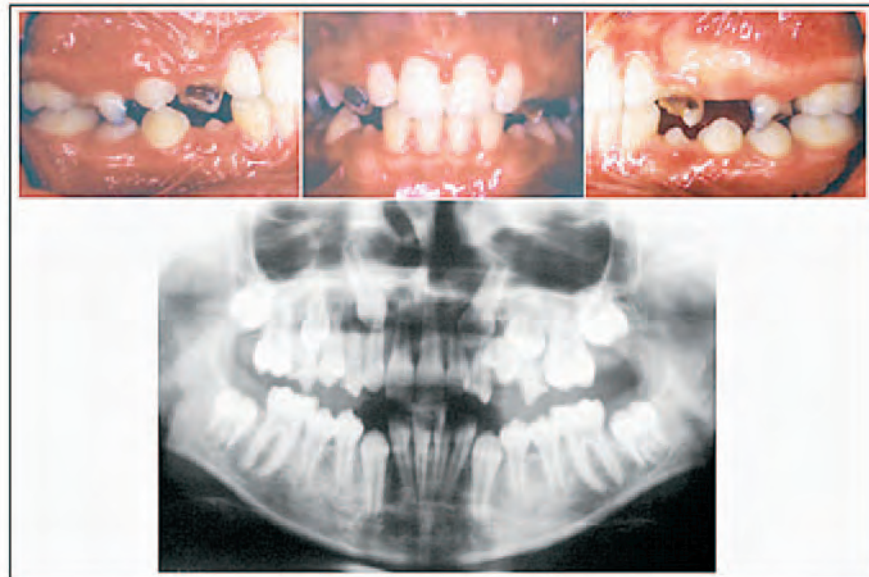

Figure 4. Intraoral photographs and panoramic radiograph of Case #1 at the end of first treatment phase.

incisor followed by fixed orthodontic treatment consisting of brackets on the incisors and bands on the molars in the upper arch. Monitoring of the eruption of the other permanent teeth would be performed periodically.

Initially an orthodontic attachment with a 0.010-inch ligature wire was bonded on the labial surface of the upper right impacted central incisor using a closed flap technique. An upper removable appliance with a high labial archwire was fabricated. A light force of approximately

40 to 60 grams was applied by 1/8 inch, 2.5 oz elastics between the ligature wire and the high labial archwire. Direction of force was adjusted occlusally and labially to guide the movement of the impacted central incisor into the correct position. At the end of six months of treatment, the central incisor had erupted into the oral cavity. At this stage the fixed appliance was applied to the upper arch to correct the angulation of the incisors. After the alignment of upper incisors, the orthodontic attachments were removed and a Hawley retainer inserted (Figure 4).

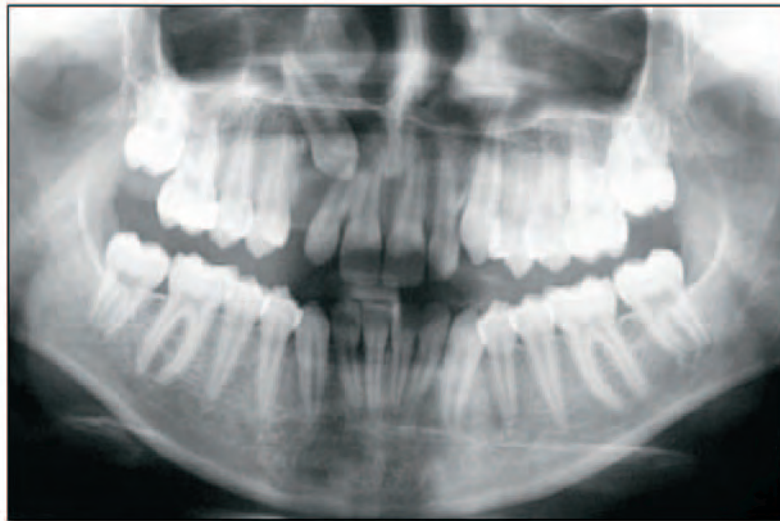

Figure 5. Panoramic radiograph of Case #1 at the end of the two-year follow-up examination.

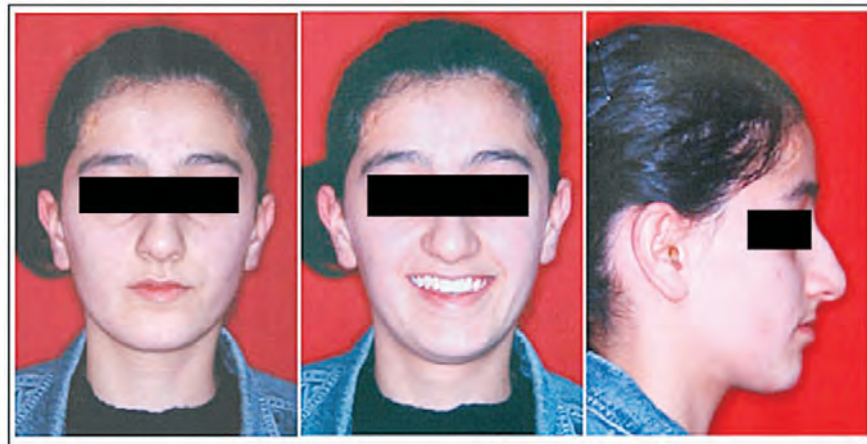

Figure 6. Post-treatment facial photographs of Case #1.

The two year follow-up radiological examination revealed the maxillary right canine was impacted in a vertical orientation with the crown located at the apex of the maxillary right lateral incisor (Figure 5).

At this point, surgical exposure of the impacted canine was carried out and a full fixed appliance was placed with orthodontic attachments in the upper and lower arches. Elastic power chains were used for alignment of the impacted canine, followed by a Ballista spring, a type of effective sectional arch wire, designed to pull palatally impacted maxillary canines forward in a vertical direction.

After approximately four years of treatment, the impacted central incisor and canine were aligned (Figures 6, 7, and 8).

Case #2

Diagnosis

An 11.5-year-old girl presented for orthodontic treatment with the chief complaint of an unerupted tooth and the appearance of her upper anterior teeth. The clinical examination revealed late mixed dentition stage with an anterior cross-bite and some maxillary transverse deficiency (Figures 9 and 10).

The maxillary right canine and central incisor were absent but the maxillary right deciduous canine was still present. The crowns of both impacted teeth (upper right central incisor and canine) could be palpated on the labial mucosa. An inadequate space distribution of the maxillary incisors caused

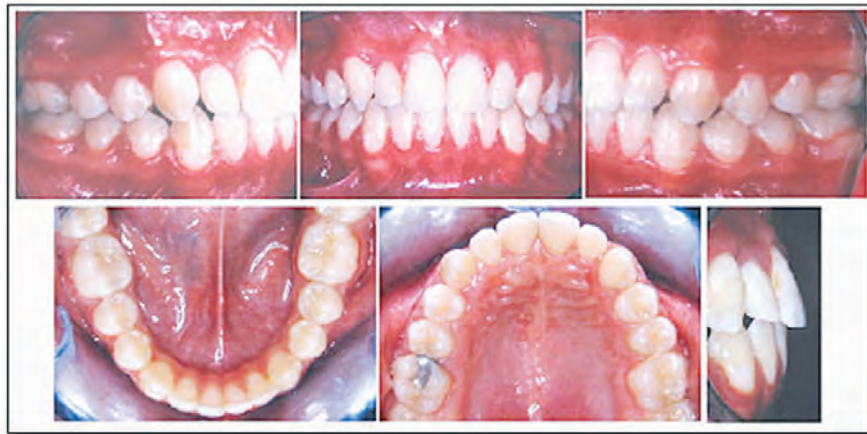

Figure 7. Post-treatment intraoral photographs of Case #1.

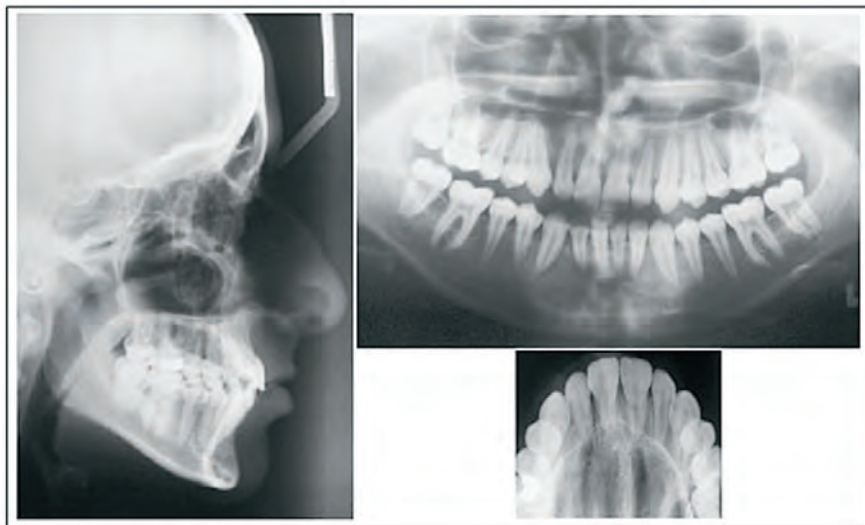

Figure 8. Post-treatment panoramic, lateral cephalometric, and upper occlusal radiographs of Case #1.

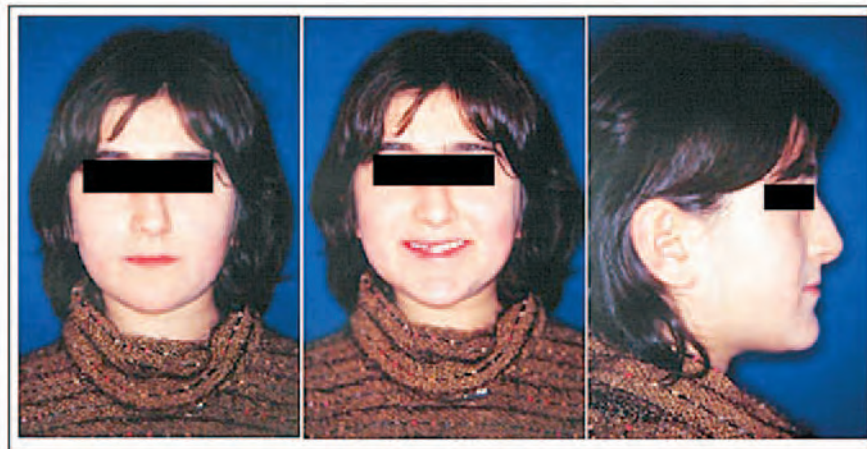

Figure 9. Pre-treatment facial photographs of Case #2.

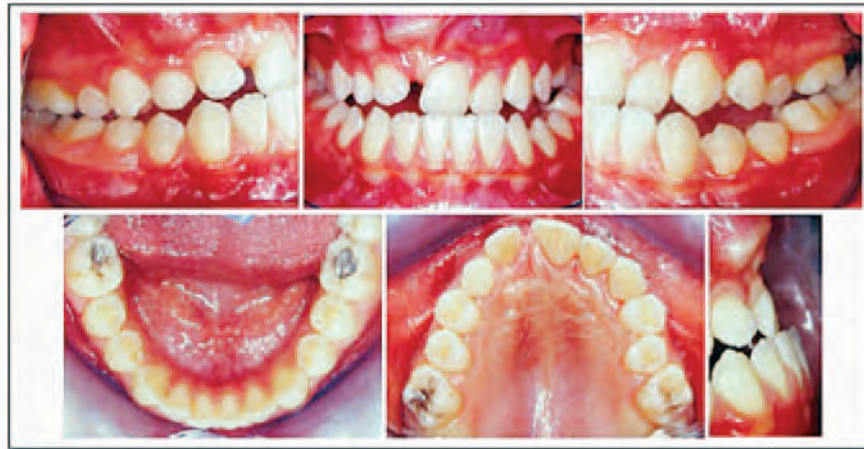

Figure 10. Pre-treatment intraoral photographs of Case #2.

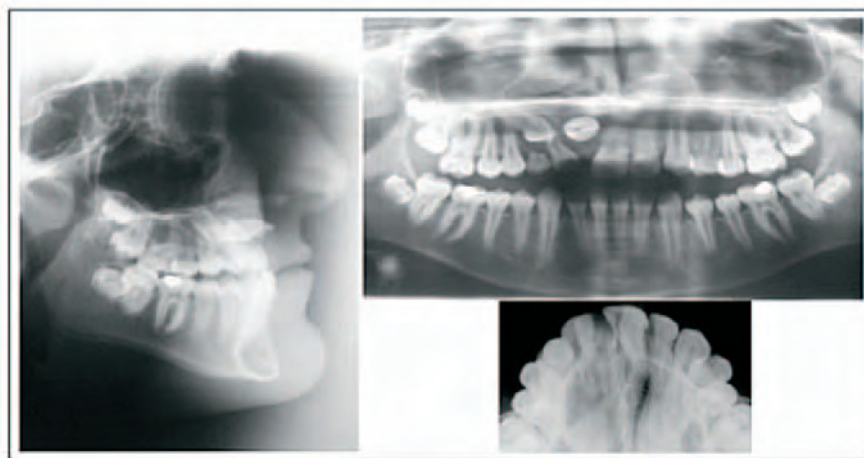

Figure 11. Pre-treatment panoramic, lateral cephalometric, and upper occlusal radiographs of Case #2.

a severe midline deviation as a result of drifting of the adjacent teeth into the edentulous space.

The panoramic radiograph revealed the impaction of the maxillary right central incisor and right canine. The impacted canine was positioned mesially with the tip of crown close to the apex of the right lateral incisor, and the impacted central incisor was positioned horizontally (Figure 11). The crown of the impacted central incisor was located below the anterior nasal spine and its apex was located palatally. Cephalometric evaluation revealed a skeletal Class III pattern and -2 mm overjet.

Treatment

The first step in the treatment plan was to expand the maxillary arch with rapid palatal expansion to correct the transverse constriction and to gain

space for the impacted central incisor. Next, fixed orthodontic appliances were to be placed in both arches followed by the surgical exposure of the impacted teeth and the placement of orthodontic attachments. The patient was informed of the potential risk of a failed response of the impacted teeth to orthodontic treatment which could result in extraction of the impacted teeth. Prosthetic rehabilitation with an implant or bridgework would then be required later when growth had ceased.

The maxillary arch was expanded with a Hyrax type expansion appliance using two quarter turns per day until the required expansion was achieved. Then the fixed orthodontic appliances were placed in both arches. At the completion of the leveling and alignment phase, NiTi open-coil springs were used to open the space for the impacted central and canine. Once adequate

space was achieved the patient was referred to an oral surgeon for exposure of the impacted teeth.

The surgeon raised a wide mucoperiosteal flap similar to the closed-eruption technique described in by Vermette et al.²⁵ Orthodontic attachments with a 0.010-inch ligature wire were bonded to the labial surface of the impacted incisor and canine during surgical exposure. The flap was closed and sutured, leaving the tied ligature wires with a hook end protruding through the mucosa. The patient returned one week later to begin orthodontic traction of the impacted teeth.

A light force of approximately 40 to 60 g was applied to the impacted central by an elastomeric chain between the 0.019 x 0.025-inch stainless steel main arch wire and the protruding ligature wire. During the orthodontic traction of the

impacted canine an auxiliary spring was used. As the impacted teeth moved downward, the ligature wires were cut shorter to maintain the effective forces. Approximately six months later, the attached buttons were then removed and a standard incisor and canine bracket were bonded so the teeth could be properly positioned.

The treatment was completed within 24 months (Figures 12, 13, and 14). The bands and brackets were removed and replaced with a maxillary Hawley retainer and a lower fixed lingual retainer.

Discussion

Impaction is defined as the total or partial lack of eruption of a tooth well after the normal age for eruption. An impacted tooth may appear blocked by another tooth, bone, or soft tissue, but the cause of tooth impaction is often unknown.²⁶

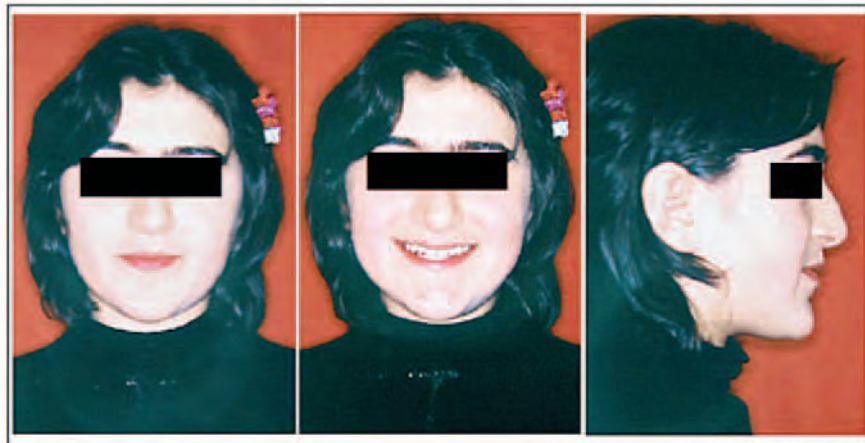

Figure 12. Post-treatment facial photographs of Case #2.

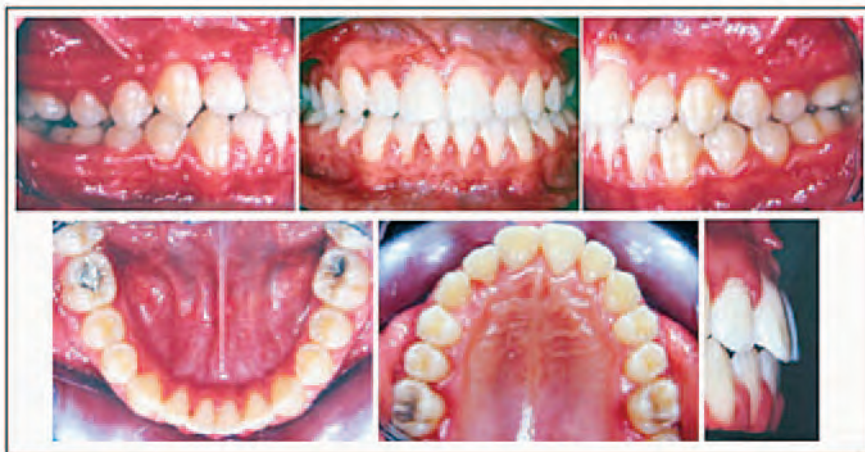

Figure 13. Post-treatment intraoral photographs of Case #2.

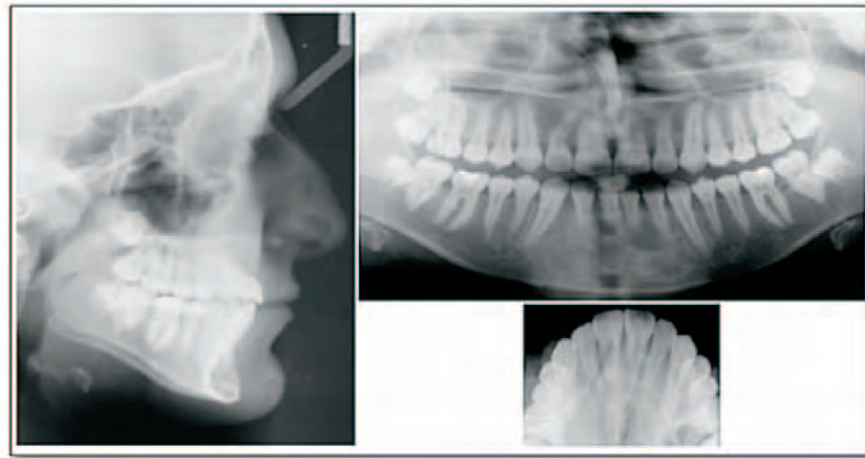


Figure 14. Post-treatment panoramic, lateral cephalometric, and upper occlusal radiographs of Case #2.

Impacted teeth can cause serious dental and esthetic difficulties as well as psychological problems especially in the anterior part of maxilla. Although the impaction of the maxillary incisor occurs less frequently than the maxillary canine, it raises concerns for parents because of the cosmetic deficit associated with the non-eruption of the tooth.²⁷ Other than third molars, the maxillary canines and the central incisors are the most likely to remain unerupted or impacted. They are also the teeth most commonly requiring surgical exposure and orthodontic guidance during eruption.^{1,27,28}

Chaushu et al.²⁴ state when a maxillary central incisor becomes impacted from obstruction, dilaceration, trauma, or other cause (nonspecific), there is a high probability (41.3%) the canine on the side of the impaction will be displaced compared with the canine on the other side (1.6%). When there is an impacted central incisor, their data show the adjacent lateral incisor root is displaced distally by a mean of 5 mm compared with the contralateral lateral incisor's normally positioned root. Therefore, the lateral incisor alters its (desirable) relationship with the adjacent canine at a very critical stage of the latter's development. An environment is created in which the lateral incisor root can become an obstacle leading to an alteration in the mesial or buccal position of the canine.

Wasserstein et al.²⁶ also described an impacted maxillary central incisor and incomplete transposition between the canine and the lateral

incisor and related these anomalies to an earlier traumatic event. At the beginning of the treatment, in both cases in this study, the maxillary lateral incisor's root was positioned distally on the path of eruption of the ipsilateral maxillary canine. We suggest this situation obstructed the eruption of the maxillary canine and caused its impaction.

The problem of an impacted maxillary incisor resulting in space deficit in the anterior region of the early mixed dentition stage is usually a clinical challenge for orthodontists. Recent reports have shown impacted canines or incisors can be properly positioned using direct orthodontic traction instead of surgical extraction.^{26,29-32} The treatment approach of impacted maxillary teeth requires the cooperation of dental specialties such as orthodontics, oral surgery, and prosthodontics. Rather than extraction our treatment of choice is to use surgical crown exposure with the placement of an auxiliary orthodontic attachment followed by orthodontic positioning of the tooth.

Anomalies of maxillary canine position are frequently described in the orthodontic literature. The debate on the cause of this phenomenon is the secondary purpose of this article. However, the uniqueness of this case report is the presence of a combination of canine impaction along with maxillary central incisor impaction. The treatment success in these cases is the result of mutual efforts of the orthodontist, the oral surgeon, and the patients.

The cases presented here show multiple tooth malpositions such as labial impaction of the canines with horizontally impacted maxillary central incisors. The apex of the impacted central was near the anterior nasal spine in one case and located palatally in the other case with no root dilaceration. One possible explanation in these cases for some of these dental anomalies is the earlier dental trauma involving intrusion of one or more deciduous teeth when the patients were younger. However, the argument the trauma worsened an already existing dental abnormality cannot be ruled out.

In the literature two basic approaches described as open (apically positioned flap) and closed-eruption techniques are used in the surgical exposure of impacted teeth.²⁵ The closed-eruption technique is believed by some to be the best method of uncovering labially impacted teeth. This is especially true if the tooth is located high above the mucogingival junction or deep in the alveolus where an apically positioned flap may be difficult or impossible to use successfully.³³⁻³⁶ Some clinicians believe the closed-eruption method replicates natural tooth eruption and, therefore, produces the best esthetic and periodontal results.³³ Vermette et al.²⁵ compared

these two surgical techniques and found the apically positioned flap technique had more negative esthetic effects such as increased crown length and gingival scars than the closed-eruption technique. Therefore, the closed-eruption technique was performed in the surgical exposure of all impacted teeth reported in the two cases here. In these cases, the periodontal status of the exposed incisors and canines after orthodontic treatment revealed an acceptable gingival contour and attached gingiva. Bringing the unerupted or impacted maxillary teeth into normal alignment should not be the only goal in managing these cases. The aim should be to attain proper occlusion, a healthy zone of attached gingiva, and ideal alveolar bone height.

Summary

This case report provides some evidence of a significant environmental influence of an impacted maxillary central incisor on the path of eruption of the ipsilateral maxillary canine. When an impacted maxillary central incisor exists, the maxillary lateral incisor's root might be positioned distally into the path of eruption of the maxillary canine preventing its normal eruption. Ongoing assessment and early intervention might help to prevent such adverse situations from occurring.

References

1. Jacoby H. The etiology of maxillary canine impactions. *Am J Orthod* 1983;84:125-32.
2. Becker A, Sharabi S, Chaushu S. Tooth size variation in dentitions affected by palatal canine displacement. *Eur J Orthod* 2002;24:313-8.
3. Chaushu S, Sharabi S, Becker A. Dental morphologic characteristics of normal versus delayed developing dentitions with palatally displaced canines. *Am J Orthod Dentofacial Orthop* 2002;121:339-46.
4. Langberg BJ, Peck S. Tooth-size reduction associated with occurrence of palatal displacement of canines. *Angle Orthod* 2000;70:126-8.
5. Pirinen S, Arte S, Apajalahti S. Palatal displacement of canine is genetic and related to congenital absence of teeth. *J Dent Res* 1996;75:1742-6.
6. Peck S, Peck L, Kataja M. The palatally displaced canine as a dental anomaly of genetic origin. *Angle Orthod* 1994;64:249-56.
7. Peck L, Peck S, Attia Y. Maxillary canine-first premolar transposition, associated dental anomalies and genetic basis. *Angle Orthod* 1993;63:99-109.
8. Miller BH. The influence of congenitally missing teeth on the eruption of the upper canine. *Dent Pract Dent Rec* 1963;13:497-504.
9. Thilander B, Jacobson SO. Local factors in impaction of maxillary canines. *Acta Odont Scand* 1968;26:145-68.
10. Becker A, Smith P, Behar R. The incidence of anomalous maxillary lateral incisors in relation to palatally displaced cuspids. *Angle Orthod* 1981;51:24-9.
11. Becker A. Etiology of maxillary canine impaction. *Am J Orthod* 1984;86:437-8.
12. Becker A, Gillis I, Shpack N. The etiology of palatal displacement of maxillary canines. *Clin Orthod Res* 1999;2:62-6.

13. Becker A, Chaushu S. Dental age in maxillary canine ectopia. *Am J Orthod Dentofacial Orthop* 2000;117:657-62.
14. Dachi SF, Howell FV. A survey of 3874 routine full-mouth radiographs II. A study of impacted teeth. *Oral Surg Oral Med Oral Pathol* 1961;14:1165-9.
15. Brin I, Becker A, Shalhav M. Position of the maxillary permanent canine in relation to anomalous or missing lateral incisors: a population study. *Eur J Orthod* 1986; 8:12 -6.
16. Oliver RG, Mannion JE, Robinson JM. Morphology of the lateral incisor in cases of unilateral impaction of the canine. *Br J Orthod* 1989;19:9-16.
17. Brin I, Zilberman Y, Azaz B. The unerupted maxillary central incisor: review of its etiology and treatment. *J Dent Child* 1982;43:352-6.
18. Tai F, Pang A, Yuen S. Unerupted maxillary anterior supernumerary teeth: report of 204 cases. *J Dent Child* 1984;51:289-94.
19. Zilberman Y, Malron M, Shteyer A. Assessment of 100 children in Jerusalem with supernumerary teeth in the premaxillary region. *J Dent Child* 1992;59:44-7.
20. Day RCB. Supernumerary teeth in the premaxillary region. *Br Dent J* 1964;116:304-8.
21. DiBiase DD. The effects of variations in tooth morphology and position on eruption. *Dent Pract Dent Rec* 1971;22:95-108.
22. Munns D. Unerupted incisors. *Br J Orthod* 1981; 8:39 -42.
23. Mitchell L, Bennett TG. Supernumerary teeth causing delayed eruption—a retrospective study. *Br J Orthod* 1992; 19:41 -6.
24. Chaushu S, Zilberman Y, Becker A. Maxillary incisor impaction and its relationship to canine displacement. *Am J Orthod Dentofacial Orthop* 2003;124:144-50.
25. Vermette ME, Kokich VG, Kennedy DB. Uncovering labially impacted teeth: apically positioned flap and closed-eruption techniques. *Angle Orthod* 1995;65:23-34.
26. Wasserstein A, Tzur B, Brezniak N. Incomplete canine transposition and maxillary central incisor impaction—a case report. *Am J Orthod Dentofacial Orthop* 1997;111:635-9.
27. Bishara SE. Impacted maxillary canines: a review. *Am J Orthod Dentofacial Orthop* 1992;101:159-71.
28. Fournier A, Turcotte J, Bernard C. Orthodontic considerations in the treatment of maxillary impacted canines. *Am J Orthod* 1982;81:236-9.
29. Lin YTJ. Treatment of an impacted dilacerated maxillary central incisor. *Am J Orthod Dentofacial Orthop* 1999;115:406–409.
30. Kolokithas G, Karakasis D. Orthodontic movement of dilacerated maxillary central incisor. *Am J Orthod* 1979;76:310–315.
31. Tanaka E, Watanabe M, Nagaoka K, Yamaguchi K, Tanne K. Orthodontic traction of an impacted maxillary central incisor. *J Clin Orthod* 2001;35:375–378.
32. Suri S, Utreja A, Rattan V. Orthodontic treatment of bilaterally impacted maxillary canines in an adult. *Am J Orthod Dentofacial Orthop* 2002;429:429-37.
33. Crescini A, Clauser C, Giorgetti R, Cortellini P, Pini Prato GP. Tunnel traction of infraosseous impacted maxillary canines. A three-year periodontal follow-up. *Am J Orthod Dentofacial Orthop* 1994;105:61–72.
34. Fournier A, Turcotte J, Bernard C. Orthodontic considerations in the treatment of maxillary impacted canines. *Am J Orthod* 1982;81:236–239.
35. Hunter S. Treatment of the unerupted maxillary canine. *Br Dent J* 1983;154:294–296.
36. Wong-Lee T, Wong F. Maintaining an ideal tooth-gingiva relationship when exposing and aligning an impacted tooth. *Br J Orthod* 1985;12:189–192.

About the Authors

Mehmet Bayram, DDS, PhD



Dr. Bayram is in private practice in Samsun, Turkey. He received his dental degree from the Faculty of Dentistry at the University of Hacettepe in Ankara. He received his PhD degree in 2005 from the Faculty of Dentistry at Ondokuz Mayıs University in Samsun. Dr. Bayram is a member of the European Orthodontic Society and the Turkish Orthodontic Society.

e-mail: dtmehmetbayram@yahoo.com

Mete Özer, DDS, PhD



Dr. Özer is an Assistant Professor in the Department of Orthodontics of the Faculty of Dentistry at Ondokuz Mayıs University in Samsun, Turkey. He received his dental degree from the Faculty of Dentistry at the University of Hacettepe in Ankara. Dr. Özer received his PhD degree in 1999 from the Faculty of Dentistry at Ondokuz Mayıs University in Samsun. He is a member of the European Orthodontic Society and the Turkish Orthodontic Society.

e-mail: meteozer@omu.edu.tr

Ismail Sener, DDS, PhD



Dr. Sener is a Research Assistant in the Department of Oral and Maxillofacial Surgery of the Faculty of Dentistry at Ondokuz Mayıs University in Samsun, Turkey. He is a member of the Turkish Oral and Maxillofacial Surgery Society.

e-mail: lsener@omu.edu.tr