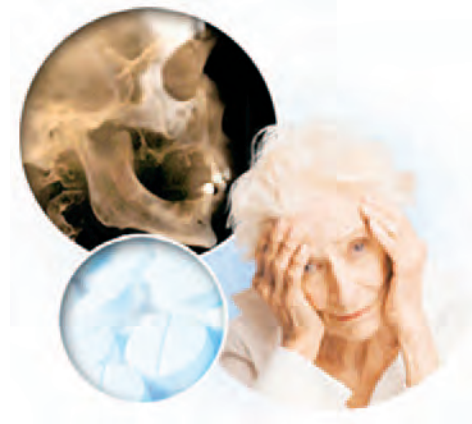

## Osteonecrosis of the Jaws Secondary to Bisphosphonate Therapy: A Case Series

Satish K. S. Kumar, BDS, MSc; Michael C. Meru, BS, (DDS);  
Parish P. Sedghizadeh, DDS, MS



### Abstract

**Aim:** The objective of this report is to present the clinical experiences of several patients affected with osteonecrosis (ONJ) secondary to bisphosphonate (BP) therapy and to provide a discussion of the specific BPs implicated in this condition.

**Background:** ONJ secondary to BP therapy is becoming an increasingly reported complication following dental therapy. This is particularly true of surgical dental procedures such as extractions. BPs are a class of pharmaceuticals used in the treatment of numerous disorders affecting bone, including osteoporosis, cancer metastases to bone, hypercalcemia of malignancy, and multiple myeloma. Although ONJ is a more recently described phenomenon, it is an emerging problem that may be associated with significant morbidity such as oral dysfunction, impaired eating ability, pain, and compromised esthetics resulting in a poor quality of life in affected patients.

**Case Report:** This is a description of 13 patients affected with ONJ secondary to BP therapy managed at the Orofacial Pain & Oral Medicine Center, Special Patients Clinic, and Oral and Maxillofacial Surgery Clinic at the University of Southern California, School of Dentistry between October 2005 and April 2007, with a discussion of the specific BPs implicated in this condition, the clinical presentation, management, and follow-up.

**Summary:** Thorough reporting of every case of ONJ is important to help advance the understanding of this poorly understood condition. The authors' approach to care represents a more conservative mode to management than previously described by many investigators.

© Seer Publishing

**Keywords:** Bisphosphonates, BPs, diphosphonates, osteonecrosis, ONJ, jaws

**Citation:** Kumar SKS, Meru MC, Sedghizadeh PP. Osteonecrosis of the Jaws Secondary to Bisphosphonate Therapy: A Case Series. *J Contemp Dent Pract* 2008 January;(9)1:063-069.

## Introduction

Bisphosphonates (BPs) are a class of pharmaceuticals used in the treatment of numerous disorders that affect bone, including osteoporosis, cancer metastases to bone, hypercalcemia of malignancy, and multiple myeloma.<sup>1</sup> The Food and Drug Administration (FDA) began approving BPs for clinical use in 1991. The drugs are formulated to be delivered by intravenous or oral routes of administration as shown in Table 1. BPs are effective for the following:

1. Treatment of refractory bone pain and prevention of skeletal events in metastatic cancers.<sup>2</sup>
2. Reduction of pathologic vertebral fractures and pain.<sup>3,4</sup>
3. Prevention and treatment of corticosteroid-induced bone loss at the lumbar spine and femoral neck.<sup>5</sup>

Recent evidence indicates BPs also have direct anti-cancer effects.<sup>6</sup> BP medications considerably improve patient quality of life and help attenuate the morbidity or prevent the mortality that may be associated with osteoporosis-related fractures. However, the optimal dosing and initiation of BP therapy and appropriate duration of treatment remains uncertain.<sup>7</sup>

BPs have a high affinity for bone and demonstrate anti-osteoclastic and anti-angiogenic properties, thereby, affecting osseous remodeling where they aggregate in bone. BPs currently share numerous pharmacologic properties such as the following:<sup>8-11</sup>

1. They form strong bonds with hydroxyapatite crystals concentrating selectively in bone.
2. They are potent inhibitors of osteoclastic activity suppressing osteoclast-mediated bone resorption.
3. They clear rapidly from the circulation; when excreted in urine, they are unmetabolized.
4. They are notably persistent drugs

accumulating over extended periods of time in mineralized bone matrix, remaining in the body for years; for example, the estimated half-life for alendronate is up to 12 years.

Over the 16-year period of BP use since approval by the FDA, numerous side effects have surfaced. Adverse effects of BPs include gastrointestinal tract intolerance, symptomatic hypocalcemia, bone stress fractures, influenza-like illness, myalgia, deterioration of renal function (especially those on nephrotoxic drugs), renal failure, acute tubular necrosis, esophageal erosions and ulcerations, and anti-angiogenic effects. Despite the list of side effects, their prevalence is low and toxicologic animal studies have revealed little toxicity.<sup>1,6,11-14</sup> Since 2003, there have been more than 2000 reports of BP-associated osteonecrosis (ONJ) affecting exclusively the jaw bones.<sup>15</sup> Most cases are associated with nitrogen-containing BPs as compared to non-nitrogen BPs. The FDA now requires a precaution regarding ONJ on package inserts for all nitrogen-containing BPs. The estimated prevalence of ONJ is high (6-10%) in cancer patients receiving intravenous BP therapy but much lower (<1%) for patients on oral BP therapy.<sup>11,12,16</sup>

## Case Report (A Series)

In this case series 13 patients affected with ONJ secondary to BP therapy managed at the Orofacial Pain & Oral Medicine Center, Special Patients Clinic, and Oral and Maxillofacial Surgery Clinic at the University of Southern California, School of Dentistry (Los Angeles, CA, USA) between October 2005 and April 2007 is reported. At the time of initial presentation, all the patients had been or were currently under treatment with BPs for systemic diseases not involving oral/dental tissues; two patients had multiple myeloma, one had breast cancer, one had prostate cancer, and nine had osteoporosis.

The patients with breast and prostate cancer had been previously diagnosed with advanced stage

**Table 1. BP medications approved by the FDA.**

Generic Name	Brand Name	Formulation	Manufacturer	Nitrogen-containing	FDA-approval
Alendronate	Fosamax <sup>®</sup>	Oral	Merck & Co.	Yes	1995
Etidronate	Didrone <sup>®</sup>	Oral/IV	Procter & Gamble	No	1977
Ibandronate	Boniva <sup>®</sup>	Oral	Roche	Yes	2005
Pamidronate	Aredia <sup>®</sup>	IV	Novartis	Yes	1991
Risedronate	Actonel <sup>®</sup>	Oral	Procter & Gamble	Yes	1998
Tiludronate	Skelid <sup>®</sup>	Oral	Sanofi	No	1997
Zoledronic Acid	Zometa <sup>®</sup>	IV	Novartis	Yes	2001

Adapted from Ruggiero et al.<sup>18</sup>

disease with skeletal metastases not involving the jaw bones. The mean patient age at the time of presentation was 72.3 years, with a range of 63–80 years. The male-to-female ratio is 1:3.3 (3 males and 10 females). The following information was recorded for every patient: (Table 2)

- Type of BP used
- Medical condition being treated
- Duration of use
- Other medical and co-morbid conditions
- Location of ONJ
- Inciting factors such as previous dental extractions or dental trauma to the site.

Radiographs obtained for all patients included panoramic X-rays, while selected patients also received cone-beam CT scans if conventional radiographs showed extensive disease or if symptoms were described by patients in areas of the jaws without clinically identifiable abnormal change. Radiographic findings generally demonstrated ill-defined lytic change with bony sequestrum (necrotic bone) and no signs of malignancy.

Patients with multiple myeloma and breast cancer had received treatment with zoledronic acid, the patient with prostate cancer was treated with pamidronate, while all of the patients with

osteoporosis were treated with alendronate. The duration of BP therapy ranged from eight months to 48 months (average 29 months) in IV form once a month for the four cancer patients and 12 months to 120 months (average 54.6 months) in oral (PO) form once a week for the nine patients with osteoporosis.

The inciting factor in the development of ONJ was denture trauma in six cases, tooth extraction in six cases, and both denture trauma and tooth extraction in one case. Nine patients (69.2%) had only mandibular involvement; three (23.1%) had only maxillary involvement, while one patient (7.7%) had both maxillary and mandibular involvement.

Four of the cases are of particular interest. The first is patient #3, a 71-year-old African-American male who received zoledronic acid for 24 months for multiple myeloma. Although diagnosed with this malignancy, he had several co-morbid conditions such as hypertension, hyperthyroidism, depression, and schizophrenia. Due to his psychiatric illness and poor compliance, he had been wearing his complete maxillary and partial mandibular denture for almost a year without removal, which had resulted in severe ONJ involving the entire maxilla (Figures 1 and 2) and most of the mandible.

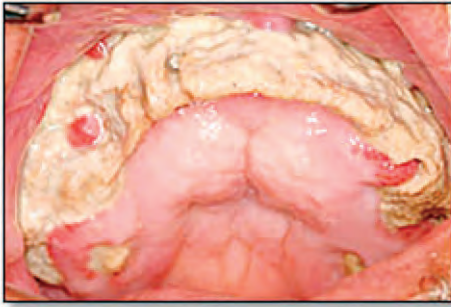**Table 2. Clinico-pathologic parameters in patients with ONJ secondary to BP therapy.**

Patient	Age/ Sex	Ethnicity	Medical condition for bisphosphonate intake	Other medical & co-morbid conditions	BP administered	Duration	Predisposing Dental Procedure	Location of osteonecrosis	Treatment
#1	75/F	Asian- American	Breast cancer	Chemotherapy, radiotherapy, hypertension	Zoledronic acid 4mg IV once/ month	48 months	Tooth Extraction & Denture Trauma	Right & left mandible	Antibiotics, local debridement, spontaneous sequestration, daily chlorhexidine mouth rinsing
#2	67/M	Hispanic- American	Prostate cancer	Steroid therapy for chronic adrenal insufficiency, chemotherapy, anemia	Pamidronate 90mg IV once/ month	36 months	Tooth Extraction	Left maxilla	Antibiotics, local debridement, spontaneous sequestration, daily chlorhexidine mouth rinsing
#3	71/M	African- American	Multiple myeloma	Hypertension, hyperthyroidism, schizophrenia, depression	Zoledronic acid 4mg IV once/ month	24 months	Denture Trauma	Entire maxilla & mandible	Antibiotics, local debridement, sequestrectomies, daily chlorhexidine mouth rinsing
#4	68/M	African- American	Multiple myeloma	Type II diabetes, hypertension, dyslipidemia, osteoarthritis	Zoledronic acid 4mg IV once/ month	8 months	Tooth Extraction	Right mandible	Antibiotics, local debridement, daily chlorhexidine mouth rinsing, soft stent to cover bone exposure
#5	73/F	Asian- American	Osteoporosis	Hypertension, hypercholesterolemia, osteoarthritis, gastroesophageal reflux disease	Alendronate 70mg PO once/ week	36 months	Denture Trauma	Left mandible	Daily chlorhexidine mouth rinsing
#6	80/F	Asian- American	Osteoporosis	Type II diabetes, osteoarthritis, stroke, heart stent	Alendronate 70mg PO once/ week	120 months	Denture Trauma	Left maxilla	Discontinuation of alendronate, Antibiotics, local debridement, daily chlorhexidine mouth rinsing
#7	74/F	Asian- American	Osteoporosis	Peptic ulcer	Alendronate 70mg PO once/ week	60 months	Denture Trauma	Right mandible	Antibiotics, local debridement, daily chlorhexidine mouth rinsing
#8	75/F	Hispanic- American	Osteoporosis	Hypercholesterolemia, hypothyroidism	Alendronate 70mg PO once/ week	36 months	Denture Trauma	Right & left mandible	Antibiotics, daily chlorhexidine mouth rinsing
#9	79/F	Asian- American	Osteoporosis	Type II Diabetes, Hypertension, hypercholesterolemia	Alendronate 70mg PO once/ week	60 months	Tooth Extraction	Right mandible	Discontinuation of alendronate, Antibiotics, local debridement, daily chlorhexidine mouth rinsing

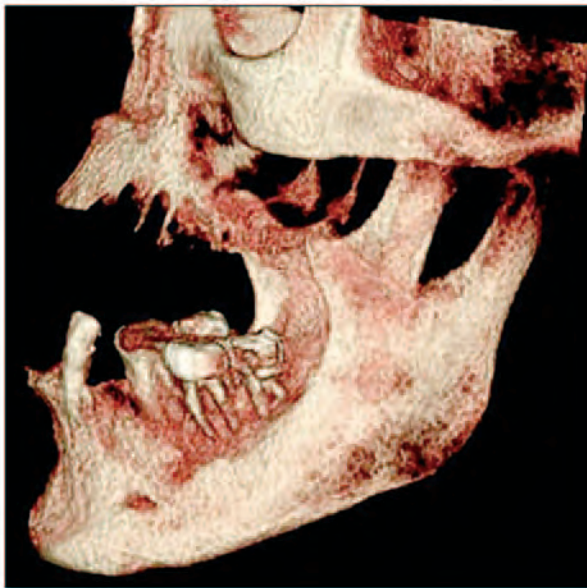
**Table 2. Clinico-pathologic parameters in patients with ONJ secondary to BP therapy.**

Patient	Age/ Sex	Ethnicity	Medical condition for bisphosphonate intake	Other medical & co-morbid conditions	BP administered	Duration	Predisposing Dental Procedure	Location of osteonecrosis	Treatment
#10	63/F	Hispanic- American	Osteoporosis	Hypertension, chemotherapy and steroid therapy for rheumatoid arthritis	Alendronate 70mg PO once/ week	36 months	Denture Trauma	Right maxilla	Discontinuation of alendronate Antibiotics, sequestrectomy, local debridement, daily chlorhexidine mouth rinsing
#11	74/F	Asian- American	Osteoporosis	Hypertension, hypercholesterolemia	Alendronate 70mg PO once/ week	12 months	Tooth Extraction	Right mandible	Discontinuation of alendronate Antibiotics, sequestrectomy, local debridement, daily chlorhexidine mouth rinsing
#12	76/F	Asian- American	Osteoporosis	Cancers (ovary, uterus, colon, liver), chemotherapy, hypertension, asthma	Alendronate 70mg PO once/ week	120 months	Tooth Extraction	Left mandible	Discontinuation of alendronate, partial sequestrectomy, local debridement, daily chlorhexidine mouth rinsing
#13	65/F	Asian- American	Osteoporosis	Hypertension, hypercholesterolemia	Alendronate 70mg PO once/ week	12 months	Tooth Extraction	Left mandible	Local debridement, daily chlorhexidine mouth rinsing





**Figure 1.** Extensive ONJ of the upper jaw in patient #3 showing nothing but maxillary skeleton coated with white plaque-like debris in addition to a reactive granulation tissue-like response involving the palate.



**Figure 2.** A three-dimensional reconstruction of the cone-beam CT scan demonstrates the extensive bony destruction of the mandible and maxilla. The maxillary involvement extends to the maxillary sinus while the mandibular involvement extends inferiorly to the level of the mental foramen.

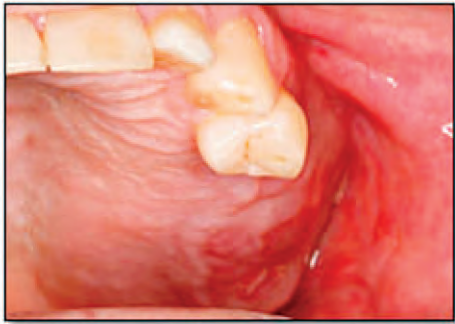The second case is patient #6, who is an 80-year-old Asian-American female diagnosed with osteoporosis and was taking alendronate orally once weekly for nearly ten years (120 months). The patient presented with ONJ in the left maxillary quadrant with an oro-antral fistula and active, draining purulence. This patient is being managed with systemic antibiotic therapy, chlorhexidine mouth rinses several times daily, and conservative debridement of bony sequestra as needed. The patient had discontinued

alendronate and seven months after cessation of alendronate, bone destruction and ONJ continues.

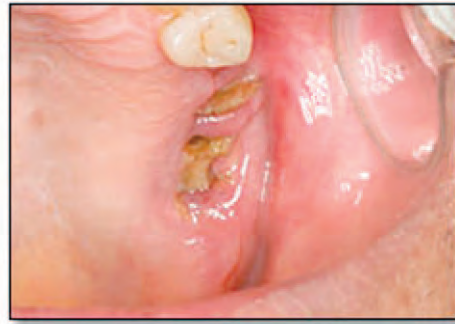The third case is patient #10, who although had been on oral alendronate for only 36 months was wearing her partial denture almost 24 hours/day and only removing it while brushing her remaining teeth twice daily. She presented with a large exposed painful sequestration in the right maxillary quadrant without oro-antral communication. This patient underwent conservative sequestrectomy and is being managed with systemic antibiotic therapy and chlorhexidine mouth rinses several times daily. This case clearly shows the critical role of inciting trauma despite the relatively low duration of BP intake.

The fourth case is patient #5 who is an Asian-American female referred to the clinic for left temporomandibular joint ‘crepitation’ and occasional pain on function. Her medication included alendronate PO once weekly for 36 months, and the site of ONJ intra-orally in the mandible was an incidental finding. The patient was partially edentulous with most of the posterior teeth missing and was wearing maxillary and mandibular partial dentures. On intra-oral examination, a mucosal ulcer measuring approximately 1 mm in diameter was noted at the left mandibular alveolar ridge with no evidence of inflammation or infection. On probing, the periodontal probe dropped >10 mm into the mandibular bone at the ulcer site. The patient reported no symptoms and denied having noticed any mucosal breakdown at the partially edentulous left mandibular ridge. No clinical expansion, paresthesia, or dysesthesia was noted. The patient was informed about the nature of her condition and is being managed with chlorhexidine mouth rinses several times daily and shows no signs of disease progression.

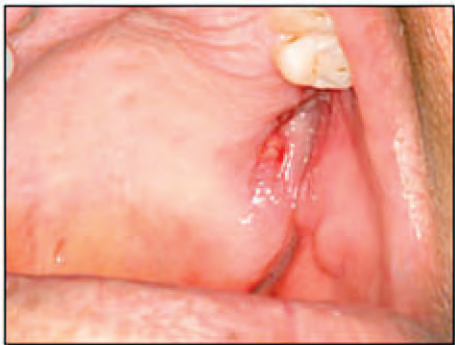In all cases patients were managed conservatively and consistent with their presentation. Conservative treatment may have included chlorhexidine rinses for weeks to months, oral antibiotics (Clindamycin, Amoxicillin and clavulanate, or Azithromycin and Metronidazole) for one to two weeks at a time, gentle debridement, and warm saline irrigation. Soft acrylic stents were fabricated when exposed or sharp bone would cause trauma to adjacent



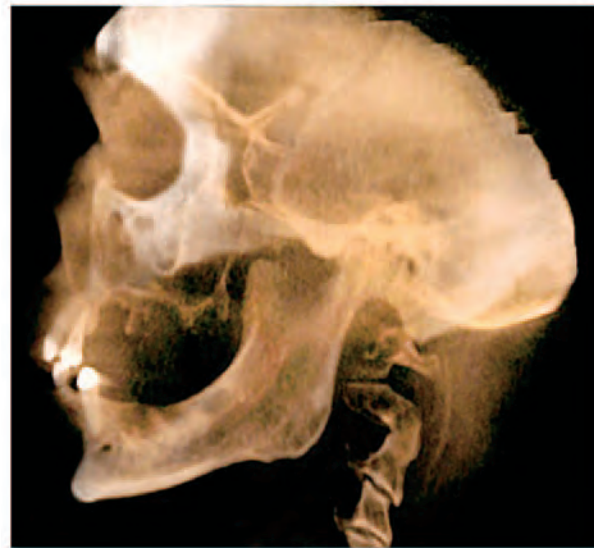**Figure 3.** Initial clinical presentation of patient #2 with soft tissue swelling in the maxillary left quadrant with a history of dental extractions of the molar teeth in the region seven months earlier.



**Figure 4.** After one week of systemic antibiotics, the swelling dramatically subsided, exposing necrotic maxillary bone.



**Figure 5.** Spontaneous sequestration occurred a month later, and soft tissue coverage was achieved shortly thereafter with the patient on a 0.12% chlorhexidine mouthrinse and frequent warm saline rinses at home daily.



**Figure 6.** Three-dimensional reconstruction of cone-beam CT scans shows extensive necrosis of the left maxillary bone extending towards the sinus floor and demonstrating sequestering alveolar sockets.

tissue such as the tongue or other oral structures. In advanced cases with symptoms such as paresthesia or pain, sequestrectomies were performed as needed to control disease or prevent further progression.

Figures 3 to 6 illustrate a clinical presentation sequel before and after treatment in patient #2. Complete healing and soft tissue coverage occurred after management with antibiotics, spontaneous sequestration, and daily chlorhexidine mouth rinsing for one month.

### Discussion

Currently the pathogenesis of ONJ is unknown and clinical and epidemiologic studies are lacking, therefore, no evidence-based therapeutic protocols exist for treating the condition. Diagnostic criteria are not well-established, inclusion and exclusion criteria in reported

cases is lacking, animal models have not been established, and no prospective studies have been conducted to characterize this condition. Preventive dentistry has been recommended as the only measure for trying to prevent ONJ,<sup>17</sup> but this is not always successful nor is the outcome predictable for every patient. Significant research into ONJ is needed at both the basic science and clinical level in order to elucidate the pathogenesis and provide more insight and a rationale for the use of therapeutics.

ONJ secondary to BPs are clinically similar in appearance to those of radiation-induced ONJ or osteomyelitis of the jaws showing oral mucosal

ulcerations with bony sequestrum. These cases are usually asymptomatic and painless until necrotic bone gets secondarily infected. Lesions are often persistent and do not respond well to conventional treatment modalities such as debridement, antibiotic therapy, or hyperbaric oxygen therapy.

The common clinical history includes delayed or lack of tissue healing, usually following dental extractions or after trauma induced by denture appliances. If left unmanaged, ONJ lesions can progress and may lead to extensive areas of bony exposure and dehiscence.<sup>18,19</sup> ONJ cannot be diagnosed until there is a frank clinical lesion be it necrotic bone exposure or secondary infection, swelling, and drainage. Early ONJ without any clinical evidence does not show appreciable bony changes in a routine dental radiograph and, hence, early diagnosis is difficult. Ruggiero et al.<sup>18</sup> has proposed a clinical staging and recommended therapy for each stage of ONJ.

The destruction in ONJ secondary to BP therapy is considered to be a time- and dose-dependent phenomenon due to the long half-life of BPs in bone. This makes it essential to obtain a complete history for every patient who takes BP's, both oral and IV, the duration taken, and the level of compliance.<sup>11</sup> This was seen in this case series with respect to both oral and IV BPs. For example, three patients received IV zoledronic acid; one received the least amount and duration of treatment lasting only months and had the least amount of jaw bone affected with ONJ. The other two patients received years of therapy and had extensive ONJ that at least crossed the midline of the jaw, and in the worst case both the maxilla and mandible were bilaterally affected.

Similarly, among patients on oral alendronate, the minimum duration was one year. However, the two patients on oral alendronate for ten years had the most severe bone destruction with an oro-antral communication in patient #6 and inferior alveolar nerve involvement and secondary left lower lip paresthesia in patient #12 when compared to the other seven patients on oral alendronate for a shorter period of time. Interestingly, the majority of patients (69.2%) in this series were on oral alendronate which has a relatively lower prevalence of ONJ reported in the literature thus far.<sup>11,16</sup>

The risk of ONJ secondary to alendronate is of concern because several million women take this medication for prevention of post menopausal osteoporosis; as the aging population continues to grow, one can expect the possible complication of ONJ to increase as well. However, with emerging clinical evidence<sup>20</sup> the decision to discontinue alendronate treatment after five years of treatment without increased risk of fractures may be followed by many physicians and, hence, there could be reduction of ONJ complication in these patients.

In a review by Woo et al.<sup>11</sup> more than half of all cases (60%) of ONJ have been reported to occur after dentoalveolar surgery (such as tooth extraction) to treat infections, and the remaining 40% were related to infection, denture trauma, or other physical trauma. All the patients reported in the present case series had inciting factors of dental or periodontal infections and eventual teeth extractions or denture trauma.

BPs can generally be subdivided into two categories; nitrogen-containing BPs (located on one of the R groups) and non-nitrogen-containing BPs. The exact mechanism of action of BPs is currently being investigated, though there appears to be differences between them. Non-nitrogen containing BPs are metabolized by osteoclasts to inactive non-hydrolyzable ATP analogues, which accumulate intracellularly and are directly cytotoxic to the cell and induce apoptosis.<sup>6,11</sup> Nitrogen-containing BPs inhibit critical enzymes of the mevalonate pathway, particularly farnesyl diphosphate synthase, which is required for the synthesis of farnesyl diphosphate and geranyl diphosphate and, thereby, suppress prenylation of small GTPases essential for many cellular functions.<sup>6,21,22</sup> Nitrogen-containing BPs have been implicated in ONJ more than the non-nitrogen containing ones.<sup>11,19</sup> All the patients reported in this case series were taking nitrogen-containing BPs, namely zoledronic acid, pamidronate, and alendronate.

BPs suppress osteoclastic bone resorption, and oversuppression of osteoclasts has been thought to play a role in the pathogenesis of ONJ.<sup>23</sup> The inhibition of osteoclastic activity by BPs is achieved by the prevention of the differentiation of precursor monocytes into osteoclasts, blocking the activity of mature osteoclasts, and



the induction of osteoclast apoptosis.<sup>6</sup> BPs also inhibit the formation and activation of osteoclasts by impairing the distribution of osteopontin, B3 integrin, Rac1, and Cdc42.<sup>24</sup> The anti-resorptive potency of each BP varies, and zoledronic acid, which has the highest anti-resorptive potency ( $\geq 10,000$ ),<sup>8</sup> has been implicated in more than 90% of ONJ cases.<sup>11</sup> Three of the ten patients with extensive ONJ lesions in this case series were taking zoledronic acid. Avascularity and anti-angiogenic properties of BPs are also thought to be involved in the pathogenesis of ONJ.<sup>23</sup>

The intriguing phenomenon of ONJ secondary to BPs affecting the jaws exclusively (with the rare exception of one case of ONJ occurring in the tympanic plate portion of the auditory canal)<sup>25</sup> continues to remain poorly understood, though numerous hypotheses have been formed. One hypothesis is the properties of the bones in the jaw are different than elsewhere in the body. The maxilla and mandible form primarily through intramembranous ossification, whereas long bones form through endochondral ossification. In general, the jaws have a greater blood supply than other bones and a faster bone turnover rate related both to their daily activity and the presence of teeth which mandates daily bone remodeling around the periodontal ligament. Hence, BPs should be highly concentrated in the jaws though this has not been proven. These factors, when combined with chronic invasive dental diseases and their treatment, could provide the necessary circumstances for ischemic bone necrosis that could become secondarily infected, particularly when exposed to the oral cavity as sequestra.

Another hypothesis, that may or may not correspond with the former, is BPs inhibit new vessel formation,<sup>26</sup> though Hellstein and Marek<sup>27</sup> report avascularity does not appear to be a major cofactor.

An additional predominate theory is the microbial flora in the oral cavity, many of which are involved in numerous dental/periodontal disease processes as well as with the induction of osteoclastogenesis, can come into direct contact with the bone due to the thin, easily traumatized epithelium, which does not usually occur elsewhere in the body.

Although no long-term supportive data exists, the protocol for dental treatment of patients with ONJ secondary to BP therapy has been grouped into three types: (1) patients who will soon start BPs therapy, (2) patients receiving BPs with no evidence of ONJ, and (3) patients with established ONJ.<sup>18</sup> For patients who will soon start BPs therapy, optimizing dental health is the primary goal. Any necessary dental therapy should be provided prior to initiation. Patients who are receiving BPs and have no sign of ONJ should maintain meticulous oral hygiene. Non-surgical dental treatment, including dental prophylaxis, conservative scaling and root planning, routine restorations, placement of crowns, as well as other conservative prosthodontic appliances should not present an increased risk of developing ONJ. Dental extractions, deep cleanings that violate the biologic width, dental implants, and other oral and periodontal surgeries should be avoided and only performed in cases where it is essential or emergent.<sup>18,28</sup>

The treatment and management of patients with established ONJ depends on the clinical stage of their condition. For patients with exposed, asymptomatic necrotic bone (sequestrum), daily antimicrobial rinses with 0.12% chlorhexidine and regular clinical follow-up as dictated by the disease is recommended.<sup>14,18,28</sup> A non-alcoholic formulation of chlorhexidine, though much more expensive, can be used for patients who cannot tolerate the burning sensation from the contact of alcohol in conventional chlorhexidine on open sores.

Those with exposed, necrotic bone associated with pain and infection, antibiotic therapies based on culture, analgesics, as well as daily antimicrobial rinses are recommended.<sup>18</sup> Penicillin VK is the antibiotic of choice to manage this condition. Levofloxacin, Amoxicillin and clavulanate, Clindamycin, Azithromycin, Doxycycline, Erythromycin ethylsuccinate and Metronidazole have also been used based on penicillin allergy and microbial cultures.<sup>29-31</sup> For patients with exposed, necrotic bone and in patients with pain, infection, and pathologic fracture, extra-oral fistula, or osteolysis extending to the inferior border, surgical debridement of necrotic bone, antimicrobial therapy (PO or IV), analgesics, as well as daily antimicrobial rinses is recommended. The oral surgeon is occasionally compelled to

offer resection of the maxilla or mandible in some of these cases though more recent publications argue against such an approach.<sup>18</sup> In most cases debridement is not recommended; rather, bony projections that cause soft tissue irritation may be smoothed off and the patient placed on a course of antibiotics and 0.12% chlorhexidine. This approach is based on the identification of many pathogens, including actinomyces as well as patients' positive clinical response to this regimen.<sup>23,28,32</sup> Importantly, no single therapeutic modality applies to every patient with ONJ and many clinical factors must be taken into consideration during treatment planning and informed consent. The experience of the authors suggests the need for clinical vigilance and multiple frequent appointments (e.g., once a week for several months) combined with patient compliance with a given regimen in order to control or cure ONJ.

Although there is no definitive cure for ONJ and most treatment is palliative, treating patients' dental and periodontal disease prior to initiation

of BP therapy<sup>11,18</sup> and treating symptoms to control or prevent the spread of ONJ and secondary infection is important.<sup>18,33,34</sup>

Once the diagnosis of ONJ has been made, there has been support for both continuing BP treatment<sup>18</sup> and discontinuation<sup>14,29</sup> of the drug for a period of time while managing the ONJ. However, due to the long half-life of BPs in bone, cessation would seem to be of little value in the short-term. Until the results of prospective studies are known, clinicians should follow a therapeutic protocol based on collective experience, institutional policies, and individual patient needs.

### Conclusion

BPs possess significant therapeutic benefits, and their use will continue to grow and eventually ONJ complications can be expected to rise until optimal dosing and duration of treatment are determined. Treatment of dental and periodontal infections and maintenance of good oral hygiene is critical before starting BP therapy in order to help prevent this significant complication of ONJ.

### References

1. Epstein S. Update of current therapeutic options for the treatment of postmenopausal osteoporosis. *Clin Ther* 2006;28(2):151-73.
2. Yuen KK, Shelley M, Sze WM, Wilt T, Mason MD. BPs for advanced prostate cancer. *Cochrane Database Syst Rev* 2006(4):CD006250.
3. Djulbegovic B, Wheatley K, Ross J, Clark O, Bos G, Goldschmidt H, Cremer F, Alsina M, Glasmacher A. BPs in multiple myeloma. *Cochrane Database Syst Rev* 2002(3):CD003188.
4. Wong R, Wiffen PJ. BPs for the relief of pain secondary to bone metastases. *Cochrane Database Syst Rev* 2002(2):CD002068.
5. Homik JE, Cranney A, Shea B, Tugwell P, Wells G, Adachi JD, Suarez-Almazor ME. A metaanalysis on the use of BPs in corticosteroid induced osteoporosis. *J Rheumatol* 1999;26(5):1148-57.
6. Caraglia M, Santini D, Marra M, Vincenzi B, Tonini G, Budillon A. Emerging anti-cancer molecular mechanisms of amino BPs. *Endocr Relat Cancer* 2006;13(1):7-26.
7. Pavlakis N, Schmidt R, Stockler M. BPs for breast cancer. *Cochrane Database Syst Rev* 2005(3):CD003474.
8. Licata AA. Discovery, clinical development, and therapeutic uses of BPs. *Ann Pharmacother* 2005;39(4):668-77.
9. Papapoulos SE. BP actions: physical chemistry revisited. *Bone* 2006;38(5):613-6.
10. Guay DR. Ibandronate, an experimental intravenous BP for osteoporosis, bone metastases, and hypercalcemia of malignancy. *Pharmacotherapy* 2006;26(5):655-73.
11. Woo SB, Hellstein JW, Kalmar JR. Narrative [corrected] review: BPs and osteonecrosis of the jaws. *Ann Intern Med* 2006;144(10):753-61.
12. Reid DM. Once-monthly dosing: an effective step forward. *Bone* 2006;38(4 Suppl 1):S18-22.
13. Grigg AP, Shuttleworth P, Reynolds J, Schwarzer AP, Szer J, Bradstock K, Hui C, Herrmann R, Ebeling PR. Pamidronate reduces bone loss after allogeneic stem cell transplantation. *J Clin Endocrinol Metab* 2006;91(10):3835-43.

14. Dimitrakopoulos I, Magopoulos C, Karakasis D. BP-induced avascular osteonecrosis of the jaws: a clinical report of 11 cases. *Int J Oral Maxillofac Surg* 2006;35(7):588-93.
15. Kuehn BM. Reports of adverse events from bone drugs prompt caution. *JAMA* 2006;295(24):2833-6.
16. Mavrokokki T, Cheng A, Stein B, Goss A. Nature and frequency of BP-associated osteonecrosis of the jaws in Australia. *J Oral Maxillofac Surg* 2007;65(3):415-23.
17. Bilezikian JP. Osteonecrosis of the jaw--do BPs pose a risk? 2006;355(22):2278-81.
18. Ruggiero SL, Fantasia J, Carlson E. BP-related osteonecrosis of the jaw: background and guidelines for diagnosis, staging and management. *Oral Surg Oral Med Oral Pathol Oral Radiol Endod* 2006;102(4):433-41.
19. Ruggiero SL, Mehrotra B, Rosenberg TJ, Engroff SL. Osteonecrosis of the jaws associated with the use of BPs: a review of 63 cases. *J Oral Maxillofac Surg* 2004;62(5):527-34.
20. Black DM, Schwartz AV, Ensrud KE, Cauley JA, Levis S, Quandt SA, Satterfield S, Wallace RB, Bauer DC, Palermo L, Wehren LE, Lombardi A, Santora AC, Cummings SR. Effects of continuing or stopping alendronate after 5 years of treatment: the Fracture Intervention Trial Long-term Extension (FLEX): a randomized trial. *JAMA* 2006;296(24):2927-38.
21. Shanbhag AS. Use of BPs to improve the durability of total joint replacements. *J Am Acad Orthop Surg* 2006;14(4):215-25.
22. Van den Wyngaert T, Huizing MT, Vermorcken JB. BPs and osteonecrosis of the jaw: cause and effect or a post hoc fallacy? *Ann Oncol* 2006;17(8):1197-204.
23. Marx RE, Sawatari Y, Fortin M, Broumand V. BP-induced exposed bone (osteonecrosis/osteopetrosis) of the jaws: risk factors, recognition, prevention, and treatment. *J Oral Maxillofac Surg* 2005;63(11):1567-75.
24. Suzuki K, Takeyama S, Sakai Y, Yamada S, Shinoda H. Current topics in pharmacological research on bone metabolism: inhibitory effects of BPs on the differentiation and activity of osteoclasts. *J Pharmacol Sci* 2006;100(3):189-94.
25. Polizzotto MN, Cousins V, Schwarzer AP. BP-associated osteonecrosis of the auditory canal. *Br J Haematol* 2006;132(1):114.
26. Purcell PM, Boyd IW. BPs and osteonecrosis of the jaw. *Med J Aust* 2005;182(8):417-8.
27. Hellstein JW, Marek CL. BP osteochemonecrosis (bis-phossy jaw): is this phossy jaw of the 21st century? *J Oral Maxillofac Surg* 2005;63(5):682-9.
28. Migliorati CA, Siegel MA, Elting LS. BP-associated osteonecrosis: a long-term complication of BP treatment. *Lancet Oncol* 2006;7(6):508-14.
29. Advisory Task Force on Bisphosphonate-Related Osteonecrosis of the Jaws. American Association of Oral and Maxillofacial Surgeons position paper on bisphosphonate-related osteonecrosis of the jaws. *J Oral Maxillofac Surg* 2007;65(3):369-76.
30. American Dental Association Council on Scientific Affairs. Dental management of patients receiving oral bisphosphonate therapy: expert panel recommendations. *J Am Dent Assoc* 2006;137(8):1144-50.
31. Marx RE. *Oral & Intravenous BP-Induced Osteonecrosis of the Jaws*. Illinois: Quintessence Publishing Co, Inc; 2007.
32. Dannemann C, Gratz KW, Riener MO, Zwahlen RA. Jaw osteonecrosis related to bisphosphonate therapy: a severe secondary disorder. *Bone* 2007;40(4):828-34.
33. Migliorati CA, Casiglia J, Epstein J, Jacobsen PL, Siegel MA, Woo SB. Managing the care of patients with bisphosphonate-associated osteonecrosis: an American Academy of Oral Medicine position paper. *J Am Dent Assoc* 2005;136(12):1658-68.
34. Carter G, Goss AN, Doecke C. Bisphosphonates and avascular necrosis of the jaw: a possible association. *Med J Aust* 2005;182(8):413-5.

## About the Authors

Satish K. S. Kumar, BDS, MDSc



Dr. Kumar is an Assistant Professor of Clinical Dentistry at the University of Southern California, School of Dentistry (USCSD) in Los Angeles, CA, USA. He received his dental degree in 2001 from Sri Ramachandra Dental College and Research Institute in Chennai, India, a Masters of Dental Science from the University of Malaya, Kuala Lumpur, Malaysia in 2005, and then completed an advanced dual-specialty residency program in Orofacial Pain and Oral Medicine at USCSD in 2007. Dr. Kumar has published in the areas of oral medicine, oral pathology, and orofacial pain. He has won many academic and research awards during his education including the prestigious Lester Burket Memorial Award for his research efforts in oral cancer epidemiology from the American Academy of Oral Medicine. He provides clinical services and teaches oral medicine, medically complex patients, orofacial pain, and oral radiology. His current research efforts are in understanding osteonecrosis of jaws secondary to BP therapy and the oral cancer burden among diverse ethnic populations in the state of California.

e-mail: [satish.kumar@usc.edu](mailto:satish.kumar@usc.edu)

Michael C. Meru, BS, (DDS)



Mr. Meru is a BA graduate in Public Relations from Brigham Young University in Salt Lake City, UT, USA and joined the DDS Program at the University of Southern California, School of Dentistry in 2005. He is currently in his third year of the DDS program and has a special interest in the dental specialties of Oral Medicine and Orofacial Pain. He has been recently appointed as the Editor-in-Chief of the *Journal of the American Student Dental Association*.





Dr. Parish Sedghizadeh is an Assistant Clinical Professor at the University of Southern California, School of Dentistry (USCSD) and Center for Craniofacial Molecular Biology (CCMB) in Los Angeles, CA, USA. He received his bachelor degree in biology from the University of California, Los Angeles (UCLA), and his dental degree from USCSD. He then pursued specialty training in Oral and Maxillofacial Pathology at The Ohio State University in Columbus, OH, USA where he received his MS degree in Oral Biology and was awarded fellowship status in the American Academy of Oral and Maxillofacial Pathology.

While in Ohio, Dr. Sedghizadeh was awarded fellowship in the American Cancer Society for conducting research at the Arthur G. James Cancer Hospital and Richard J. Solove Research Institute investigating the early molecular events involved in the progression of head and neck cancer.

He is a Diplomate of the American Board of Oral and Maxillofacial Pathology and currently provides clinical pathology and histopathologic services to patients at USCSD. He is currently the pathologist for the Center for Advanced Head & Neck Cancer in collaboration with Cedars-Sinai® Hospital. His recent research interests focus on osteonecrosis of the jaws, osteomyelitis of the jaws, and the role of biofilms in craniofacial diseases.

### **Acknowledgement**

The authors would like to thank Dr. Saravanan Ram for his assistance with patient management.