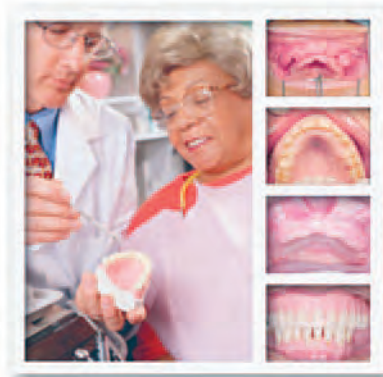

Inflammatory Fibrous Hyperplasia Treated with a Modified Vestibuloplasty: A Case Report

Miguel Jaimes, DDS; Jose Muñante, DDS;
Jaime Giuseppe Rodriguez-Chessa, DDS; Sergio Olate, DDS;
Jose Ricardo de Albergaria-Barbosa, DDS, Msc, PhD;
Renato Mazzone, DDS, Msc, PhD;
Leandro Eduardo Klüppel, DDS, MSc



Abstract

Aim: The purpose of this report is to present a case of surgical and prosthetic treatment of a woman with inflammatory fibrous hyperplasia (IFH) and her evaluation during a six month period.

Background: IFH is a benign pathology, prevalent in female patients, and principally associated with ill-fitting prosthetic devices in need of adjustment. It is common for patients to require surgical removal of the hyperplastic tissue and fabrication of a new prosthesis.

Case Report: A 55-year-old female with a history of smoking presented with a chief complaint of missing the scheduled adjustment of her maxillary complete denture and the presence of moveable tissue under the denture. Surgical excision of the hyperplastic tissue followed with fixation of the prosthesis for six months to guide the healing of the soft tissue and to reshape the contours of the maxillary supporting tissues.

Summary: Surgical removal of hyperplastic soft tissue is a routine procedure, and the fixation of the prosthesis for the support of tissue during healing improves intraoral conditions for the fabrication of a new prosthesis in the future.

Keywords: Vestibuloplasty, inflammatory fibrous hyperplasia, IFH, preprosthetic surgery, remodeling oral surgery

Citation: Jaimes M, Muñante J, Rodriguez-Chessa JG, Olate S, de Albergaria-Barbosa JR, Mazzone R, Klüppel LE. Inflammatory Fibrous Hyperplasia Treated with a Modified Vestibuloplasty: A Case Report. J Contemp Dent Pract 2008 March; (9)3:135-141.

Introduction

Inflammatory fibrous hyperplasia (IFH) is a benign lesion of the oral mucosa, classified as a non-neoplastic proliferative process.¹ Formation of the lesion begins with a proliferative cellular process generally caused by low intensity, chronic trauma. The following are known examples of low intensity, chronic trauma that can cause a proliferative cellular increase:^{2,3,4}

- Wearing an ill-fitting full or partial denture prosthesis
- Wearing a fractured or worn-out prosthesis
- Oral soft tissue rubbing on fractured teeth with sharp edges
- The presence of diastemas allowing trauma to soft tissue
- Improper oral hygiene
- Iatrogenic procedures

Clinically, they appear as a series of hyperplastic tissue folds in the vestibule and on the lingual aspect of the alveolar ridge area. Generally, the tissue is firm and fibrous; the size of the lesion depends on its degree of aggressiveness and the time it has been under development.⁵

The treatment can be either conservative or surgical depending on the severity of the tissue damage and the amount of affected tissue. In cases of considerable and long-term evolving tissue damage the most suitable option is the surgical excision of the hyperplastic tissue with a small security margin.^{6,7,8} The vestibular fornix has to be maintained as much as possible to avoid tissue interference with the retention of the denture or, if it is necessary, perform a combined surgery to increase this depth.

There are a wide variety of surgical procedures to increase the vestibular fornix. One of them is the surgical division of anatomical structures that interfere with the retention and adherence of the prosthesis. Although surgical techniques can vary from one procedure to another, they all require sufficient bone height for the procedure to succeed. Another challenge of surgical techniques designed to increase the depth of the vestibular fornix is the occurrence of a fibrous cord at its base that makes retention of the prosthesis impossible.

The purpose of this report is to present a clinical case of IFH treated with using a vestibuloplasty

and fixation of the existing maxillary complete denture by using a titanium retention screw in the hard palate region.

Case Report

Diagnosis

A 55-year-old female with a smoking habit came to the Oral and Maxillofacial Surgery Unit of the Piracicaba Dental School (UNICAMP) in Campinas, SP, Brazil seeking care for her oral condition. She presented with an increase in the amount of soft tissue in the base of the vestibular fornix of her maxilla, which evolved with symptoms during a six-month period. The presence of the tissue was making it more difficult to wear her maxillary complete denture which, in turn, made it difficult to chew and swallow. The patient reported wearing this prosthesis for 11 years and denied any important medical family background.

The clinical examination revealed a substantial growth of erythematous hyperplastic tissue with a fibrous consistency and multiple folds in the vestibular region. There was no evidence of micotic infection related to the lesion (Figure 1).

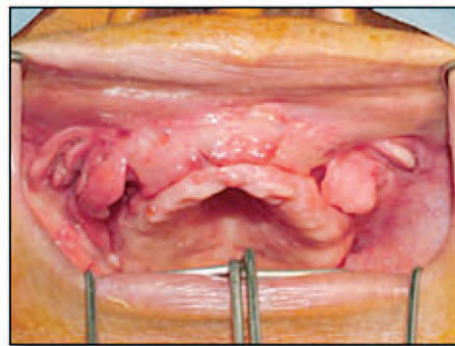


Figure 1. Pre-surgical clinical condition.

Treatment

Because of the extensive size of the pathology, a vestibuloplasty with secondary epithelialization was done following the proposed by Kazanjian.⁹ The surgical procedure was done under local anesthesia (lidocaine HCL 2% with epinephrine 1:100,000, Alphacaina, DFL[®], SP, Brazil).

An incision was performed over the wedge shaped hyperplastic tissue at the pedicle level and removed leaving a small security margin of normal tissue. The incision was then

electrocauterized and compressed with wet gauzes to improve hemostasis (Figure 2). Once the IFH was removed, a division of the deep tissues was performed (Figure 3) to uninsert the attached muscles. The margin of the mucosal flap was repositioned to the bottom of the vestibular fornix created and sutured to the periosteum with a cat-gut 4-0 suture material (Figure 4).

The complete denture used by the patient was perforated at the middle palate level, and it was adapted to the maxillary soft tissues with surgical cement along the prosthetic margins. The prosthesis was fixed to the hard palate using an 8 mm titanium screw to prevent the denture from dropping in order to maintain the depth of the newly created vestibular fornix. The soft tissue was left to heal by secondary union (intention). (Figure 5).

The surgical specimen (Figure 6) was sent for histopathologic analysis. The histological sections showed larger quantities of collagen fibers and fibroblasts associated with an intense and chronic inflammatory infiltrate, confirming the preliminary diagnosis of IFH (Figure 7).

The first post surgical evaluation was done after five days with no surgical complications found. The evaluation revealed the presence of fibrin in contact with the prosthetic margins at the bottom of the vestibule (Figure 8).

The second post-surgery evaluation was done ten days after the surgery. At this time, the screw and the prosthesis were removed and the healing process consistent with the post surgery period was verified. The prosthesis was then adapted using a tissue conditioner.

The third post surgery evaluation was conducted after 18 days. This phase of the healing process demonstrated a fibrin decrease at the bottom part of the vestibular fornix (Figure 9).

The patient was referred to the Unit for Oral Rehabilitation for the fabrication of a new prosthesis, which was inserted after 30 days with all the adjustment and stability requirements addressed. Six months after the surgery all the soft tissues could be seen, and the correct adjustment of the prosthesis was verified without a recurrence of the lesion (Figures 10 and 11).

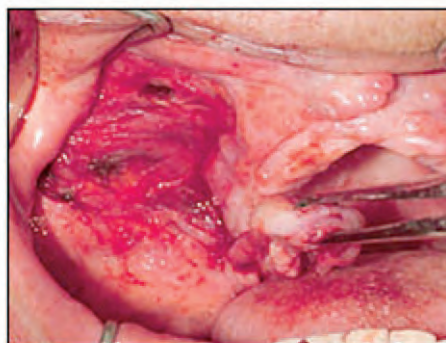


Figure 2. Pedicle level incision and electrocauterized tissue.

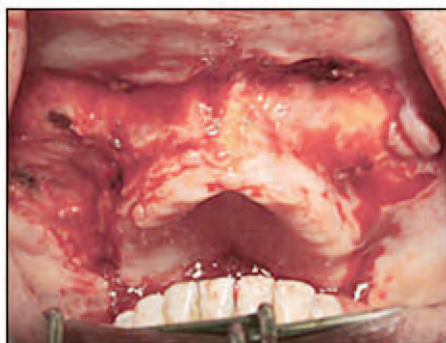

Figure 3. Excision of hyperplastic lesion.

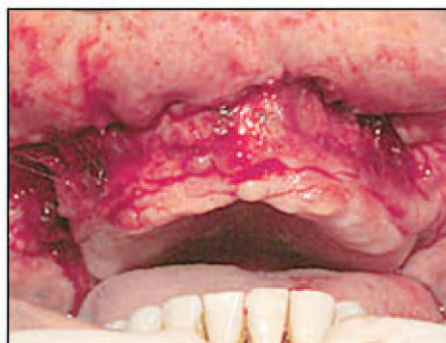

Figure 4. Labial tissue sutured to the periosteum.

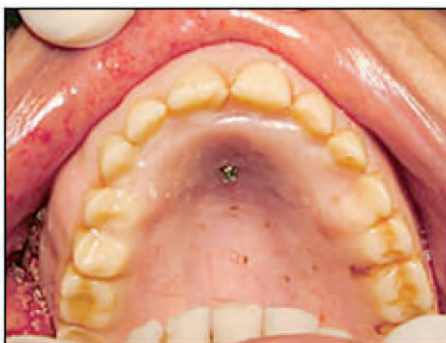

Figure 5. Insertion of screw in the middle palatal zone.

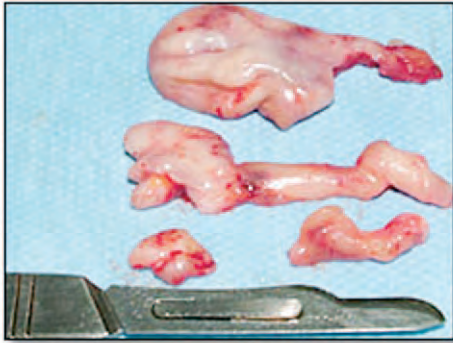

Figure 6. Specimen tissue removal.

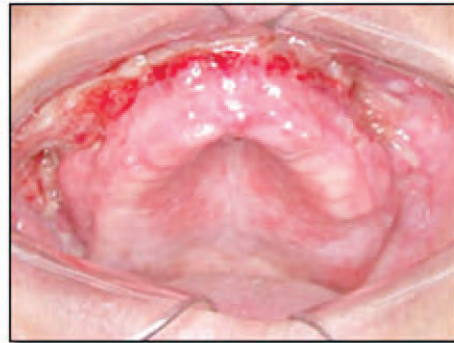

Figure 9. Eighteen day post-surgical clinical status.

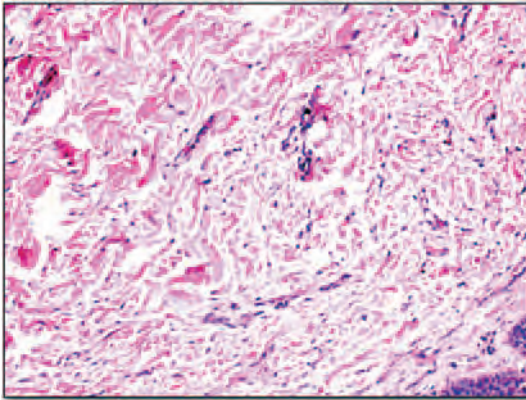


Figure 7. Histological image (H-E). Multiples collagen tissue unit.

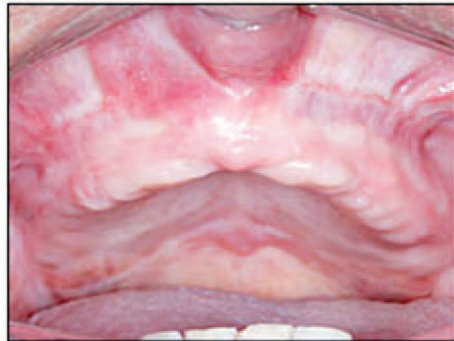

Figure 10. Six month post-surgical clinical status with noted improvement of the soft tissue.

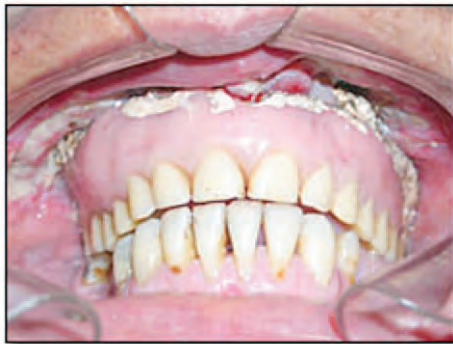

Figure 8. Five day post-surgical clinical status.

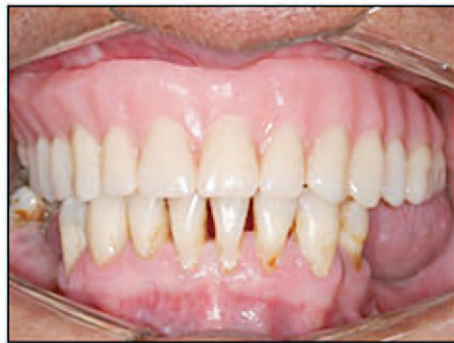

Figure 11. Six month post-surgical exam with a new prosthesis in use.

Discussion

IFH is a consequence of a response of oral mucosa to low intensity chronic trauma commonly caused by an ill-fitting denture. Coelho et al.¹⁰ showed an IFH frequency of 15% of the total of diagnosed pathologies, predominantly between the fifth and sixth decade of life among females (5:1). This IFH frequency is related to the extended use of the prosthesis.

Several authors agreed^{6,7,8} the best therapeutic option in the presented case was the surgical excision with a small security margin. The upper prosthesis was fixed to the palate using a screw for the purpose of maintaining an appropriate vestibular fornix and to avoid reduction of its depth during the healing process.

The fabrication and insertion of the appropriate prosthesis will avoid the recurrence of IFH because recurrence levels are low when the traumatic agent is removed.¹⁰ Kazanjian⁹ recommends placing the final prosthesis in a maximum of ten days after the insult to the anatomic structures has been eliminated.

Total prosthesis success depends on the quality of the adjacent tissues. Many of the adjacent tissues can be the cause of a decrease in size of the vestibular fornix due to bone resorption or soft tissue deficiency.¹¹ In the present case the Kazanjian technique was used which included the removal of the diseased tissue and repositioning of the mucosal flap which preserved healthy fornix tissue and maintained a stable anatomical configuration for the final rehabilitation.

Finally, the surgery has a certain number of techniques and modifications, which vary according to the requirements of the individual case. In vestibuloplasty cases a Kazanjian technique, modified or not, demonstrated a better result in terms of achieving a favorable mucosal attachment.^{11,12} In the present case there was mucosal reattachment at the six-month follow-up examination which continued without complications until the new prosthesis was fabricated. The treatment was accomplished without implant therapy and has been a complete success for the patient.

Summary

Surgical removal of hyperplastic soft tissue is a routine procedure, and the fixation of the prosthesis for the support of tissue during healing improves intraoral conditions for the fabrication of a new prosthesis in the future.

References

- 1 Tommasi AF. Diagnóstico en Patología bucal. 1st ed. São Paulo: Artes Médicas Ltda.; 1982.
- 2 Bassi APF, Vieira EH, Gabrielli MAC. Hiperplasia Fibrosa Inflatória. R G O. 1998; 46(4):209-11.
- 3 Kignel S. Hiperplasia Fibrosa Inflatória. Rev Paulista Odontol. 1999; 21(2):40-4.
- 4 Castro MVM, Duarte CA. Remoção cirúrgica de hiperplasia labial induzida por diastema –relato de caso. B C I. 2001; 8(31):46-8.
- 5 Neville B, Damm D, Allen C, Bouquot J, editors. Odontogenic cyst and tumors. In: Oral and maxillofacial pathology. 2nd ed. Philadelphia: W. B. Saunders; 2002. p. 565–617.
- 6 Boldine RL. Oral lesions caused by ill-fitting dentures. J Prosthet Dent. 1969; 6(21):580-8.
- 7 Buchner A, Calderon S. Pathologic conditions of the oral mucosa associated with ill-fitting dentures: III Epulis fissuratum and flabby ridge. Isr J Dent Med. 1979; 2(28):7-13.
- 8 Cooper EH. Hyperplasia of the oral tissues caused by ill-fitting dentures. Br Dent J. 1964; 2(116):111-14.
- 9 Kazanjian VH. Surgery as an aid to more efficient service with prosthetic dentures. J Am Dent Assoc. 1935;22:566
- 10 Coelho CMP, Sousa YTCS, Daré AMZ. Denture-related oral mucosal lesions in a Brazilian school of dentistry. J Oral Rehabil. 2004; 31:135-9.
- 11 Fröschl T, Kerschler A. The optimal vestibuloplasty in preprosthetic surgery of the mandible. J Canio Maxillofac Surg. 1997; 25:85–90.
- 12 Al-Mahdy F. Mandibular anterior ridge extension: a modification of the kazanjian vestibuloplasty technique. J Oral Maxillofac Surg. 1997; 55:1057–9.

About the Authors

Miguel Jaimes, DDS



Dr. Jaimes is a graduate student in the Oral and Maxillofacial Surgery Unit of the Department of Oral Diagnosis at the State University of Campinas – UNICAMP in Campinas, SP, Brazil. His research interests include oral implant and orthognatic surgery.

e-mail: miajape@fop.unicamp.br

Jose Mufante, DDS



Dr. Mufante is a Trainee in the Oral and Maxillofacial Surgery Unit of the Department of Oral Diagnosis at the State University of Campinas – UNICAMP in Campinas, SP, Brazil. His research interests include oral and maxillofacial surgery.

e-mail: vonpaulus9@hotmail.com

Jaime Giuseppe Rodriguez-Chessa, DDS



Dr. Rodriguez-Chessa is a graduate student in the Oral and Maxillofacial Surgery Unit of the Department of Oral Diagnosis at the State University of Campinas – UNICAMP in Campinas, SP, Brazil. His research interests include oral implants and orthognatic surgery.

e-mail: jaime@fop.unicamp.br

Sergio Olate, DDS



Dr. Olate is a Professor of the Department of Integral Odontology, University of La Frontera in Temuco, Chile. He is also a graduate student in the Oral and Maxillofacial Surgery Unit of the Department of Oral Diagnosis at the State University of Campinas – UNICAMP in Campinas, SP, Brazil. His research interests include oral and maxillofacial implantology and maxillofacial trauma.

e-mail: solate@fop.unicamp.br

Jose Ricardo de Albergaria-Barbosa, DDS, Msc, PhD



Dr. Albergaria-Barbosa is a Professor in the graduate program of the Oral and Maxillofacial Surgery Unit of the Department of Oral Diagnosis at the State University of Campinas – UNICAMP in Campinas, SP, Brazil. He has been involved in research activities focusing on oral and maxillofacial implants and biomaterials.

e-mail: barbosa@fop.unicamp.br

Renato Mazzone, DDS, Msc, PhD



Dr. Mazzone is a Professor in the graduate program of the Oral and Maxillofacial Surgery Unit of the Department of Oral Diagnosis at the State University of Campinas – UNICAMP in Campinas, SP, Brazil. He has been involved in research activities focusing on oral and maxillofacial implants and orthognathic surgery.

e-mail: renatomz@fop.unicamp.br

Leandro Eduardo Klüppel, DDS, MSc



Dr. Klüppel is a PhD student in the Oral and Maxillofacial Surgery Unit of the Department of Oral Diagnosis at the State University of Campinas UNICAMP in Campinas, SP, Brazil. His research interests include oral and maxillofacial implants and orthognathic surgery.