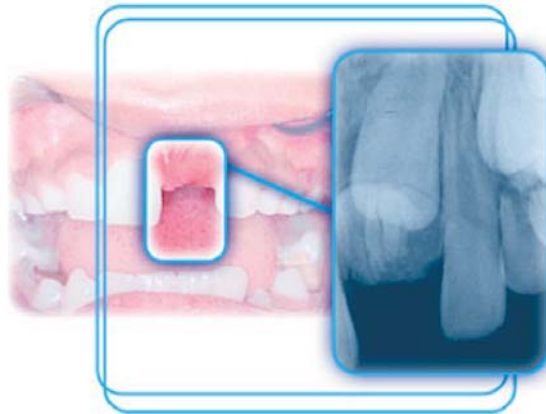


## Central Incisor Impacted by an Odontoma

Catiara Terra da Costa, DDS, MSC; Dione Dias Torriani, DDS, MSC, PhD;  
Marcos Antônio Torriani, DDS, MSC, PhD; Raquel Barbieri da Silva, DDS



**Aim:** The aim of this report is to present a clinical case of impaction of a maxillary left central incisor in a mixed dentition caused by the presence of an odontoma as well as a review of the pertinent dental literature.

**Background:** Knowledge of the normal tooth eruption patterns is essential for the identification and appropriate treatment of deviations in eruption that may endanger physiologic development. A delay in time between the exfoliation of a deciduous tooth and the eruption of its permanent successor may be related to a disorder known as dental retention. This occurs when tooth eruption does not occur within a normal time frame, the tooth is not present in the dental arch, and there is no potential for eruption due to the presence of a completely formed root or when the homologous tooth has been erupted for at least six months with complete root formation.

**Report:** A 10-year-old boy in the mixed dentition stage presented with an impacted maxillary left central incisor due to the presence of an odontoma. Treatment included the surgical removal of the lesion and the follow up of the spontaneous eruption while a partial fixed appliance was used to recover the space of the missing tooth. Since spontaneous eruption failed to occur within the expected time frame, surgical exposition of the crown and bonding of an orthodontic appliance for traction was done to facilitate eruption.

**Summary:** The incisor was integrated to the dental arch without any root or periodontal sequelae. The treatment was considered a success, since both health and aesthetics of the smile were recovered. The importance of the clinical and radiographic diagnosis of the retention of a permanent tooth associated with a pathological entity should be emphasized. The participation of a multidisciplinary team to accomplish the

appropriate treatment of such patients is extremely relevant because of the esthetic and functional ramifications of a missing anterior tooth as well as the psychological well-being of the individual.

**Keywords:** Impacted tooth, odontoma, malocclusion, mixed dentition

**Citation:** Costa CT, Torriani DD, Torriani MA, da Silva RB. Central Incisor Impacted by an Odontoma. J Contemp Dent Pract 2008 September; (9)6:122-128.

## Introduction

Clinicians should be knowledgeable about the dynamics of dentition development from the beginning of tooth formation to total eruption as a part of the integration of a tooth into an established dentition. Such knowledge is essential for the diagnosis and treatment of irregularities in this process that may endanger physiologic development. The time interval between the exfoliation of a deciduous tooth and the eruption of its permanent successor is predictable; however, the delay in this process, mainly between homologous teeth, may be related to a disorder known as dental retention. A diagnosis of dental retention can be made when the following criteria exist:<sup>1</sup>

- The normal time for eruption has been exceeded.
- The tooth is not present in the dental arch and shows no potential for eruption.
- The root of the unerupted tooth is completely formed.
- The homologous tooth has been erupted for at least six months with complete root formation.

Etiologic factors of dental retention are shown in Table 1:<sup>2-4</sup>

The odontoma is a pathologic entity known as hamartoma (malformation tumor). It represents 22% of the odontogenic tumors,<sup>5</sup> however, the prevalence is increased to 24.91% in the Brazilian population.<sup>6</sup> The tumor presents as an asymptomatic, slow growing lesion seen radiographically as a radiopaque image. Surgical removal is indicated with an extremely favorable prognosis since the recurrence is not expected. Its etiology is unknown, however, local trauma, infection, and genetic characteristics are suggested as possible factors.<sup>7,8</sup>

The odontoma can be classified as compound when it shows an anatomic resemblance to a normal tooth or complex when it presents as an irregular mass with dentin and enamel formation but without any defined morphologic aspects. The compound type is more frequently found in the anterior region of the maxilla, while the complex type is more common in the posterior region of the lower jaw.<sup>7,9</sup>

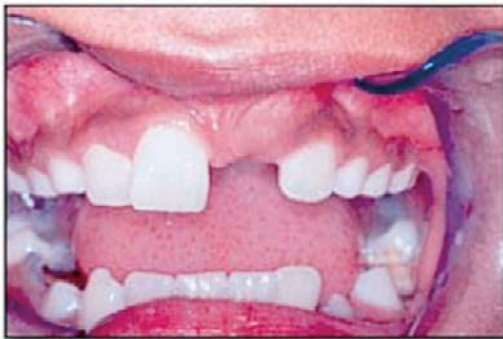**Table 1. Etiological factors of dental retention.**

<ul style="list-style-type: none"><li>• Ectopic tooth development</li><li>• Ectopic tooth eruption</li><li>• Premature apical closure</li><li>• Unfavorable tooth rotation</li><li>• Altered eruption sequence</li><li>• Premature loss of a deciduous tooth</li></ul>	<ul style="list-style-type: none"><li>• A supranumerary tooth</li><li>• Presence of tumor (odontoma, etc.)</li><li>• Presence of a cyst</li><li>• Insufficient space in the dental arch</li><li>• Sequelae of oral trauma</li></ul>
--	---

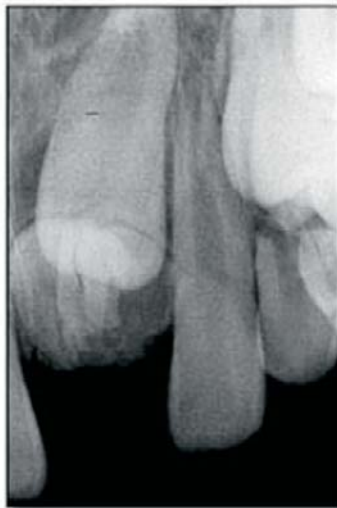## Case Report

### Diagnosis

A 10-year-old boy presented to the Children's Dental Clinic of the Dental School at the Federal University of Pelotas in Pelotas, RS, Brazil. His only complaint was the lack of the maxillary left central incisor which bothered him because it was not esthetically acceptable. A clinical examination revealed a balanced face, good oral health, an Angle Class I malocclusion, a mixed dentition, lack of the maxillary left central incisor, and the loss of space caused by the inclination of the teeth that were adjacent to the space of the retained tooth (Figure 1).



**Figure 1.** Initial frontal view of the mixed dentition.

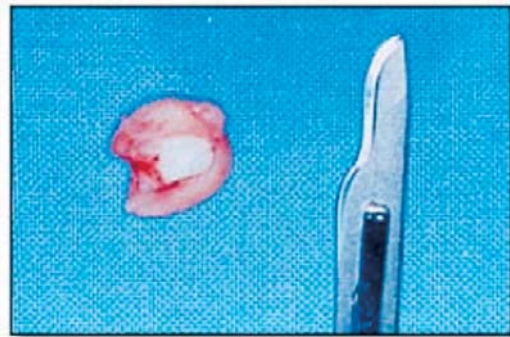


**Figure 2.** Initial periapical radiograph.

A radiopaque mass was found on a periapical radiograph (Figure 2). Using the radiographic localization technique described by Clark<sup>10</sup> the

mass was found to be in an anterior position relative to the maxillary left incisor which prevented its eruption.

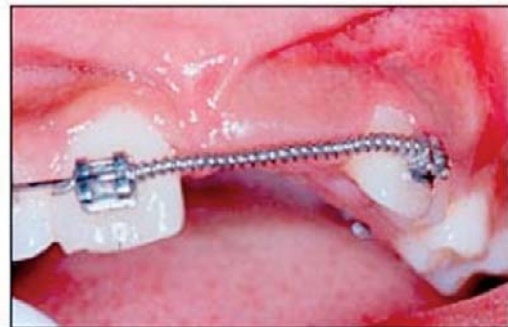Using the clinical and radiographic findings the presumptive diagnosis was a complex odontoma with surgical excision being indicated. After the removal of the lesion, a histopathological exam of the tissue confirmed the diagnosis (Figure 3).



**Figure 3.** Excised lesion.

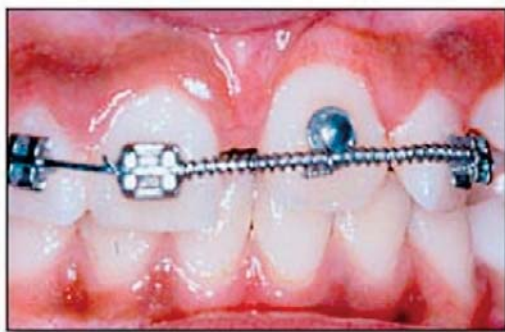### Treatment

Spontaneous eruption of the maxillary left central incisor was expected during the subsequent four months. Since eruption did not occur a partial fixed appliance was fabricated because the patient was in the mixed dentition stage. The appliance, with a push coil spring, was attached using brackets bonded to teeth adjacent to the edentulous space using light-cured composite to accomplish alignment of the teeth, space recovery, and leveling of the dental arch (Figure 4).



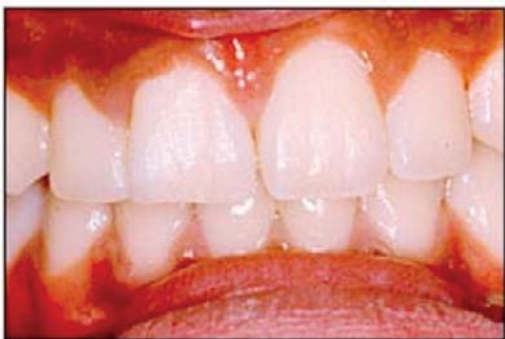**Figure 4.** Recovered space.

Despite the recovery of space following eight months of treatment with the partial orthodontic appliance spontaneous eruption of the maxillary left central incisor failed to occur. Treatment was then altered to include orthodontic traction and the surgical exposure of the crown of the impacted tooth was accomplished. Later, bonding of the button to the traction appliance was done in the same way as the original orthodontic appliance brackets. The orthodontic button with an extension of the ligature wire was bonded to the buccal surface of the maxillary left central incisor. Light and extrusive forces were applied with an elastic ligature until the tooth reached the desired position and favorable positioning in the arch was possible (Figure 5).

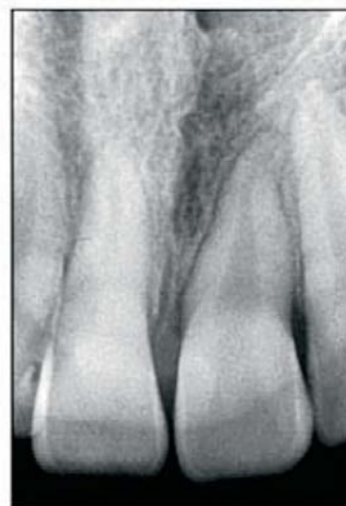

**Figure 5.** Tractioned incisor.

While the tooth was being positioned in the arch, its pulp vitality and periodontal health were maintained with no signs of root resorption. When the occlusion was stabilized, the orthodontic appliance was removed and the patient was scheduled for periodic re-evaluation visits and hygiene control (Figures 6 and 7).



**Figure 6.** Completed case.



**Figure 7.** Final periapical radiograph.

### Discussion

The treatment of impacted teeth requires the services of a multidisciplinary team of dental professionals. Normally, the pediatric dentist is the first to detect the abnormality and together with the surgeon and the orthodontist treat the patient to ensure the integration of function and esthetics. The need for a pediatric dentist is emphasized to achieve the best behavior management of the patient.<sup>11</sup>

The majority of impacted teeth are found in the permanent dentition when orthodontic treatment is considered by clinicians responsible for treatment of general malocclusions. Exceptions are the maxillary central incisors because of the esthetic aspect for the patient.<sup>12</sup> This is exactly what happened in the present case. The retention of the maxillary central incisor of the 10-year-old boy was diagnosed because his mother was concerned about the missing tooth and its negative impact on the esthetics of the boy's smile and sought treatment for her son.

The presence of an odontoma as an etiologic factor in dental retention cases is not new to the scientific community.<sup>2,3</sup> However, the location of a complex odontoma in the anterior region of maxilla differs from report in the literature indicating a greater frequency of this kind of hamartoma in the posterior region of the mandible.<sup>7</sup> Similarly, there are findings of the presence of compound odontomas in the region of mandibular primary cuspid.<sup>13</sup>



Once a dental impaction is detected the diagnosis must be established and treatment rendered in order to minimize the negative impact on the occlusion such as the inclination of the adjacent teeth towards the edentulous space of the unerupted tooth. The removal of the obstacle that interfered with the physiologic eruptive path makes potential eruption process easier but the retained tooth still may not erupt spontaneously. In these cases orthodontic traction and subsequent correction of the positioning of the teeth is indicated.<sup>12</sup>

When an obstruction to tooth eruption is detected, it must be removed and orthodontic treatment rendered when there is inadequate space in the dental arch for the proper positioning of a retained tooth or when a retained tooth is in a severely impacted position.<sup>11</sup> Clinicians who have observed rapid spontaneous eruption of the permanent incisor after an obstruction is removed have adopted a different opinion.<sup>14</sup>

Usually lost arch space should be regained prior to surgical removal of the cause of the dental retention.<sup>12</sup> In the present case regaining the space was done after removal of the obstructive odontoma due to the small amount of space loss and the potential for rapid space recovery without disturbing spontaneous eruption. However, eruption did not occur because formation of the retained tooth was complete and provided little eruptive force.<sup>11,15</sup>

When the lack of spontaneous eruption was apparent, a partial fixed orthodontic appliance was used for alignment and leveling procedures. A push coil spring was used as a space regaining device and an orthodontic button with twisted wire was used as a traction device to facilitate eruption.<sup>12,16</sup> It is important to extend the edentulous space apically to include the entire root area to allow the unerupted tooth an unobstructed path into the mouth.<sup>12</sup>

Surgery to expose the dental crown of the retained tooth should be done in the area from which the odontoma was removed to prepare it

to receive a bonded orthodontic traction device. The advantage of this technique is the possibility of visualizing the movement of the retained tooth and facilitating rapid eruption.<sup>17</sup>

Because of the concern for esthetics some retained teeth are extracted while other cases may offer a favorable prognosis through the combination of surgery and orthodontic treatment in a more conservative approach when dealing with retained maxillary incisors.<sup>14</sup>

Cases considered successful in periodontal terms are those with teeth that are sound and stable within bone and even those with slight apical resorption similar to the initial radiograph. Those classified as periodontally involved are the ones that show mobility, bone dehiscence, and severe root resorption. Such a difference is due to the distance crossed by the retained elements, the time in which the force was applied, and individual differences.<sup>18</sup> Final results of the present case included an appropriate probing depth, stability within bone, and no radiographic evidence of root resorption.

The periodontal destruction of tractioned teeth can be due to the inappropriate plaque control.<sup>17</sup> This did not occur in the present case because the patient was extremely motivated to receive treatment and to cooperate in maintaining a favorable level of oral hygiene.

### Summary

The incisor was integrated to the dental arch without any root or periodontal sequelae. The treatment was considered a success, since both health and aesthetics of the smile were recovered. The importance of the clinical and radiographic diagnosis of the retention of a permanent tooth associated with a pathological entity should be emphasized. The participation of a multidisciplinary team to accomplish the appropriate treatment of such patients is extremely relevant because of the esthetic and functional ramifications of a missing anterior tooth as well as the psychological well-being of the individual.

## References

1. Lindauer SJ, Rubenstein LK, Hang WM, Andersen WC, Isaacson, RJ. Canine impaction identified early with panoramic radiographs. *J Am Dent Ass* 1992; 123:91-97.
2. Brin I, Zolberman Y, Azaz B. The unerupted maxillary central incisor: review of its etiology and treatment. *J Dent Child* 1982; 49:352-56.
3. Bishara SE. Impacted maxillary canines: a review. *Am J Orthod Dentofacial Orthop* 1992; 101(2):159-171.
4. O'Sullivan EA. Multiple dental anomalies in a young patient: a case report. *Int J Paediatr Dent* 2000; 10(1):63-6.
5. Shafer WG, Hine MK., Levy BM. A textbook of oral pathology. 4th edn. Philadelphia: WB Saunders Co, 1983; 308-11.
6. Fernandez AM, Duarte EC, Pimenta FJ, Souza LN, Santos, VR, Mesquita RA, de Aguiar MC. Odontogenic tumors: a study of 340 cases in a brazilian population. *J Oral Pathol Med* 2005; 34(10):583-7.
7. Barnes L, Evenson JW, Reichart P, Sidransky D, editors. World Health Organization Classification of Tumours. Pathology and Genetics of Head and Neck Tumours. Lyon: IARC Press, 2005; 310-311.
8. Sciubba JJ, Fantasia JE, Kahn LB, editors. Tumors and cysts of the jaw. Washington: Armed Forces Institute of Pathology, 2001; 117-20.
9. Neville BW, Damm DD, Allen CM, Bouquot JE. *Oral & Maxillofacial Pathology*. 2nd edn. Philadelphia: WB Saunders Co, 2002; 631-632.
10. Jacobs SD. Radiographic localization of unerupted maxillary anterior teeth using the vertical tube shift technique: The history and application of the method with some case reports. *Am J Orthod Dentofacial Orthop* 1999; 116(4):415-23.
11. Ibricevic H, Al-Mesad S, Mustagrudic D, Al-Zohejry N. Supranumerary teeth causing impaction of permanent maxillary incisors: consideration of treatment. *J Clin Pediatr Dent* 2003; 27(4):327-332.
12. Becker A. Early treatment for impacted maxillary incisors. *Am J Orthod Dentofacial Orthop* 2002; 121(6):586-587.
13. Cildir SK, Sencift K, Olgac V, Sandalli N. Delayed eruption of a mandibular primary cuspid associated with compound odontoma. *J Contemp Dent Pract* 2005; 6(4):152-159.
14. Veis A, Tziafas D, Lambrianidis T. A case report of a compound odontoma causing delayed eruption of a central maxillary incisor: clinical and microscopic evaluation. *J Endod* 2000; 26(8):477-479.
15. Kamamura S, Matsui K, Katou F, Shirai N, Kochi S, Motegi K. Surgical and orthodontic management of compound odontoma without removal of the impacted permanent tooth. *Oral Surg Oral Med Oral Pathol* 2002; 94(5):540-542.
16. Kocadereli I, Turgut MD. Surgical and orthodontic treatment of an impacted permanent incisor: case report. *Dent Traumatol* 2005; 21:234-239.
17. Frank CA, Long M. Periodontal concerns associated with the orthodontic treatment of impacted teeth. *Am J Orthod Dentofacial Orthop* 2002; 121(6):639-649.
18. Brand A, Akhavan M, Tong H, Kook YA, Zernik JH. Orthodontic, genetic and periodontal considerations in the treatment of impacted maxillary central incisors: A study of twins. *Am J Orthod Dentofacial Orthop* 2000; 117(1):68-74.

## About the Authors

**Catiara Terra da Costa, DDS, MSC**

Dr. Costa is a postgraduate student in pediatric dentistry in the Pelotas Dental College at the Federal University of Pelotas in Pelotas, RS, Brazil.

e-mail: [catiaraorto@ibest.com.br](mailto:catiaraorto@ibest.com.br)

**Dione Dias Torriani, DDS, MSC, PhD**

Dr. Torriani is a Professor of Dental Pediatrics at the Infant Clinic in the Department of Social and Preventive Dentistry of the Pelotas Dental College at the Federal University of Pelotas in Pelotas, RS, Brazil.

e-mail: [dionedt@brturbo.com.br](mailto:dionedt@brturbo.com.br)

**Marcos Antônio Torriani, DDS, MSC, PhD**

Dr. Torriani is a Professor in the Department of Oral Surgery and Traumatology of the Pelotas Dental College at the Federal University of Pelotas in Pelotas, RS, Brazil.

**Raquel Barbieri da Silva, DDS**

Dr. da Silva is in Private Practice in Santa Cruz, RS, Brazil.