

The Dilemma of the Open Gingival Embrasure Between Maxillary Central Incisors

Orlando Motohiro Tanaka, DDS, MSc, PhD;
Bruno D'Aurea Furquim, DDS; Renata Corrêa Pascotto, DDS, MSc, PhD;
Gerson Luiz Ulema Ribeiro, DDS, MSc, PhD;
José Antonio Bósio, DDS, MSc; Hiroshi Maruo, DDS, MSc, PhD



Aim: The aim of this report is to present the etiology, diagnosis, and treatment planning strategy in the presence of an open gingival embrasure between the maxillary central incisors.

Background: The open gingival embrasure or “black triangle” is a visible triangular space in the cervical region of the maxillary incisors. It appears when the gingival papilla does not completely fill in the interdental space. The space may occur due to: (1) disease or surgery with periodontal attachment loss resulting in gingival recession; (2) severely malaligned maxillary incisors; (3) divergent roots; or (4) triangular-shaped crowns associated with or without periodontal problems and alveolar bone resorptions.

Report: The post-treatment prevalence in adult orthodontic patients is estimated to be around 40% compromising the esthetic result.

Conclusion: Several methods of managing patients with open gingival embrasure exist, but the interdisciplinary aspects of treatment must be emphasized to achieve the best possible result. The orthodontist can play a significant role in helping to manage these cases.

© Seer Publishing

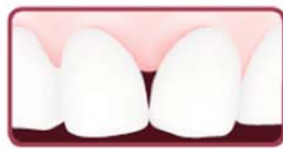Clinical Significance: Various treatment strategies are available to treat cases of an undesirable black triangle and are dependent on the etiology of the condition.

Keywords: Black space, maxillary central incisors, open gingival embrasure

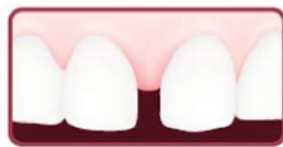Citation: Tanaka OM, Furquim BD'A, Pascotto RC, Ribeiro GLU, Bósio JA, Maruo H. The Dilemma of the Open Gingival Embrasure Between Maxillary Central Incisors. J Contemp Dent Pract 2008 September; (9)6:092-098.

Introduction

The open gingival embrasure, also called the “black triangle,” is a visible triangular space caused by the lack of interdental gingival papilla filling this area. The central incisors are the most dominant anterior teeth in the maxillary arch because they can be fully visible¹ in patients with a broad smile. In such patients the open gingival embrasure between the maxillary central incisors interferes with the esthetics of their smile. An embrasure is considered to be open whenever it is located in the cervical position below the approximal contact point and not completely filled in by gingiva.²



Black Triangle



Diastema

A diastema differs from a black triangle in that it is a complete space between two teeth without any approximal contact. On the other hand, in the black triangle scenario there is contact between the incisors with space in the cervical region. Diastemas may

result from agenesis or malformation of lateral incisors, hypertrophic labial frenum, bone/dental discrepancy, habits, or by a relapse following orthodontic treatment. Black triangles can result from a variety of circumstances such as:^{2,4,5}

- Secondary consequence of periodontal disease or periodontal surgical therapy
- Stretching of gingival fibers
- Periodontal attachment loss with a resultant gingival recession
- An excessive distance from the alveolar bone to the approximal contact

- A tight approximal contact near the incisal edge
- Excessively divergent roots
- Triangular shaped crowns

The mean prevalence of black triangles in adolescent patients after the correction of malposed incisors was reported to be 41.9%³ and 38% in adult orthodontic post-treatment patients.² Adult patients are usually more demanding in terms of esthetics, periodontal alterations, and expectations of less treatment time. Black spaces affect the esthetics of the smile and may affect periodontal health due to chronic retention of food debris and subsequent gingival inflammation and abnormal gingival morphology. Therefore, a correct diagnosis and treatment plan are relevant to prevent, minimize, and correct the problem.^{2,3,6} Due to the high incidence of open gingival embrasure, Burke et al.³ suggest this problem needs to be discussed with the patient before undergoing orthodontic treatment.

Triangular-shaped incisor crowns usually overlap before treatment. Once the teeth are straightened black triangles formerly masked by the crooked teeth may become apparent. The care provider should be able to detect and discuss this possibility with the patient before treatment.⁷

Arch length can be influenced by how much teeth are tipped. Therefore, its possible to increase the arch length by changing crown angulation.^{8,9} However, the position of roots must also be considered because tipping the central incisors mesially to close space and creating excessively divergent roots through the use of improper bracket placement can cause an open gingival embrasure.¹⁰

The loss of the interdental papilla may cause esthetic deformities as well as problems related to speech and food impaction.^{11,12} The vertical distance from the bone base to the approximal contact is a determinant factor concerning the presence or absence of a papilla. Patients with advanced periodontitis are always at high risk for a black triangle. Special care must be taken with patients undergoing orthodontic treatment who have had non-surgical periodontal therapy for advanced periodontal disease in order to avoid the normal marked interdental recession that can result.¹⁰

When the distance between the alveolar bone crest and the gingival papilla is less than 5 mm, the papilla fills in the interdental space in 100% of the cases; when the distance equals 6 mm, the papilla is present in 56% of the cases; and when it is greater than 7 mm, the papilla is present in 27% (or less) of the cases.^{11,12}

If the black triangle is the result of triangular anatomy of the adjacent crowns, then treatment will involve re-contouring the approximal crown surfaces to enlarge the contact point and move it cervically to fill the space. Composite resin is commonly used as a restoration which is slightly inserted into the gingival sulcus to function as a

dento-gingival architecture to guide the shape of the interdental papilla. Besides the development of the interdental papilla, “stops” can be made out of modeling resin to help open the gingival parabolic shape in a horizontal direction.¹³ Worn crowns have a reduced and displaced contact area with higher width/length ratios than unworn crowns.¹⁴ Thus, it is important to consider both morphology and proportionality in order to fulfill the orthodontic treatment objectives of an approximate 80% width/height ratio considered the ideal for maxillary central incisors.¹⁴ Furthermore, the appropriate ratio for the connector between central incisors is 50% of tooth height; central and lateral incisor connector is 40% of the central incisor height; and lateral incisor and canine connector is at 30% of the central incisor height. Embrasures are smallest between central incisors and grow larger as they progress posteriorly in dentition.¹²

Clinical Report

Figure 1 is an example of the wrong approach to close a midline diastema. The “black triangle” was formed as a result of the mesial inclination of maxillary central incisors to close the space without regard for maintaining root parallelism.

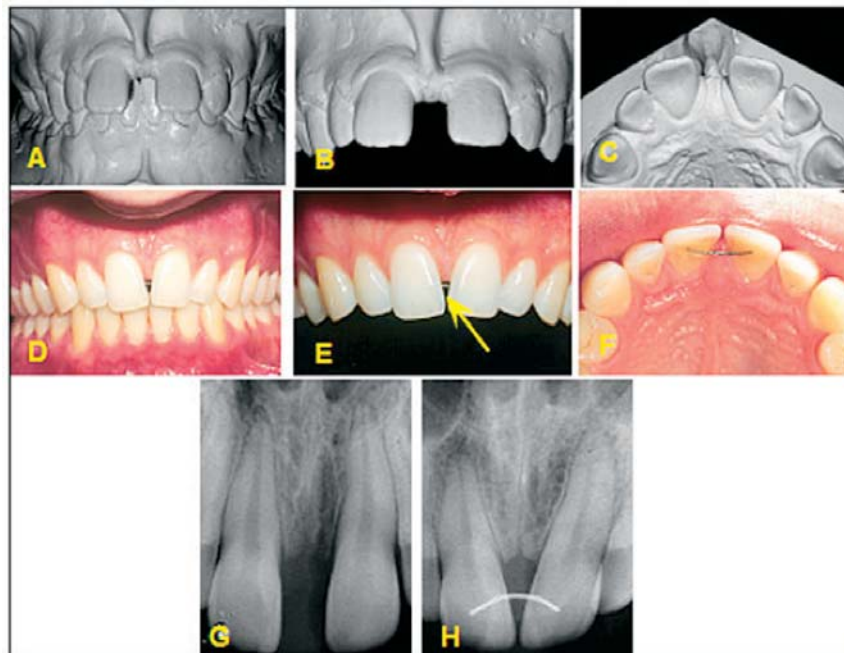


Figure 1. A-C. Large pre-treatment diastema. D-F. Space closure with no attention paid to root parallelism and the resultant “black triangle” (arrow). G and H show on the periapical radiographs the lack of roots parallelism.

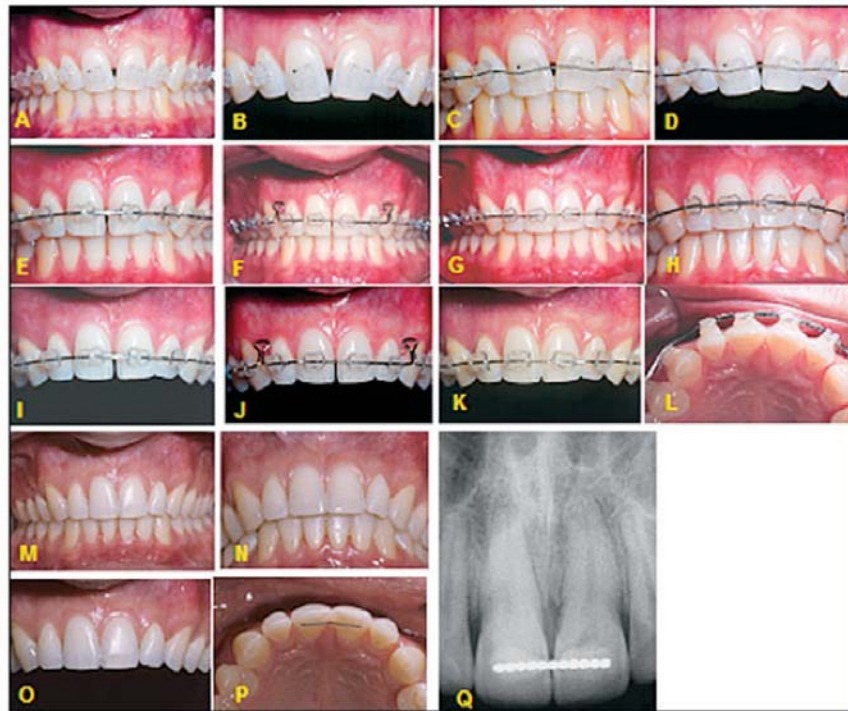

Figure 2. A-D. Re-treatment with the brackets positioned correctly and a .0175" coaxial arch wire correcting the problem at initial stages of treatment. E-L. Rectangular arch wires with closing loops associated with elastomeric chains helped to close the black triangle. M-P. Finished case with teeth inclination achieved. Spaces maintained distally of lateral incisors for composite restoration. Q. Ideal root parallelism and retention wire bonded on the lingual surface of maxillary central incisors.

Figure 2 shows the correct way to close a "black triangle" and achieve root parallelism when orthodontic brackets were positioned correctly, along with a 0.0175 coaxial arch wire at the initial stages of treatment. Closing loops associated with elastomeric chains were used. Ideal root parallelism was achieved and retention was provided by a wire bonded on the lingual surface of maxillary incisors.

Discussion

Since the mean prevalence of cervical diastemas in post-treatment adult orthodontic patients is about 38%, according to Kokich et al.,⁵ precautions must be taken during the early stages of leveling and alignment, when treating severely malaligned maxillary central incisors in adults seeking orthodontic therapy. Burke et al.³ reported a 41% prevalence of esthetic problems such as the black triangle between maxillary central incisors previously overlapped among 15% of patients who had undergone orthodontic treatment.

The prevalence of open gingival embrasures is greater in orthodontic patients over 20 years of age, and it is more likely to occur due to resorption of the alveolar crest rather than extrusion of the mandibular incisors.^{6,15} Open gingival embrasures were found in 43.7% of the subjects undergoing orthodontic treatment. No statistically significant differences between the subjects with slight, moderate, and severe mandibular incisor crowding was found in a group with open gingival embrasures. Similar percentages of subjects with open gingival embrasures were found in both treatment duration groups.¹⁵ Orthodontic patients showed significantly more alveolar bone loss radiographically than did the untreated patients. The greatest alveolar bone loss was noted in the closed extraction spaces, particularly on the pressure side of the retracted canines.¹⁶ Thus, the incidence of opening the gingival embrasure may be caused by alveolar bone loss secondary to orthodontic treatment.

A positive relationship between age and bone loss and a negative relationship between initial bone level and subsequent bone loss was revealed. No association was found between bone loss and length of treatment, post-treatment gingival appearance, amount of horizontal or vertical tooth movement, or treatment with maxillary osteotomy. These results show the risk appears to increase with age. However, previous attachment loss is not a risk factor which determines the length or type of treatment, nor does the amount of tooth movement influence additional attachment loss to any major extent.¹⁷

Tarnow¹¹ conducted a study to determine whether the distance between the approximal contact point and the crest of bone had any influence on the presence or absence of the interproximal papilla in humans. When the distance was 5 mm or less, an interdental papilla was almost always present. When the distance was 7 mm or more, the papilla was usually missing, while at 6 mm (only 1 mm less) it was present 56% of the time with an unknown significant difference between these three measurements.

According to Sarver¹² approximal contact points are defined as the exact place where the teeth touch as they progress posteriorly. Contact between anterior teeth is when they actually touch and connector is where teeth appear to touch. The appropriate ratio for connector between central incisors is 50% of the tooth height. On the other hand, the contact point between the central incisors is closer to the incisal third rather than in the center of the clinical crown in most cases. This feature, inherent to the central incisors, might explain their greater propensity for the occurrence of black triangles.¹⁸

Threshold levels vary among orthodontists, general dentists, and lay people in terms of when an open gingival embrasure is noticeably less attractive in an ideal smile.⁵ For the orthodontist, the acceptable length of the open gingival embrasure was 2 mm while the general dentist and lay people were unable to detect an open gingival embrasure unless it was at least 3 mm. This variation in the acceptable levels of an open embrasure may aid the dental professional in making specific treatment recommendations.

Orthodontic correction is indicated whenever the roots are divergent and the crowns converge toward one another. Treatment should be designed to create parallelism of the roots and a favorable position of the approximal contact point of the crowns. In cases where incisors are malposed or overlapped they should be uprighted and moved mesially to correct the inclination of the roots. The mesial cemento-enamel junctions of each incisor will then be closer causing the stretched transeptal fibers to relax. The same soft tissue will fill in the gingival embrasure, which will then be narrower.³

Kokich¹⁹ proposed the recontouring of the mesial surface of the central incisor that is triangular shaped with both roots aligned and parallel. As the diastema is closed, the approximal contact moves gingivally while the papilla moves incisally resulting in the elimination of the open gingival embrasure. In some cases restoration of the incisal edge is required after orthodontic treatment.

If the loss of papillary height is due to soft tissue damage by a oral hygiene device then interproximal hygiene procedures must be discontinued to allow for tissue recovery then modified to eliminate or minimize continued trauma to the papillae.²⁰ Meguro²¹ suggested the use of laser irradiation to prevent or minimize the occurrence of post-orthodontic treatment black triangles, since it reduces the levels of E2 prostaglandine (E2PG) and plasmin activator which are responsible for inflammation of the gingival tissue during orthodontic treatment.

Papillary reconstruction may also be employed to solve the problem of a black triangle. However, the outcome is unpredictable and involves a risk of cicatricial contraction and necrosis of the conjunctive grafted tissue. The evolution of surgical techniques may eventually lead to an increase in clinical success with positive clinical results.²² Using orthodontic extrusion, the migration of the gingival tissue incisally may restore the interdental papilla and bring harmony in a black triangle patient's smile.²² However, in cases of triangular roots extrusion may exacerbate the black triangle. In this case enamel stripping at the mesial and recontouring at the distal might be indicated to improve

esthetics and achieve stable results. A removable prosthesis may also be employed in the region of the gingival embrasure spaces of markedly compromised dentitions, whenever psychological implications of having such profound gingival retractions are serious.¹⁰

Reconstruction of the maxillary midline papilla following a combined orthodontic-periodontic treatment at the end of orthodontic treatment in adult periodontal patients is predictable in patients with either thin or wide gingival.²⁴ However, Nemcovsky²⁵ states both clinical and histological longitudinal studies are required to establish predictability and stability of the reconstruction. Moreover, in order for a papillary reconstruction to be performed successfully the tissue should not have a loss of insertion at the periodontal junction. This condition would favor development of a periodontal pocket in that region. Carnio²² showed complete papilla reconstruction in a 20-year-old woman using an interposed subepithelial connective tissue graft to treat the loss of interdental papillae and achieving long-term success and stability.

It has been suggested the variation in morphology of the human periodontium may be related to the shape and form of the teeth. This observation tends to confirm the hypothesis that subjects with long and narrow teeth have a comparatively thin periodontium and may be more susceptible to gingival recession than subjects who belong to a "biotype" with large maxillary central incisors and a thick periodontium.²⁶

A thin gingiva may serve as a *locus minoris resistenciae* for developing soft tissue defects in the presence of plaque-induced inflammation or as a result of tooth brushing trauma.²⁰ Therefore, triangular shaped incisors are more susceptible to an open gingival embrasure once their vertical distance from the approximal contact point to the alveolar crest is increased for two reasons:

1. They have a small and occlusally located contact point.
2. The soft tissue is more likely to be damaged once it becomes inflamed.

Moreover, Becker et al.,²⁷ in a study using dry skulls, observed no significant differences when tooth shapes were compared with bone anatomy. Turverson⁹ also reported triangular teeth present contact points rather than contact areas which makes them more instable and more susceptible to crowding. Thus, preventive care is required during orthodontic tooth movement in patients with a thin gingival and triangular maxillary central incisor biotype.

Orthodontic extrusion is another alternative solution for the papilla loss problem in patients with triangular roots where the black triangle may be exacerbated. A removable prosthesis may also be applied in the gingival embrasure space areas in order to mask the black triangle.

The morphology of the coronal portion of central incisors presenting with a divergence of their mesial surfaces can be corrected by reduction of interdental enamel by stripping or by adding bonded composite material. The selective reduction of the mesio-distal enamel in patients that maintain good oral hygiene increases the contact areas providing more stability to the treatment.⁹ Nevertheless, the use of composites must be carefully assessed so as to prevent undue thickness that may cause plaque retention, compression of the papilla, and inflammation, leading to subsequent esthetic problems.³

All etiological factors and treatment alternatives associated with an open gingival embrasure must be discussed with the patient before embarking on orthodontic treatment. A multidisciplinary approach must be considered mandatory if a successful clinical outcome is to be achieved.

In the past decade there has been a remarkable upswing in interdisciplinary collaboration between dentists, orthodontists, and periodontists in terms of smile enhancement. Currently, an entire field of "cosmetic periodontics" has evolved in collaboration with cosmetic restorative dentistry. Through the interaction between different clinical disciplines and through the knowledge gained, the definition of a desirable smile has been refined and included in the finishing stage of anterior

esthetics for our patients¹² while retaining the consideration and respect for individual variations.

Conclusion

Several methods of managing patients with open gingival embrasure exist, but the interdisciplinary aspects of treating must be emphasized to provide

the best possible result. Orthodontists can play a significant role in helping to manage these cases.

Clinical Significance

Various treatment strategies are available to treat cases of an undesirable black triangle and are dependent on the etiology of the condition.

References

1. Hasanreisoglu U, Berksun S, Aras K, Arslan I. An analysis of maxillary anterior teeth: facial and dental proportions. *J Prosthet Dent* 2005; 94:530-8.
2. Kurth JR, Kokich VG. Open gingival embrasures after orthodontic treatment in adults: Prevalence and etiology. *Am J Orthod Dentofacial Orthop* 2001; 120:116-23.
3. Burke S, Burch JG, Tetz JA. Incidence and size of pretreatment overlap and posttreatment gingival embrasure space between maxillary central incisors. *Am J Orthod Dentofacial Orthop* 1994; 105:511.
4. Kokich, VG. Esthetics: the orthodontic-periodontic restorative connection. *Semin Orthod* 1996; 2:21-30.
5. Kokich JR, Kyak HA, Shapiro PA. Comparing the perception of dentists and lay people to altered dental aesthetics. *J Esthet Dent* 1999; 11:311-24.
6. Ko-Kimura N, Kimura-Hayashi M, Yamaguchi M, Ikeda T, Meguro D, Kanekawa M, Kasai K. Some factors associated with open gingival embrasures following orthodontic treatment. *Aust Orthod J* 2003; 19:19-24.
7. Bennett JC. *The future of orthodontics*. Belgium:Leuven University Press; 1998.
8. Hussels W, Nanda RS. Effect of maxillary incisor angulation and inclination on arch length. *Am J Orthod Dentofacial Orthop* 1987; 91:233-9.
9. Turverson DL. Anterior interocclusal relations. Part I. *Am J Orthod* 1980; 78:361-70.
10. Zachrisson BU *Orthodontic and Periodontics. Clinical Periodontology and Implant Dentistry – Jan Lindhe*. 4th ed. 2005; 576p.
11. Tarnow DP, Magner, AW, Fletcher P. The effect of the distance from the contact point to the crest of bone on the presence or absence of the interproximal dental papilla. *J Periodontol* 1992; 63:995-6.
12. Sarver DM. Principles of cosmetic dentistry in orthodontics: Part 1. Shape and proportionality of anterior teeth. *Am J Orthod Dentofacial Orthop* 2004; 126:749-53.
13. Mondelli, José. *Estética e cosmética na clínica integrada restauradora*. São Paulo:Quintessence Ed; 2003.
14. Kokich VG, Spears FM, Guidelines for managing the orthodontic-restorative patient. *Semin Orthod* 1997; 3:3-20.
15. Ikeda T, Yamaguchi M, Meguro D. Prediction and causes of open gingival embrasure spaces between the mandibular central incisors following orthodontic treatment. *Aust Orthod J* 2004; 20:87-92.
16. Zachrisson BU, Alnaes L. Periodontal condition in orthodontically treated individuals. II Alveolar bone loss: radiographic findings. *Angle Orthod* 1974; 44:48-55.
17. Nelson PA, Artun J. Alveolar bone loss of maxillary anterior teeth in adult orthodontic patients. *Am J Orthod Dentofacial Orthop* 1997; 111:328-34.
18. Rufenacht, CR. *Principles of Esthetic Integration*. São Paulo:Quintessence Pub Co;2000.
19. Kokich VG, Kokich VO. Maximizing anterior esthetics: an interdisciplinary approach. In McNamara JA Jr, editor. *Frontiers in dental and facial esthetics. Craniofacial Growth Series*. Ann Arbor: Center for Human Growth and Development. University of Michigan:Needham Press; 2001. p.1-18.
20. Wennström JL, Prato GP. *Mucogingival Therapy – Periodontal Plastic Surgery. Clinical Periodontology and Implant Dentistry – Jan Lindhe*. 4th ed 2005; 576p.

21. Meguro D, Yamaguchi M, Kasai K. Laser irradiation inhibition of open gingival embrasure space after orthodontic treatment. *Aust Orthod J* 2002; 18:53-63.
22. Carnio J. Surgical reconstruction of interdental papilla using an interposed subepithelial connective tissue graft: a case report. *Int J Periodontics Restorative Dent* 2004; 24:31-7.
23. Francischone CE, Costa CG, Francischone AC, Ribeiro HT, Silva RJ. Controlled orthodontic extrusion to create gingival papilla: a case report. *Quintessence Int* 2002; 33:561-5.
24. Cardaropoli D, Re S, Corrente G, Abundo R. Reconstruction of the maxillary midline papilla following a combined orthodontic-periodontic treatment in adult periodontal patients. *J Clin Periodontol* 2004; 31:79-84.
25. Nemcovsky CE. Interproximal papilla augmentation procedure: a novel surgical approach and clinical evaluation of 10 consecutive procedures. *Int J Period Res Dent* 2001; 21:553-9.
26. Olsson M, Lindhe J. Periodontal characteristics in individuals with varying form of the upper central incisors. *J Clin Periodontol* 1991; 18:78-82.
27. Becker W, Ochselbein C, Tibbetts L, Becker BE. Alveolar bone anatomic profiles as measured from dry skulls. Clinical ramifications. *J Clin Periodontol* 1997; 24:727-31.

About the Authors

Orlando Motohiro Tanaka, DDS, MSc, PhD



Dr. Tanaka is a Senior Professor in the Graduate Dentistry Program (Orthodontics) at the Pontifical Catholic University of Paraná in Curitiba, Brazil. He is a Diplomate of the Brazilian Board of Orthodontics and Dentofacial Orthopedics.

e-mail: tanakaom@gmail.com

Bruno D'Aurea Furquim, DDS



Dr. Furquim is a Dentist – Pontifical Catholic University of Paraná, Curitiba, Brazil and a Master of Science Student – Orthodontics USP-BAURU, Brazil.

e-mail: brunofurquim@ortodontista.com.br

Renata Corrêa Pascotto, DDS, MSc, PhD



Dr. Pascotto is an Adjunct Professor in the Department of Dentistry at Estate University of Maringá, PR, Brazil.

e-mail: rpascotto@uol.com.br

Gerson Luiz Ulema Ribeiro, DDS, MSc, PhD



Dr. Ribeiro is an Associate Professor at the Federal University of Santa Catarina, Florianópolis, SC, Brazil. He is a Diplomate of the Brazilian Board of Orthodontics and Dentofacial Orthopedics.

e-mail: gersonlr@expresso.com.br

José Antonio Bósio, DDS, MSc



Dr. Bósio is a Diplomate of the American Board of Orthodontics and the Brazilian Board of Orthodontics and Dentofacial Orthopedics.

e-mail: jbosio@bosio.odo.br

Hiroshi Maruo, DDS, MSc, PhD



Dr. Maruo is a Senior professor in the Graduate Dentistry Program (Orthodontics) at the Pontifical Catholic University of Paraná in Curitiba, Brazil. He is a Diplomate of the Brazilian Board of Orthodontics and Dentofacial Orthopedics.

e-mail: h.maruo@pucpr.br