



Surgical Elevation of Bilateral Maxillary Sinus Floor with a Combination of Autogenous Bone and Lyophilized Bovine Bone

Danilo Barral Araujo, Elisângela de Jesus Campos, Marcos André Matos Oliveira, Max José Pimenta Lima, Gabriela Botelho Martins, Roberto Paulo Correia Araujo

ABSTRACT

Aim: Realize the surgery of sinus lifting floor to allow the installation of osseointegrated implants for oral rehabilitation, with the combination of different biomaterials, autogenous bone and lyophilized bovine bone.

Background: Oral rehabilitation using the installation of osseointegrated implants is an alternative surgical approach that results in the satisfactory form, function and esthetics of the dental units.

Case report: After clinical, dental and laboratory assessment, a 47-year-old female patient underwent full maxillary oral rehabilitation involving the installation of osseointegrated implants to allow her to meet the physiological demands of occlusion and mastication. It was found that the patient had fully pneumatized maxillary sinuses with insufficient height to anchor implants, with a loss of the vertical dimension of the occlusal and masticatory functions due to general dental loss, compounded by the use of ill-fitting dentures; hence, the choice was made to take autogenous bone from the patient's chin area and supplement it with lyophilized bovine bone as collateral for larger areas to be grafted. It was also decided to avulse the remaining tooth units due to their impairment by periodontal disease.

Conclusion: Bone grafts do not constitute suitable alternatives in the cosmetic and functional rehabilitation of the maxilla in patients requiring bilateral sinus elevation. The chin region provides bone tissue that, when complemented by lyophilized bovine bone grafts, ensures greater volume and less invasive surgery. In the case described here, a height gain of approximately 550% was obtained, making it possible to anchor seven implants.

Clinical significance: In this study, the surgical procedures used for grafting a combination of autogenous and lyophilized bovine bone, aimed to elevate the maxillary sinus floor to allow the installation of osseointegrated implants for oral rehabilitation.

Keywords: Maxillary sinus, Bone transplantation, Autograft, Dental implantation.

How to cite this article: Araujo DB, de Jesus Campos E, Oliveira MAM, Lima MJP, Martins GB, Araujo RPC. Surgical Elevation

of Bilateral Maxillary Sinus Floor with a Combination of Autogenous Bone and Lyophilized Bovine Bone. *J Contemp Dent Pract* 2013;14(3):445-450.

Source of support: Nil

Conflict of interest: None declared

BACKGROUND

Relevant aspects of oral rehabilitation can be addressed with the use of osseointegrated implants, an alternative approach that results in the satisfactory form, function and esthetics of dental units. However, the success of this type of surgical-prosthetic rehabilitation treatment requires adequate amounts of bone, the biological structure that supports or anchors dental devices so that the impacts of chewing are absorbed and tolerated.¹⁻⁴ Due to certain exceptional situations that can occur in the oral cavity, such as periodontitis, loss of teeth, traumatic extractions, cysts, tumors or trauma aggravated over time, the surgeon does not always find the most favorable conditions to accomplish rehabilitative treatments involving the installation of dental implants.⁵⁻¹⁰

To recover the ideal size dimensions lost by alveolar bone that has suffered resorption, particularly in edentulous patients, it is necessary to increase the height and width of the bone to accommodate implants of the appropriate size with an axial angle that adequately allows for future prosthesis.^{2,8}

Two dimensions must be taken into consideration regarding the material needed to anchor the implantation of these structures: height, which determines the length of the implants to be installed and, thickness which dictates the size of their turns and, consequently, their platform. Therefore, the greater the length and width of the implant

platform, the better the retention and distribution of loads along the bones of the jaws, leading to better recovery of lost function.^{2,4,8,11-15}

Such conditions can be met through surgical procedures known as bone grafts. Bone grafts can recover bone thickness in block or appositional dimensions, or even height, through a procedure known as the elevation of the maxillary sinus floor, which involves the introduction of particulate bone or biomaterials into the sinus cavity itself.

According to reports from specialized scientific literature, grafts have proven effectiveness and predictability when performed with the use of autogenous bone or with the help of bone substitutes to restore a sufficient amount of alveolar bone.¹⁶⁻¹⁸ The alternative method described here is intended to solve the pneumatization of the maxillary sinus, i.e. vertical bone resorption brought about by the absence of teeth. This resorption occurs specifically with the roots of posterior dental units, as these are close to the maxillary sinus and is accompanied by an expansion of the sinus membrane and a consequent increase of the sinus cavity, which is physiologically designed for heating and cleaning inspired air in the breathing process.^{9,10,19,20}

The filling of this cavity can be done with a number of diverse materials from different organic and inorganic sources from the laboratory and elsewhere. All of these materials will lead to an immunological response of a lesser or greater degree; however, the results should be predictable and postoperative sequelae should be minimal.² According to the literature, biomaterials can be defined as a substance or combination of two or more pharmacologically inert substances, whether natural or synthetic, which are used to improve, enhance or fully or partially replace tissues and organs.^{7,21}

Therefore, the ideal bone substitute should maintain mechanical stability and tissue volume during the early stages of healing and subsequently be supplied with new bone by osteoclast activity followed by the deposition of an osteoid matrix mediated by osteoblasts and mineralization.²² In the case described here, autogenous bone grafting was chosen in combination with lyophilized bovine bone.

CASE REPORT

A patient, female, mixed race, nonsmoker, of 49 years and 9 months of age, after thorough clinical evaluation, underwent complete oral maxillary rehabilitation using the installation of osseointegrated implants, to meet the physiological demands of occlusion and mastication with which she had reported difficulty.

Preliminarily, panoramic radiography was performed to analyze, in terms of quality and quantity, the bone structure

of the areas to be rehabilitated. Particular attention was given to the dimension of height because the patient reported the loss of dental units since approximately 15 years previously.

With the information from the imaging exam and data from the clinical examination, it was found that units 18 and 28 showed good periodontal health and satisfactory levels of bone attachment, while the other remaining dental units, 11, 21, 23 and 24, were in poor periodontal condition, making it impractical to maintain them in joint rehabilitation with the osseointegrated implants to be installed. These mobile dental units showed marked and severe horizontal bone resorption, indicating an advanced degree of periodontitis.

During the process of planning the treatment, certain conditions were found that needed to be resolved prior to the installation of the osseointegrated implants for the subsequent prosthetic rehabilitation. Initially, it was found that the patient had fully pneumatized maxillary sinuses, with insufficient height for the anchoring of implants. The heights, ranging from 1.98 mm in the region of the unit 16 to 3.92 mm in the region of unit 26, indicated that surgery was necessary to lift the maxillary sinus floor, as noted in Figures 1 and 2. However, the bone thickness was satisfactory, negating the need for appositional bone graft surgery.

To rehabilitate the jaw effectively, the choice was made to perform surgery for maxillary sinus lifting in the regions of units 14, 15, 16, 17, 26 and 27. However, as the areas to be grafted were relatively large, it was concluded that the amount of autogenous bone to be removed from areas identified as possible donors would not be sufficient. The mandibular branches, left and right, were relatively reduced and the chin by itself would generate a quantity that would not meet the need of the two jaw cavities.

Based on this diagnosis, it was decided to complement the autogenous bone taken from the patient's chin area with

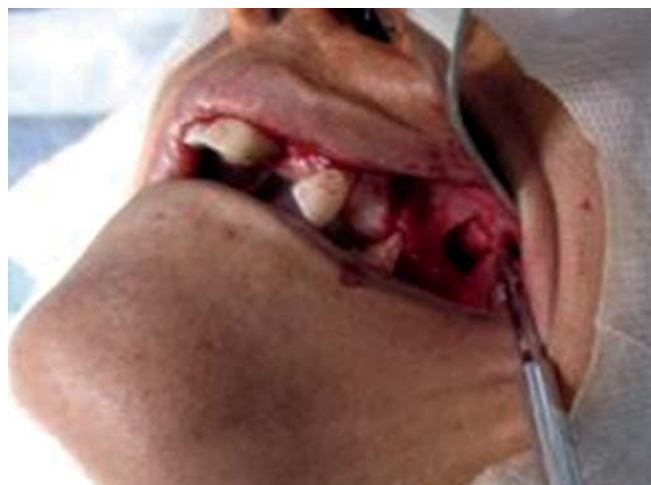

Fig. 1: Access to the left maxillary sinus

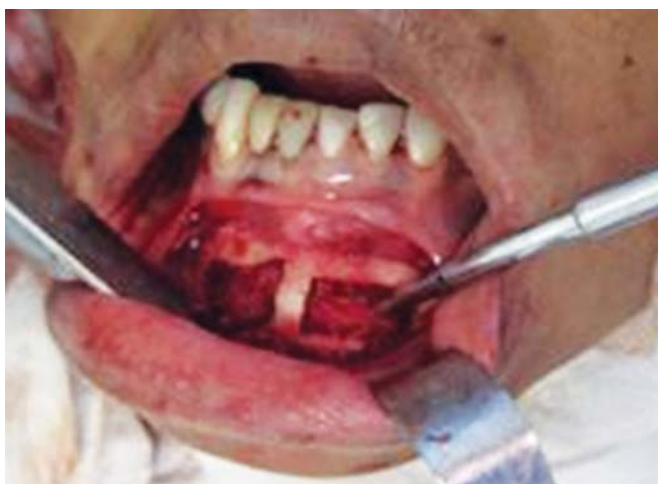

Fig. 2: Chin exposure

lyophilized bovine bone as a guarantee of greater volume for the area to be grafted. This approach would prevent the opening of a third surgical wound or a second surgical procedure to perform a new bone graft and would provide the filling for both cavities in the maxillary sinuses.

Given the timeline and the surgical steps necessary, it was decided to perform as a first step the bilateral lifting of the maxillary sinus floor. It was also decided to avulse units 11, 21, 23 and 24 and to install seven implants of various lengths and widths on grafted areas in the remaining alveoli 6 months after completion of the first surgical step. The 6 months waiting time would ensure the consolidation of the grafts.

After signing the term of free and informed consent (TFIC), the patient was prescribed a drug protocol consisting of 1 gm of oral amoxicillin cryohydrate to be taken 1 hour before the surgery to be performed and the oral administration of 500 mg of this antibiotic every 8 hours for seven consecutive days after surgery. The prescription also included the simultaneous use of 8 mg of oral dexamethasone 1 hour before surgery and 4 mg every 12 hours for 4 days after the surgical procedure; as well as 10 mg of ketorolac tromethamol, 1 hour before surgery and 1 tablet every 8 hours after surgery, depending on the intensity of pain. As an adjunct to oral prophylaxis, the patient was prescribed the pre- and postoperative use of a chlorhexidine mouthwash three times daily for 1 minute, limited to 10 days.

SURGICAL PROCEDURES

Local anesthetic infiltration was used, with a base of articaine hydrochloride at 4% and epinephrine at 1:100,000, in the areas under intervention. Surgical procedures began with incisions in the right and left alveolar ridges, followed by a relaxing incision on both sides to provide exposure of

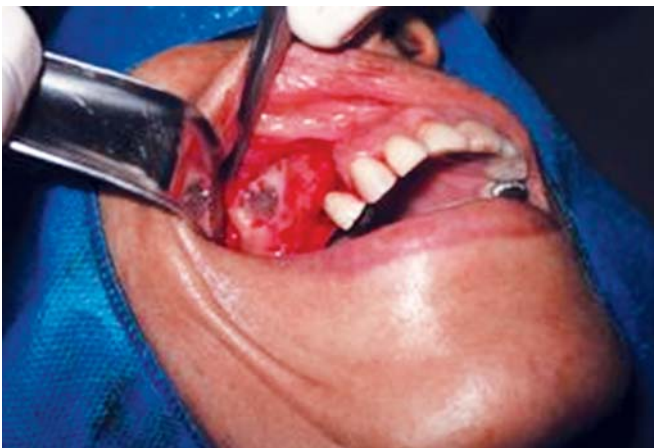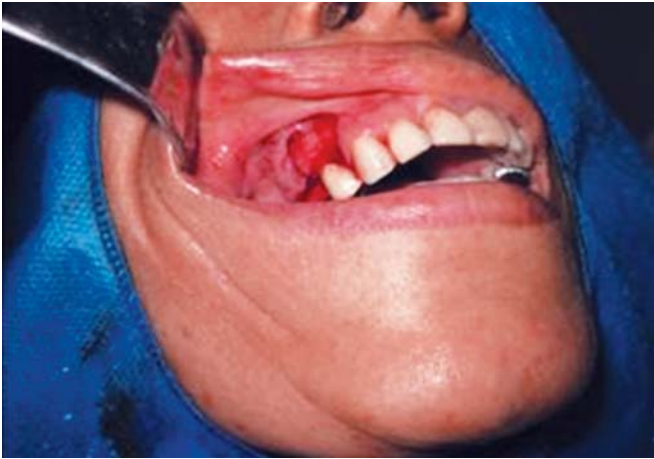the vestibular walls of the maxillary sinus. The next step was the opening of an access cavity for each maxillary sinus, as seen in Figure 1; to this end, a rotary handpiece (K9 PLUS/KAVO) equipped with a round diamond number 8 bur was used. This tool was irrigated with saline to neutralize the heat resulting from contact with the surgical drill in an attempt to reduce surgical trauma because the heat causes the destruction of bone osteoblasts and osteocytes. After exposing the receptor sites for the material to be grafted, it was decided to open the chin, the surgical space defined as donor, due to the higher amount of biological material that this area would provide in the case of the patient in the study. An incision was made in two steps in the region of the lower groove extending from canine to canine, in order to expose the chin and to ensure the removal of two bone blocks (Fig. 4).

After removing the bone blocks, the suture in the donor area was performed in two steps to re-enable it functionally; this was followed by the fragmentation of the same bone in a Muzimed® (Canoas, RS, Brazil) grinder and its combination with lyophilized bovine bone of the brand bioinnovation-Bonefill. After the formation of the mass of the resulting mixture of autogenous bone and lyophilized bovine bone was performed, the filling of the cavities in the maxillary sinuses on both sides was completed in a satisfactory manner followed by the suturing of the incised areas (Figs 3A and B). The surgery was completed without any complications.

After the 6 months required for the consolidation of the grafts, a significant gain in bone volume and height was found for all grafted areas, which led to the installation of the implants because the grafted areas had begun to show adequate bone height and thickness.

Comparing imaging tests before and after surgery (Figs 4 to 7), it is remarkable that the areas that had bone heights of only 1.98 mm before surgery had heights equivalent to 11.07 mm after surgery, i.e. a percentage gain of 550%.

During the second surgery, dental units 11, 21, 23, and 24 were avulsed, and the alveoli units 11 and 21 received immediate implants, both with platforms of 4 mm and lengths of 15 mm. The alveolus unit 24 also received an immediate implant with a 4 mm platform and 13 mm length. After the installation of these three implants in alveoli where dental units had been removed, four more implants were installed in the areas that were grafted 6 months prior. Of these, three implants were placed in the regions of units 16, 25 and 26, all with platforms of 4 mm and lengths of 11.5 mm, and a final implant was placed in the region of unit 14 with a smaller platform of 3.75 mm and the same length of 11.5 mm. No perioperative events were recorded during this second surgery (Fig. 8).



Figs 3A and B: Filling the cavity of the maxillary sinus

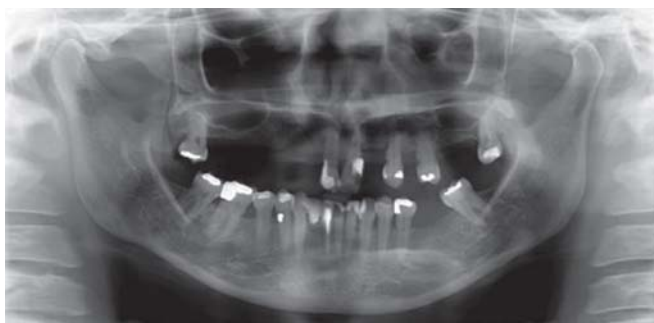

Fig. 4: Preoperative radiologic examination. Pneumatized maxillary sinuses; the bone heights were considered insufficient to anchor the implants

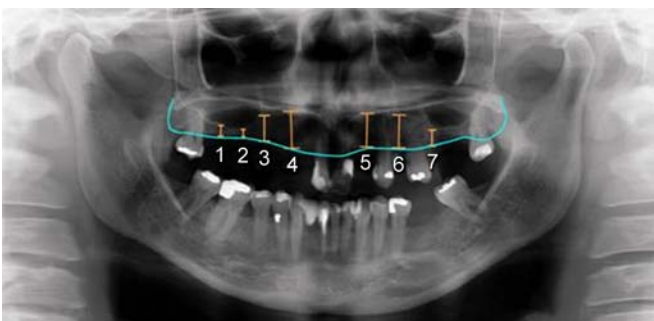


Fig. 5: Preoperative radiologic examination. Pneumatized maxillary sinuses; the bone heights were considered insufficient to anchor the implants

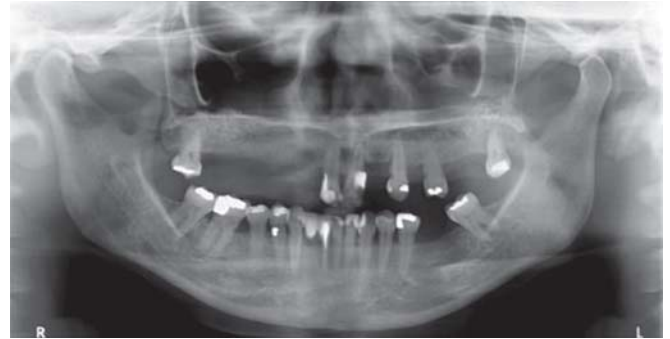

Fig. 6: Radiological examination of the patient's postoperative condition

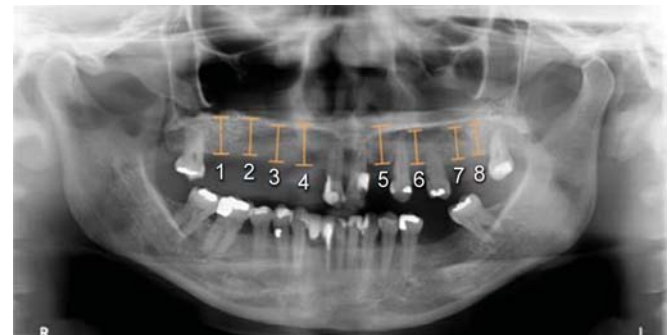


Fig. 7: Radiological examination of the patient's postoperative condition. The bone heights were considered sufficient for the anchoring of implants

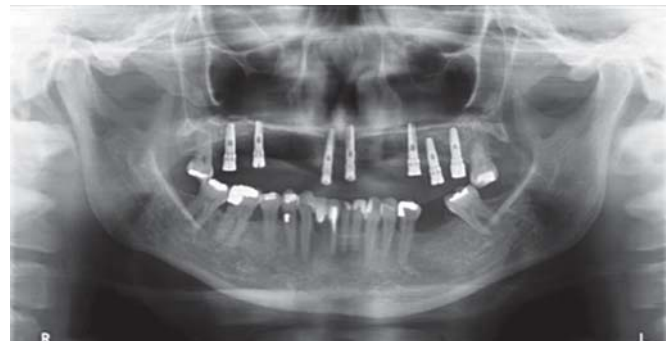

Fig. 8: Postoperative radiological examination of the installed implants

Six months after the surgery, which was the estimated time for osseointegration, the cicatrizers were installed and a Branemark protocol-style implant was made, which satisfactorily met the expectations of the patient (Fig. 9).

DISCUSSION

Current techniques of bone grafting for oral rehabilitation are considered satisfactory, both esthetically and functionally. For the choice of the donor area, one should take into account the amount of bone necessary to carry out the graft and to adopt minimally invasive surgical procedures. In this study, the autogenous bone taken from the patient's chin area and complemented by lyophilized bovine bone fully met the needs of the receptor beds,

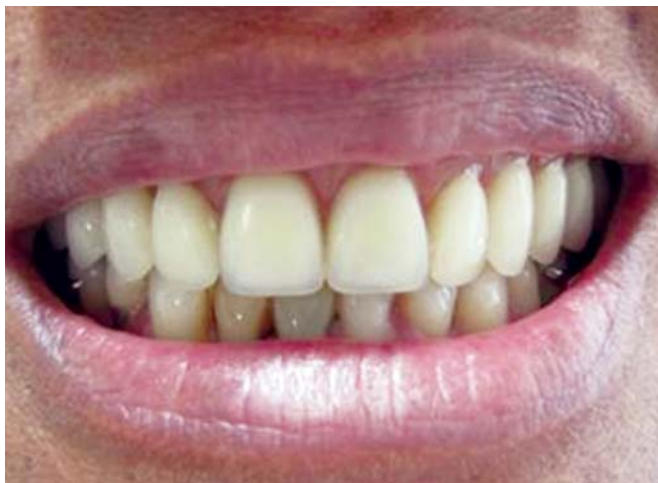

Fig. 9: Oral rehabilitation: Branemark protocol

ensuring that the volume of material was sufficient for the recovery of bone height essential for anchoring the seven planned implants. This treatment was also preferred because of the impossibility of using either the left or right mandibular branches as donor sites due to the reduced bone volume offered by these areas. Moreover, this choice resulted in surgical procedures that are considered less aggressive. The finding of pneumatized maxillary sinuses, which indicated insufficient bone height for successful implants, led to surgery to increase the heights of the maxillary sinuses, which had ranged from 1.98 mm to 3.92 mm but became 11.07 mm on average after surgery. This value can be considered high compared to other surgeries performed in similar situations or even to reports made in a significant portion of the specialized scientific literature. Although the use of autogenous bone is preferred to carry out intraoral grafts, the augmentation of autogenous bone with lyophilized bovine bone allows a guarantee of greater volume in the area to be grafted for patients who need extensive expansion of the height of the maxillary sinus to enable rehabilitation by prosthetic implants as in the case described here. As illustrated in the exam images, the extreme precariousness of the periodontium justified the replacement of the remaining teeth with implants. Finally, the drug coverage before and after surgery allowed the post-operative period to be well tolerated by the patient, whose recovery was uneventful. The patient's dental esthetics were improved as was the vertical dimension of occlusion and masticatory function that had been lost due to widespread tooth loss, which was increased by the use of ill-fitting dentures.

CONCLUSION

Bone grafts are suitable to other alternatives in the cosmetic and functional rehabilitation of the maxilla in patients

requiring bilateral sinus lift. The chin region provides a large amount of bone tissue, which when complemented by lyophilized bovine bone grafts, ensures greater volume and allows for the performance of less invasive surgical procedures. In the case described here, an average gain in bone height of approximately 550% was obtained, making it possible to anchor the seven implants.

CLINICAL SIGNIFICANCE

Oral rehabilitation using the installation of osseointegrated implants is an alternative surgical approach that results in the satisfactory form, function and esthetics of the dental units. In this study, the surgical procedures used for grafting a combination of autogenous and lyophilized bovine bone, aimed elevate the maxillary sinus floor to allow the installation of osseointegrated implants for oral rehabilitation.

ACKNOWLEDGMENT

The authors thank Pierre Fauchard Image Service—Radiology Bucco-Maxillofacial (www.imagempierre.com.br), represented by Mr Sérgio Ribeiro, MD for providing their services.

REFERENCES

1. Araújo Filho N. New bone formation in maxillary sinuses of monkeys elevated and with grafted with hydroxyapatite and platelet-rich plasma thesis. Rio de Janeiro, BR 2001;1-85.
2. Dalapicula SS, Vidigal Junior GM, Conz MB, Cardoso ES. Characteristics physicochemical of the biomaterials used of bone grafts: a critical review. *Implant News* 2006;3(5):487-491.
3. Tristão JW. Graft in maxillary sinus with hydroxyapatite and platelet-rich plasma—monograph. Rio de Janeiro, BR 2007; 1-65.
4. Gonçalves ARQ. The association of platelet-rich plasma with inorganic bovine bone in maxillary sinus grafts induces new bone formation (monograph)? Rio de Janeiro, BR: 2008;78.
5. Lindhe J, Karring T, Lang NP. *Tratado de Periodontia Clínica e Implantologia Oral*. (Clinical Periodontology and Implant Dentistry), 4th ed. Guanabara Koogan, Rio de Janeiro, BR 2005; 1-1013.
6. Zerbo IR, Zijderveld SA, de Boer A, et al. Histomorphometry of human sinus floor augmentation using a porous beta tricalcium phosphate: a prospective study. *Clin Oral Impl Res* 2004;15(6): 724-732.
7. Conz MB, Granjeiro JM, Soares GA. Physicochemical characterization of six commercial hydroxyapatite for medical-dental applications as bone graft. *J Appl Oral Sci* 2005;13(2): 136-140.
8. Scarano A, Degidi M, Iezzi, et al. Maxillary sinus augmentation with different biomaterials: a comparative histologic and histomorphometric study in man. *Implant Dent* 2006;15(2): 197-207.
9. Contar CMM, Sarot JR, Bordini Jr J, Galvão GH, Nicolau GV, Machado MAN. Maxillary ridge augmentation with fresh-frozen bone allografts. *J Oral Maxillofac Surg* 2009;67(6):1280-1285.

10. Buser D, Dahlin C, Schenk RK. Guided bone regeneration in implant dentistry. Quintessence Publishing Co. Inc., Chicago, USA 1994;1-265.
11. Benke D, Olah A, Molher H. Protein-chemical analysis of Bio-Oss bone substitute and evidence on its carbonated content. *Biomaterials* 2001;22(9):1005-1012.
12. Hallman M, Sennerby L, Lundgren S. A clinical and histologic evaluation of implant integration in the posterior maxilla after sinus floor augmentation with autogenous bone, bovine hydroxiapatite, or a 20:80 mixture. *Int J Oral Maxillofac Implants* 2002;17(5):635-643.
13. Hassani A, Khojasteh A, Shamsabad AN. The anterior palate as a donor site in maxillofacial bone grafting: a quantitative anatomic study. *J Oral Maxillofac Surg* 2005;63(8):1196-2000.
14. Artzi ZTH, Dayan D. Porous bovine bone mineral in healing of human extraction socket. Part 1: Histomorphometric evaluations at 9 months. *J Periodontol* 2007;71(6):1015-1023.
15. Gonçalves ARQ, Maior CMV, Mattos FR, Gigli RE, Motta SHG. Evaluation the success of osseointegrated implants in maxillary sinus grafts RGO 2008;56(4):423-427.
16. Spiekermann H, Donath K, Hassell T, Jovanovic S, Richter J. Biomechanics, color atlas of dental medicine implantology. Thieme Medical Publishers, New York, USA 1995;1-388.
17. Wenz B, Oesch B, Horst M. Analysis of the risk of transmitting bovine spongiform encephalopathy through bone grafts derived from bovine bone. *Biomaterials* 2001;22(12):1599-1660.
18. Indovina A Jr, Block MS. Comparison of 3 bone substitute in canine extraction sites. *J Oral Maxillofac Surg* 2002;60(1):53-58.
19. Cruz GA, Sallum EA, Toledo S. Morphological study of bone substitutes by using scanning electron microscopy. *R Periodontia* 2007;17(1):39-46.
20. Baptista AD, Sorrilha A, Tormes TAM, et al. A histological study of human allografts, *Acta Ortop Bras* 2003;11(4):220-224.
21. LeGeros RZ. Properties of osteoconduction biomaterials: calcium phosphates. *Clin Ortho Res* 2002;395:81-98.
22. Novaes AB Jr, Novaes AB. Procedimentos cirúrgicos em periodontia e implantodontia. ARTMED. Porto Alegre, BR. 1st ed. São Paulo 2004:299p.

ABOUT THE AUTHORS

Danilo Barral Araujo (Corresponding Author)

Professor, Department of Biofunction, Federal University of Bahia Bahia, Brazil, e-mail: danilobarral81@hotmail.com

Elisângela de Jesus Campos

Professor, Department of Biofunction, Federal University of Bahia Bahia, Brazil

Marcos André Matos Oliveira

Professor, Department of Surgery, IAPPEM, Bahia, Brazil

Max José Pimenta Lima

Professor, Department of Biofunction, Federal University of Bahia Bahia, Brazil

Gabriela Botelho Martins

Professor, Department of Biofunction, Federal University of Bahia Bahia, Brazil

Roberto Paulo Correia Araujo

Professor, Department of Biofunction, Federal University of Bahia Bahia, Brazil