

CLINICAL TECHNIQUE

Osseointegrated Silicone Finger Prosthesis using Dental Implants: A Renovated Technique

¹Dileep Nag Vinnakota, ²V Vijay Sankar, ³Naveen Chirumamilla, ⁴V Vamsikrishna Reddy

ABSTRACT

Aim and background: In clinical practice, we come across patients with traumatically amputated or congenitally missing partial or complete fingers that can be restored using microsurgical replantation or transplantation procedures. However, in some cases this might not be possible due to systemic or local factors and the lost or missing part has to be replaced prosthetically to offer psychological and functional wellbeing. These prostheses can be constructed with various materials like acrylics or silicone retained with the help of auxiliary aids. However, these prostheses cause some hindrance in performing functions like writing, typing, etc. The aim of the present trial was to ameliorate the existing design of implant supported finger prosthesis.

Technique: Distal phalange of middle finger replaced with implant supported silicone finger prosthesis is modified by utilizing a metal framework to support silicone material to improve rigidity while working.

Conclusion and clinical significance: We could achieve a good function, esthetics and tactile sensibility with this modified design. Whenever, feasible this design can improve the performance and patients feel a deep sense of satisfaction and improved self-esteem with this modified prosthesis.

Keywords: Finger, Implant, Prosthesis, Silicone.

How to cite this article: Vinnakota DN, Sankar VV, Chirumamilla N, Reddy VV. Osseointegrated Silicone Finger Prosthesis using Dental Implants: A Renovated Technique. *J Contemp Dent Pract* 2014;15(6):818-820.

Source of support: Nil

Conflict of interest: None

INTRODUCTION

Complete or partial amputation of finger/s is the most common form of body amputations.¹ Immediate replantation of the lost finger or transplantation with procedures such as toe-to-finger transfers, lengthening procedures and osteocutaneous flaps are possible with the help of

microsurgical reconstruction techniques.² However, when surgical techniques are not successful, unacceptable, or inadvisable, rehabilitation of amputated part is a useful alternative. The primary intention of prosthetic rehabilitation is to restore the form and resolve functional deficiencies of hand such as loss of grasp, strength, transmitting sense of pressure and position, protecting the sensitive stump as well as to obviate social and psychological problems. Digital prostheses were made of acrylic resin or silicone; with vacuum effect as a mode of retention,^{1,3-5} the major drawback being instability and lack of sensibility.⁶ As they lack the major determinant factor in the success of any prosthesis, i.e. retention, implant supported rehabilitation has been opted by many with successful osseointegration of implants reported in literature.⁷⁻¹⁴ The advantage of this type of rehabilitation is the provision of some level of tactile sensation to the patients, make perception of pressure and vibration possible. However, the silicone prosthesis that is retained using an implant has got its own inadequacy of being less rigid to totally transfer the sensations whilst performing tasks.¹⁵ Thus, there is a need to precisely alter the design of the prosthesis to improve its functional capacity. Hence, this paper presents the use of an osseointegrated dental implant for the retention of a digital prosthesis made of silicone supported by a metal framework in patients reported with traumatic amputation of a single finger tip.

TECHNIQUE

After radiographic evaluation to determine the required width and length of the implant, a local flap should be raised on the stump to expose the distal part of the bone and an osteotomy should be performed. A single stage overdenture implant of suitable dimensions should be placed longitudinally into the medullary canal in the middle phalange of middle finger. The skin flaps should be sutured back in place and the implant left unloaded for 3 months to allow for osseointegration (Fig. 1) after which a confirmation radiograph should be taken.

A custom made tray should be fabricated using self-polymerizing acrylic resin, a O-ring placed on the ball head of the implant with a retentive rubber inside and impression made using addition silicone rubber base material. The O-ring should be removed from the impression

^{1,2,4}Reader, ³Postgraduate Student

¹⁻⁴Department of Prosthodontic Dentistry, Narayana Dental College and Hospital, Nellore, Andhra Pradesh, India

Corresponding Author: Dileep Nag Vinnakota, Reader Department of Prosthodontic Dentistry, Narayana Dental College and Hospital, Nellore, Andhra Pradesh, India, Fax: +91-861-2305092, e-mail: dileepnagmds@yahoo.co.in

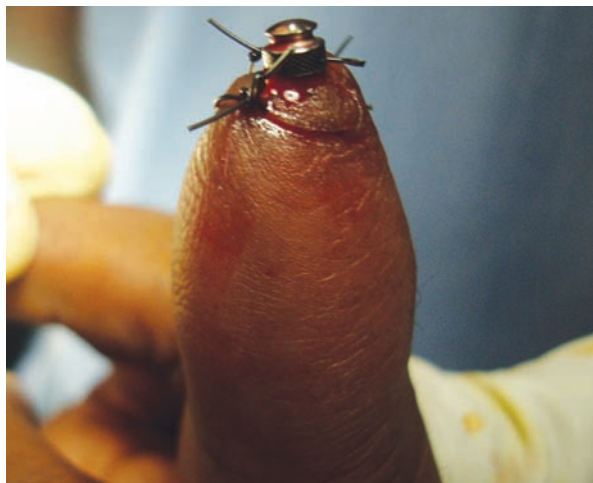

Fig. 1: Flaps sutured with O-ring in position



Fig. 2: Fabrication of meshwork for picking up of O-ring

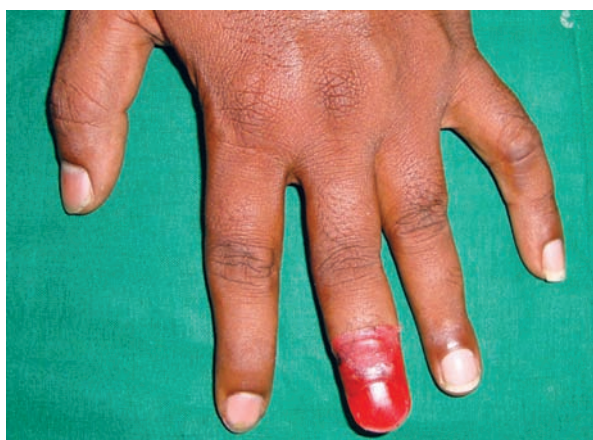

Fig. 3: Wax pattern on the meshwork

and mold space left after removal should be poured with pattern resin and rest of the impression poured with type IV dental stone. The cast should be removed from the impression, layered with modeling wax (to create space for the silicone material to flow) and duplicated with agar material. Phosphate bonded refractory material should be poured into the negative mold of agar to replicate the amputated finger, the refractory cast removed and a pattern for mesh work adapted and casted with cobalt chromium metal alloy (Fig. 2). Considering the contralateral finger as control a wax pattern for the missing phalange should be adapted on the metal frame work along with a provision for the finger nail and wax trial should be done (Fig. 3). The wax pattern along with the metal frame work should be secured to the pattern resin (area simulating the O-ring) of the cast using resin modified glass ionomer cement and flaked using type IV dental stone. Lost wax technique can be used to create the mold, after which the framework secured in the mold (as it is cemented to the pattern resin) should be coated with an oil paint to mask the color of the metal. Silicone should be mixed as per manufacturer's instructions and intrinsically stained in order to match the color of dorsal and ventral surface of the hand, (Fig. 4) and layered into the mold, transferred

to a clamp and processed at 100°C for 30 minutes. After processing, the prosthesis should be retrieved from the mold and excess silicone trimmed using scissors. The fit of the prosthesis should be evaluated on the patient, and the color matching improved under day light using oil colors for external pigmentation. Commercially available acrylic nail should be obtained, trimmed and polished to adapt to the nail bed that has been created on the silicone finger prosthesis which can be secured in place using cyanoacrylate. The O-ring should be picked along with the prosthesis using resin cement (Fig. 5). Instructions for maintaining the hygiene of the appliance should be given for the patients and periodically recalled.

DISCUSSION

An effective digital prosthesis should not only ameliorate the cosmetic appearance but also improve the function of the hand and when blended skillfully these will alleviate the patient from the psychological trauma. Hence, restoring function while attaining a best cosmetic result should be the prime objective during rehabilitation. Various materials and modes of retention^{1,3-9} have been tried for the rehabilitation of the amputated finger, and silicone material with implant mode of retention have given best promising results in achieving the desired effects. Silicone prosthesis has been proved to have high acceptance, esthetics, overall durability, stain resistance and ability to desensitize and protect the injured tip.^{4,5} Though silicone prosthesis is proved to be beneficial in many aspects compared to other materials, the rigidity of the material is to a lesser extent and considerable loss of sensitivity whilst performing their tasks has been reported.¹⁵ Hence, we modified the design by incorporating a metal frame work to increase the rigidity of the prosthesis. This new design also improved the tactile sensation for the patient due to the transfer of tactile stimuli from the digit to intraosseous nerves via the

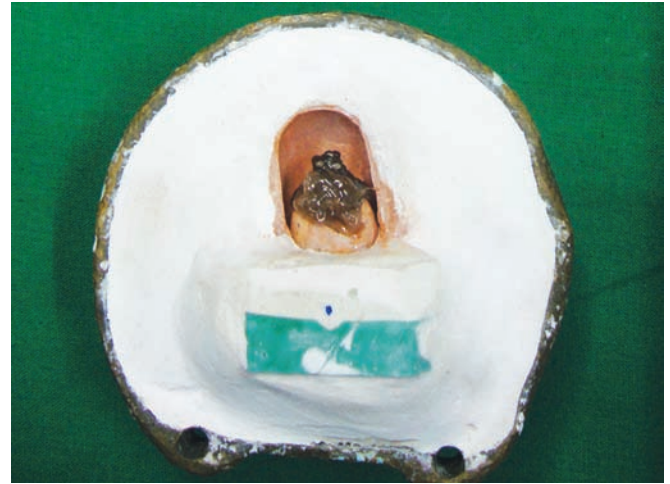
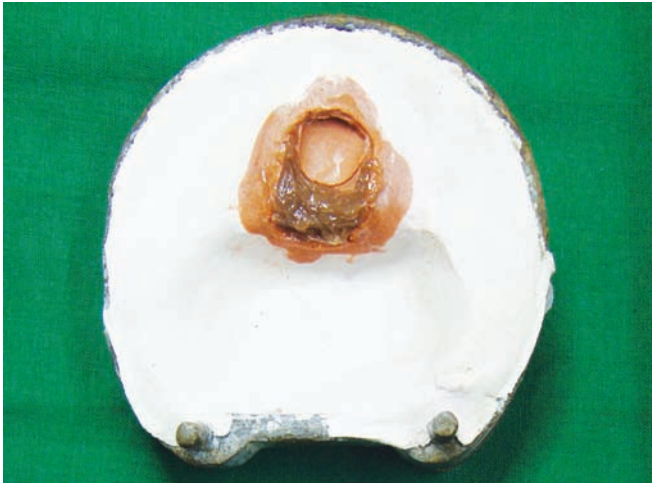

Fig. 4: Flasking of silicone material

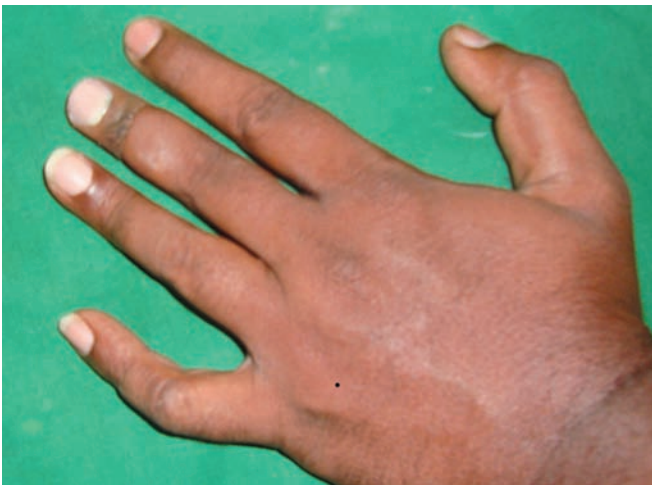

Fig. 5: Final prosthesis with external pigmentation

osseointegrated implant. However, the major limitation of the present design is its limitation for amputations that involve single phalange (i.e. distal phalange).

CONCLUSION AND CLINICAL SIGNIFICANCE

Esthetics and function are the basic requisites of any digital prosthesis and modification presented in the present paper improves the functional component of the prosthesis significantly. Whenever feasible, minor alterations in the design should be attempted to minimize the psychological trauma of the patient.

REFERENCES

1. Shanmuganathan N, Uma Maheswari M, Anandkumar V, Padmanabhan TV, Swarup S, Jibrán AH. Aesthetic finger prosthesis. *J Ind Prosthodont Soc* 2011;11(4):232-237.
2. Heitmann C, Levin S. Alternatives to thumb replantation. *Plast Reconstr Surg* 2002;110(6):1492-1503.

3. Dogra S, Lall S, Shah F, Aeran H. Fabrication of a glove type finger prosthesis using silicone elastomers. *J Ind Prosthodont Soc* 2008;8(3):165-168.
4. Buckner H, Michael JW. Options for finger prosthesis. *J Prosthet Orthot* 1994;6(1):11-19.
5. Jacob PC, Shetty KHM, Garg A, Pal B. Silicone finger prosthesis: a clinical report. *J Prosthodont* 2012;21(8):631-633.
6. Doppen P, Solomons M, Kritzing S. Osseointegrated finger prostheses. *J Hand Surg Eur* 2009;34(1):29-34.
7. Aydin C, Karakoca S, Yilmaz H. Implant-retained digital prostheses with custom-designed attachments: a clinical report. *J Prosthet Dent* 2007;97(4):191-195.
8. Manurangsee P, Isariyawut C, Chatuthong V, Mekraksawanit S. Osseointegrated finger prosthesis: an alternative method for finger reconstruction. *J Hand Surg* 2000;25(1):86-92.
9. Aydin C, Karakoca S, Yilmaz H, Yilmaz C, Yamalik K. The use of dental implants to retain thumb prostheses: a short-term evaluation of 2 cases. *Int J Prosthodont* 2008;21(2):138-140.
10. Lundborg G, Branemark PI, Rosen B, Malmö, Göteborg. Osseointegrated thumb prostheses: a concept for fixation of digit prosthetic devices. *J Hand Surg* 1996;21(2):216-221.
11. Lundborg G, Waites A, Björkman A, et al. Functional magnetic resonance imaging shows cortical activation on sensory stimulation of an osseointegrated prosthetic thumb. *Scand J Plast Reconstr Surg Hand Surg* 2006;40(4):234-239.
12. Cervelli V, Bottini DJ, Arpino A, Grimaldi M, Rogliani M, Gentile P. Bone-anchored implant in cosmetic finger reconstruction. *Annales de chirurgie plastique esthetique* 2008; 53(4):365-367.
13. Branemark R, Branemark PI, Rydevik B, Myers RR. Osseointegration in skeletal reconstruction and rehabilitation: A review. *J Rehabil Res Dev* 2001;38(2):175-181.
14. Goiato MC, Idelmo Rangel Garcia-Junior IR, Magro-Filho O, Magro-Filho O, dos Santos DM, Pellizzer EP. Implant-retained thumb prosthesis with anti-rotational attachment for a geriatric patient. *Gerodontology* 2010;27(3):243-247.
15. Pilley MJ, Quinton DN. Digital prostheses for single finger amputations. *J Hand Surg Eur* 1999;24(5):539-541.