


## CASE REPORT



## Nonsurgical Management of Phenytoin-induced Gingival Hyperplasia

Yousef A AlJehani

### ABSTRACT

**Introduction:** The aim of this report is to present a severe case of phenytoin (PHT)-induced gingival hyperplasia in a Saudi patient.

**Materials and methods:** A 12-year-old male epileptic patient, undergoing PHT therapy, was diagnosed clinically with severe gingival hyperplasia. His treatment consisted meticulous oral care and weekly professional prophylaxis. The patient was advised oral folic acid supplementation (0.5 mg/day) and was also recommended 0.2% chlorhexidine gluconate mouthwash twice daily.

**Results:** There was significant reduction in the hyperplastic tissue within 4 weeks of treatment.

**Conclusion:** It is possible to treat PHT-induced gingival hyperplasia non-surgically with intensive dental care, correct oral hygiene and oral folic acid supplements.

**Keywords:** Gingival hyperplasia, Oral hygiene, Oral prophylaxis, Phenytoin.

**How to cite this article:** AlJehani YA. Nonsurgical Management of Phenytoin-induced Gingival Hyperplasia. *J Contemp Dent Pract* 2015;16(4):319-321.

**Source of support:** Nil

**Conflict of interest:** None

### INTRODUCTION

Epilepsy is a neurological disorder characterized by sudden, recurrent and transient disturbances of mental function or movements of the body that result from excessive discharging of group of brain cells. The disease

is characterized by a group of symptom complexes, of which some are static and some are progressive. The most common manifestations are partial or complete loss of consciousness, localized or generalized muscular spasms or jerks or apparently purposeful behavior performed while awareness is depressed. Among the many social and systemic challenges patients with epilepsy face is the deterioration of their oral health.<sup>1</sup> In patients taking phenytoin (PHT), gingival fibroblasts proliferate, causing tissue overgrowth and gingival hyperplasia.<sup>2</sup>

The drugs which have been reported to produce gingival hyperplasia can be categorized as follows: anti-epileptics, calcium channel blockers and immune-suppressants. Though many medications and combinations of medications are available for the controlling epilepsy, but PHT continues to be a very effective treatment for most of the patients.<sup>3</sup> Phenytoin is one of the most widely used antiepileptic drug in the treatment of epilepsy. It has got several side effects like skeletal, endocrine, immunological and connective tissue disturbances. Of these, gingival overgrowth is characterized by an increased amount of non-collagenous extracellular matrix, associated with gingival inflammation. The most common side effect of this drug is the development of moderate to severe gingival hyperplasia in tooth-bearing areas, which can contribute to problems of function, oral hygiene, appearance, and, eventually, loss of teeth.<sup>4-6</sup>

Poppell et al<sup>7</sup> studied the effect of folic acid on PHT induced gingival overgrowth following gingivectomy. He concluded that the treatment group had significantly higher red blood cell folic acid levels. Brown et al studied the effect of administration of folic acid to institutionalized epileptic adults with PHT induced gingival hyperplasia. But, he found that there was no significant difference between the treatment groups and concluded that a single daily dose of 3 mg capsule of folic acid did

Department of Dental Health, College of Applied Medical Sciences, King Saud University, Riyadh, Saudi Arabia

**Corresponding Author:** Yousef A AlJehani, Assistant Professor, Department of Dental Health, College of Applied Medical Sciences, King Saud University, Riyadh, Saudi Arabia  
Phone: +966500655550, e-mail: aljehaniyousef@gmail.com

not show efficacy as the sole therapeutic agent in the reduction of PHT-induced gingival hyperplasia.<sup>8</sup>

## CASE REPORT

A 12-year-old Saudi male reported to the out patient ward of the Dental Service Department of National Guard Health Affairs, Saudi Arabia, with a chief complaint of swelling of gums and unesthetic appearance of mouth. The patient had a positive history for epilepsy and was under antiepileptic therapy for the past 5 years. On initial clinical examination, it was observed that the patient had drug-induced gingival hyperplasia due to antiepileptic medication but had no other side effects. Patient had poor oral hygiene and reported frequent bleeding while brushing. Gingival hyperplasia was more prominent labially, and buccally than lingually. Also the mandibular gingiva were more hyperplastic than the maxilla (Fig. 1). The patient was briefed on the clinical situation and treatment options. Patient consent was obtained to proceed with the treatment approach.

## TREATMENT

Due to the poor oral hygiene status of the patient, he was advised meticulous oral care and weekly professional prophylaxis. The patient was advised oral folic acid supplementation (0.5 mg/day) and was also recommended 0.2% chlorhexidine gluconate mouthwash twice daily. Oral hygiene instructions and dietary advice were provided to the patient. Professional prophylaxis was repeated the following week. The gingival hyperplasia had reduced significantly in the following week. This was especially evident in the labial gingiva of the mandible. Treatment was completed over a period of 4 weeks and a good esthetic result was achieved. As the gingival hyperplasia had regressed significantly, further gingival surgery was not considered.

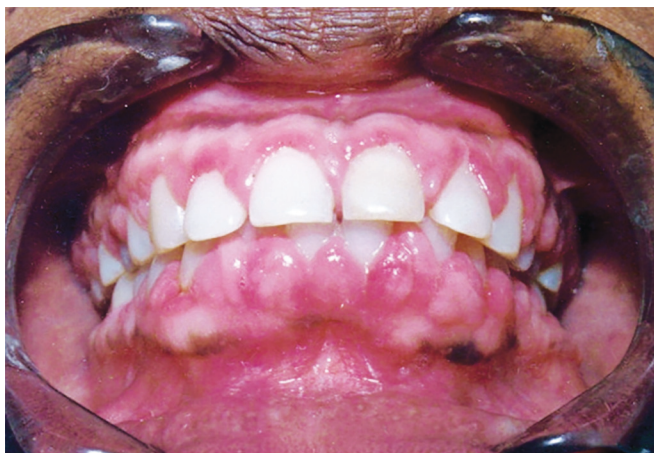

Fig. 1: Initial presentation

## DISCUSSION AND CONCLUSION

After numerous studies of the incidence of gingival hyperplasia in different populations treated with PHT,<sup>9-11</sup> it is widely accepted that patients treated with PHT may experience gingival hyperplasia. One of the earliest reports of gingival hyperplasia to be a side effect of antiepileptic therapy with PHT was described by Kimball in 1939.<sup>12</sup> A number of investigators have examined the direct effect of PHT and its metabolites on gingival connective tissue but the mechanism by which the drug brings about gingival hyperplasia remains obscure.

Many theories have been suggested to explain the pathogenesis of PHT induced gingival overgrowth. In the gingival connective tissue different subpopulations of fibroblasts, some of which are capable of high protein and collagen synthesis (high activity fibroblasts), and others capable of low protein synthesis (low activity fibroblasts). The proportions of high to low activity fibroblasts are genetically determined. High activity fibroblasts in presence of certain predisposing factors become sensitive to PHT and there is a subsequent increase in collagen production. Another theory is based on the correlation of gingival hyperplasia to salivary and gingival tissue level of phenytoin. Phenytoin can accumulate selectively in dental plaque resulting in high concentration of the drug near the disrupted epithelium. An immunologic basis for PHT induced gingival overgrowth has been proposed, since a significantly lower concentration of salivary IgA has been found in patients taking PHT. It has been suggested that PHT induces degranulation of mast cells and liberation of substances that capable of increased cell reproduction and collagen formation. The occurrence of PHT induced gingival overgrowth can be related to the effect of PHT on the metabolism of steroid hormones, increases in their level may be correlated to these hyperplastic changes.

In this case, the patient was advised oral folic acid supplements. Folic acid deficiency is known to occur along with PHT induced gingival hyperplasia.<sup>7</sup> Deficiencies of folic acid precipitated by PHT therapy have been reported to be avoidable with the administration of oral folic acid.<sup>13</sup> Also, it has been reported that the plasma levels of PHT decreased significantly when folic acid was administered.<sup>14</sup> The proposed mechanisms of PHT induced folic acid depletion include inhibition of the enzyme folate conjugase, PHT induced impairment of folic acid transport into the tissues, malabsorption of the vitamin from the intestinal lumen due to the alkaline pH produced by the drug, depletion of folic acid via enhanced metabolic process resulting from PHT-induced liver enzyme activity or by displacement of the vitamin from

its carrier protein. These interactions may result from the similarity in chemical configuration of the both PHT and folic acid.

The treatment mainly consisted of thorough professional prophylaxis followed by reinforcing to the patient the importance of regular brushing and mouth rinse. Although no significant relationship has been established between the gingival hyperplasia and the amount of local irritants, some investigators suggested that good oral hygiene is important in controlling the drug induced gingival proliferation.<sup>15-17</sup> The nature of the relationship between plaque and the expression of gingival hyperplasia is unclear, and, controversy exists as to whether plaque accumulation is the cause of the gingival changes or the consequence of it.<sup>18</sup> The primary aim of non surgical approaches is to reduce the inflammatory component in the gingival tissues and, thereby avoid the need for surgery.<sup>19</sup> By intensive dental care, correct mouth hygiene and by change of treatment of carbamazepine it is possible to prevent gingival hyperplasia from PHT treatment.<sup>20</sup> The known effectiveness of 0.2% chlorhexidine gluconate mouthwash in preventing plaque formation, prompted us to advise regular use for the current patient.<sup>21</sup>

The observations of the present study suggest the possibility of effectively treating PHT induced gingival hyperplasia using a nonsurgical approach. However, it should be emphasized here that this was a case report and, therefore, the findings should be interpreted with caution. It is recommended that further studies should be undertaken to provide more valuable data on this topic.

## ACKNOWLEDGMENT

The author would like to express his appreciation to the Research Center, College of Applied Medical Sciences and Deanship of Scientific Research at King Saud University, Riyadh, Saudi Arabia, for funding this study.

## REFERENCES

1. Aragon CE, Burneo JG. Understanding the patient with epilepsy and seizures in the dental practice. *J Can Dent Assoc* 2007;73(1):71-76.
2. Seymour R, Thomason J, Ellis J. The pathogenesis of drug-induced gingival overgrowth. *J Clin Periodont* 1996;23(3):165-175.
3. Mitchell WG. Status epilepticus and acute repetitive seizures in children, adolescents, and young adults: etiology, outcome, and treatment. *Epilepsia* 1996;37(s1):S74-S80.
4. Dongari A, McDonnell HT, Langlais RP. Drug-induced gingival overgrowth. *Oral Surg Oral Med Oral Pathol* 1993;76(4):543-548.
5. Prasad V, Chawla HS, Goyal A, Gauba K, Singhi P. Folic acid and phenytoin induced gingival overgrowth—is there a preventive effect. *J Ind Soc Pedod Prev Dent* 2004;22(2):82-91.
6. Marshall RI, Bartold PM. A clinical review of drug-induced gingival overgrowths. *Aust Dent J* 1999;44(4):219-232.
7. Poppell TD, Keeling SD, Collins JF, Hassell TM. Effect of folic acid on recurrence of phenytoin-induced gingival overgrowth following gingivectomy. *J Clin Periodont* 1991;18(2):134-139.
8. Brown RS, Stanislaw PT, Beaver WT. Administration of folic acid to institutionalized epileptic adults with phenytoin induced gingival hyperplasia: a double blind, randomised, placebo controlled parallel study. *Oral Surg Oral Med Oral Pathol* 1991;71:565.
9. Thomason JM, Seymour RA, Rawlins MD. Incidence and severity of phenytoin-induced gingival overgrowth in epileptic patients in general medical practice. *Community Dent Oral Epidemiol* 1992;20(5):288-291.
10. Perlik F, Kolinova M, Zvarova J, Patzelova V. Phenytoin as a risk factor in gingival hyperplasia. *Ther Drug Monit* 1995;17(5):445-448.
11. Sasaki T, Maita E. Increased bFGF level in the serum of patients with phenytoin-induced gingival overgrowth. *J Clin Periodontol* 1998;25(1):42-47.
12. Kimball OP. The treatment of epilepsy with sodium diphenyl hydantoinate. *J Am Med Assoc* 1939;112:1244-1939.
13. Arya R, Gulati S, Kabra M, Sahu JK, Kalra V. Folic acid supplementation prevents phenytoin-induced gingival overgrowth in children. *Neurology* 2011;76(15):1338-1343.
14. Harden C, Pennell P, Koppel B, Hovinga C, Gidal B, Meador K, Hopp J, Ting T, Hauser W, Thurman D. Practice parameter update: management issues for women with epilepsy—focus on pregnancy (an evidence-based review): Vitamin K, folic acid, blood levels, and breastfeeding Report of the Quality Standards Subcommittee and Therapeutics and Technology Assessment Subcommittee of the American Academy of Neurology and American Epilepsy Society. *Neurology* 2009;73(2):142-149.
15. Takada K, Sugiyama H, Umezawa K, Mega J, Hirasawa M. The subgingival microflora in phenytoin-induced gingival hyperplasia. *J Periodontal Res* 2003;38(5):477-481.
16. Hood KA. Drug-induced gingival hyperplasia in transplant recipients. *Progress in Transplantation* 2002;12(1):17-23.
17. Clocheret K, Dekeyser C, Carels C, Willems G. Idiopathic gingival hyperplasia and orthodontic treatment: a case report. *J Orthod* 2003;30(1):13-19.
18. Mavrogiannis M, Ellis J, Thomason J, Seymour R: The management of drug-induced gingival overgrowth. *J Clin Periodont* 2006;33(6):434-439.
19. Somacarrera ML, Lucas M, Scully C, Barrios C. Effectiveness of periodontal treatments on cyclosporine-induced gingival overgrowth in transplant patients. *Br Dent J* 1997;183(3):89-94.
20. Tigarán S. A 15-year follow-up of phenytoin-induced unilateral gingival hyperplasia: a case report. *Acta Neurol Scand* 1994;90(5):367-370.
21. McBain AJ, Bartolo RG, Catrenich CE, Charbonneau D, Ledder RG, Gilbert P. Effects of a chlorhexidine gluconate-containing mouthwash on the vitality and antimicrobial susceptibility of in vitro oral bacterial ecosystems. *Appl Environ Microbiol* 2003;69(8):4770-4776.