

## ***In vitro* Comparative Evaluation of Various Restorative Materials used for restoring Class III Cavities in Deciduous Anterior Teeth: A Clinical Study**

<sup>1</sup>Harsh Priyank, <sup>2</sup>Ankita Verma, <sup>3</sup>Komal Gupta, <sup>4</sup>Esha Chaudhary, <sup>5</sup>Deepak khandelwal, <sup>6</sup>Shweta Nihalani

### **ABSTRACT**

**Introduction:** Beauty standards in today's modernized world scenario are formed by well-aligned and well-designed bright white teeth. One of the major reasons behind patients reporting to dental clinics is pain. Caries in the anterior primary teeth forms one of the major concerns from a restorative point of view. Very few studies are quoted in literature which stresses on the follow-up of anterior restorations in primary teeth. Hence, we evaluated and compared the efficacy of composite resin and resin-modified glass ionomer cement (RGIC) for class III restorations in primary anterior teeth.

**Materials and methods:** The present study was conducted in the pediatric dental wing and included a total of 80 patients aged 3 to 5½ years who reported with the chief complaint of carious lesions in the primary anterior teeth. Patients having minimal of a pair of similar appearing small carious lesions on the same proximal surfaces of the deciduous maxillary incisors were included for the study. All the patients were randomly divided into two groups: One in which RGIC restoration was done and other in which composite restoration was done. Cavity preparation was done and

filling of the cavity with the restorative materials was carried out. Assessment of the restorations was done at 4, 8, and 12 months time following criteria given by Ryge et al. All the results were analyzed by Statistical Package for the Social Sciences (SPSS) software. Mann-Whitney test and one-way analysis of variance (ANOVA) were used to evaluate the level of significance; p value less than 0.05 was considered as significant.

**Results:** For composite and RGIC restorations, the mean score for anatomic shape was 1.21 and 1.10 respectively. While comparing the clinical parameters, nonsignificant results were obtained between composite and RGIC restorative materials at 4-, 8-, and 12-month interval. On comparing the clinical parameters for individual restorative materials at different time intervals, statistically significant results were obtained only for anatomical shape and form.

**Conclusion:** Both RGIC and composite resin restorative materials showed acceptable clinical outcomes after 12 months of follow-up in deciduous anterior teeth. In restoring class III restorations in primary anterior teeth, both the restorative materials showed similar outcome.

**Clinical significance:**

**Keywords:** Composite, Marginal, Resin-modified glass ionomer cement.

**How to cite this article:** Priyank H, Verma A, Gupta K, Chaudhary E, Khandelwal D, Nihalani S. *In vitro* Comparative Evaluation of Various Restorative Materials used for restoring Class III Cavities in Deciduous Anterior Teeth: A Clinical Study. J Contemp Dent Pract 2016;17(12):1022-1026.

**Source of support:** Nil

**Conflict of interest:** None

<sup>1</sup>Department of Conservative Dentistry and Endodontics Hazaribagh college of Dental Sciences and Hospital, Hazaribagh Jharkhand, India

<sup>2</sup>Department of Pedodontics and Preventive Dentistry, Hazaribagh College of Dental Sciences and Hospital, Hazaribagh, Jharkhand India

<sup>3</sup>Department of Pedodontics and Preventive Dentistry, M.A. Rangoonwala College of Dental Sciences and Research Centre Pune, Maharashtra, India

<sup>4</sup>Department of Conservative Dentistry and Endodontics Institute of Dental Studies and Technologies, Modinagar, Ghaziabad, India

<sup>5</sup>Department of Pedodontics and Preventive Dentistry, University college of medical sciences, GTB Hospital, New Delhi, India

<sup>6</sup>Department of Pedodontics and Preventive Dentistry, Shree Bankey Bihari Dental College and Research Centre, Ghaziabad Uttar Pradesh, India

**Corresponding Author:** Harsh Priyank, Department of Conservative Dentistry and Endodontics, Hazaribagh College of Dental Sciences and Hospital, Hazaribagh, Jharkhand, India Phone: +919501544877, e-mail: harshpriyank123@gmail.com

### **INTRODUCTION**

Well-aligned and well-designed bright white teeth form the beauty standards in today's modernized world scenario.<sup>1</sup> Apart from well-formed esthetics, the other major reason behind patients reporting to dental clinics is pain.<sup>2</sup> Pediatric patients routinely report to dental clinics with the chief complaint of caries, malformations, fractures of teeth, change in physiologic coloration of teeth, etc.<sup>1</sup> Nursing bottle caries forms the majority of the cases

of mutilated deciduous anterior teeth among pediatric patients.<sup>3</sup> One of the major infectious diseases among children which is difficult to control and forms a major health issue among general public population is early childhood caries.<sup>4,5</sup> Literature quotes very few studies highlighting the long-term follow-up data of restorative treatments of primary anterior teeth.<sup>6</sup> Hence, we evaluated and compared the efficacy of composite resin and resin-modified glass ionomer cement (RGIC) for class III restorations in primary anterior teeth.

**MATERIALS AND METHODS**

The present study was carried out in the pediatric wing of the dental institution and included all the patients of age 3 to 5½ years reporting with the chief complaint of caries in the anterior teeth. A total of 80 patients were selected after following the inclusion and exclusion criteria as given below.

**Inclusion Criteria**

- Age group : 3 to 5½ years
- Patients having minimal of a pair of similar appearing small carious lesions on the same proximal surfaces of the deciduous maxillary incisors.

**Exclusion Criteria**

- Presence of deep carious lesions requiring indirect or direct pulp therapy
- Presence of any sign of abscess of sinus tract formation
- Teeth requiring crown fabrication for restoration
- Patient with presence of malocclusion involving anterior teeth
- Patients with presence of deleterious oral habits
- Patients with highly uncooperative behavior
- Patients with any systemic illness or any sign of mental retardation.

All the patients were randomly divided into two study groups as shown in Table 1. All the patients’ guardians/parents were preinformed about the study protocol and written consent was obtained. Ethical approval was obtained from the institution after explaining, in written, about the study procedure and principles. Entertainment and musical objects were used to divert children’s attention while performing dental cars. Shade guide was used to select suitable color shade of the composite. Isolation of the teeth was done using rubber dam followed by placement of wooden wedges to protect the gingival tissues. Labial route was chosen to make access

**Table 1:** Distribution of patients in different groups

Groups	No. of patients	Restorative material
I	40	Solare for class III cavities
II	40	GC Fuji filling for class III cavities

to the lesion and after debridement of the carious part; an outline form was made followed by dovetail pattern formation. Cavity was extended in the gingivoincisor direction followed by roughening of peripheral enamel.

Steps taken for restoring anterior teeth by composite resins:

- Polishing of teeth with pumice
- Placement of matrix band on the proximal surface of anterior
- Rubbing of self-etching primer solution with an applicator tip for 18 to 20 seconds
- Application of bonding agent followed by curing with light beam for 18 to 20 seconds
- Incremental placement of composite followed by curing for 38 to 40 seconds
- Finishing and polishing

Steps taken for restoring anterior teeth by RGIC:

- Polishing of teeth with pumice
- Placement of matrix band on the proximal surface of anterior
- Conditioning of the prepared cavity for 10 seconds
- Placement of curing of RGIC in the cavity
- Finishing and polishing.

Follow-up and evaluation of the restorations were done at 4, 8, and 12 months time following criteria given by Ryge et al<sup>6</sup> as shown in Table 2. All the results were analyzed by Statistical Package for the Social Sciences (SPSS) software. Mann–Whitney test and one-way analysis of variance were used to evaluate the level of significance; p value less than 0.05 was considered as significant.

**RESULTS**

Table 3 highlights the p value of comparative evaluation of clinical parameters between RGIC and composite

**Table 2:** Evaluation of clinical parameters by Ryge’s criteria

Clinical parameters	Rating	Ryge’ criteria
Adaptations of the margins	A	No visible evidence of lesion
	B	Small catch without exposure of dentin
	C	Exposure of dentin
	D	Mobility of restoration or missing in part
Anatomic form	A	Continuity of restoration’s contour with physiologic anatomic shape
	B	Under contour restoration along with discontinuity of restorative material lining from the physiologic anatomic shape
	C	Exposure of dentin by loss of material
Secondary caries	A	No evidence of the caries
	B	Evidence of caries along the margins of the restorations
Marginal discoloration	A	Absence of discoloration along the margins of the material in direction towards the pulp tissue
	B	Presence of discoloration along the margins of the material in direction towards the pulp tissue

**Table 3:** p-value on comparing clinical parameters between RGIC and composite after 4 months interval

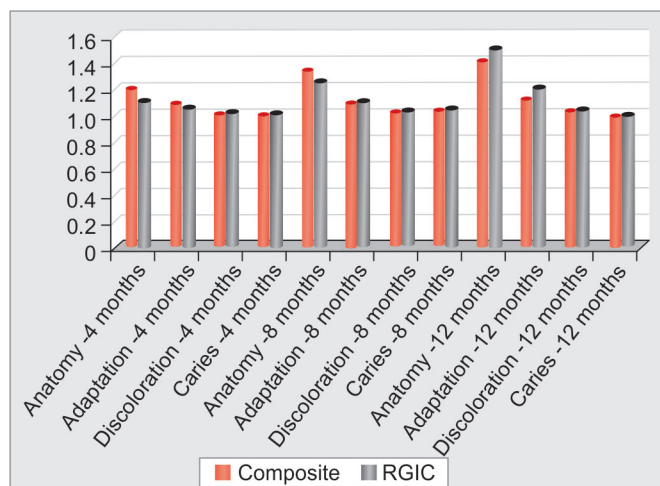
Mean score	Composite	RGIC	p-value
Form of the anatomical shape	1.21	1.10	0.212 NS
Adaptation of the margins	1.10	1.05	0.0135 NS
Discoloration of the margins	1	1	1.00 NS
Secondary caries	1	1	1.00 NS

NS: Nonsignificant

**Table 5:** p-value on comparing clinical parameters between RGIC and composite after 12 months interval

Mean score	Composite	RGIC	p-value
Form of the anatomical shape	1.45	1.42	0.311 NS
Adaptation of the margins	1.15	1.12	0.114 NS
Discoloration of the margins	1	1	1.00 NS
Secondary caries	1	1	1.00 NS

NS: Nonsignificant



**Graph 1:** Comparison of clinical parameters between composite and RGIC at 4, 8, and 12 months' time

after 4 months interval. Mean score for anatomic shape for composite and RGIC was 1.21 and 1.10 respectively (Graph 1). No statistically significant results were obtained while comparing forms of anatomic shape, marginal adaptation, discoloration of margins, and secondary caries parameter between composite and RGIC restorations ( $p < 0.05$ ). On comparing the clinical parameters after 8 months follow-up between RGIC and composite restorations, no statistically significant result was seen ( $p < 0.05$ ) (Table 4). Mean score for marginal adaptations for composite and RGIC was found to be the same (1.10). Table 5 shows the p value for mean score of clinical parameters on comparing between composite and RGIC restorative materials. Mean score for anatomic shape of composite restoration and RGIC was found to be 1.45 and 1.42 respectively. No significant alteration was seen on comparing the clinical parameters between composite and RGIC at 1 year follow-up. Significant difference was obtained for anatomical shape and form of composite

**Table 4:** p-value on comparing clinical parameters between RGIC and composite after 8 months interval

Mean score	Composite	RGIC	p-value
Form of the anatomical shape	1.50	1.40	0.222 NS
Adaptation of the margins	1.20	1.10	0.315 NS
Discoloration of the margins	1	1	1.00 NS
Secondary caries	1	1	1.00 NS

NS: Nonsignificant

and RGIC restorations when compared individually at 4, 8 months, and 1 year follow-up.

## DISCUSSION

Marginal caries of the restorations have been cited by numerous researchers as the primary cause for the replacement of GIC.<sup>7-10</sup> However, contrasting results have also been reported by various authors in the past. Mount reported absence of marginal caries associated with GIC up to 5 years follow-up.<sup>11</sup> Recent data show an increase in surface area of the enamel by preparation of full labial surface along with veneering of the surface for additional bonding, thus improving the retention of class III fillings in deciduous teeth.<sup>12</sup> It has also been shown that the shear bond strength of the composite to enamel is increased by air abrasion by production of irregular rough surface, which further increases the total surface area for bonding. Also, wettability of the tooth structure has also been found to be increased by the abrasion effect of air-borne particles, which further increases the effect of dentin adhesive systems.<sup>13,14</sup> Hence, we compared the clinical efficacy of composite and RGIC for class III restorations by evaluating Ryge's various parameters in deciduous anterior teeth.

### Anatomical Form and Shape

At 4 months follow-up, the mean score for anatomical form for composite and RGIC restoration was found to be 1.21 and 1.10 respectively ( $p < 0.05$ ) (Table 3, Graph 1). Similar results were reported by de Araujo et al<sup>15</sup> and Usha et al<sup>3</sup> who also reported a high success rate of RGIC and composite restorative materials at 12 weeks follow-up. A higher success rate of RGIC was seen at 8 months follow-up as compared with composite restorations (Table 4). However, the results were nonsignificant ( $p < 0.05$ ). Brackett et al<sup>16</sup> also reported similar findings in their study with high success rate of RGIC. Although nonsignificant, a higher percentage of success rates was observed for composite restoration in comparison with RGIC after 12 months follow-up ( $p < 0.05$ ), as shown in Table 5. While comparing at different time intervals, significant alterations were observed for composite and RGIC individually ( $p > 0.05$ ).

### Marginal Adaptation

After 4, 8, and 12 months follow-up, nonsignificant alterations were observed on comparing the clinical parameters between composite restorations and RGIC restorations ( $p < 0.05$ ). Our results were in correlation with the results of Brackett et al<sup>16</sup> and Usha et al<sup>3</sup> who also observed a high success rate of RGIC and composite restorations. However, nonsignificant alterations were seen on individual comparison of composite and RGIC at different time intervals during follow-up.

### Marginal Discoloration

Nonsignificant results were observed after 4, 8, and 12 months follow-up on comparing RGIC and composite for marginal discoloration. Both of the restorative materials showed 100% success rate, which was in correlation with the results obtained by de Araujo et al<sup>15</sup> and Usha et al<sup>3</sup>; however, no significant alterations were seen in individual restorative materials at various time intervals during follow-up ( $p < 0.05$ ).

### Secondary Caries

In case of assessment of secondary caries, no significant alteration was seen at 4, 8, and 12 months interval while comparing between RGIC and composite restorative materials. Ozgünaltay et al<sup>17</sup> and Hse and Wei<sup>18</sup> reported similar findings in their respective studies in which they reported 100% success rate for the above-mentioned clinical parameter at different time intervals.

Duhan et al<sup>19</sup> compared the clinical performance of composite biological restoration with stainless steel band for coronal building of mutilated deciduous anterior teeth. They randomly selected 20 patients of age group 3 to 6 years who presented with the chief complaint of mutilated deciduous anterior teeth due to caries. From the results, they concluded that most satisfying esthetic results for anterior teeth rehabilitation was found in case of biological restorations. Deliperi and Bardwell<sup>20</sup> evaluated the effectiveness of whitening of teeth with nonvital pulp along with clinical performance of direct composite restorations, which were used for reconstructing endodontically bleached teeth. They analyzed 21 patients and from the results concluded that after completion of whitening therapy on teeth with devitalized pulp, significant amount of tooth bleaching was observed. Also, excellent clinical outcome was demonstrated by microhybrid resin composite. Franco et al<sup>21</sup> comparatively analyzed the 5-year clinical outcome of a 1-bottle adhesive and resin composite system with RGIC in the restoration of noncarious cervical lesions. They placed 70 restorations in 30 patients and after observing the results of 5 years of evaluation, concluded that the RGIC restorations had

significantly higher clinical performance in comparison to resin composite restoration. Zanata et al<sup>22</sup> evaluated the clinical performance of glass ionomer cement in controlling dental caries. From the results, they concluded that for a population at high risk, high-quality preventive and restorative care is delivered by highly viscous glass ionomer cement when applied through a minimal intervention approach. Also, in anterior tooth region, behavior of composite is comparable with glass ionomer cement. Harris et al<sup>23</sup> presented the clinical report for the treatment of class III cervical resorption in maxillary central incisor by combining endodontic therapy with periodontal surgery, for final repairing of the defect, they used RGIC along with zirconia crown. No complications were observed in the patient after 30 months follow-up. Heintze et al<sup>24</sup> through a meta-analysis evaluated the efficacy of composite resin restorations in restoring class III cavities in anterior teeth. They searched the database SCOPUS and PubMed for clinical trials and from the results, concluded that significant reduction in the deterioration of the anatomical form was associated with beveling of the enamel as compared with no beveling.

### CONCLUSION

From the above results, it can be concluded that acceptable clinical outcomes have been shown by RGIC and composite resin restorative material after 12 months of follow-up in deciduous teeth. Also both the restorative materials do well in class III restoration in primary anterior teeth. Further studies involving esthetic restorative materials are required in the future to improve the clinical performances of these materials.

### REFERENCES

1. Sahana S, Vasa AA, Shekhar KR. Esthetic crown for primary teeth: a review. *Ann Essences Dent* 2010 Apr;2(2):87-93.
2. Mathew RA. Esthetics in primary teeth. *Int Res J Pharm* 2013;4:80-82.
3. Usha M, Deepak V, Venkat S, Gargi M. Treatment of severely mutilated incisors: a challenge to the pedodontist. *J Indian Soc Pedod Prev Dent* 2007;25(Suppl):34S-36S.
4. Tiwari E, Kulkarni VK, Sharma DS, Bhusari CP. Esthetic and functional rehabilitation of primary teeth in an emotionally immature child under general anesthesia. *Natl J Dent Speciality Res* 2014;2:35-37.
5. Grewal N, Seth R. Comparative *in vivo* evaluation of restoring severely mutilated primary anterior teeth with biological post and crown preparation and reinforced composite restoration. *J Indian Soc Pedod Prev Dent* 2008 Dec;26(4):141-148.
6. Das UM, Viswanath D, Azher U. Clinical evaluation of resin composite and resin modified glass ionomer in class III restorations of primary maxillary incisors: a comparative *in vivo* study. *Int J Clin Paediatr Pract* 2009 May;2(2):13-19.
7. Mjör IA, Moorhead JE, Dahl JE. Reasons for replacement of restorations in permanent teeth in general dental practice. *Int J Dent* 2000 Dec;50(6):361-366.

8. Van Nieuwenhuysen JP, D'Hoore W, Carvalho J, Qvist V. Long term evaluation of extensive restorations in permanent teeth. *J Dent* 2003 Aug;31(6):395-405.
9. Burke FJ, Cheung SW, Mjör IA, Wilson NH. Reasons for the placement and replacement of restorations in vocational training practices. *Prim Dent Care* 1999 Jan;6(1):17-20.
10. Burke FJ, Cheung SW, Mjör IA, Wilson NH. Restorations longevity and analysis of reasons for the placement and replacement of restorations provided by vocational dental practitioners and their trainers in the United Kingdom. *Quintessence Int* 1999 Apr;30(4):234-242.
11. Mount GJ. Longevity of glass ionomer cements. *J Prosthet Dent* 1986 Jun;55(6):682-685.
12. Waggoner, WF. Restorative dentistry for the primary dentition. In: Casamassimo, PS; Fields, HW; McTigue, DJ; Nowak, AJ, editors. *Pediatric dentistry: infancy through adolescence*. 5th ed. St. Louis: Saunders; 2013. p. 324.
13. Mujdeci A, Gokay O. The effect of airborne-particle abrasion on the shear bond strength of four restorative materials to enamel and dentin. *J Prosthet Dent* 2004 Sep;92(3):245-249.
14. Hatibovic-Kofman S, Butler SA, Sadek H. Microleakage of three sealants following conventional, bur, and air-abrasion preparation of pits and fissures. *Int J Paediatr Dent* 2001 Nov;11(6):409-416.
15. de Araujo MAM, Araujo RM, Marsilio AL. A retrospective look at esthetic resin composite and glass-ionomer Class III restorations: a 2-year clinical evaluation. *Quintessence Int* 1998 Feb;29(2):87-93.
16. Brackett MG, Dib A, Brackett WW, Estrada BE, Reyes AA. One-year clinical performance of a resin-modified glass ionomer and a resin composite restorative material in unprepared class V restorations. *Oper Dent* 2002 Mar-Apr;27(2):112-116.
17. Ozgünaltay G, Onen A. Three-year clinical evaluation of a resin modified glass-ionomer cement and a composite resin in noncarious class V lesions. *J Oral Rehabil* 2002 Nov;29(11):1037-1041.
18. Hse KM, Wei SH. Clinical evaluation of compomer in primary teeth: 1-year results. *J Am Dent Assoc* 1997 Aug;128(8):1088-1096.
19. Duhan H, Pandit IK, Srivastava N, Gugnani N, Gupta M, Kochhar GK. Clinical comparison of various aesthetic restorative options for coronal build-up of primary anterior teeth. *Dent Res J (Isfahan)* 2015 Nov-Dec;12(6):574-580.
20. Deliperi S, Bardwell DN. Two-year clinical evaluation of nonvital tooth whitening and resin composite restorations. *J Esthet Restor Dent* 2005;17(6):369-378.
21. Franco EB, Benetti AR, Ishikiriama SK, Santiago SL, Lauris JR, Jorge MF, Navarro MF. 5-year clinical performance of resin composite versus resin modified glass ionomer restorative system in non-carious cervical lesions. *Oper Dent* 2006 Jul-Aug;31(4):403-408.
22. Zanata RL, Navarro MF, Barbosa SH, Lauris JR, Franco EB. Clinical evaluation of three restorative materials applied in a minimal intervention caries treatment approach. *J Public Health Dent* 2003 Fall;63(4):221-226.
23. Harris BT, Caicedo R, Lin WS, Morton D. Treatment of a maxillary central incisor with class III invasive cervical resorption and compromised ferrule: a clinical report. *J Prosthet Dent* 2014 May;111(5):356-361.
24. Heintze SD, Rousson V, Hickel R. Clinical effectiveness of direct anterior restorations – a meta-analysis. *Dent Mater* 2015 May;31(5):481-495.