



Utilizing the GentleWave[®] System for Debridement of Undetected Apical Anatomy

Michael W Ford

ABSTRACT

Aim and background: Debriding and disinfecting complex anatomies within the root canal system pose a major challenge during root canal therapy. Even with current chemomechanical techniques, debris and bacterial remnants are commonly left behind, which are generally believed to increase the risk of endodontic failure. This case details the use of a new technique to debride complex apical anatomy in a maxillary molar.

Case report: A 48-year-old female presented to the clinic with a chief complaint of increasing pain in her tooth. Clinical examination of the right first maxillary molar (#3) revealed moderate sensitivity to percussion and mild sensitivity to palpation. A pulpal diagnosis of symptomatic irreversible pulpitis and a periapical diagnosis of symptomatic apical periodontitis were made. Mechanical instrumentation was performed using rotary file size #25/.04 for the mesiobuccal and distobuccal canals and size #25/.06 for the palatal canal to create a fluid path and enable obturation of the root canal system following the GentleWave[®] Procedure. The GentleWave Procedure was completed using Multisonic Ultracleaning[™] for complete debridement and disinfection of the root canal system. The tooth was obturated using a warm vertical continuous wave obturation technique. Postoperative radiographs revealed complex anatomy within the apical third that was undetected both during pre-operative radiography and mechanical instrumentation. The palatal canal exhibited a complex apical delta with multiple points of exit, and the mesiobuccal canal revealed an undetected lateral canal within the apical third that had a separate and distinct egress.

Conclusion and clinical significance: It is important for the clinician to debride and disinfect complex anatomy within the root canal system to reduce the risk of endodontic failure. This case report highlights the clinical significance of utilizing the GentleWave Procedure for detecting complex apical anatomy during endodontic therapy.

Keywords: Apical periodontitis, Endodontics, GentleWave procedure, Irreversible pulpitis.

How to cite this article: Ford MW. Utilizing the GentleWave[®] System for Debridement of Undetected Apical Anatomy. *J Contemp Dent Pract* 2018;19(3):345-351.

Source of support: Nil

Conflict of interest: None

AIM AND BACKGROUND

Complex anatomies present within the root canal system are known to contribute to endodontic failure.^{1,2} They provide challenges during detection and navigation which ultimately lead to debris and bacteria unknowingly remaining, even after chemomechanical endodontic therapy methods.³ The presence of untreated complex anatomy after the completion of endodontic therapy is generally believed to increase the risk of endodontic failure.¹⁻³ Due to the difficulty of detecting and endodontically managing complex root canal anatomy, its clinical significance to endodontic therapy success has been a subject of debate, yet clinicians agree it is preferable to debride and disinfect complex anatomy to mitigate the risk of recurrent infection.

Complex anatomy can present as one or more configurations of root curvatures, lateral and accessory canals, ramifications, isthmi, bifurcations, and apical deltas, among others. Lateral canals, for example, occur in 27 to 60% of teeth.⁴⁻⁸ The presentation of lateral canals appears to be increased in teeth with failed root canals as reported by Wada et al,⁹ who reported that 70% of cases with refractory apical periodontitis that did not respond to non-surgical root canal treatment had lateral canals. Lateral canals are most frequently located in posterior teeth as well as in the apical 3 mm of a canal but can be found throughout the root canal systems of all teeth. Lateral canals that connect to the main root canal are

Endodontic Associates of Central Texas, Harker Heights, Texas United States

Corresponding Author: Michael W Ford, Endodontic Associates of Central Texas, Harker Heights, Texas, United States, Phone: +2545543636, e-mail: ford.dds@protonmail.com

created during the formation of dentin in the root when the sheath grows around existing blood vessels.⁴ Dentin does not form where lateral canals are created but instead gives rise to a canal containing small blood vessels and nerves.³ Therefore, these lateral canals comprise pathways through which bacteria, and their byproducts, might reach the periodontal ligament and cause disease.³ Due to the natural anatomical configuration of lateral canals and other complex anatomies, appropriate endodontic therapies to effectively debride, disinfect, and obturate are required to close the pathways of infection to the periodontal ligament, and thus prevent the initiation or exacerbation of apical periodontitis.

Complex anatomy is difficult to predict and detect preoperatively, thus making these naturally occurring morphologies and varying canal configurations a challenge for debridement, disinfection, and obturation.¹⁰⁻¹² This is primarily due to the limitations of standard techniques, such as film and digital radiography, which has demonstrated low diagnostic accuracy for such anatomies. Scarfe et al¹³ demonstrated low sensitivity, specificity, and negative predictive values for both lateral and accessory canals, even when radiopaque material was introduced. Sousa et al¹⁴ sought to locate lateral canals with cone-beam computed tomography but also reported low diagnostic accuracy at detecting lateral canals. Hence, clinicians are often unaware of complex anatomy, which may increase the risk of endodontic failure if left untreated.

The presence of complex anatomy is associated with endodontic failure.^{3,5-8} This is likely because conventional chemomechanical preparation techniques fail to adequately debride and disinfect all complex anatomy. Song et al¹ reported that complex anatomy and missing canals were the cause of 8.7 and 19.7% of failed cases respectively, in 493 root-canal-treated teeth. Hoen and Pink¹⁵ reported even higher failure rates: missed canals were the primary cause of failure in 42% of 1,100 failed root canal treatments. In fact, partial removal of necrotic tissue from the entrance of lateral canals does not reduce inflammation or infection associated with periradicular disease, indicating that apart from simply detecting complex anatomy, better techniques to prevent the onset or exacerbation of apical periodontitis are needed.³ Currently, an endodontic therapy has been reported to meet the demands for a more effective method of debridement and disinfection of the root canal system. This innovative endodontic therapy is the GentleWave Procedure. It is designed to deliver distilled water, sodium hypochlorite (NaOCl), and ethylenediaminetetraacetic acid (EDTA) throughout the root canal system using advanced fluid dynamics, acoustics, and tissue dissolution chemistry. Utilizing multisonic ultracleaning, the GentleWave Procedure debrides and

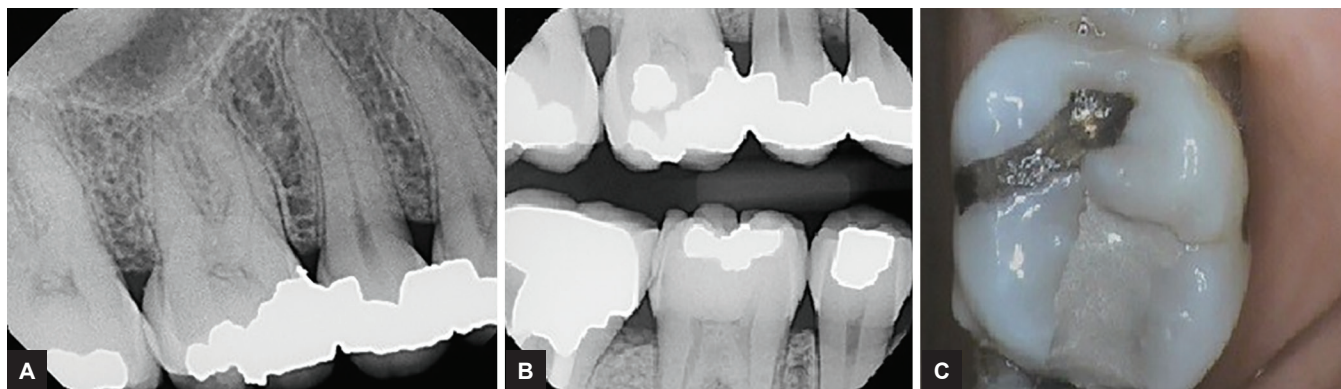
disinfects areas of the root canal system often untouched or undetected by standard techniques. In a study comparing the GentleWave System, standard needle irrigation, the Piezon Master 700 (EMS, Dallas, TX) ultrasonic system, and the EndoVac (SybronEndo, Orange, CA) negative-pressure irrigation system, Haapasalo et al¹⁶ reported the GentleWave Procedure provided seven times faster tissue dissolution in comparison with other systems. In apical pressure testing, when teeth were filed from size 15/.04 to perforating the apical foramen with file size #40, the GentleWave Procedure created negative apical pressure compared with standard needle irrigation which created positive apical pressures.¹⁷ Molina et al¹⁸ revealed debridement capabilities of 97.2% for the GentleWave Procedure and 67.8% for standard root canal therapy in a histology study on mesiolingual and mesio-buccal roots of endodontically treated molar teeth. Long-term healing rates following endodontic therapy with the GentleWave Procedure demonstrate 97.4 and 97.3% respectively, success at 6 and 12 months, respectively.^{19,20}

This case report describes endodontic therapy of a maxillary molar first molar with complex canal anatomy within the apical third of the root canal system that was undetected until post-obturation radiographic review after utilizing the GentleWave Procedure for cleaning and debridement. The postobturation radiograph demonstrates the presence of multiple exits for a palatal apical delta; the mesiobuccal root exhibited a distinct lateral canal, neither of which was visible during the preoperative radiographic examination nor throughout the instrumentation process. These complex apical anatomies were debrided and disinfected only through the GentleWave Procedure. This anatomy only became visible upon postobturation radiography.

CASE REPORT

A 48-year-old female with a history of hypertension was referred for endodontic evaluation of the maxillary right first molar. The patient presented to the clinic with a chief complaint of slowly increasing pain. The patient reported a current pain level of 8 on a 10-point verbal pain scale.

Clinical examination of the right first maxillary molar (#3) revealed moderate sensitivity to percussion and a mild pain response to palpation. The patient reported a recent mesio-occlusal restoration which was noted and confirmed as having been placed 1-month prior. In addition, two older buccal and distolingual restorations were also visualized. No mobility or soft tissue lesions were noted. Vitality testing with a carbon dioxide ice stick elicited an immediate response. Radiographic examination revealed a deep mesio-occlusal restoration; no furcation or root resorption was found to be present on the subject



Figs 1A to C: Preoperative clinical and radiographic appearances of maxillary right first molar. (A) Preoperative periapical radiograph, (B) bitewing radiograph highlighting depth of mesio-occlusal restoration as well as the older buccal and distolingual restorations, (C) preoperative intraoral view of maxillary right first molar

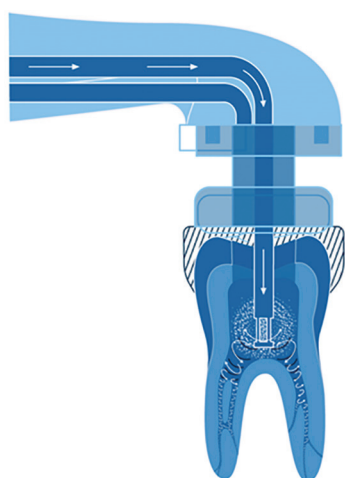


Fig. 2: Schematic of the GentleWave procedure

tooth (Fig. 1). The patient's history of symptoms and the clinical examination indicated a pulpal diagnosis of symptomatic irreversible pulpitis and a periapical diagnosis of symptomatic apical periodontitis. After a review of options with the patient, endodontic therapy was recommended to retain the tooth and the patient consented to care.

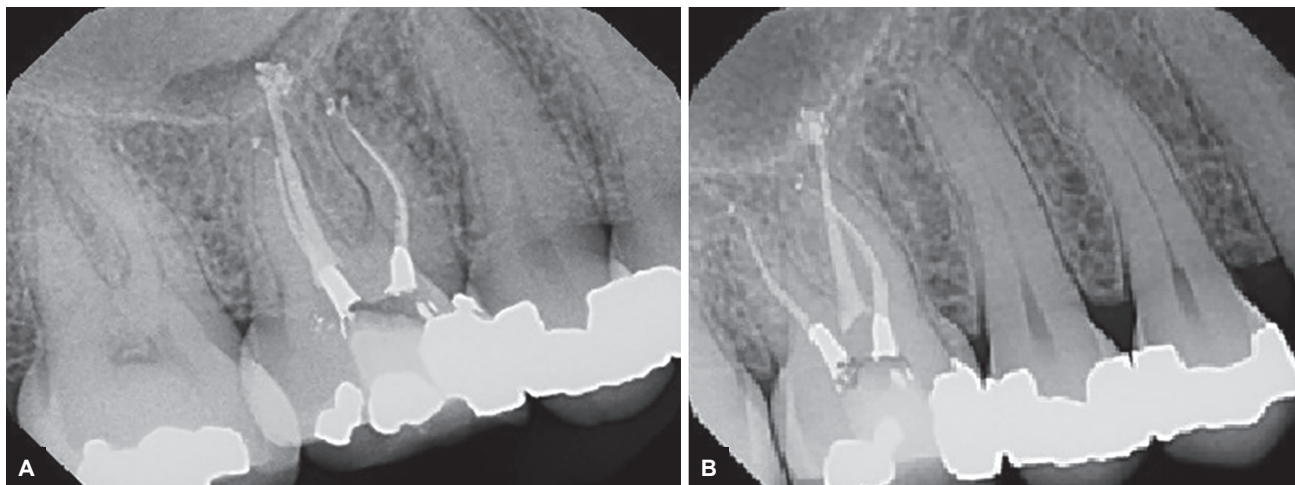
A standard anesthesia protocol was administered using 2% lidocaine (36 mg) with 1:100,000 epinephrine and 0.5% Marcaine (9 mg) with 1:200,000 epinephrine through buccal and palatal infiltration (The Wand®, Single Tooth Anesthesia® System, Milestone Scientific, Inc., USA). Therapy was completed after single tooth isolation with a dental dam and a dental operating microscope (Global™ Surgical Corporation, USA).

A minimally invasive, straight-line endodontic access opening was created. Upon entry to the pulp chamber, initial examination of the floor revealed three distinct canals: palatal, distobuccal, and mesiobuccal. The mesiobuccal-2 canal did not appear to open into the pulp floor. After patency and working length were established, mechanical instrumentation was performed to create a fluid path for the GentleWave System, a debridement and

disinfection technique, and obturation of the root canal system (Fig. 2). Instrumentation was completed to a final file size of EdgeFile® X7 (EdgeEndo™, Albuquerque, NM) size 25/.04 for the mesiobuccal and distobuccal canals and EdgeFile® X3 size 25/.06 for the palatal canal.

Before initiating the GentleWave Procedure, a temporary build-up utilizing Kool-Dam™ (PulpDent®, Watertown, USA) was placed to maintain a sealed environment for the facilitation of optimum Multisonic Ultracleaning™. Distilled water, NaOCl, and EDTA were delivered throughout the root canal system utilizing the GentleWave Procedure. Obturation was completed with gutta-percha and AH Plus® (Dentsply, Tulsa Dental Specialties, Tulsa, OK) sealer using a fitted gutta-percha cone adapted using a continuous-wave warm vertical compaction technique followed by a warm vertical back-fill and final compaction. Final periapical radiographs were taken after the access cavity was sealed.

Upon completion of endodontic therapy with the GentleWave Procedure, postoperative radiographs revealed complex anatomy within the apical third, which was undetected during both pre-operative radiography and mechanical instrumentation (Figs 3 and 4). The palatal canal exhibited a complex apical delta containing multiple points of exit, which were visualized in different radiographic angulations. In addition, the mesiobuccal canal revealed an undetected lateral canal within the apical third that had a separate and distinct egress. These previously undetected complex anatomies occurred within two of the three root canals and presented clinically as significantly obturated root canals. On clinical contact with the patient 1-day postoperatively, the patient reported no concerns and the self-reported pain level decreased from 8 points to a 3 on the 10-point verbal numeric pain scale. Two days posttreatment, the self-reported pain level was zero. A cast restoration was not yet in place, and the patient was reminded to not bite or chew on the tooth until the tooth was fully restored.



Figs 3A and B: Postoperative periapical radiograph of maxillary right first molar highlighting the obturated lateral canals in the apical region

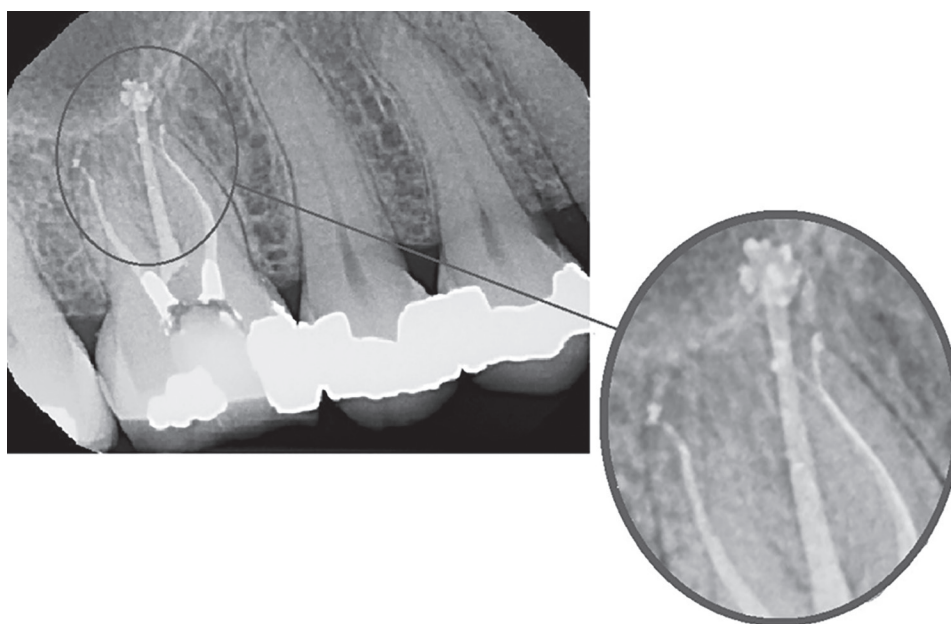


Fig. 4: Postoperative periapical radiography highlighting complex apical anatomy

CONCLUSION

Although the success rates of nonsurgical endodontics have been consistent over the years, failures are attributed to various causes including untreated canals.^{1,2,7,8} Successful healing is largely dependent on the elimination of debris and bacteria to prevent the onset or exacerbation of apical periodontitis. Even when complex anatomy is not present, approximately 35 to 50% of the root canal system can remain untouched after endodontic therapy is completed.^{21,22} When complex anatomies are present, these inaccessible regions require greater reliance on debridement and disinfection techniques relative to the rest of the root canal system.²³ Complex anatomy also creates further procedural difficulties, which can leave debris and bacteria behind inadvertently.³ Research

demonstrates that bacteria remaining after endodontic therapy typically resides in complex anatomical regions, such as the lateral canals and isthmi.^{18,24,25}

New endodontic technologies have emerged in the last few decades, which aimed at addressing current limitations. Although many endodontic therapies have been introduced, including negative-pressure irrigation, ultrasonic irrigation, sonic irrigation, laser, and photo-induced photo-acoustic streaming (PIPS), none have provided sufficient evidence of adequate debridement and disinfection within the root canal system to prevent the onset and exacerbation of apical periodontitis.^{19,26-28} Unfortunately, the safety, efficacy, and reliability of such devices are not well-established.²⁶⁻³⁰ For example, because positive pressure is created at the apex with PIPS and standard needle irrigation systems, irritants

may extrude apically and result in adverse events.²⁹ A negative-pressure irrigation system, the EndoVac System (Danaher, Kerr Endodontics, Orange, CA), was reported to have similar rates of debridement to conventional needle irrigation and was unable to remove all debris from complex anatomy.^{31,32} In terms of the insufficiency of the standard endodontic techniques in debridement and disinfection, long-term success may be unsustainable.^{26,27,29,30,33} Reports demonstrate that long-term healing rates for these endodontic therapies are hindered in part due to the necessary removal of additional natural tooth structure for sufficient penetration of irrigants into the apical third of the root canal system.^{33,34} The need for more progressive innovation to enhance debridement and disinfection has only grown as ongoing endodontic therapy inadequacies continue to present themselves.

A new multisonic approach, the GentleWave Procedure, has been reported to show promising results for thorough debridement and disinfection, and more recently, long-term healing rates after root canal treatment. The GentleWave System utilizes advanced fluid dynamics, acoustics, and tissue dissolution chemistry to more thoroughly debride and disinfect the entire root canal system. Reaching areas of the root canal system often untouched or undetected by standard root canal therapy has been an essential challenge in endodontics to this day. A multicenter, prospective clinical study in 89 molar teeth treated with the GentleWave Procedure demonstrated that patients had no severe or moderate post-treatment pain in the first two postoperative days and had no incidence of pain reported by day 14.²⁰ In this study, 92.1% of patients were treated in a single visit with the GentleWave Procedure. The study showed a 92.9% healing rate for patients whom had a necrotic lesion preoperatively, and the overall healing rate was 97.4% after 12 months.²⁰ A meta-analysis by Ng et al³³ reported the weighted success rate of standard endodontic techniques was 67.7%. Murphy et al³⁵ also reported similar results; retrospective healing rates were 70.6% following standard nonsurgical endodontic therapy.

Irrigation fluids have limited access to the apical 3 mm of the root canal system during endodontic treatment.²⁴ However, Vandrangi³⁶ reported that NaOCl penetration in the apical third was four times more effective with the GentleWave Procedure than active ultrasonic activation. The GentleWave Procedure has also shown minimal dentin erosion.³⁷ Debridement efficacy of the GentleWave System was shown by Ma et al,³⁸ who demonstrated that calcium hydroxide removal in the apical third of mesial and distal molar canals was 98.78 to 100% using the GentleWave System compared

with 47.82 and 77.68% using conventional irrigation. In addition, the GentleWave Procedure demonstrated to remove 99.85 to 99.97% of calcium hydroxide within 90 seconds when using water and no instrumentation.³⁸ In another study, Molina et al¹⁸ demonstrated that the GentleWave Procedure debrided 98.3% of isthmi regions, whereas conventional rotary instrumentation with needle irrigation was only able to debride 64.3% of isthmi regions. When complex anatomies are successfully debrided after endodontic therapy utilizing the GentleWave Procedure, as in this case report, they have the ability to prevent the onset or exacerbation of apical periodontitis.

This present case report features a maxillary molar with undetected complex apical root canal anatomy before utilizing the GentleWave Procedure. The complex anatomies include the palatal canal with an apical delta containing multiple exits and the mesiobuccal canal with a distinct lateral canal. These complex anatomies were not evident on pre-operative radiography, and indeed the literature provides evidence that it is extremely difficult to visualize this intricate anatomy with any of our presently available radiographic technologies. Although these complex anatomies did not become evident during instrumentation, had they been visualized literature shows that it would have been a challenge to navigate, debride, and disinfect them with standard endodontic therapy. Residual debris and bacteria would likely have remained in the complex anatomies following standard endodontic therapy and increased the risk of endodontic failure. Using the GentleWave Procedure, the complex anatomies in the apical region were detected, debrided, and disinfected, thus allowing for their subsequent clinically significant obturation. As a result, the patient experienced relief from pain and a favorable endodontic treatment outcome.

CLINICAL SIGNIFICANCE

This case report highlights the clinical significance of utilizing the GentleWave Procedure for undetected complex apical anatomy during endodontic therapy. It is critical to be aware of the prevalence of complex anatomy within root canal systems and the risks if these anatomies are left undetected and untreated. The GentleWave Procedure presents as a minimally invasive endodontic therapy to more effectively debride and disinfect the entire root canal system. Moreover, it has the technological capabilities to debride and disinfect these integral complex anatomies which are often inaccessible through standard endodontic therapies. Although further research is needed utilizing larger patient populations, the GentleWave System shows promise for successful management and improved

endodontic treatment outcomes for undetected complex apical anatomies.

ACKNOWLEDGMENTS

The author would like to thank Dr Stephanie Cravens for providing medical writing support and Jami Lynn Trobaugh for her thorough contributions.

REFERENCES

- Song M, Kim HC, Lee W, Kim E. Analysis of the cause of failure in nonsurgical endodontic treatment by microscopic inspection during endodontic microsurgery. *J Endod* 2011 Nov;37(11):1516-1519.
- Tabassum S, Khan FR. Failure of endodontic treatment: the usual suspects. *Eur J Dent* 2016 Jan-Mar;10(1):144-147.
- Ricucci D, Siquiera JF. Fate of the tissue in lateral canals and apical ramifications in response to pathologic conditions and treatment procedures. *J Endod* 2010 Jan;36(1):1-15.
- Carrotte P. Endodontics: part 4. Morphology of the root canal system. *Br Dent J* 2004 Oct;197(7):379-383.
- Adorno CG, Yoshioka T, Suda H. Incidence of accessory canals in Japanese anterior maxillary teeth following root canal filling *ex vivo*. *Int Endod J* 2010 May;43(5):370-376.
- De Deus QD. Frequency, location, and direction of the lateral, secondary, and accessory canals. *J Endod* 1975 Nov;1(11):361-366.
- Weine FS. The enigma of the lateral canal. *Dent Clin North Am* 1984 Oct;28(4):833-852.
- Iqbal MK, Gartenberg J, Kratchman SI, Karabucak B, Bui B. The clinical significance and management of apical accessory canals in maxillary central incisors. *J Am Dent Assoc* 2005 Mar;136(3):331-335.
- Wada M, Takase T, Nakanuma K, Arisue K, Nagahama F, Yamazaki M. Clinical study of refractory apical periodontitis treated by apicectomy. Part 1. Root canal morphology of resected apex. *Int Endod J* 1998 Jan;31(1):53-56.
- Christie WH, Peikoff MD, Fogel HM. Maxillary molars with two palatal roots: a retrospective clinical study. *J Endod* 1991 Feb;17(2):80-84.
- von Arx T, Steiner RG, Tay FR. Apical surgery: endoscopic findings at the resection level of 168 consecutively treated roots. *Int Endod J* 2011 Apr;44(4):290-302.
- Vertucci FJ. Root canal morphology and its relationship to endodontic procedures. *Endod Topics* 2005 Mar;10(1):3-29.
- Scarfe WC, Fana CR Jr, Farman AG. Radiographic detection of accessory/lateral canals: use of radio visio graphy and hypaque. *J Endod* 1995 Apr;21(4):185-190.
- Sousa TO, Hassan B, Mirmohammadi H, Shemesh H, Haiter-Neto F. Feasibility of cone-beam computed tomography in detecting lateral canals before and after root canal treatment: an *ex vivo* study. *J Endod* 2017 Jun;43(6):1014-1017.
- Hoehn MM, Pink FE. Contemporary endodontic retreatments: an analysis based on clinical treatment findings. *J Endod* 2002 Dec;28(12):834-836.
- Haapasalo M, Wang Z, Shen Y, Curtis A, Patel P, Khakpour M. Tissue dissolution by a novel multisonic ultracleaning system and sodium hypochlorite. *J Endod* 2014 Aug;40(8):1178-1181.
- Haapasalo M, Shen Y, Wang Z, Park E, Curtis A, Patel P, Vandrangi P. Apical pressure created during irrigation with the gentleWave™ system compared to conventional syringe irrigation. *Clin Oral Investig* 2016 Sep;20(7):1525-1534.
- Molina B, Glickman G, Vandrangi P, Khakpour M. Evaluation of root canal debridement of human molars using the GentleWave system. *J Endod* 2015 Oct;41(10):1701-1705.
- Sigurdsson A, Le KT, Woo SM, Rassoulilian SA, McLachlan K, Abbassi F, Garland RW. Six-month healing success rates after endodontic treatment using the novel GentleWave™ system: the pure prospective multi-center clinical study. *J Clin Exp Dent* 2016 Jul;8(3):e290-e298.
- Sigurdsson A, Garland RW, Le KT, Woo SM. 12-month healing rates after endodontic therapy using the novel GentleWave system: a prospective multicenter clinical study. *J Endod* 2016 Jul;42(7):1040-1048.
- Peters OA, Schönenberger K, Laib A. Effects of four Ni-Ti preparation techniques on root canal geometry assessed by micro computed tomography. *Int Endod J* 2001 Apr;34(3):221-230.
- Haapasalo M, Endal U, Zandi H, Coil JM. Eradication of endodontic infection by instrumentation and irrigation solutions. *Endod Topics* 2005 Mar;10(1):77-102.
- Kishen A, Peters OA, Zehnder M, Diogenes AR, Nair MK. Advances in endodontics: potential applications in clinical practice. *J Conserv Dent* 2016 May;19(3):199-206.
- Paqué F, Laib A, Gautschi H, Zehnder M. Hard-tissue debris accumulation analysis by high-resolution computed tomography scans. *J Endod* 2009 Jul;35(7):1044-1047.
- Paqué F, Boessler C, Zehnder M. Accumulated hard tissue debris levels in mesial roots of mandibular molars after sequential irrigation steps. *Int Endod J* 2011 Feb;44(2):148-153.
- Munoz HR, Camacho-Cuadra K. *In vivo* efficacy of three different endodontic irrigation systems for irrigant delivery to working length of mesial canals of mandibular molars. *J Endod* 2012 Apr;38(4):445-448.
- Beus C, Safavi K, Stratton J, Kaufman B. Comparison of the effect of two endodontic irrigation protocols on the elimination of bacteria from root canal system: a prospective, randomized clinical trial. *J Endod* 2012 Nov;38(11):1479-1483.
- Li D, Jiang S, Yin X, Chang JW, Ke J, Zhang C. Efficacy of needle, ultrasonic, and endoactivator irrigation and photon-induced photoacoustic streaming in removing calcium hydroxide from the main canal and isthmus: an *in vitro* micro-computed tomography and scanning electron microscopy study. *Photomed Laser Surg* 2015 Jun;33(6):330-337.
- Tay FR, Gu LS, Schoeffel GJ, Wimmer C, Susin L, Zhang K, Arun SN, Kim J, Looney SW, Padhley DH. Effect of vapor lock on root canal debridement by using a side-vented needle for positive-pressure irrigant delivery. *J Endod* 2010 Apr;36(4):745-750.
- Yost RA, Bergeron BE, Kirkpatrick TC, Roberts MD, Roberts HW, Himel VT, Sabey KA. Evaluation of 4 different irrigating systems for apical extrusion of sodium hypochlorite. *J Endod* 2015 Sep;41(9):1530-1534.
- Buldur B, Kapdan A. Comparison of the antimicrobial efficacy of the endovac system and conventional needle irrigation in primary molar root canals. *J Clin Pediatr Dent* 2017 Sep;41(4):284-288.
- Keleş A, Alçın H, Sousa-Neto MD, Versiani MA. Supplemental steps for removing hard tissue debris from isthmus-containing canal systems. *J Endod* 2016 Nov;42(11):1677-1682.

33. Ng YL, Mann V, Rahbaran S, Lewsey J, Gulabivala K. Outcome of primary root canal treatment: systematic review of the literature—part 1. Effects of study characteristics on probability of success. *Int Endod J* 2007 Dec;40(12):921-939.
34. Saini HR, Tewari S, Sangwan P, Duhan J, Gupta A. Effect of different apical preparation sizes on outcome of primary endodontic treatment: a randomized controlled trial. *J Endod* 2012 Oct;38(10):1309-1315.
35. Murphy WK, Kaugars GE, Collett WK, Dodds RN. Healing of periapical radiolucencies after nonsurgical endodontic therapy. *Oral Surg Oral Med Oral Pathol* 1991 May;71(5):620-624.
36. Vandrangi P. Evaluating penetration depth of treatment fluids into dentinal tubules using the GentleWave® system. *Dentistry* 2016 Mar;6:366.
37. Wang Z, Maezono H, Shen Y, Haapasalo M. Evaluation of root canal dentin erosion after different irrigation methods using energy-dispersive X-ray spectroscopy. *J Endod* 2016 Dec;42(12):1834-1839.
38. Ma J, Shen Y, Yang Y, Gao Y, Wan P, Gan Y, Patel P, Curtis A, Khakpour M, Haapasalo M. *In vitro* study of calcium hydroxide removal from mandibular molar root canals. *J Endod* 2015 Apr;41(4):553-558.