

CASE REPORT



Versatility and Importance of Bichat's Fat Pad in Dentistry: Case Reports of Its Use in Occlusal Trauma

¹Juan FD Montero, ²Humberto CM de Souza, ³Mariana S Martins, ⁴Miguel N Oliveira, ⁵César AM Benfatti
⁶Ricardo de Souza Magini

ABSTRACT

Introduction: The knowledge of the anatomy surrounding Bichat's fat pad, as well as its clinical applications, is essential to indicate and to safely perform its removal. This surgery is indicated not only for esthetic purposes, but also for functional reasons. When used properly, Bichat's fat pad is composed of stem cells that have a similar phenotype to adipose stem cells, useful in the treatment of pathologies and/or complications, such as maxillary sinus membrane perforation, oroantral/oronasal communications, peri-implantitis, ulcers, fibrosis of the oral mucosa, soft tissue reconstruction, among others. Due to its location, it is prone to suffer clinically significant pathologies, as well as constant trauma.

Aim: The aim of this study is to report two clinical cases and subsequent follow-ups, where bichectomy was performed to avoid dental trauma to mucosal tissues during the masticatory function. Also, literature review on the application of Bichat's fat pad in dentistry is provided.

Case report: Two female patients (20 and 24 years) reported discomfort and constant pain in the oral mucosa caused by dental trauma. At the clinical examination, patient presented augmented and injured mucosa. The surgical sequence of Bichat's fat pad removal, as well as the extra-/intraoral photographic follow-up (8, 15, 30, and 180 days) of the patients is described.

Conclusion: In order to indicate and/or accomplish surgical procedures involving Bichat's fat pad, it is fundamental to know its anatomy and possible applications, not only for esthetic purposes, but also for functional purposes. The patients showed evident improvements following the removal of Bichat's fat pad.

Clinical significance: Application of Bichat's fat and its removal should be evaluated, being an alternative in patients who constantly undergo mucosal injury during masticatory function.

Keywords: Adipose tissue, Bichat's fat pad, Oral lesions.

How to cite this article: Montero JFD, de Souza HCM, Martins MS, Oliveira MN, Benfatti CAM, de Souza Magini R. Versatility and Importance of Bichat's Fat Pad in Dentistry: Case Reports of Its Use in Occlusal Trauma. *J Contemp Dent Pract* 2018;19(7):888-894.

Source of support: Nil

Conflict of interest: None

INTRODUCTION

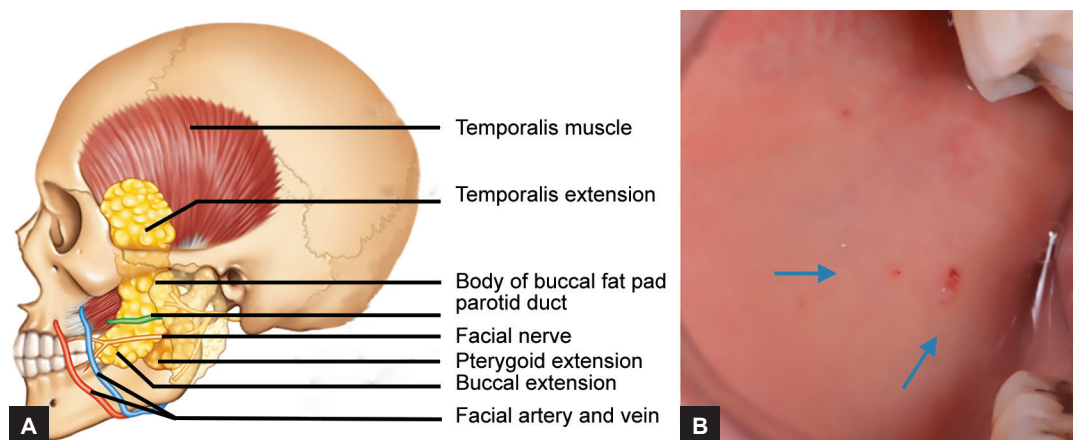
The adipose body of the cheek, also known as Bichat's fat pad, Bichat ball, cheek fat, buccal pad of fat, is a spherical fat mass surrounded by a thin layer of connective tissue, described by Bichat in 1802. It consists of a main body and four extensions (buccal, pterygoid, superficial temporal, and deep temporal) (Fig. 1A). It is located externally to the buccinator muscle and in front of the anterior margin of the masseter muscle, and it facilitates the movement of one muscle relative to another as well as contributing to the external morphology of the face. The Bichat's fat pad is especially prominent in newborns and infants and has been called a suction pad.¹

Bichat's fat pad plays an important role in the internal volume of the oral cavity, which can lead to frequent traumas causing discomfort and injury, with the possibility of evolving to pathologies, such as lipoma, herniation, and pseudoherniation.^{2,3}

Histologically, Bichat's fat pad is similar to body fat. However, in case of weight loss, its size does not reduce, contrary to other regions.⁴ The indication for the removal of Bichat's fat pad can change, being particular in each patient. Bichat's fat pad is removed when there is constant trauma to the cheeks caused by teeth during

¹⁻⁶Postgraduate Program in Dentistry, Center for Research and Education on Dental Implants, School of Dentistry, Federal University of Santa Catarina, UFSC Florianópolis, Santa Catarina, Brazil

Corresponding Author: Juan FD Montero, Postgraduate Program in Dentistry, Center for Research and Education on Dental Implants, School of Dentistry, Federal University of Santa Catarina UFSC, Florianópolis, Santa Catarina, Brazil, e-mail: jfdum@hotmail.com



Figs 1A and B: (A) Bichat's fat pad anatomy (image adapted from Kim et al)⁷ and (B) Lacerations in jugal mucosa caused by biting during the masticatory function

the masticatory function, generating traumatic ulcers. In India, oral submucous fibrosis, a disease with unknown etiology and with varied signs and symptoms, has been described. This oral submucous fibrosis can occur at any age; however, it is more common in adolescents and adults between the ages of 16 and 35.⁵ The oral fat pad can be removed or used in the surgical treatment of oral submucous fibrosis with good functional and esthetic results.⁶

Thus, with the objective of standardizing the indication and providing alternatives to the dentist, there is the need to present the surgical sequence of Bichat's fat pad extraction, as well as to describe its clinical applications, not only esthetic but also functional.

CASE REPORT

The following case reports describe two female patients, 20 and 24 years, presenting systemic conditions that conformed to the clinic of the Center for Research and Education on Dental Implants, at the Federal University of Santa Catarina. Patients initially reported discomfort in the oral mucosa with frequent lacerations caused during masticatory function (Fig. 1B), even without the presence of third molars or malocclusion, and also desired to improve the external face morphology. Before signing the consent term, patients were made aware of the procedure protocol, as well as the changes to expect during the postoperative follow-up.

Surgical planning was performed, starting with anesthesia: Buccal branch of the facial nerve, medial alveolar nerve, superior posterior alveolar nerve, inferior alveolar nerve, and the area surrounding Bichat's fat pad, and anesthesia will depend on the surgical technique and the place of access to the Bichat's fat pad; in this case, it was superior to Stensen's duct (Fig. 2).

After identifying the exit of the Stensen's duct from the parotid gland, a 1 cm length incision at a distance of 5 mm from the duct was performed. Tissues were dissected

with Kelly tweezers, allowing to identify Bichat's fat pad. Then, after holding the fat tissue with an Allis tweezer, delicate lateral traction movements were performed, without letting it go, thus guaranteeing the complete withdrawal. Soft tissue borders were repositioned and sutured with single interrupted absorbable sutures (Vicryl No. 4/0; Ethicon, Johnson & Johnson Company, SP, Brazil) (Fig. 3).

Thereafter, right and left side Bichat's fat pads were evaluated and compared, because due to their insertion, a part of it could still remain adhered to the adjacent structures. The removed Bichat's fat pads presented a mean length of 5.4 cm (Fig. 4).

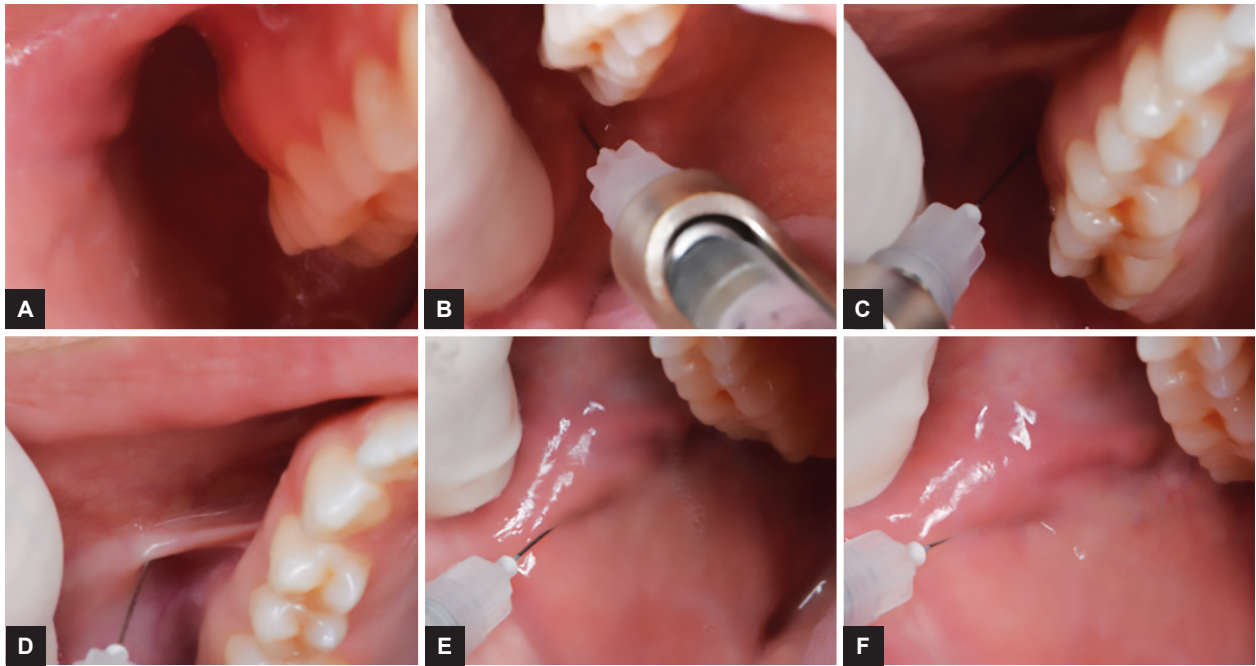
Both patients were evaluated previously, during and 8, 15, 30, and 180 days after surgery. Evaluation was performed by means of extra/intraoral examination and photographs to assess possible complications (Figs 5 and 6).

After intraoral follow-up of both cases, the improvement of the oral mucosa was evident, presenting tissue without lesions or signal lines of dental trauma to the mucosa, as well as the patient's notification of nontraumatic mucosa during masticatory function. The extraoral follow-up did not show great facial changes, given the conditions and facial classification, as well as the time of follow-up, although the patients reported changes in their face. In the search for evidence-based treatments, a review of Bichat's fat pad and its applications was carried out.

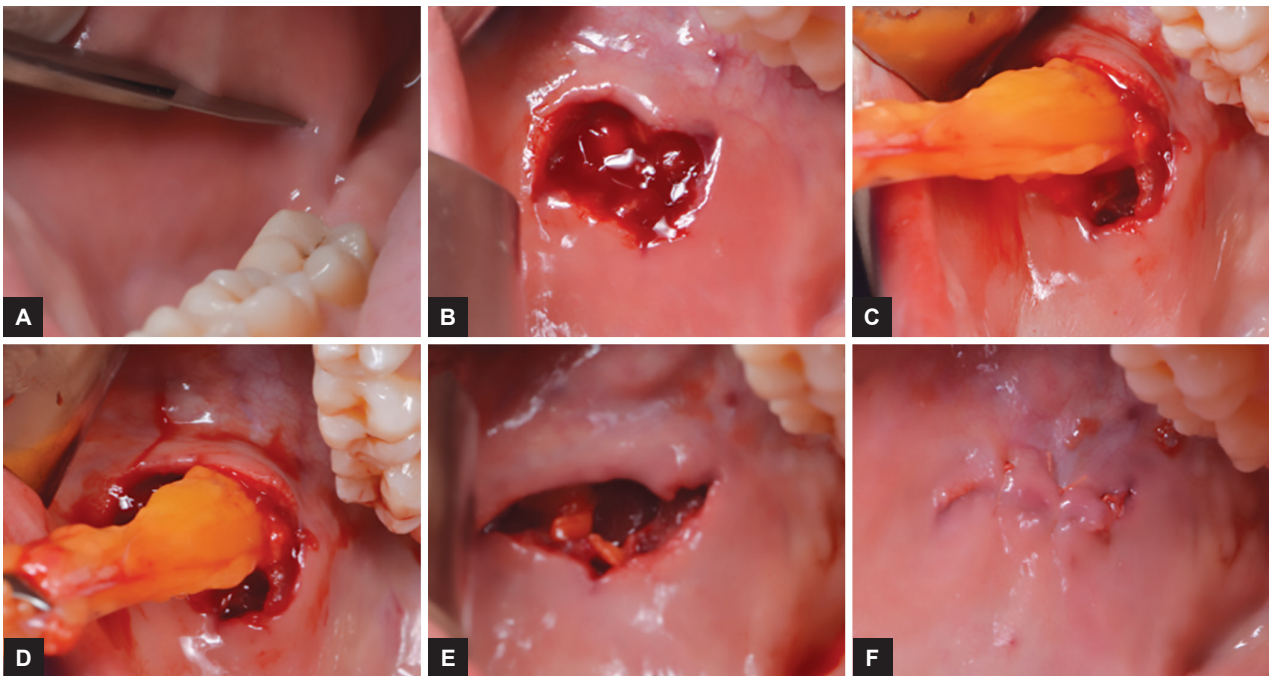
DISCUSSION/LITERATURE REVIEW

Anatomy and Function

Bichat's fat pad is limited by the buccinator muscle medially, the deep cervical fascia and the facial expression muscles anterolaterally, and the masticatory space and parotid gland posteriorly. Buccal space contents include Bichat's fat pad, the salivary glands, the parotid duct, the buccal artery, the facial artery and vein, the lymphatic



Figs 2A to F: Anesthesia. (A) Identification of the area to perform anesthesia, (B–E) Anesthesia of different blocks: buccal branch of the facial nerve, medial alveolar nerve, superior posterior alveolar nerve, inferior alveolar nerve, and (F) The area surrounding Bichat's fat pad



Figs 3A to F: Sequence of the surgical technique for removal of Bichat's fat pad, (A) Performing an incision of 1 cm superficial, (B) Dissecting the tissues, without deepening, identifying Bichat's fat pad, its characteristic orange color, (C and D) Bichat's fat pad traction with delicate and slow movements, in the lateral and front direction, (E) Verification of complete tissue removal, and (F) Single point suture

channels, and branches of facial and mandibular nerves,² with volume relatively consistent for men and women throughout their lives.

The morphology of the cheek fat body was first described by Bichat in 1802. Egyedi⁸ was the first to use it for oral defect reconstructions. The method described has shown no disadvantages in four cases. Defects in

hard palate and in posterior postextraction sockets up to a diameter of 4 cm can sometimes be closed just by covering them with the buccal fat pad and grafting the fat pad with a split thickness skin graft. However, some caution is recommended when using this approach.

Zhang et al⁹ described step by step the dissection procedure and the anatomical structures surrounding the

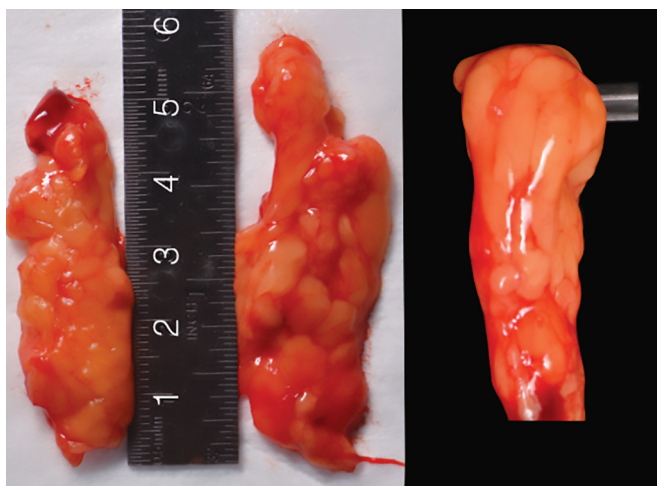


Fig. 4: Evaluation of the integrity and length with rule (5–6 cm) of Bichat's fat pad

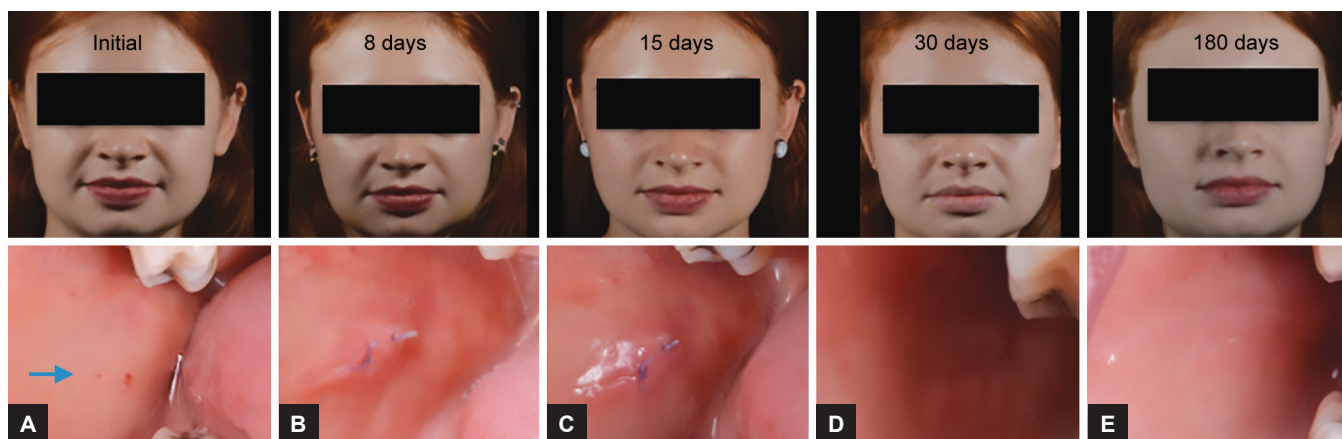
buccal fat pad in 11 head specimens (i.e., 22 sides of the face). The dissection showed that the buccal fat pad can be divided into three lobes: Anterior (triangular, located below the zygoma, and extending anterior to the buccinator), intermediate (in adults and large in children, located in the space surrounding the lateral maxilla between the anterior and posterior lobes), and posterior (located in the masticatory space), buccal, pterygoid, pterygopalatine, and temporal extensions (superficial and profound) are derived from the posterior lobe. The buccal fat pad is fixed by six ligaments to the maxilla, posterior zygoma, and inner and outer rim of the infraorbital fissure, temporalis tendon, or buccinator membrane. Several nutritional vessels exist in each lobe and in the subcapsular vascular plexus forms. Buccal fat pads fill deep tissue spaces, thus acting as gliding pads when masticatory and mimetic muscles contract, and cushion important structures from extrusion due to muscle contraction or outer force impulsion. Based on dissection findings, the authors provide several clinical applications for the buccal fat pad, such

as the mechanism of deepening the nasolabial fold and possible rhytidectomy to suspend the anterior lobe upward and backward. On the contrary, Loukas et al¹⁰ investigated its volumetric variation with computerized tomography and magnetic resonance imaging, as well as the thickness, weight, and volume with conventional methods in 80 formalin-fixed adult cadavers. They concluded that the mean volume of the cheek fat body was 10.2 mL (7.8–11.2) in men, while in women, the mean volume was 8.9 mL (7.2–10.8). In addition, the average thickness of the buccal fat pad was 6 mm, with an average weight of 9.7 g.²

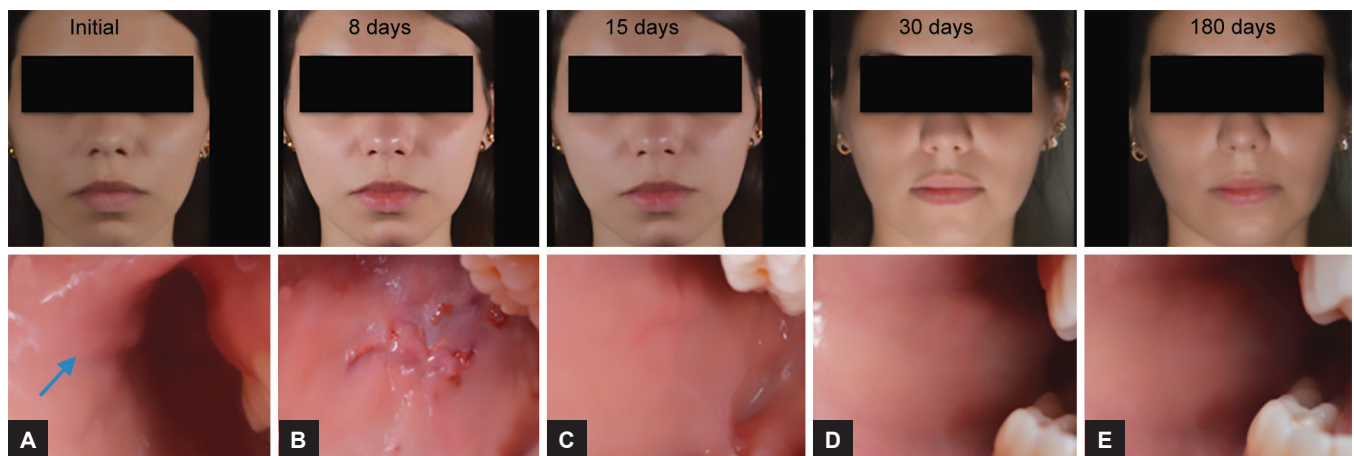
Due to its blood supply and location, Bichat's fat pad is an option for the treatment of many intraoral defects, presenting high success rates in several clinical applications (approximately 90%).⁷ These include the closure of oroantral fistula, rupture of the Schneiderian membrane, soft and hard tissue management, treatment of peri-implantitis, with functional and esthetic repercussions (facial contour). The prognosis can be influenced by etiological factors, defect size, anatomical location of the defect, and the general condition of the patient. Therefore, it is a useful and reliable tool that can be applied in various clinical situations.

Herniation

Due to its location, the cheek adipose body is prone to suffer clinically significant pathologies, such as lipoma, herniation, and pseudo-herniation.² Zipfel et al¹ reported the treatment for fat pad herniation, revealing that almost all reported cases of traumatic herniation occurred in young children. Zhang et al⁹ suggested that relaxation, poor development of ligaments, or rupture of buccal fat pad capsules which may lead to buccal extension or prolapse of the subcutaneous layer into the oral cavity can occur due to local trauma and, subsequently, herniation.



Figs 5A to E: Patient 1, extra-/intraoral photographs: (A) Initial after surgery, arrow indicating lacerations in the mucosa, (B and C) Follow-up of 8 and 15 days partially present suture, without complications and with a normal process of tissue healing, (D and E) Follow-up of 30 and 180 days completely healed tissue, without visible lacerations



Figs 6A to E: Patient 2, extra-/intraoral photographs: (A) Initial after surgery, arrow indicating tissue indicating mucosal lines, (B) Follow-up of 8 days partially present suture, without complications, (C) Follow-up of 15 days normal process of tissue healing, (D and E) Follow-up of 30 and 180 days completely healed tissue

In a systematic review, Kim et al¹¹ assessed the prognosis after surgical relocation and conservative treatment of buccal fat pad herniation. Initially, 811 articles were identified, and case series, case reports, technical notes, case reports with literature review, and retrospective case series were included. After screening and manual review, the sample was narrowed to 35 reports (41 patients) based on eligibility criteria. Patients' age ranged from 4 months to 12 years, with no specific gender predilection. Management consisted of excision (82.9%), relocation (14.6%), and observation (2.4%). Follow-up ranged from 1 week to 4 months. No reports presented a follow-up longer than 4 months.

Before performing any kind of treatment, it is of great importance to make an adequate diagnosis, by identifying each characteristic and its evolution. Khadilkar et al¹² performed a systematic review using the following terms: Traumatic pseudolipoma, traumatic prolapse of buccal fat pad, and traumatic avulsion of buccal fat pad. Of the 95 articles initially screened, 45 were included in the study; however, only 24 cases were found to have correctly reported the condition. The authors proposed a classification for posttraumatic craniofacial fatty masses (herniation of the buccal fat pad and fatty tumors), classification system: I, intraoral traumatic herniation of the buccal fat pad; II, antral traumatic herniation of the buccal fat pad; III, inward pseudoherniation of the buccal fat pad; IV, outward pseudoherniation of the buccal fat pad; V, post-traumatic pseudolipoma; and VI, posttraumatic lipoma.

Oronasal and Oroantral Communications

According to Egyedi,⁸ the adipose cheek body can be used mainly for the closure of communications like oroantral fistulas with satisfactory results.¹³ Abad-Gallegos et al¹⁴ obtained a complete closure of oroantral communications using the buccal fat pedicle. Immediate postoperative complications included pain (37.5%),

inflammation (37.5%), edema (32.5%), trismus (37.5%), halitosis (14.3%), suppuration (12.5%), and rhinorrhea (12.5%). Nonetheless, the authors concluded that it is a good option for large communications.

Facial Contour

The cheek fat body volume is relatively constant for both men and women, despite varying body weight and body mass index. In fact, the fat body of the cheek persists, to some extent, despite weight loss and subcutaneous fat loss. Matarasso¹⁵ performed the excision of the cheek fat body to improve the facial contour in some patients with oral lipodystrophy and to treat oral pseudoherniation of the fat pad. This author recommends an intraoral approach.

According to Hasse and Lemperle,¹⁶ the ideal candidate for resection of Bichat's fat pad has strong cheek bones that are hidden by prominent cheeks. After resection of the adipose cheek body, the zygomatic arch is accentuated. The result is a sculpted facial appearance. Bichat's fat pad should not be removed in patients with poorly developed malar bones, as it will exhibit insignificant esthetic results. Unfavorable results may be due to overcorrection to achieve a significant esthetic improvement. However, a reduction of 4 to 5 gm (weight/gram) can result in a marked change in the esthetic appearance. The upper part of Bichat's fat pad (parotid duct) has an important sliding function between the buccal, masseter, and temporal muscles during mastication. However, the resection of the lower half does not bring any functional impairment.¹⁶ The removal of this lower half is part of the surgical procedures for facial feminization/facial contour.¹⁷

Tissue Engineering

Stem cells provide an interesting tool for tissue engineering, but clinical applications are limited by morbidity of

the donor site and by the low number of cells harvested. Recent studies have identified an abundant source of stem cells in subcutaneous adipose tissue. Farré-Guasch et al⁴ showed that the buccal fat pad contains a population of stem cells that share a similar phenotype with adipose stem cells from subcutaneous abdominal adipose tissue and are also able to differentiate into chondrogenic, adipogenic, and osteogenic lineages. These results define Bichat's fat pad as a new, rich, and accessible source of adipose stem cells for tissue engineering purposes.

Oral Mucosa Ulcers and Fibrosis

Traumatic ulcers are one of the most common lesions in oral soft tissues.¹⁸ These are considered traumatic because they are produced by mechanical, chemical, electrical, or thermal irritation. A correct differential diagnosis is necessary to establish the appropriate treatment. It is usually characterized by short and painful episodes in which the causative agent should be excluded.¹⁸

Oral mucosa fibrosis has been highly described in India. It is a disease with unknown etiology and with varied signs and symptoms. It can occur at any age, but is most commonly seen in adolescents and adults in the age range between 16 and 35 years.⁵ Lambade et al⁶ evaluated several surgical treatment modalities for oral mucosal fibrosis affecting 20 patients with an interincisal mouth opening of less than 16 mm. The surgical procedure included fiberotomy, third molar extraction and coronoidotomy (or coronoidectomy) followed by reconstruction of the fiberotomy defect with Bichat's fat pad. They concluded that the adipose cheek body can be used effectively in the surgical treatment of oral mucosa fibrosis with good functional and esthetic results.

Sinus Membrane Perforation

The use of Bichat's fat pad is increasing due to its biological properties. It is useful for procedures, such as closing of a Schneiderian membrane perforation during elevation of the maxillary sinus. Falah and Srouji¹⁹ evaluated the bone formation under a perforated Schneiderian membrane grafted with adipose cheek body using the lateral window approach. In a preliminary study, six patients (24 dental implants) underwent sinus lift and the compartment around the implants under the lining of the sinus mucosa was filled with Bichat's fat pad; the bone consolidation in the maxillary sinus was radiologically and histologically observed within an average of 7.2 months after the sinus augmentation. According to the histomorphometric data, $62.8 \pm 13.1\%$ vital bone formation was observed despite the sample size limitation, it could be concluded that Bichat's fat pad can be considered as an autologous bone graft material.

Soft Tissue Management

Gingival recession is a condition that results in root exposure, which leads to root sensitivity, pain, caries, plaque retention, low esthetics, and tooth loss. Sites that present Miller's classes III and IV gingival recessions are not suitable for treatment with surgical root coverage techniques, as their prognosis is very poor with current techniques. Panda et al²⁰ reported the use of Bichat's fat pad as a subepithelial graft technique for root coverage of a class III gingival recession defect. It was possible to conclude that the adipose cheek body can be considered a reliable alternative for root coverage of gingival recession defects.

Also, de Moraes²¹ assessed the use of Bichat's fat pad as an option to prevent complications like oroantral communications after zygomatic implant surgery in patients with atrophic maxilla. Authors concluded that coating the implant with Bichat's fat pad presented a high success rate and that it is a viable and predictable treatment option to prevent and treat complications.

Bone Defects/Peri-implant and Peri-implantitis Treatment

Bichat's fat pad has also been used in the treatment of oral defects. Peñarrocha-Diago et al²² evaluated the use of the buccal fat pad as a bone graft material in the regeneration of the peri-implant bone defects of immediate implants placed in the posterior maxilla. Survival and success implant rates were found to be 97.6% and mean marginal bone loss 12 months after prosthetic loading was 0.58 ± 0.27 mm.

On the contrary, peri-implantitis is a common condition, but no specific treatment protocol has been shown to be definitely effective. Kablan²³ reported the use of Bichat's fat pad in the treatment of peri-implantitis. Bichat's fat pad was removed in eight patients and used in association with bone substitutes to regenerate 22 peri-implant lesions. Mechanical debridement of the implant surface and granulation tissue removal were done with curettes or erbium-doped yttrium aluminum garnet laser. Clinical parameters, such as plaque index, bleeding on probing, pocket depth, gingival recession, and adherence were recorded during the follow-up period. It was concluded that the use of Bichat's fat pad in the treatment of peri-implantitis increases bone protection and increases soft tissue at the receptor site. The free oral fat graft causes fibrosis, improving the level of adhesion of the soft tissue around implants and their survival. The mean follow-up period was 12 months and excellent functional and esthetic results were obtained without recurrence of peri-implantitis.

CONCLUSION

In the present case report, Bichat's fat pad were removed in two patients reporting pain and discomfort in the

mucosa caused by dental trauma during the masticatory function. The improvement of the oral mucosa was evident in the 8-, 15-, 30-, and 180-day postoperative follow-up.

CLINICAL SIGNIFICANCE

In order to indicate and/or accomplish surgical procedures involving Bichat's fat pad, it is fundamental to know its anatomy and possible applications, and Bichat's fat pad removal should be evaluated, being an alternative in patients who constantly undergo mucosal injury during the masticatory function.

REFERENCES

1. Zipfel TE, Street DF, Gibson WS, Wood WE. Traumatic herniation of the buccal fat pad: a report of two cases and a review of the literature. *Int J Pediatr Otorhinolaryngol* 1996 Dec;38(2):175-179.
2. Yousuf S, Tubbs RS, Wartmann CT, Kapos T, Cohen-Gadol AA, Loukas M. A review of the gross anatomy, functions, pathology, and clinical uses of the buccal fat pad. *Surg Radiol Anat* 2010 Jun;32(5):427-436.
3. Aldridge T, Thomson A, Ilankovan V. Abnormal anatomy of inferior orbital fissure and herniation of buccal fat pad. *Br J Oral Maxillofac Surg* 2015 Jan;53(1):92-93.
4. Farré-Guasch E, Martí-Pagè C, Hernández-Alfaro F, Klein-Nulend J, Casals N. Buccal fat pad, an oral access source of human adipose stem cells with potential for osteochondral tissue engineering: an *in vitro* study. *Tissue Eng Part C Methods* 2010 Oct;16(5):1083-1094.
5. Bande C, Dawane P, Gupta MK, Gawande M, Rode V. Immediate versus delayed aggressive physical therapy following buccal fat pad interposition in oral submucous fibrosis—a prospective study in Central India. *Oral Maxillofac Surg* 2016 Dec;20(4):397-403.
6. Lambade P, Dawane P, Thorat A. Efficacy of buccal fat pad in the surgical management of oral submucous fibrosis: a prospective study. *Oral Maxillofac Surg* 2016 Jun;20(2):167-170.
7. Kim MK, Han W, Kim SG. The use of the buccal fat pad flap for oral reconstruction. *Maxillofac Plast Reconstr Surg* 2017 Feb;39(1):5.
8. Egyedi P. Utilization of the buccal fat pad for closure of oro-antral and/or oro-nasal communications. *J Maxillofac Surg* 1977 Nov;5(4):241-244.
9. Zhang HM, Yan YP, Qi KM, Wang JQ, Liu ZF. Anatomical structure of the buccal fat pad and its clinical adaptations. *Plast Reconstr Surg* 2002 Jun;109(7):2509-2518.
10. Loukas M, Kapos T, Louis RG Jr, Wartman C, Jones A, Hallner B. Gross anatomical, CT and MRI analyses of the buccal fat pad with special emphasis on volumetric variations. *Surg Radiol Anat* 2006 Jun;28(3):254-260.
11. Kim SY, Alfafara A, Kim JW, Kim SJ. Traumatic buccal fat pad herniation in young children : a systematic review and case report. *J Oral Maxillofac Surg* 2017 Sep;75(9):1926-1931.
12. Khadilkar AS, Goyal A, Gauba K. The enigma of "Traumatic Pseudolipoma" and "Traumatic Herniation of Buccal Fat Pad": a systematic review and new classification system of post-traumatic craniofacial fatty masses. *J Oral Maxillofac Surg* 2018 Jun;76(6):1267-1278.
13. Galletti C, Cammaroto G, Galletti F, Camps-Font O, Gay-Escoda C, Bara-Casaus JJ. Dental implants after the use of bichat's buccal fat pad for the sealing of oro-antral communications. A case report and literature review. *J Clin Exp Dent* 2016 Dec;8(5):e645-e649.
14. Abad-Gallegos M, Figueiredo R, Rodríguez-Baeza A, Gay-Escoda C. Use of Bichat's buccal fat pad for the sealing of orosinus communications. A presentation of 8 cases. *Med Oral Patol Oral Cir Bucal* 2011 Mar;16(2):e215-e219.
15. Matarasso A. Managing the buccal fat pad. *Aesthetic Surg J* 2006 May-Jun;26(3):330-336.
16. Hasse FM, Lemperle G. Resection and augmentation of Bichat's fat pad in facial contouring. *Eur J Plast Surg* 1994 Sep;17(5):239-242.
17. Altman K. Facial feminization surgery: current state of the art. *Int J Oral Maxillofac Surg* 2012 Aug;41(8):885-894.
18. Muñoz-Corcuera M, Esparza-Gómez G, González-Moles MA, Bascones-Martínez A. Oral ulcers: clinical aspects. A tool for dermatologists. Part I. Acute ulcers. *Clin Exp Dermatol* 2009 Apr;34(3):289-294.
19. Falah M, Srouji S. Use of buccal fat pad for closure of perforation and graft material in a maxillary sinus elevation procedure: a preliminary study. *Int J Oral Maxillofac Implants* 2016 Jul-Aug;31(4):842-848.
20. Panda S, Del Fabbro M, Satpathy A, Das AC. Pedicled buccal fat pad graft for root coverage in severe gingival recession defect. *J Indian Soc Periodontol* 2016 Mar-Apr;20(2):216-219.
21. de Moraes EJ. The buccal fat pad flap: an option to prevent and treat complications regarding complex zygomatic implant surgery. Preliminary report. *Int J Oral Maxillofac Implants* 2012 Jul-Aug;27(4):905-910.
22. Peñarrocha-Diago M, Alonso-González R, Aloy-Prósper A, Peñarrocha-Oltra D, Camacho F, Peñarrocha-Diago M. Use of buccal fat pad to repair post-extraction peri-implant bone defects in the posterior maxilla. A preliminary prospective study. *Med Oral Patol Oral Cir Bucal* 2015 Nov;20(6):e699-e706.
23. Kablan F. The use of Buccal fat pad free graft in regenerative treatment of peri-implantitis: A new and predictable technique. *Ann Maxillofac Surg* 2015 Jul-Dec;5(2):179-184.