

## CASE REPORT



## Methodological Approach to the Endodontic Treatment of First Premolars with Three Root Canals: Two Case Reports

<sup>1</sup>Rémy Balthazard, <sup>2</sup>Pascale Corne, <sup>1</sup>Marin Vincent, <sup>1</sup>Eric Mortier

### ABSTRACT

**Aim:** The aim of this article was to promote a methodology in the endodontic management of complex premolars with multiple root canals

**Background:** The success of endodontic treatment depends on a meticulous clinical and radiographic analysis, the creation of a suitable access cavity and chemical and mechanical preparation, followed by three-dimensional filling of the entire root canal system. Consequently, it is essential to look for the presence of additional root canals to prevent endodontic treatment failure

**Case description:** Two cases are presented. The first case concerned a 50-year-old male patient of North African origin who consulted in the context of a global prosthetic restoration including endodontic treatment of the maxillary left first premolar (tooth no. 24).

The second case concerned a 29-year-old male patient of North African origin who was referred to us by his primary care practitioner in an urgent context of pain and infection present for two weeks (tooth no. 44).

In both cases, it was the in-depth radiographic analysis, combined with manual exploration under the surgical microscope, that led to the relatively rare identification of a third root canal. Shaping, disinfection and three-dimensional filling of the entire root canal system were then performed in accordance with widely validated protocols.

**Conclusion:** The maxillary and mandibular premolars, due to their highly variable root canal system configuration and a number of root canals and roots, appear to be teeth for which treatment is potentially complex.

The acuteness of digital-tactile sense and the advent of 3D imaging and optical aids optimize the treatment of all the root canals of a tooth

**Clinical significance:** These case reports demonstrate the importance of clinical and radiographic inspections to guide practitioners in the search for additional root canals in premolars and promote a methodological approach.

**Keywords:** Additional root canals, Mandibular first premolar, Maxillary first premolar, Root canal treatment.

**How to cite this article:** Balthazard R, Corne P, Vincent M, Mortier E. Methodological Approach to the Endodontic Treatment of First Premolars with Three Root Canals: Two Case Reports. *J Contemp Dent Pract* 2019;20(2):263-269.

**Source of support:** Nil

**Conflict of interest:** None

### BACKGROUND

The success of endodontic treatment is closely correlated, among other things, with anatomical and morphological knowledge of the teeth.<sup>1,2</sup> A thorough visual inspection of the crown is an initial step that provides a wealth of information before endodontic treatment is performed. When faced with an atypical crown morphology, practitioners should consider the presence of a potentially complex root canal anatomy. In addition, careful examination of preoperative X-ray films taken from different angles usually reveals specific root anatomy.<sup>3</sup> Given their numerous possible anatomical variations, premolars appear to be teeth that are potentially difficult to treat using endodontic methods.<sup>4-6</sup>

The mandibular first premolars have a single root in around 98% of cases, two roots in 1.8% of cases and three or more roots in 0.2% of cases; irrespective of the number of roots, two or more root canals are found in 24.2% of clinical cases.<sup>7</sup>

The maxillary first premolars are considered to present the greatest variations in terms of both their

<sup>1</sup>Department of Conservative Dentistry, Faculty of Dentistry, Vandoeuvre-lès-Nancy, France

<sup>2</sup>Department of Prosthodontics, Faculty of Dentistry, Vandoeuvre-lès-Nancy, France

**Corresponding Author:** Rémy Balthazard, Faculty of Dentistry, Vandoeuvre-lès-Nancy, France, Phone: +33 621 093 852, e-mail: remy.balthazard@univ-lorraine.fr

root anatomy and their root canal morphology.<sup>8</sup> In their review of the literature, Ahmad and Alenezi<sup>9</sup> demonstrated that the majority of maxillary first premolars present one (41.7%) or two roots (56.6%), while they have three roots in only 1.7% of cases. As regards root canal configuration, the majority of these premolars (86.6%) present two root canals, mostly with a type 4 configuration (64.8%) according to Vertucci's classification (Fig. 1).

However, it is important to note that all root canal configurations can be found in the premolars.

While these findings provide important indications to practitioners, guiding them in the search for potential additional root canals, it should be noted that they come from studies using different investigations methods, which may partly explain the heterogeneity in the results found.<sup>7</sup>

Several publications have established that the presence of a third root or an additional root canal was significantly influenced by the genetics, gender and ethnic or geographic origins of the patient.<sup>7-11</sup> Hence, for example, a high number of cases of teeth presenting additional roots and/or root canals has been reported in African, Chinese, Australian or Sub-Saharan populations, while the number appears to be lower in Western Arctic, Japanese or North American populations.<sup>7</sup>

These case reports present and describe the difficulties encountered during endodontic treatment of a maxillary first premolar and a mandibular premolar demonstrating complex root canal and root morphologies.

## CASE DESCRIPTION

The two cases presented were treated in the endodontics unit of the Department of Dentistry at Nancy University Hospital Center (France).

### Clinical Case 1

A 50-year-old male patient of North African origin consulted in the context of a global prosthetic restoration. The patient did not present any systemic contraindications to his dental treatment, requiring several endodontic retreatments, including treatment of the maxillary left first premolar (tooth no. 24). Since the tooth was asymptomatic, endodontic revision treatment was necessary due to a marked deterioration of the crown and incomplete initial endodontic treatment. A temporary resin crown was made to compensate for the crown tissue loss during a session prior to the endodontic procedures.

Careful examination of the preoperative retroalveolar X-ray film of tooth no. 24 revealed a partially filled palatal root and vestibular root and suggested the presence of a second untreated vestibular root (Fig. 2A). Following the removal of the temporary crown and the creation of an operative field, reshaping of the endodontic access cavity (EAC) and enlargement of the buccal crown part using an Endo Success Retreatment kit (Acteon, Mérignac, France) under a surgical microscope (Evolution xR6, Seiler, St Louis, USA) revealed the presence of a second mesiobuccal root canal not previously treated and confirmed the presence of a single canal per root

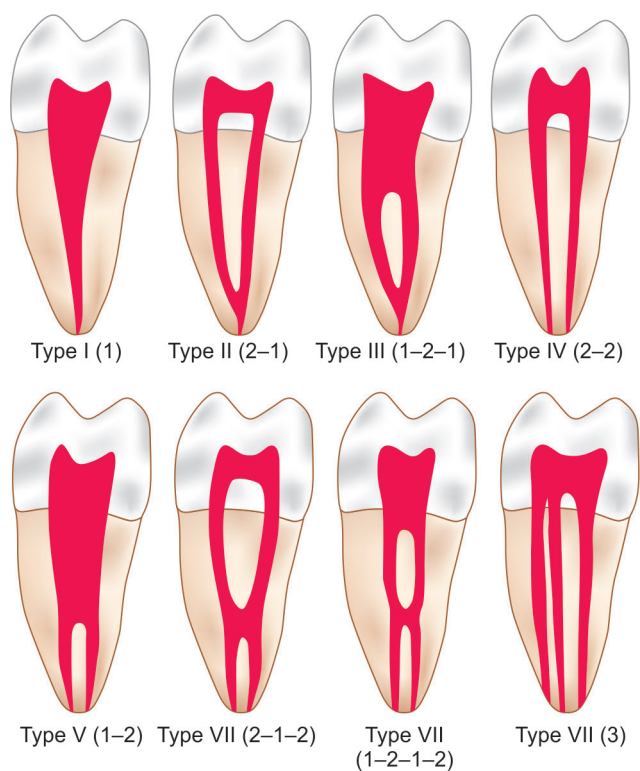


Fig. 1: Vertucci's classification of root canal morphology

(Vertucci type 1). Along with irrigation using 3% sodium hypochlorite (NaOCl) (Parcan, Septodont, St Maur des Fossés, France), root canal exploration and catheterization using manual files (Micro-Mega, Besançon, France) were performed. The working lengths were determined using an apex locator (Apex Pointer+, Micro-Mega), then confirmed by instrumental X-rays (Figs 2B and C).

Root canal shaping using a continuously rotating iRaCe Plus instrument sequence (FKG, La-Chaux-de-Fonds, Switzerland) resulted in a final prepared root canal with a diameter of 0.30 mm and 4% conicity. After validation using an X-ray with the master cones in place (Fig. 2D), a final irrigation sequence using 17% liquid EDTA (CanalPro EDTA, Coltène, Altstätten, Switzerland) then 3% sodium hypochlorite (Parcan, Septodont) was administered; activation of these solutions was performed using an EndoActivator (Dentsply Maillefer, Ballaigues, Switzerland). The root canals were then dried using sterile paper points then filled by thermomechanical compacting (Revo-Condensor, Micro-Mega) with gutta-percha (FKG) combined with a zinc oxide-eugenol root canal sealing cement (Sealite Regular, Acteon) (Fig. 2E). After removal of

the operative field, the temporary crown was resealed using carboxylate cement (Durelon, 3M, Saint Paul, MI, USA).

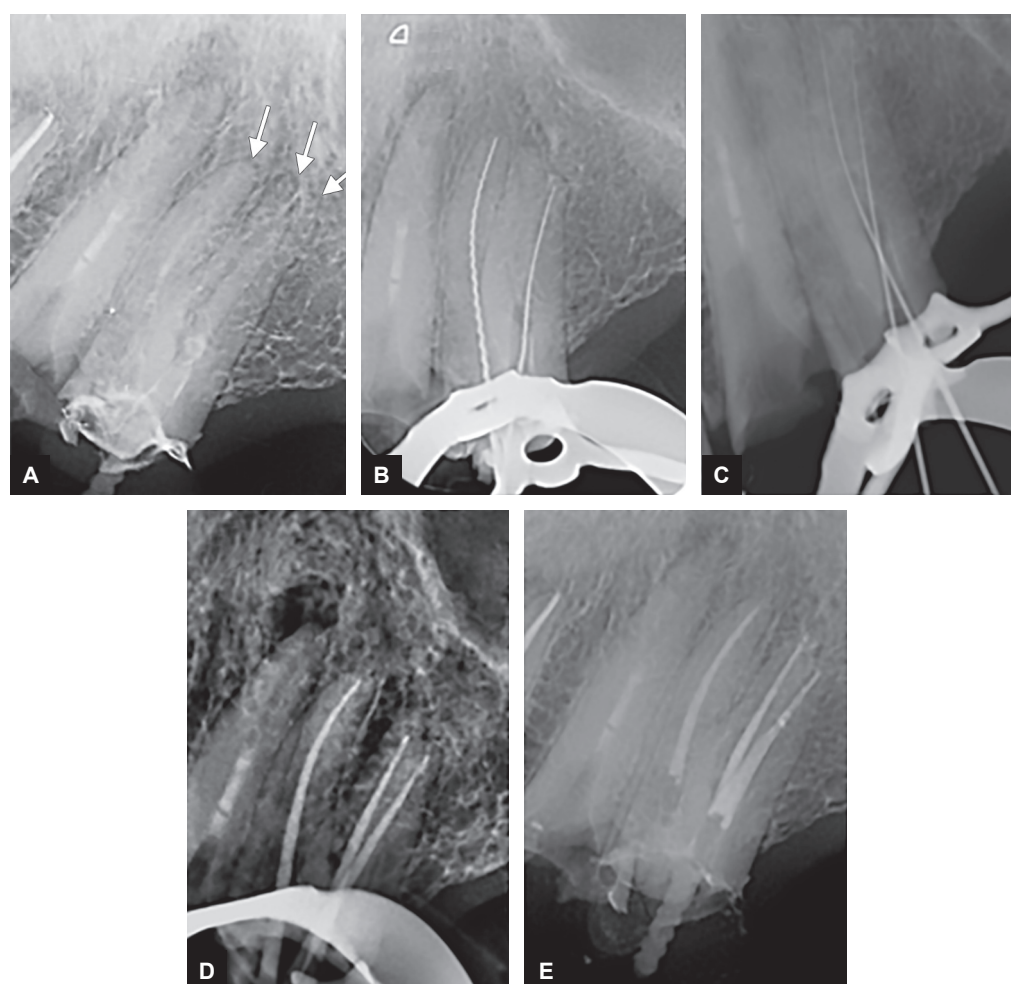
### Clinical Case 2

A 29-year-old male patient of North African origin was referred to us by his primary care practitioner in an urgent context of pain and infection present for two weeks. The patient did not present any systemic contraindications to his dental treatment. An extra-oral clinical examination revealed right submandibular cellulitis, the source of which was revealed to be the mandibular right first premolar (tooth 44).

The preoperative X-ray performed on the day of the consultation highlighted the presence of incomplete endodontic filling of tooth 44, associated with a large periapical lesion (Fig. 3A).

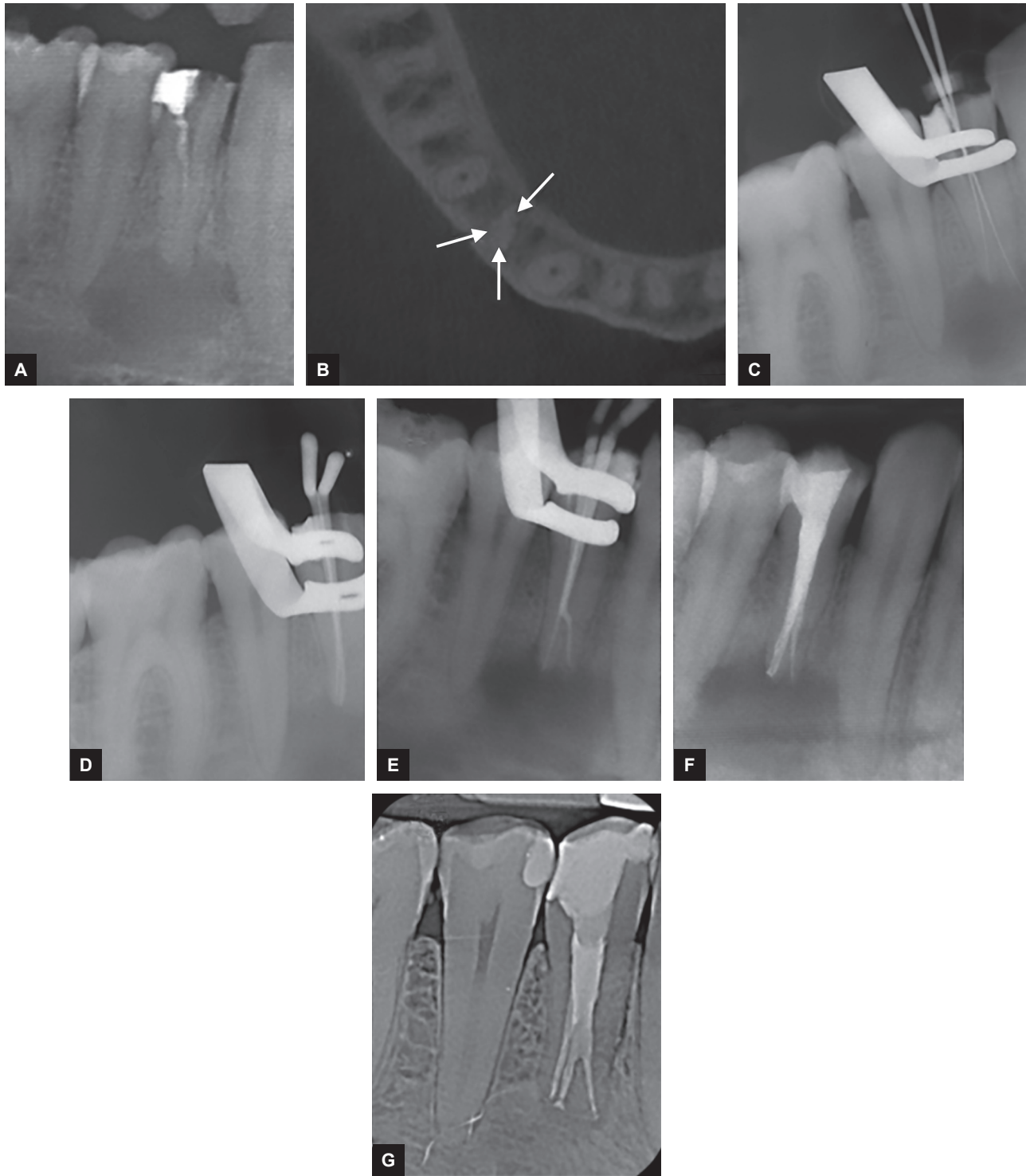
The disease history, combined with the clinical examinations and imaging findings resulted in a diagnosis of secondary acute apical periodontitis.

The disappearance of the root canal lumen in the main root canal suggested complex apical anatomy. The performance of a cone beam CT scan (CBCT)



**Fig 2A to E:** (A) Preoperative X-ray of the maxillary left first premolar showing the presence of three roots (Mesiobuccal, Distobuccal and Palatine; white arrows); (B and C) X-rays with files in place, validating the working length; (D) X-ray with the master cones in place, validating root canal preparation; (E) Postoperative X-ray showing filling of the three root canals





**Fig 3A to G:** (A) Preoperative X-ray of the mandibular right first premolar showing the presence of a bulky periapical lesion; (B) Cone-beam computed tomography image (axial view) showing the presence of three root canals (Mesiobuccal, Distobuccal, and Lingual; white arrows); (C) X-ray with files in place, validating the working length; (D and E) X-rays with the master cones in place, validating root canal preparation; (F) Postoperative X-ray showing filling of the three root canals and the placement of a temporary crown restoration; (G) Control X-ray after 18 months demonstrating apical healing and the placement of a permanent crown restoration

revealed the presence of two roots, including a buccal root with a type 5 root canal configuration and a lingual root with a type 1 root canal configuration according to Vertucci's classification (Figs 1 and 3B). In addition, the CBCT confirmed filling of only two-thirds of the coronal structures of the vestibular root canal upstream of its division.

The amalgam restoration was removed and a pre-endodontic restoration was performed using glass ionomer cement modified by the addition of resin (CVIMAR) (Fuji II LC, GC Corporation, Tokyo, Japan) before an operative field was created. No local anesthesia was used.

The presence of root canals was investigated under a surgical microscope (Evolution xR6, Seiler) after

enlargement of the coronal third using an Endo Success Retreatment kit (Acteon). The use of a surgical microscope and tactical sense via low-diameter manual files (MMC, Micro-Mega) enabled detection of the two buccal root canals and the palatine root canal. As in clinical case 1, irrigation with NaOCl (Parcan, Septodont) and manual catheterization, combined with electronic apex location (Apex Pointer +, Micro-Mega), enabled precise determination of the working length (Fig. 3C). In view of the symptoms, after physical debridement using an R2 instrument (25.04) from the iRaCe Plus sequence, intra-canal medication with calcium hydroxide was initiated for 7 days in order to reduce the bacterial load. Crown impermeability was ensured during the intermediate phase by filling with zinc oxide-eugenol (IRM, Dentsply Caulk, Milford, DE, USA).

After 7 days, following removal of the temporary filling and irrigation, root canal shaping was finalized, preparation was validated using X-rays with the master cones in place (Figs 3D and 3E), the final irrigation protocol was implemented and the root canals were filled in the same way as in clinical case No. 1 (Fig. 3F). After removal of the operative field, an impermeable temporary coronal filling was put in place using CVIMAR (Fuji II LC, GC). After 6 months, with all the symptoms have disappeared, the CVIMAR filling was removed and replaced by a resin composite restoration (Gaenial, GC).

Regular postoperative follow-up was carried out to monitor apical healing, demonstrated after 18 months (Fig. 3G).

## DISCUSSION

Chemical and mechanical debridement and complete three-dimensional filling of the root canal system are essential points that largely determine the success of endodontic treatment. The absence of localization, chemical and/or mechanical preparation and, finally, filling of a root canal is a known potential cause of endodontic treatment failure.<sup>12,13</sup>

The clinician must, therefore, know the crown and root morphology of all the tooth groups to detect any anatomical variation. The possible presence of an additional root canal must always be considered, primarily when performing endodontic treatment on premolars.<sup>1,14,15</sup>

According to Hoen and Pink, 42% of endodontic retreatment indications are related to the presence of an untreated root canal or root.<sup>16</sup>

The success of endodontic treatment, therefore, depends on a precise diagnosis and meticulous clinical and radiographic assessment.

The retroalveolar X-rays conventionally used during endodontic treatment may prove to be inadequate: the two-dimensional superimposition of three-dimensional

structures and the distortion of the image affect the quality and quantity of the information that can be detected.<sup>17</sup>

However, modifying the angle of the X-ray tube may be a solution to combat the superimposition of anatomical elements.<sup>18</sup> Following a straight, centered X-ray, a second film angled horizontally by 20 to 40° in a mesial or distal direction is a method of choice to visualize the presence of an additional root canal or root.<sup>18,19</sup> It was this method that was applied for clinical case No. 1.

In addition, a sudden change in root canal trajectory or the sudden disappearance of the canal lumen is signed to look out for that suggest the possible presence of additional root canals.<sup>20,21</sup> In clinical case 2, it was the sudden loss of lumen a few millimeters from the radiological apex, along with the patient's ethnic origin (North African), that prompted us to investigate for the presence of an additional root canal.

As more specifically regards the maxillary first premolars and the X-ray visualization of a third root, Sieraski et al.<sup>3</sup> suggested that a mid-root mesiodistal dimension greater than the coronal mesiodistal dimension is a significant indicator of the presence of such a third root.

The advent of cone beam CT scan imaging has made it possible to compensate for the shortcomings of two-dimensional imaging, simplifying the visualization and identification of specific anatomical characteristics and thereby facilitating the preoperative analysis and management of root canal problems during treatment.<sup>17,22</sup> In clinical case 2, it was the performance of a cone beam CT scan that confirmed the presence of a second canal within the buccal root (Fig. 3B).

In addition to coronal morphological analysis and examining of imaging films, it is necessary to follow meticulous surgical practices when creating the access cavity. Endodontic access cavities are generally oval-shaped in the vestibulopalatal axis on maxillary premolars and rounded on mandibular premolars.<sup>23</sup>

Maxillary first premolars with three roots are regularly called "small molars" in the literature.<sup>24</sup> This name, based on the similarity of their root anatomy to that of maxillary molars, suggests a more triangular-shaped EAC. Balleri et al.<sup>25</sup> recommend the creation of an EAC that is more T-shaped in this case, authorizing access to the buccal root canals while at the same time better preserving the coronal structures.

For mandibular premolars with three roots, Ordinola-Zapata et al.<sup>4</sup> also describe a triangle-shaped pulp chamber with a buccal base.

Despite adjustments made to the overall shape of EACs, detection of root canal entrances and visualization of additional root canals on these relatively small-volume teeth remains difficult.

Consequently, the use of a small-diameter, stainless steel manual file appears to be an effective method, combined with the practitioner's tactile sense. Hence, for example, the presence of a stop before the estimated working length may suggest the existence of an additional root canal.<sup>24,26</sup> In clinical case 2, we were able to locate and manage this complex apical configuration by using a manual file with a diameter of 10/100<sup>th</sup> and a pre-bent tip, after rotating it through a quarter turn when it came up against an abutment (Fig. 3).

In addition, optical aids, magnifying glasses or, preferably, a surgical microscope appear to be tools that greatly facilitate examination of the pulp floor, as well as detection and preparation of additional root canals.<sup>8,11</sup> In clinical case 1, it was the use of a surgical microscope (Fig. 2) that enabled us to locate the distobuccal root canal, despite the two buccal root canals sharing a common entrance. For clinical case 2, the microscope enabled precise differentiation between the different root canals and their consecutive shaping (Fig. 3).

It is important to note that the application of these various methods and techniques intended to ensure the clinical success of endodontic treatment has an impact on the duration of the procedure and assumes that adequate time has been allocated for surgery.<sup>13</sup>

## CONCLUSION

In-depth knowledge of crown and root anatomy is essential for the success of endodontic treatment. This knowledge is particularly important when treating premolars, which sometimes have a complex root canal morphology. Practitioners now have various methods and materials at their disposal to help them more easily overcome the problem. To this end, meticulous assessment of X-ray films, adjustment of the EAC, the use of an optical aid and manual exploration of the root canal based on tactile sense all represent simple and effective solutions. Lastly, the use of cone beam CT scan imaging removes any remaining doubt, confirming and supplementing the information initially collected by the practitioner.

## CLINICAL SIGNIFICANCE

These case reports demonstrate the importance of clinical and radiographic inspections to guide practitioners in the search for additional root canals in premolars and promote a methodological approach.

## REFERENCES

1. Friedman S. Prognosis of initial endodontic therapy. *Endod Topics*. 2002;2:59-88.
2. Krasner P, Rankow HJ. Anatomy of pulp chamber floor. *J Endod*. 2004 Jan;30(1):5-16.

3. Sieraski SM, Taylor GN, Kohn RA. Identification and endodontic management of three-canal maxillary premolars. *J Endod*. 1989 Jan;15(1):29-32.
4. Ordinola-Zapata R, Bramante CM, Villas-Boas MH, Cavenago BC, Duarte MH, Versiani MA. Morphologic micro-computed tomography analysis of mandibular premolars with three root canals. *J Endod*. 2013 Sep;39(9):1130-1135.
5. Slowey RR. Root canal anatomy. Road map to successful endodontics. *Dent Clin North Am*. 1979 Oct;23(4):555-573.
6. Weng XL, Yu SB, Zhao SL, Wang HG, Mu T, Tang RY, Zhou XD. Root canal morphology of permanent maxillary teeth in the Han nationality in Chinese Guanzhong area: a new modified root canal staining technique. *J Endod*. 2009 May;35(5):651-656.
7. Cleghorn BM, Christie WH, Dong CC. The root and root canal morphology of the human mandibular first premolar: a literature review. *J Endod*. 2007 Sep;33(9):509-516.
8. Kartal N, Ozcelik B, Cimilli H. Root canal morphology of maxillary premolars. *J Endod*. 1998 Jun;24(6):417-419.
9. Ahmad IA, Alenezi MA. Root and Root Canal Morphology of Maxillary First Premolars: A Literature Review and Clinical Considerations. *J Endod*. 2016 Jun;42(6):861-872.
10. Ok E, Altunsoy M, Nur BG, Aglarci OS, Çolak M, Güngör E. A cone-beam computed tomography study of root canal morphology of maxillary and mandibular premolars in a Turkish population. *Acta Odontol Scand*. 2014 Nov;72(8):701-706.
11. Trope M, Elfenbein L, Trondstad L. Mandibular premolars with more than one root canal in different race groups. *J Endod*. 1986 Aug;12(8):343-345.
12. Vertucci FJ. Root canal morphology and its relationship to endodontic procedures. *Endod Topics*. 2005;10:3-29.
13. Cantatore G, Berutti E, Castellucci A. Missed anatomy: frequency and clinical impact. *Endod Topics*. 2006;15:3-31.
14. Shalavi S, Mohammadi Z, Abdolrazzagh M. Root canal treatment of maxillary and mandibular three-rooted premolars: a case report. *Iran Endod J*. 2012 Summer;7(3):161-164.
15. Dadresanfar B, Khalilak Z, Shahmirzadi S. Endodontic treatment of a maxillary first premolar with type IV buccal root canal: A case report. *Iran Endod J*. 2009 Winter;4(1):35-37.
16. Hoehn MM, Pink FE. Contemporary endodontic retreatments: An analysis based on clinical treatment findings. *J Endod*. 2002 Dec;28(12):834-836.
17. Patel S, Dawood A, Whaites E, Pitt Ford T. New dimensions in endodontic imaging: part 1- conventional and alternative radiographic systems. *IntEndod J*. 2009 Jun;42(6):447-462.
18. Martínez-Lozano MA, Forner-Navarro L, Sánchez-Cortés JL. Analysis of radiologic factors in determining premolar root canal systems. *Oral Surg Oral Med Oral Pathol Oral RadiolEndod*. 1999 Dec;88(6):719-722.
19. Balakasireddy K, Pavan Kumar K, Gijo J, Gagan C. Cone Beam Computed Tomography Assisted Endodontic Management of a Rare Case of Mandibular First Premolar with Three Roots. *J Int Oral Health*. 2015 Jun;7(6):107-109.
20. Yoshioka T, Villegas JC, Kobayashi C, Suda H. Radiographic evaluation of root canal multiplicity in mandibular first premolars. *J Endod*. 2004 Feb;30(2):73-74.
21. Soares JA, Leornado RT. Root canal treatment of three rooted maxillary first and second premolars: A case report. *IntEndod J*. 2003 Oct;36(10):705-710.
22. Matherne RP, Angelopoulos C, Kulild JC, Tira D. Use of cone-beam computed tomography to identify root canal systems *in vitro*. *J Endod*. 2008 Jan;34(1):87-89.

---

*Methodological Approach to the Endodontic Treatment of First Premolars with Three Root Canals: Two Case Reports*

---

23. Krapež J, Fidler A. Location and dimensions of access cavity in permanent incisors, canines, and premolars. *J Conserv Dent.* 2013 Sep;16(5):404-407.
24. Maibaum W. Endodontic treatment of a "ridiculous" maxillary premolar: a case report. *General Dent.* 1989;37(4):340-341.
25. Balleri P, Gesi A, Ferrari M. Primer premolar superior com tresraices. *EndodPract.* 1997;3:13-15.
26. England MC Jr, Hartwell GR, Lance JR. Detection and treatment of multiple canals in mandibular premolars. *J Endod.* 1991 Apr;17(4):174-178.