

# Cone-beam Computed Tomographic Usage: Survey of American Endodontists

Ziyad T Alzamzami<sup>1</sup>, Ayman M Abulhamael<sup>2</sup>, Darshita J Talim<sup>3</sup>, Hala Khawaji<sup>4</sup>, Sarah Barzanji<sup>5</sup>, Rafael A Roges<sup>6</sup>

## ABSTRACT

**Aim:** The aim of this study was to investigate the acceptance, accessibility, and usage of cone-beam computed tomographic (CBCT) imaging among American Association of Endodontists (AAE) members in the United States by means of an online survey.

**Materials and methods:** An invitation to participate in a Web-based survey was sent to 3,000 members of the AAE. The survey consisted of 19 questions on demographics, access to CBCT machines, frequency of use for particular applications, and reasons in case CBCT was not used.

**Results:** A total of 477 endodontists responded to the survey, representing a 15.9% response rate. Around 91.8% of endodontists used CBCT imaging in their practice. Around 86% of endodontists had access to CBCT in their office, while 14% referred their patients to an outside office. Cone-beam computed tomographic units used by endodontists were Carestream (59.6%), Morita (20.8%), and Sirona (5.7%). Around 81.1% of endodontists didn't think CBCT imaging has high risk of radiation exposure; however, 10% of their patients declined CBCT imaging due to both cost and radiation exposure. Around 92.7% requested the segmental view when asking for CBCT. Endodontists' opinion was that CBCT enhances diagnosis of odontogenic pathosis, anatomical structures, treatment of iatrogenic errors, and diagnosis of nonodontogenic pathosis by 96.4%, 96.3%, 92.2%, and 88%, respectively. Around 93% of endodontists agreed that they would not consider doing CBCT for pregnant women. Majority of endodontists (74.6%) use CBCT in their practice for surgery, followed by 60.2% in nonsurgical retreatment. While 59.1% use CBCT in initial nonsurgical treatment, 44% reported that they use CBCT in endodontic recall and 9.2% use CBCT for pediatric patients.

**Conclusion:** CBCT technology is becoming the imaging modality of choice for nonsurgical retreatments and presurgical treatment planning. Endodontists deal with complex cases and thus the CBCT is a necessary tool that helps save a lot of time and effort during treatment procedures, looking for canals or determining why a previous treatment failed, and in providing the most comprehensive care.

**Clinical significance:** With the advancement in technology in the latest era, the three-dimensional CBCT imaging helped provide superior information over the two-dimensional periapical radiograph in making the correct diagnostic decision. This survey enlightened the usage of CBCT among endodontic practitioners in the United States.

**Keywords:** Cone-beam computed tomography, Dentistry, Endodontics, Survey.

*The Journal of Contemporary Dental Practice* (2019): 10.5005/jp-journals-10024-2661

## INTRODUCTION

Radiographic examination is considered to be one of the most essential tools in the assessment, diagnosis, and management of pathosis in the field of dental medicine and surgery. A radiograph plays an important role as a legal record and document for all patients who visit the dental office even just for a routine examination.<sup>1</sup> Nowadays, a combination of clinical and radiographic examination is a major key and an important tool that is used specifically in the field of endodontics to detect the presence of periapical pathosis and also provides information about the root canal anatomy and neighboring structures.<sup>2</sup> The most commonly used radiograph in the endodontic field is the periapical radiograph (PR),<sup>3</sup> but it has limitations.<sup>4</sup> Two-dimensional (2D) dental radiography has two basic shortcomings: the lack of early detection of pathosis in the cancellous bone, because of the density of the cortical plates, and the influence of the superimposition of anatomic structures.<sup>4</sup> It provides a 2D view of three-dimensional (3D) structures and hence hinders the detection of periapical radiolucency within the cancellous bone.<sup>4</sup> According to Seltzer, Bender et al., for the periapical radiolucency to be detected, 7.1% of the mineral component of the cortical bone needs to be lost.<sup>5-7</sup> In addition, it possesses geometrical distortions due to difficulty in placing the film/sensor parallel to the long axis of the tooth.<sup>8</sup> However, with the fast advancement in technology, a relatively new method was introduced into the dental field to

<sup>1,2</sup>Department of Endodontics, Faculty of Dentistry, King Abdulaziz University, Jeddah, Kingdom of Saudi Arabia

<sup>3,6</sup>Department of Endodontics, Herman Ostrow School of Dentistry, University of Southern California, Los Angeles, California, USA

<sup>4,5</sup>Dental Department, King Abdulaziz Medical City, Jeddah, Kingdom of Saudi Arabia

**Corresponding Author:** Ziyad T Alzamzami, Department of Endodontics, Faculty of Dentistry, King Abdulaziz University, Jeddah, Kingdom of Saudi Arabia, Phone: +966 555646766; e-mail: dryamaniz@me.com

**How to cite this article:** Alzamzami ZT, Abulhamael AM, Talim DJ, et al. Cone-beam Computed Tomographic Usage: Survey of American Endodontists. *J Contemp Dent Pract* 2019;20(10):1132-1137.

**Source of support:** Nil

**Conflict of interest:** None

overcome these limitations called CBCT, which stands for cone-beam computed tomography.<sup>8</sup>

Cone-beam computed tomography is an extraoral medical imaging technique that provides a 3D scan of the maxillofacial skeleton. A version of this technology has been around since the early 1980s; it is obtained by a cone-shaped X-ray beam.<sup>2</sup> The entire exposed area possessed through one radiation exposure and revolution. The machine rotates between

180 and 360 degrees around the patient's head; it takes only few seconds to acquire the image.<sup>2</sup> Compared with the traditional X-ray method, CBCT is a 3D technique that offers the possibility to visualize the teeth and their surrounding tissues in horizontal, vertical, and axial views.<sup>2</sup> Nevertheless, CBCT has some limitations that should be taken into consideration when utilizing it. Some of the major drawbacks are the amount of radiation exposure, the field of view, lack of training and interpretation of the data, and the resolution of the scans.<sup>4</sup>

In 2016 a study was conducted in Tokyo University by Uraba et al.; they found that CBCT imaging is effective in detecting periapical lesions that cannot be detected on a PR, particularly in the maxillary incisors/canines and molar regions. The overall periapical lesion detection rates of PR and CBCT imaging were 31.5% and 52.2%, respectively.<sup>3</sup>

According to Frank et al., there is a widespread application of the CBCT technology in endodontic practice; a large number of survey respondents agreed on the fact that the CBCT technology can deliver additional information not available from 2D radiography.<sup>9</sup>

Recently, with the advancement in technology the field of CBCT, systems have witnessed several expansions in their application and utilization.<sup>4</sup> The global CBCT systems market is segmented on the basis of many different variables according to its specific uses and application. The aim of this study was to determine the uses of CBCT among endodontists on a daily basis to help them in the assessment, diagnosis, and treatment of their cases and how often they need to add CBCT to the conventional PR and if there is a definite condition to use CBCT.

## MATERIALS AND METHODS

An invitation to participate in an online survey administered through the Guatrics software was e-mailed through Herman Ostrow School of Dentistry of University of Southern California (USC) to 3,000 U.S. endodontists listed as "active" in the online membership directory of the American Association of Endodontists (AAE). The survey was administered over a 4-week period between November 2018 and December 2018 in the United States. The survey consisted of 19 questions on demographics, access to CBCT machines, type of the CBCT unit, field of view (FOV) used, frequency of using CBCT for particular cases, cost of the CBCT, and the reasons for not having a CBCT machine on the site (Fig. 1). In the survey for those who do not use CBCT imaging in their endodontic treatment and answered that question with "NO," the survey software will automatically take them to the end of the survey and will not let them continue the survey in order not to skew the data. The questions were asked to see the opinion of endodontists in using CBCT in endodontic practice. To encourage respondents to answer all questions, an error message was delivered if questions were left unanswered. Participants were informed that the survey was a research project and that anonymity of participants was assured.

## RESULTS

A total of 477 endodontists responded to the survey, representing a 15.9% response rate. Around 97.7% ( $n = 466$ ) of participants in practice had their practice limited to endodontics. Around 92% ( $n = 440$ ) were practicing in a private clinic setting, and 91% ( $n = 434$ ) of them practiced for more than 20 hours per week. Around 64.8% ( $n = 309$ ) of the participants were practicing endodontics for more than 10 years. Around 18.6% ( $n = 89$ ) were in practice for 5 to 10 years, and the remaining 16.6% ( $n = 79$ ) had been in practice for

less than 5 years. Around 91.8% ( $n = 438$ ) of the respondents used CBCT imaging as part of their endodontic treatment.

When it came to the accessibility of the CBCT ( $n = 375$ ), 86% of endodontists had access to CBCT in their office while 14% ( $n = 63$ ) did not, and they refer their patients to an outside office for CBCT. However, they agreed that the reason for not having the CBCT machine in their office was the high cost, and they would consider buying it if the cost of the machine was affordable to them.

Endodontists reported using Carestream (59.6%;  $n = 261$ ), Morita (20.8%;  $n = 91$ ), and Sirona (5.7%;  $n = 25$ ). Where the resolution of the image is important in diagnosing and treatment of endodontic infections, 80.8% ( $n = 354$ ) of the participants were satisfied with the resolution of their machines.

Although 81.1% ( $n = 387$ ) of the endodontists who responded did not think that CBCT imaging had a high risk of radiation exposure (Fig. 2), 10% of their patients declined using CBCT imaging due to both cost and radiation exposure (Fig. 3).

Around 92.7% ( $n = 406$ ) of the endodontists preferred using segmental views (limited FOV). However, 4.8% ( $n = 21$ ) and 2.5% ( $n = 11$ ) did use CBCT imaging for both jaws/arches and full jaw/arch CBCT, respectively.

When asked about the fee, 34% ( $n = 151$ ) did not include CBCT fees as a part of their treatment fee, while 15% ( $n = 64$ ) included it in the treatment fees.

As per their opinion, the percentage of participants who agreed that CBCT usage enhanced the diagnosis of odontogenic pathosis, diagnosis of anatomical structures, treatment of iatrogenic errors, and diagnosis of nonodontogenic pathosis were 96.4% ( $n = 460$ ), 96.3% ( $n = 459$ ), 92.2% ( $n = 440$ ), and 88% ( $n = 420$ ), respectively (Fig. 4).

Endodontists agreed on using CBCT in certain conditions like difficult cases with difficult anatomy, trauma, and diagnosis of complex cases like vertical root fracture (VRF). However, the majority (93%;  $n = 347$ ) of endodontists agreed that they would not consider doing CBCT for pregnant women (Fig. 5).

Majority of endodontists (74.6%;  $n = 356$ ) use CBCT in their practice for surgery, followed by 60.2% ( $n = 287$ ) in nonsurgical retreatment. While 59.1% ( $n = 282$ ) use CBCT in initial nonsurgical treatment, 44% ( $n = 208$ ) reported that they use CBCT in endodontic recall and 9.2% ( $n = 44$ ) use CBCT for pediatric patients (Fig. 6).

## DISCUSSION

The aim of this survey was to assess whether the use of the CBCT technology among endodontists has become more prevalent over the years and in what clinical situations practitioners think it is an essential tool before rendering root canal therapy. According to the AAE and American Academy of Oral and Maxillofacial Radiology (AAOMR) joint position statement published in 2015, limited FOV CBCT should be considered the imaging modality of choice for diagnosis in patients who present with contradictory or nonspecific clinical signs and symptoms associated with untreated or previously endodontically treated teeth, nonhealing endodontic treatment, trauma, resorptions, implants, and VRFs. It is also recommended for initial treatment of teeth with the potential for extra canals and suspected complex morphology such as mandibular anterior teeth and maxillary and mandibular premolars and molars and dental anomalies. It is also recommended for the localization of calcified canals either initially or during treatment.<sup>10</sup>

According to De Paula-Silva et al., small FOV CBCT scans have an accuracy of 0.92 in detecting apical periodontitis, which is significantly higher than that for PRs.<sup>11</sup> According to Abella et al.,

**CBCT USE IN ENDODONTIC PRACTICE**

Q1) Is your practice limited to endodontics?

- ☐ Yes
- ☐ No

Q2) Are you practicing endodontics in

- ☐ Private practice
- ☐ University
- ☐ Military
- ☐ Other (please state) \_\_\_\_\_

Q3) How long have you been practicing endodontics

- ☐ 1–5 years
- ☐ 5–10 years
- ☐ >10 years

Q4) How many hours per week do you practice endodontics?

- ☐ Less than 10 hrs.
- ☐ 10–20 hrs.
- ☐ More than 20 hrs.

Q5) If the cost of the CBCT unit was affordable to you would you consider purchasing it?

- ☐ Yes
- ☐ No

Q6) Do you think CBCT has a high risk of radiation exposure

- ☐ Yes
- ☐ No
- ☐ Maybe

Q7) In your opinion, CBCT enhances (check all that apply):

- Diagnosis of odontogenic pathoses
- Diagnosis of non-odontogenic pathoses
- Diagnosis of anatomical structures
- Treatment of iatrogenic errors

Q8) Do you use CBCT images for endodontics?

- ☐ Yes
- ☐ No

Condition: No Is Selected. Skip To End of Survey.

Q9) How long have you been using CBCT?

- ☐ <5 years
- ☐ >5 years

Q10) How do you obtain CBCT images?

- ☐ In your office
- ☐ Patient is referred to an out of the office imaging center

Q11) If you send your cases for CBCT to an outside Imaging center, it is due to:

- ☐ The cost of the CBCT unit
- ☐ Insufficient space in your practice
- ☐ You don't feel comfortable taking them
- ☐ Not applicable (I do them in my own office)

Q12) The CBCT facility unit you use in your practice is:

- ☐ Sirona
- ☐ Carestream
- ☐ J Morita
- ☐ Others (please specify): \_\_\_\_\_

Q13) Are you satisfied with the resolution of the CBCT

- ☐ Yes
- ☐ No

Q14) The CBCT in your practice is for (check all that apply):

- ☐ Initial Non-surgical Treatment <50% of cases
- ☐ Initial Non-surgical Treatment >50% of cases
- ☐ Non-surgical Retreatment <50% of cases
- ☐ Non-surgical Retreatment >50% of cases
- ☐ Endodontic Surgery <50% of cases
- ☐ Endodontic Surgery >50% of cases
- ☐ Pediatric (<18 years) patients <50% of cases
- ☐ Pediatric (<18 years) patients >50% of cases
- ☐ Endodontic Recall <50% of cases
- ☐ Endodontic Recall >50% of cases

Q15) Fees for CBCT are:

- ☐ Included in the treatment
- ☐ Not Included in the treatment
- ☐ Charged to the patient <200\$
- ☐ Charged to the patient >200\$

Q16) The % of patients who decline CBCT due to radiation concerns?

- ☐ <10%
- ☐ 11–30%
- ☐ 31–50%
- ☐ >50%

Q17) The % of patients who decline CBCT due to cost?

- ☐ <10%
- ☐ 11–30%
- ☐ 31–50%
- ☐ >50%

Q18) Would you consider using

- ☐ CBCT for o Pregnant women
- ☐ Difficult cases with difficult anatomy
- ☐ Trauma
- ☐ Diagnosis of special cases like Vertical Root Fracture (VRF)

Q19) When you request CBCT do you ask for

- ☐ Segmental CBCT
- ☐ Full Jaw CBCT
- ☐ CBCT of both Jaws

**Fig. 1:** Detailed questionnaire of a survey about CBCT usage among endodontists in the United States

CBCT imaging has advantages in detecting apical periodontitis lesions especially in teeth with symptomatic irreversible pulpitis as compared with PA radiography.<sup>12</sup> In a systematic review by Aminoshariae, Kulild, and Syed, they concluded that when 2D intraoral radiography was inconclusive, CBCT imaging had twice the

odds of detecting a periapical lesion than traditional radiography in endodontic outcome studies.<sup>13</sup>

The position statement also recommends that limited FOV CBCT should be considered as the imaging modality for intra-appointment identification and localization of calcified canals.<sup>10</sup> According to

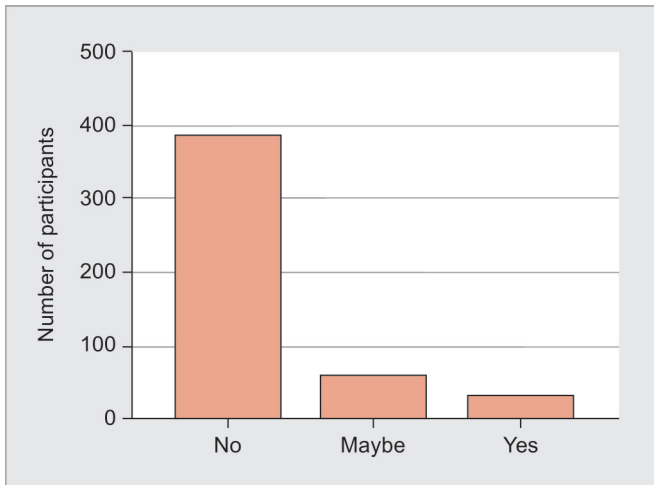


Fig. 2: CBCT and high risk of radiation exposure

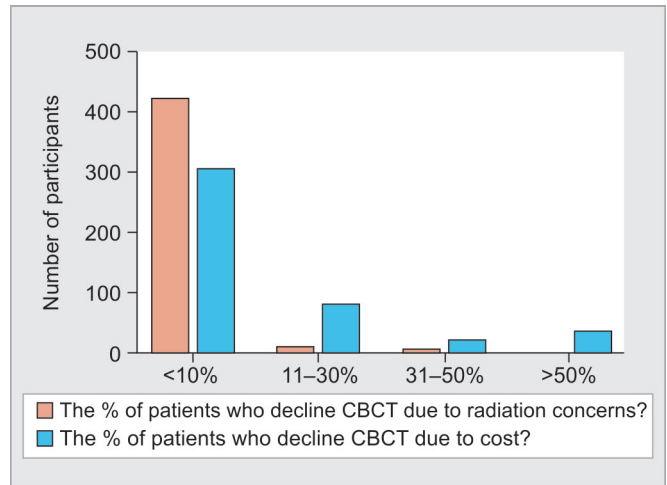


Fig. 3: Patient who declines CBCT due to cost and radiation

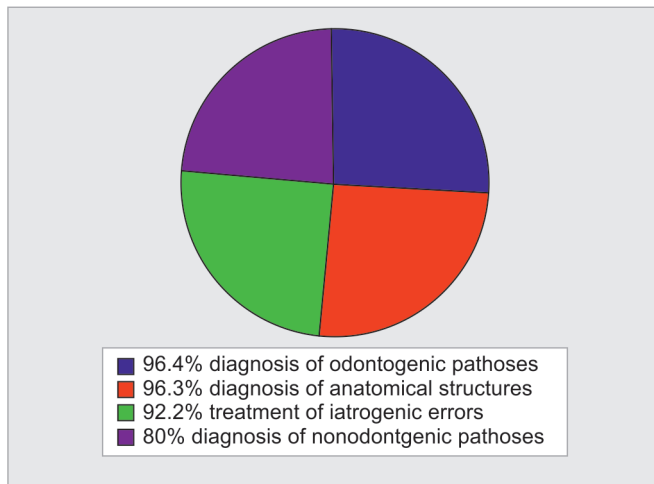


Fig. 4: CBCT and diagnosis

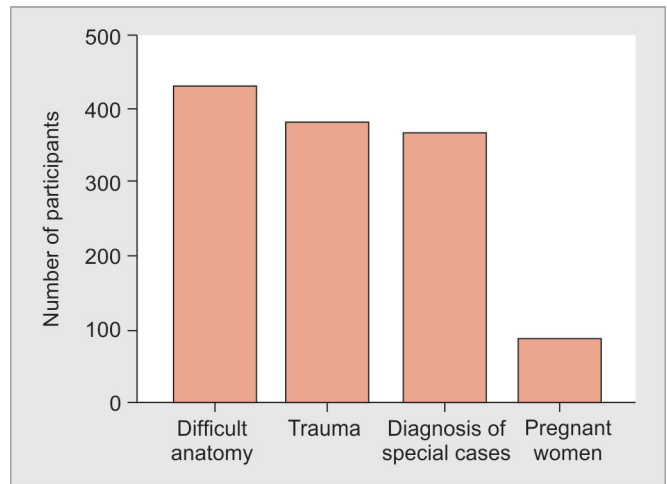


Fig. 5: Specific application of CBCT

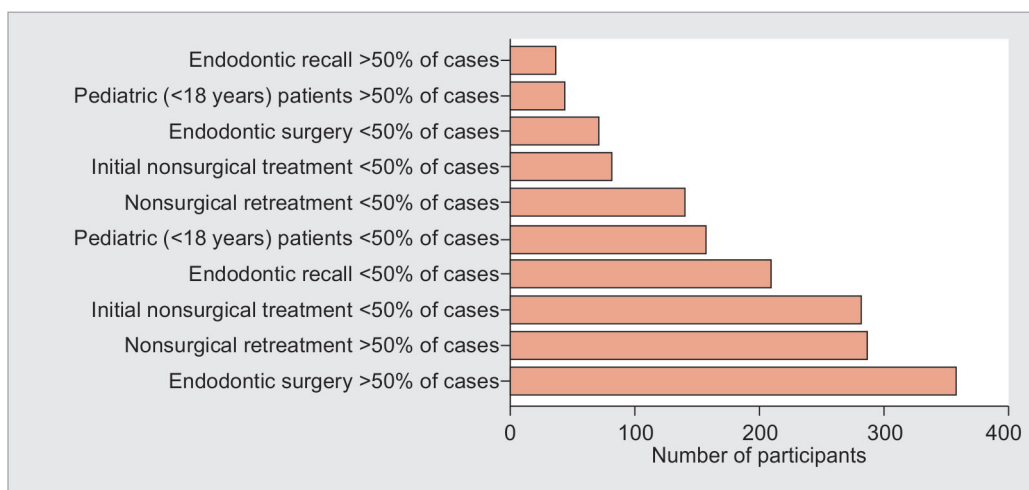


Fig. 6: Consideration of uses of CBCT

our survey, 92% of the participants agreed that it enhanced the visualization of anatomical structures and 59.1% of the survey participants use CBCT more than 50% of the time to treat initial cases.

As per the recommendations of the joint position statement, limited FOV CBCT should be considered the imaging modality of choice for nonhealing of previous endodontic treatment to help



determine the need for further treatment such as nonsurgical, surgical, or extraction and to assess endodontic treatment complications such as overextended root canal obturation material, separated endodontic instruments, and localization of perforations.<sup>10</sup> Rodríguez et al. tested the use of CBCT and its influence on retreatment strategies among general dental practitioners and endodontists as compared to 2D imaging and found a significant difference in the treatment plan between the two imaging modalities; they concluded that CBCT imaging directly influences retreatment strategies among both general dentists and endodontists.<sup>14</sup> Ee et al. also found that treatment planning decisions using CBCT vs intraoral radiographs; an accurate diagnosis was reached in 36–40% of the time using intraoral radiographs and 76–83% of the time when using CBCT.<sup>15</sup>

According to Karabucak et al., in a retrospective cohort study of the greater Philadelphia area patient population there was a significant difference in lesion prevalence in endodontically treated teeth when a canal was missed/untreated.<sup>16</sup> They concluded that limited FOV CBCT imaging should be examined before any endodontic retreatment to identify missed canals.

Another recommendation is the use of the CBCT in teeth with calcified canals. According to this survey, 96.2% used the CBCT to help demystify complex morphology.<sup>16</sup>

Limited FOV CBCT should be considered the modality of choice if clinical examination and 2D intraoral radiography are inconclusive in the detection of VRF. The first to investigate the ability of CBCT to diagnose VRF were Hassan, Metska, and Wesselink.<sup>17</sup> They investigated 39 endodontically treated teeth with suspected VRF where no fracture line could be detected on the 2D radiograph; they found a sensitivity of 93% in detecting VRF.<sup>17</sup> In nonsurgical retreatment, the presence of VRF reduces the prognosis by examining the patterns of bone loss and PDL space enlargement. It may not always be possible to view the fracture directly because detection is dependent on the size of the fracture and is only visible if the size is double the size of the resolution of the scan.<sup>17</sup>

According to Schloss et al., CBCT analysis allowed a more precise evaluation of periapical lesions and healing after micro-endodontic surgery than periapical films.<sup>18</sup> CBCT imaging should also be considered the choice for nonsurgical retreatment to assess endodontic treatment complications, such as overextended root canal obturation material, separated endodontic instruments, and localization of perforations.<sup>10,17</sup>

A recent study by Patel et al. assessed the impact of different diagnostic imaging modalities on the assessment of root canal anatomy and stress levels of endodontic residents. The group of residents who were provided with CBCT imaging along with access to the software in addition to the PA radiographs were the least stressed and rendered better-quality root canal therapy.<sup>19</sup>

An emerging additional use of CBCT scans is in computer-aided design/computer-aided manufacturing (CAD/CAM)-guided microsurgery, a case report series of surgeries performed at the Air Force Post Graduate Dental School, Joint Base San Antonio. Giacomino et al. shed light on indications for targeted endodontic microsurgery using printed guides and trephine burs.<sup>20</sup>

It is the opinion of the authors that endodontic access with prior CBCT evaluation most likely reduces the amount of dentin removed, thus preserving the structural integrity of the tooth.

### Limitations of the Study

Our survey had a low response rate of 15.9%, and interpretation of the results should be done with caution. A study conducted by

McLeod et al. used 60% as a benchmark for responses to surveys.<sup>21</sup> According to their study they found a steady decline in response rates, from 61% in the year 2000 to 36% in 2008. Funkhouser et al. found that surveys of healthcare professionals usually have low response rates.<sup>22</sup> They found that multiple methods of recruitment resulted in a high participation rate. We did not employ different methods, and our questionnaire was sent out only once via e-mail. This may explain why our response rate was low. In addition, older dentists may tend to prefer completing paper surveys rather than online surveys.<sup>22</sup>

Another limitation of our study was that we obtained our information anonymously. As a result, even though we obtained data regarding the number of years of experience of the endodontist, we could not correlate that to the answers provided as the survey was anonymous. Hence, no conclusions could be drawn to see if the experience of the clinician changed the treatment approach regarding the use of CBCT.

### CONCLUSION

This survey shows an increase in the use of the CBCT technology in a myriad of endodontic clinical situations. It is becoming the imaging modality of choice for all endodontic treatments. Endodontists for the most part deal with only complex cases, thus CBCT imaging is becoming a necessary diagnostic tool in helping clinicians evaluate cases in three dimensions and thus becomes more efficient during treatment procedures such as finding calcified canals or determining why a previous treatment did not heal. Although the cost of owning your own unit can be a deterrent factor, the time has clearly come to enhance our ability to see in three dimensions so that we can improve patient care.

### REFERENCES

1. Charangowda BK. Dental records: An overview. *J Forensic Dent Sci* 2010 Jan–Jun;2(1):5–10. DOI: 10.4103/0974-2948.71050.
2. Patel S, Kanagasalingam S, et al. Cone beam computed tomography (CBCT) in endodontics. *Dent Update* 2010 Jul–Aug;37(6):373–379. DOI: 10.12968/denu.2010.37.6.373.
3. Uraba S, Ebihara A, et al. Ability of Cone-beam Computed Tomography to Detect Periapical Lesions That Were Not Detected by Periapical Radiography: A Retrospective Assessment According to Tooth Group. *J Endod* 2016 Aug;42(8):1186–1190. DOI: 10.1016/j.joen.2016.04.026.
4. Cohenca N, Shemesh H. Clinical applications of cone beam computed tomography in endodontics: A comprehensive review Part 1: Applications associated with endodontic treatment and diagnosis. *Quintessence Int* 2015;46(6):465–480. DOI: 10.3290/j.qi.a33990.
5. Seltzer S, Bender IB, et al. Incidence and duration of pain following endodontic therapy. Relationship to treatment with sulfonamides and to other factors. *Oral Surg Oral Med Oral Pathol* 1961;14:74–82. DOI: 10.1016/0030-4220(61)90476-5.
6. Seltzer S, Bender IB, et al. Histologic changes in dental pulps of dogs and monkeys following application of pressure, drugs, and microorganisms on prepared cavities. II. Changes observable more than one month after application of traumatic agents. *Oral Surg Oral Med Oral Pathol* 1961;14:856–867. DOI: 10.1016/S0030-4220(61)80016-9.
7. Bender IB. Factors influencing the radiographic appearance of bony lesions. *J Endod* 1982;8(4):161–170. DOI: 10.1016/S0099-2399(82)80212-4.
8. Durack C, Patel S. Cone beam computed tomography in endodontics. *Braz Dent J* 2012;23(3):179–191. DOI: 10.1590/S0103-64402012000300001.
9. Setzer FC, Hinckley N, et al. A Survey of Cone-beam Computed Tomographic Use among Endodontic Practitioners in the United States. *J Endod* 2017 May;43(5):699–704. DOI: 10.1016/j.joen.2016.12.021.

10. American Association of Endodontics; American Academy of Oral and Maxillofacial Radiology. Use of cone-beam computed tomography in endodontics Joint Position Statement of American Association of Endodontics and American Academy of Oral and Maxillofacial Radiology. *Oral Surg Oral Med Oral Pathol Oral Radiol Endod* 2011;111(2):234–237. DOI: 10.1016/j.tripleo.2010.11.012.
11. De Paula-Silva FW, Wu MK, et al. Accuracy of periapical radiography and cone-beam computed tomography scans in diagnosing apical periodontitis using histopathological findings as a gold standard. *J Endod* 2009 Jul;35(7):1009–1012. DOI: 10.1016/j.joen.2009.04.006.
12. Abella F, Patel S, et al. Evaluating the periapical status of teeth with irreversible pulpitis by using cone-beam computed tomography scanning and periapical radiographs. *J Endod* 2012 Dec;38(12):1588–1591. DOI: 10.1016/j.joen.2012.09.003.
13. Aminoshariae A, Kulild JC, et al. Cone-beam Computed Tomography Compared with Intraoral Radiographic Lesions in Endodontic Outcome Studies: A Systematic Review. *J Endod* 2018 Nov;44(11):1626–1631. DOI: 10.1016/j.joen.2018.08.006.
14. Rodríguez G, Patel S, et al. Influence of Cone-beam Computed Tomography on Endodontic Retreatment Strategies among General Dental Practitioners and Endodontists. *J Endod* 2017 Sep;43(9):1433–1437. DOI: 10.1016/j.joen.2017.04.004.
15. Ee J, Fayad MI, et al. Comparison of endodontic diagnosis and treatment planning decisions using cone-beam volumetric tomography vs periapical radiography. *J Endod* 2014 Jul;40(7):910–916. DOI: 10.1016/j.joen.2014.03.002.
16. Karabucak B, Bunes A, et al. Prevalence of Apical Periodontitis in Endodontically Treated Premolars and Molars with Untreated Canal: A Cone-beam Computed Tomography Study. *J Endod* 2016 Apr;42(4):538–541. DOI: 10.1016/j.joen.2015.12.026.
17. Hassan B, Metska ME, et al. Detection of vertical root fractures in endodontically treated teeth by a cone beam computed tomography scan. *J Endod* 2009 May;35(5):719–722. DOI: 10.1016/j.joen.2009.01.022.
18. Schloss T, Sonntag D, et al. A Comparison of 2 and 3-dimensional Healing Assessment after Endodontic Surgery Using Cone-beam Computed Tomographic Volumes or Periapical Radiographs. *J Endod* 43(7):1072–1079. DOI: 10.1016/j.joen.2017.02.007.
19. Patel S, Patel R, et al. The Impact of Different Diagnostic Imaging Modalities on the Evaluation of Root Canal Anatomy and Endodontic Residents' Stress Levels: A Clinical Study. *J Endod* 2019 Apr;45(4):406–413. DOI: 10.1016/j.joen.2018.12.001.
20. Giacomino CM, Ray JJ, et al. Targeted Endodontic Microsurgery: A Novel Approach to Anatomically Challenging Scenarios Using 3-dimensional-printed Guides and Trephine Burs—A Report of 3 Cases. *J Endod* 2018 Apr;44(4):671–677. DOI: 10.1016/j.joen.2017.12.019.
21. McLeod CC, Klabunde CN, et al. Health care provider surveys in the United States, 2000–2010: A review. *Eval Health Prof* 2013;36:106–126. DOI: 10.1177/0163278712474001.
22. Funkhouser E, Vellala K, et al. Supplementing online surveys with a mailed option to reduce bias and improve response rate: The national dental PBRN. *J Pub Health Dent* 2014;74:276–282. DOI: 10.1111/jphd.12054.