

# Comparison of Efficacy of Topical Curcumin Gel with Triamcinolone-hyaluronidase Gel Individually and in Combination in the Treatment of Oral Submucous Fibrosis

Ashish B Lanjekar<sup>1</sup>, Rahul R Bhowate<sup>2</sup>, Suparna Bakhle<sup>3</sup>, Abhay Narayane<sup>4</sup>, Vipul Pawar<sup>5</sup>, Ranjeet Gandagule<sup>6</sup>

## ABSTRACT

**Aim:** To study the efficacy of topical curcumin mucoadhesive semisolid gel, triamcinolone acetonide/hyaluronidase mucoadhesive semisolid gel, and a combination of both in the treatment of oral submucous fibrosis (OSMF).

**Materials and methods:** One hundred and twenty patients diagnosed with OSMF were randomly divided into groups I, II, and III. Each patient in groups I, II, and III was given professionally prepared mucoadhesive semisolid gel of curcumin, a combination of triamcinolone acetonide and hyaluronidase mucoadhesive semisolid gel, and a combination of all three, respectively. Patients were instructed to apply the gel thrice daily for 6 weeks on buccal mucosa bilaterally using the tip of index finger. Three parameters were evaluated at the end of each week, namely, mouth opening, burning on visual analog scale (VAS), and the color of oral mucosa on the binary scale. The results were subjected to statistical analysis.

**Results:** It was observed that the group administered the three drug combinations achieved the greatest mouth opening (mean increase 4.05 mm) as compared to the other two groups. It was observed that triamcinolone and hyaluronidase group reported reduction in burning sensation on VAS (mean difference 6) as compared to the other two groups. It was observed that group III (1% curcumin, 1% hyaluronidase and 0.1% triamcinolone acetonide combined) drug therapy showed better change in mucosa color as compared to groups I (1% curcumin) and II.

**Conclusion:** Thus, we can conclude that curcumin has a therapeutic effect on patients diagnosed with OSMF. Maximum utilization and enhanced drug delivery were achieved with the help of a combination of other two active drugs, namely, triamcinolone and hyaluronidase.

**Clinical significance:** Curcumin role in the treatment of oral cancers and the precancer lesion is very promising.

**Keywords:** Hyaluronidase mucoadhesive semisolid gel, Oral submucous fibrosis, Topical curcumin mucoadhesive semisolid gel, Triamcinolone acetonide mucoadhesive semisolid gel.

*The Journal of Contemporary Dental Practice* (2020): 10.5005/jp-journals-10024-2726

## INTRODUCTION

The tremendous industrialization and urbanization of the 21st century has raised the standard of life in the recent times. However, there has also been a steady increase in stress that a human has to cope. In this scenario, people fall for habits such as gutkha, tobacco, and betel nut chewing are of great relief. They not only are addictive but also can cause debilitating irreversible damage to the oral cavity, one of which is the oral submucous fibrosis (OSMF).

Oral submucous fibrosis is a debilitating condition causing an overall reduction in the quality of life due to its ability to cause problems with speech, swallowing, opening of the mouth as well as the chances of developing into a malignant lesion. In India, the overall prevalence rate of OSMF is estimated to be about 0.2–0.5% and varies from 0.2 to 2.3% in males and 1.2 to 4.57% in females.<sup>1</sup>

The condition is characterized by a burning sensation of the oral mucosa, ulceration, pain, blanching of oral mucosa, reduced movement, depapillation of tongue, depigmentation of oral mucosa, progressive reduction in mouth opening (MO), and scarring of the mucous membrane. The atrophic mucous may often ulcerate subsequently leading to malignancy.<sup>2</sup>

A wide array of treatments both surgical and medicinal has been advocated, which were hypothesized and justified by many researchers and clinicians over decades. Medicinal treatments such as systemic administration of antioxidants, immune milk, interferon- $\gamma$  (IFN- $\gamma$ ) and intralesional injection of enzymes, steroids,

<sup>1</sup>Department of Oral Medicine and Radiology, Swargiya Dadasaheb Kalmegh Smruti Dental College, Nagpur, Maharashtra, India

<sup>2</sup>Department of Oral Medicine and Radiology, Sharad Pawar Dental College, Datta Meghe Institute of Medical Sciences, Wardha, Maharashtra, India

<sup>3</sup>Department of Pharmaceutic, Priyadarshini JL College of Pharmacy, Nagpur, Maharashtra, India

<sup>4</sup>Department of Prosthodontics and Crown and Bridge, Dr Hedgewar Smruti Rugna Seva Mandal Dental College and Hospital, Hingoli, Maharashtra, India

<sup>5</sup>Department of Oral Pathology, Dr Hedgewar Smruti Rugna Seva Mandal Dental College and Hospital, Washim, Maharashtra, India

<sup>6</sup>Department of Prosthodontics, Dr Hedgewar Smruti Rugna Seva Mandal Dental College and Hospital, Hingoli, Maharashtra, India

**Corresponding Author:** Ashish B Lanjekar, Department of Oral Medicine and Radiology, Swargiya Dadasaheb Kalmegh Smruti Dental College, Nagpur, Maharashtra, India, Phone: +91 9595052481, e-mail: Ashishlanjekar2007@gmail.com

**How to cite this article:** Lanjekar AB, Bhowate RR, Bakhle S, *et al.* Comparison of Efficacy of Topical Curcumin Gel with Triamcinolone-hyaluronidase Gel Individually and in Combination in the Treatment of Oral Submucous Fibrosis. *J Contemp Dent Pract* 2020;21(1):83–90.

**Source of support:** Nil

**Conflict of interest:** None

placental extracts, etc., have been attempted in the past, with varying degrees of benefit.<sup>3</sup>

Surgical options such as excision of fibrous bands and replacing with split thickness of skin graft, fresh human placental grafts, pedicle buccal fat, oral stent, coronoidectomy, etc. are currently used in the treatment of OSMF. These options, however, are associated with higher degree of morbidity and inconvincible long-term results. Also it has high recurrence rate and disfigurement.<sup>4</sup>

Even though there are ample options, still there is a dearth of ideal line of management suiting both clinicians and patients, which can ensure safety and predictability. With dentistry turning toward green dentistry in recent decades, naturally derived products have been proposed and being investigated. A wide range of disorders have been treated by the Indian system of holistic medicine known as "Ayurveda," which mainly uses plant-based drugs or formulations. Many chronic diseases when treated with alternate medicine like Ayurveda had good prognosis, which has been well-documented in literature.<sup>3</sup>

Turmeric (common name for *Curcuma longa*) is an Indian spice derived from the rhizomes of the plant and used in Ayurveda medicine to treat inflammatory conditions. The primary active constituent of turmeric "curcumin" was identified in 1910. Curcumin is a pleiotropic molecule that targets molecular mediators of inflammation. It had been widely used in inflammatory bowel disease, pancreatitis, rheumatoid arthritis, etc. with good results. The medicinal activity had been attributed to various pharmacological activities, including antioxidant, antimicrobial, proapoptotic and anti-inflammatory effects. Many researchers have demonstrated the antifibrotic activity of curcumin on human myofibroblasts and suggested that it may be of use in the treatment of OSMF.

Traditionally, a combination of intralesional dexamethasone with hyaluronidase injections has been successfully used for many decades for the treatment of OSMF. Intralesional injections of dexamethasone and hyaluronidase combination yielded significantly better outcomes than using one drug alone.<sup>5</sup>

The aim of the present study is to ascertain the efficacy of topical curcumin gel with triamcinolone and hyaluronidase mucoadhesive semisolid gel individually or in combination in the treatment of OSMF.

## MATERIALS AND METHODS

The present prospective study was conducted in the Department of Oral Medicine and Radiology, Sharad Pawar Dental College and Hospital, Datta Meghe Institute of Medical Sciences (DMIMS), Sawangi (M), Wardha, Maharashtra, India, after obtaining approval from the Institutional Ethics Committee of DMIMS, Deemed to be University (DU). The study population of OSMF was obtained from Swargiya Dadasaheb Kalmegh Smruti Dental College and Hospital, Wanadongri, Nagpur, and Sharad Pawar Dental College and Hospital, DMIMS, Sawangi (M), Wardha, Maharashtra, India, from 2014 to 2017.

Clinically diagnosed OSMF patient, healthy individuals without any systemic diseases, patients who were ready to quit the habit and accept regular follow-up protocol, and patients willing to register for the study with written consent were included in the study. Patients were given freedom to withdraw from study anytime during the course of the study.

Patients who have taken treatment for OSMF in last 6 months, pregnant women, patients whose MO was less than or equal to 10 mm (i.e., stage C), patients with associated premalignant and

malignant lesions, patients with a history of systemic, endocrine, metabolic, and skeletal diseases and other malignancies were excluded from the study.

The study population consisting of 120 patients was divided randomly into three groups, each group consisting of 40 patients each.

- Group I: Mucoadhesive semisolid gel of curcumin
- Group II: A combination of mucoadhesive semisolid gel of triamcinolone acetonide and hyaluronidase.
- Group III: Mucoadhesive semisolid gel of curcumin in addition to triamcinolone and hyaluronidase mucoadhesive semisolid gel.

The clinical and functional staging of OSMF were done based on Haider et al. classification and were classified into functional stages A, B, and C. In stage A, the MO >20 mm, stage B MO 11–19 mm, and stage C MO <10 mm. Stage C patients were excluded from the study as medicinal therapy shows very less effects on these patients.

After obtaining informed consent, detailed case history was recorded. The following parameters were noted.

The intensity of burning sensation was recorded using a numerical rating visual analog scale (VAS). The interincisal MO was measured in millimeter using a digital vernier caliper from the mesioincisal angle of upper central incisor to the mesioincisal angle of lower central incisor. The color of oral mucosa was recorded on VAS, with a rating of 1 for blanching and 2 for pinkish.

These parameters were recorded at an interval of 7 days for 6 weeks.

Patients were encouraged through education, counseling, and advocacy to discontinue the habit and were assisted for habit cessation at every visit till the end of 6th week.

Patients were instructed to perform stretching exercises using ice-cream sticks for 10 minutes, 3–4 times a day in addition to topical medication and warm saline water gargling with ballooning of cheeks two times a day at home.

### Preparation of 1% Curcumin Mucoadhesive Gel

One gram of curcumin crystalline (99.9% pure) powder (procured from Upper India Chemicals, Nagpur) was taken and added to 3 g of corbopol 934 (which was soaked for 24 hours). The mixture was stirred with the help of electronic stirrer. Following which sodium metabisulfite 0.5 g was added to the mixture. One milliliter of triethanolamine and 15 mL of ethanol were added to the mixture and stirred until a uniform consistency is achieved.

### Preparation of 1% Hyaluronidase Mucoadhesive Gel

One gram of hyaluronidase crystalline (99.9 % pure) powder (procured from Uday Pharmacy, Nagpur, India) was taken and added to 3 g corbopol 934 (which was soaked for 24 hours). After properly stirring and mixing, sodium metabisulfite of 0.5 g was added to the mixture. Then 1 mL of triethanolamine with 150 mL of distilled water was added to the mixture and stirred until a uniform consistency is obtained.

### Triamcinolone Acetonide (0.1%) Buccal Paste

This paste was directly procured from Uday Pharmacy, Nagpur. Marketed under the trade name ULCILONE, with 0.1% triamcinolone acetonide buccal paste and it is dispensed in 5 g collapsible tubes.

### Group I

Patients were instructed to apply little (approximately 1 cm in length) 1% curcumin mucoadhesive gel over the lesion on the

affected mucosa 3 times daily for 6 weeks. Patients were advised not to eat or drink for 30 minutes after the application of the curcumin mucoadhesive gel.

**Group II**

Patients were instructed to apply little (approximately 1 cm in length) triamcinolone acetonide and hyaluronidase mucoadhesive semisolid gel with the same frequency and instruction.

**Group III**

Patients were instructed to apply little (approximately 1 cm in length) professionally prepared mucoadhesive semisolid gel of curcumin along with triamcinolone and hyaluronidase mucoadhesive semisolid gel on the affected mucosa with the same frequency and instruction.

Collected data were analyzed by using SPSS 22 statistical package. A repeated-measure ANOVA with Greenhouse–Geisser correlation was applied for increase in MO analysis and Friedman’s non parametric test was applied to evaluate the data for burning sensation and color of oral mucosa.

**RESULTS**

Total of 120 cases were included in the present study. Simple, random allocation method was used to divide the participants into three different groups. One observer was assigned to register all the parameters.

The mean age was 31.5 ± 9.79 years, 29.9 ± 9.87 years, and 27.85 ± 8.23 years, in groups I, II, and III, respectively.

**Mouth Opening**

Kruskal–Wallis test showed a statistically significant difference in interincisal MO between different drug groups,  $\chi^2(2) = 33.041, p < 0.0001$ , with a mean rank of increase in MO of 51.813 for group I, 44.250 for group II, and 85.438 for group III (Table 1).

Post hoc test with Dunn’s multiple comparisons test showed statistically highly significant difference (for increase in MO) in group I vs group III ( $p < 0.001$ ) as well as group II vs group III ( $p < 0.001$ ) (Table 2).

It was observed that the three-drug combinations achieved the highest MO (mean increase 4.05 mm) as compared to the other two groups (Figs 1 to 4).

**Burning Sensation**

Post hoc tests were not done as the  $p$  value was greater than 0.05.

Kruskal–Wallis test showed no statistically significant difference in the reduction of burning sensation on VAS value between

different drug groups,  $\chi^2(2) = 0.8670, p = 0.6482$ , with a mean rank of VAS value of 60.563 for group I, 63.950 for group II, and 56.988 for group III (Table 3).

It was observed that group II showed more reduction in burning sensation on VAS (mean difference 6) as compared to groups I and III (Fig. 5).

**Color of Oral Mucosa**

A statistically significant difference was observed between groups as determined by one-way ANOVA ( $F(2,117) = 8.705, p = 0.000$ ). A Bonferroni post hoc test revealed that the change in color of mucosa was statistically significantly higher with group III ( $0.68 \pm 0.47$ ) compared to groups I ( $0.38 \pm 0.49, p = 0.015$ ) and II ( $0.25 \pm 0.44, p = 0.000$ ). No statistically significant difference was observed between groups I and II ( $p = 0.705$ ) (Table 4).

Hence, it was observed that group III drug therapy showed better change in color of mucosa as compared to groups I and II (Figs 6 to 9).

**DISCUSSION**

Even though diversified treatment modalities have been proposed and practiced for the management of OSMF, there is no unison in management protocol of this debilitating condition. Invasive surgical procedures aimed at increasing MO, and noninvasive regimen included vitamin A or B supplements as well as steroids. Other methods include injection of placental extract, use of trypsin, collagenase, hyaluronidase, elastase, and intralesional IFN- $\gamma$ . Oral zinc has been used, as also oral pentoxifylline and lycopene, with varying benefits.<sup>6,7</sup>

Compliance of patients is poor owing to the extended treatment regimen which leads to compromised result. Thus, to clinically overcome such problem in patients with OSMF, the two forms of mucoadhesive gels were used to evaluate its efficacy, namely, curcumin mucoadhesive semisolid gels and triamcinolone acetonide/hyaluronidase mucoadhesive semisolid gels.

In the present study, we tried to overcome the drawbacks of invasive therapy with local application of active drug. We also tried an innovative active component of turmeric (a rhizome of *Curcuma longa*) curcumin 1% mucoadhesive gel for the treatment of OSMF.

In present study subjects were chosen based on the widely accepted definition of OSMF which was proposed by Pindborg and Sirsat in 1966. The disease is exclusively reported in Indian population and in South East Asia, but cases were reported worldwide such as in Kenya, China, UK, Saudi Arabia and other parts of the world where Asians have migrated and are migrating.<sup>8</sup>

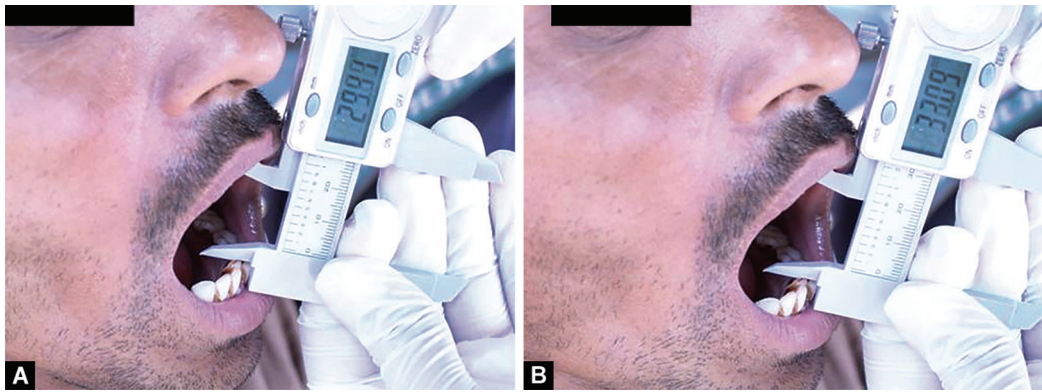
**Table 1:** Increase in mouth opening at the end of 6th week in different groups was compared using Kruskal–Wallis test (nonparametric ANOVA)

Groups	N	Mean difference	Sum of ranks	Mean of ranks	p value	Sig.
Group I	40	2.90	2072.5	51.813	<0.0001	Highly significant
Group II	40	2.55	1770.0	44.250		
Group III	40	4.05	3417.5	85.438		

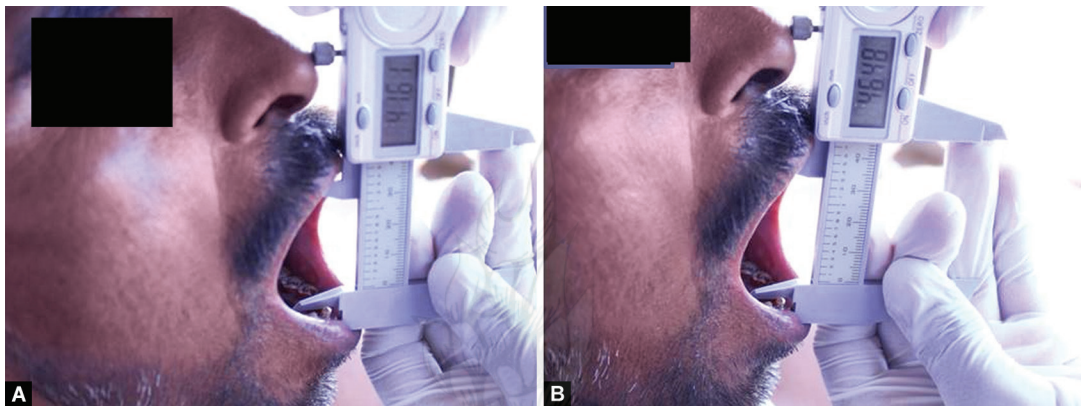
**Table 2:** Post hoc test with Dunn’s multiple comparison test

Groups	Mean rank difference	p Value	Sig.
Group I vs group II	7.563	>0.05	Not significant
Group I vs group III	–33.625	<0.001	Highly significant
Group II vs group III	–41.188	<0.001	Highly significant





Figs 1A and B: Pretreatment and posttreatment mouth opening in group I



Figs 2A and B: Pretreatment and posttreatment mouth opening in group II

In present study, the ratio of male and female was 39:1, i.e., 97.4% were males, which is more as compared to other studies, namely, the one carried out by Nanavati et al. in the state of Gujarat where the ratio was 23.28:1. This could be due to higher incidence of betel nut chewing habit in males in central India as compared to females.<sup>9</sup>

Our findings was not in agreement with the study carried out by Maher et al., showing female preponderance. This might be due to the difference in geographic locations and habits prevalent in those areas.<sup>10</sup>

### Mouth Opening

The present study showed high statistically significant difference (for increase in MO) between groups I and III ( $p < 0.001$ ) as well as groups II and III ( $p < 0.001$ ).

One percent curcumin mucoadhesive gel showed clinical improvement in MO, i.e., from  $27.7 \pm 4.01$  mm in 1st week to  $30.63 \pm 3.9$  mm at the end of 6th week. Findings of the present study are in accordance with the study conducted by Rai et al., Das et al., Yadav et al., and Saran et al.<sup>11-14</sup>

The reduced efficacy of oral curcumin alone is because of the rapid metabolism of curcumin into its less effective conjugate forms of curcumin glucuronides and curcumin sulfates or alternately reduced to hexahydrocurcumin.<sup>15</sup> However, the anti-inflammatory, antioxidant, anticarcinogenic, immunomodulatory, and antifibrotic properties of curcumin are responsible for the improvement in clinical signs and symptoms and, thus, may be responsible for reducing the malignant changes in OSF.<sup>16</sup>

It was observed that the three-drug combinations (group III) achieved the highest MO (mean increase 4.05 mm) when compared to other two groups (groups I and II).

This could be explained as, in addition to the abovementioned properties of curcumin, hyaluronidase degrades the hyaluronic acid matrix, lowers the thickness of intracellular cemental substances as well as activates definite plasmatic mechanisms. This forms the basis of the observation, and that is why a combination of curcumin, triamcinolone acetate and hyaluronidase shows better results.<sup>17</sup>

In the present study, hyaluronidase and triamcinolone elicited only slight increase in MO from pretreatment to 1 week; however, after the 6th week, MO had increased significantly ( $p < 0.001$ ). Obtained results are in accordance with the study conducted by Singh et al. who reported significant increase in MO by using a combination of triamcinolone acetate (10 mg/mL) and hyaluronidase (1,500 IU) submucosally.<sup>18</sup>

Similar results were also documented by Panigrahi et al., which showed a significant increase in MO at the end of 6 and 4 months, respectively.<sup>19</sup>

As in the present study, both the gels (curcumin and triamcinolone acetate) were used in combination, with the penetrating property of hyaluronidase, which has been helpful for deeper delivery of curcumin and triamcinolone into the affected mucosa in such a way that the combined effects of both gels brought the desired results in OSF patients. Thus, antioxidant, anticarcinogenic, immunomodulatory, antifibrotic and anti-inflammatory properties of both drugs (curcumin and



Figs 3A and B: Pretreatment and posttreatment mouth opening in group III

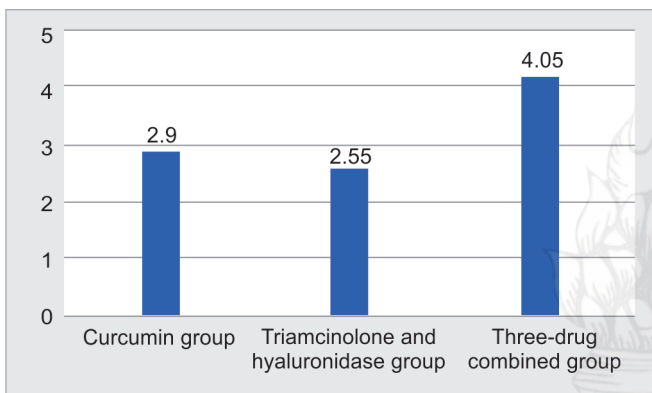


Fig. 4: Mean increase in mouth opening at the end of treatment

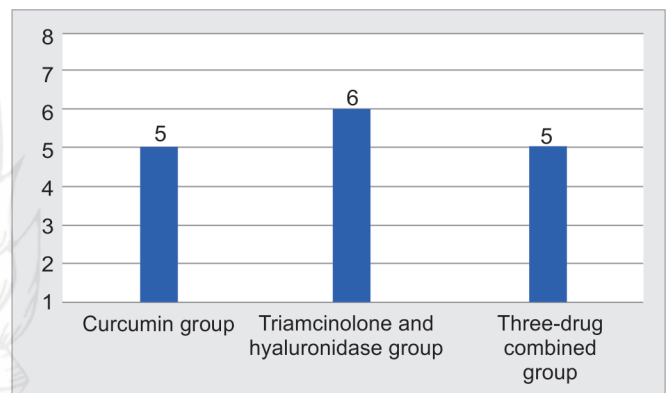


Fig. 5: Median of reduction in visual analog scale values at the end of treatment

Table 3: Reduction in burning sensation at the end of 6th week in different groups was compared using Kruskal–Wallis test (nonparametric ANOVA)

Groups	N	Mean difference	Sum of ranks	Mean of ranks	p value	Sig.
Group I	40	5	2422.5	60.563	0.6482	Not significant
Group II	40	6	2558.0	63.950		
Group III	40	5	2279.5	56.988		

ANOVA, analysis of variance

triamcinolone) are responsible for improvement in clinical signs and symptoms of OSF. In addition to this, topical drug delivery is an attractive route for drug delivery.

### Burning Sensation

The present study showed no statistically significant difference in the reduction of burning sensation on VAS value between different drug groups. It was observed that group II (triamcinolone and hyaluronidase) showed more reduction in burning sensation on VAS (mean difference 6) as compared to the other two groups, but the difference was not statistically significant.

Findings in the present study were in accordance with the study conducted by Sharma et al., Virani et al., Hazarey et al. and also concluded that topical application of turmeric oil reduces the burning sensation on VAS.<sup>20–22</sup>

In the present study, the reduction in burning sensation happened in 2 weeks, as we used topical mucoadhesive gels that have better penetrability and high local drug concentration. So an early biological effect of the drug can be seen.

Maximum reduction in burning sensation was seen in group II as triamcinolone acetonide binds to specific cytosolic glucocorticoid receptors and subsequently interacts with glucocorticoid receptor response element on DNA and alters gene expression. This results in an induction of the synthesis of certain anti-inflammatory proteins while inhibiting the synthesis of certain inflammatory mediators. Consequently, an overall reduction in chronic inflammation and autoimmune reactions is accomplished.

The reduction in burning sensation by curcumin is due to its anti-inflammatory property as well as the scavenging effect on superoxide radicals. Turmeric acts by increasing the number



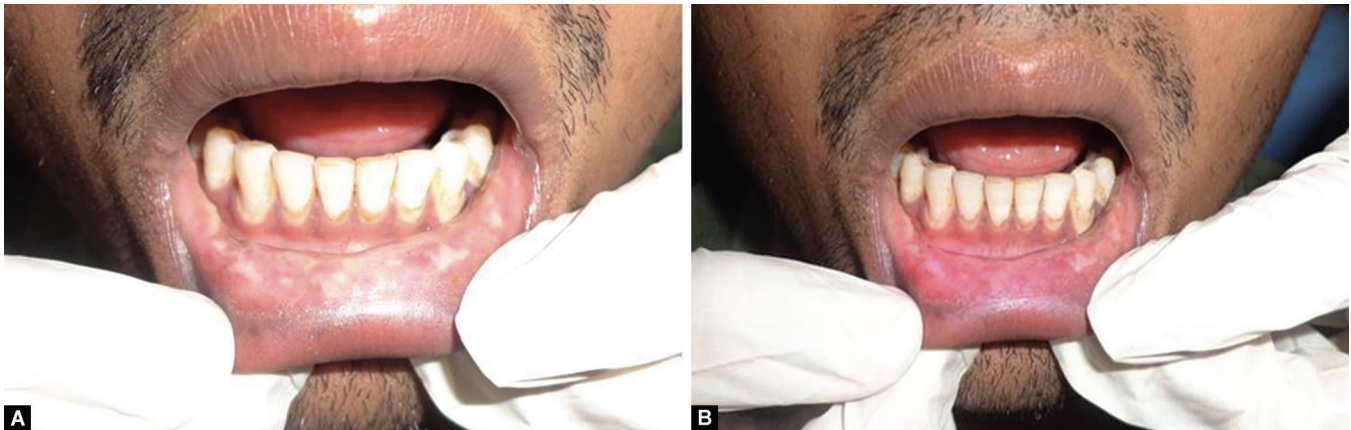
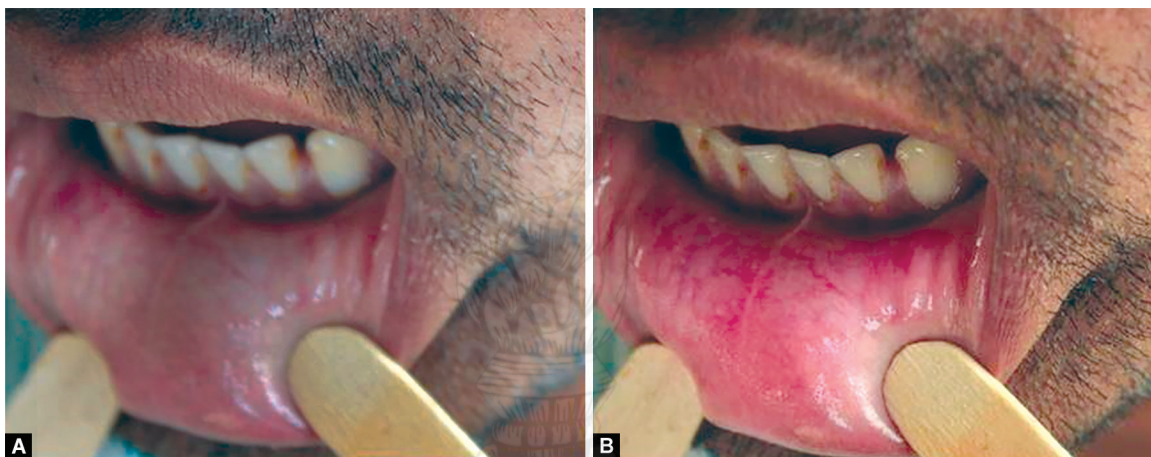

Fig 6A and B: Pretreatment and posttreatment change of color of oral mucosa in group I



Figs 7A and B: Pretreatment and posttreatment change of color of oral mucosa in group II

Table 4: Mean change in color of mucosa between all three groups

Groups	N	Mean	Std deviation
Group I	40	0.25	0.439
Group II	40	0.38	0.490
Group III	40	0.68	0.474

of micro nuclei in the circulating lymphocytes and by being an excellent scavenger of free radicals that reduce juxtaepithelial inflammation, thus reducing the burning of oral mucosa.<sup>23</sup>

As far as literature search goes, we did not come across any article related to the negative results of curcumin on MO and visual analog score for burning in OSMF.

### Color of Oral Mucosa

In the present study, statistically significant change in color of oral mucosa from blanched to pinkish was observed in the curcumin group at the end of 6th week. Literature search revealed only one study by Das et al. which was conducted on OSMF patients and its findings are in accordance with the present study and also explained that the change in color is due to the increase in vascularity.<sup>12,19,24</sup>

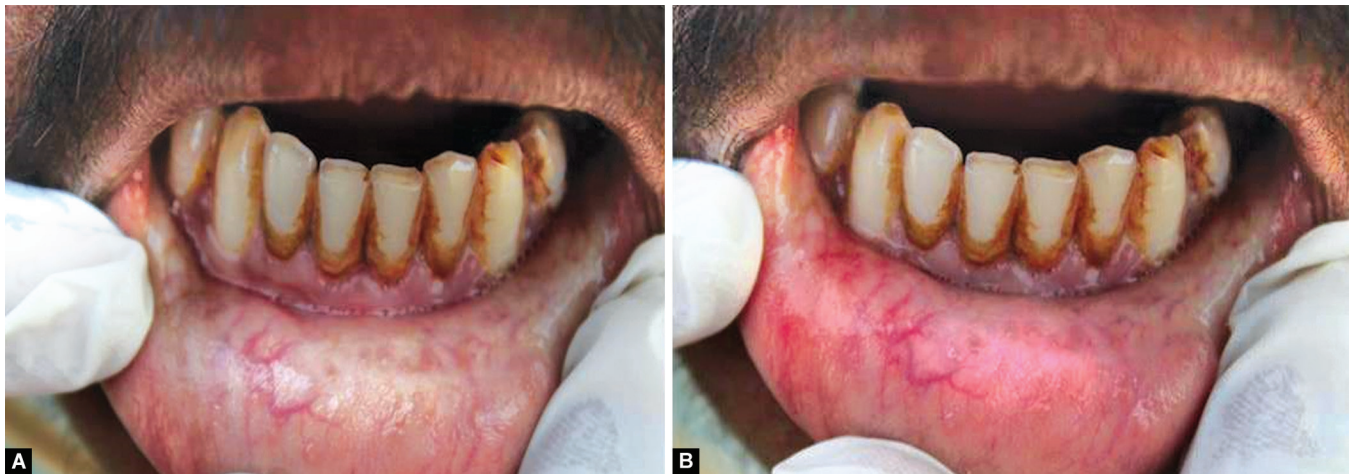
Extensive literature search showed that none of the studies in literature used topical hyaluronidase in the treatment of OSMF.

Present study revealed that the change in color of mucosa was statistically significantly higher in group III ( $0.68 \pm 0.47$ ) compared to groups I ( $0.38 \pm 0.49$ ,  $p = 0.015$ ) and II ( $0.25 \pm 0.44$ ,  $p = 0.000$ ). No statistically significant difference was observed between groups I and II ( $p = 0.705$ ).

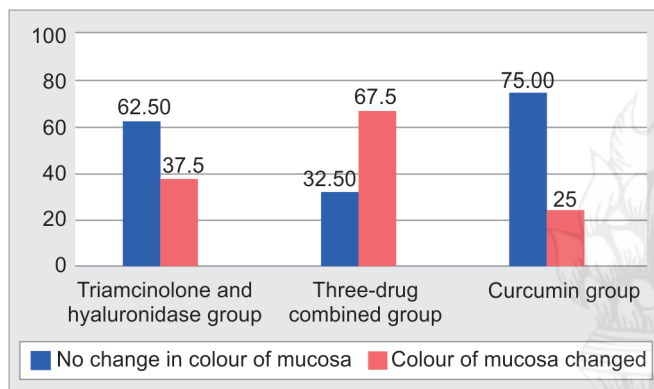
Maximum improvement was seen in group III due to the fact that curcumin has fibrinolytic and anti-inflammatory action. This may be due to the synergistic effect of the three drugs combined, and also curcumin has a fibrinolytic property due to its ability to inhibit lipid peroxidation and check cellular proliferation, reducing the rate of collagen synthesis,<sup>25</sup> which effectively decreases fibrosis, thereby changing the color of mucosa from blanched to pinkish.

### CONCLUSION

Thus, it is concluded that curcumin has a therapeutic effect in patients diagnosed with OSMF. Curcumin is considered a safe, nontoxic, and effective alternative for many conventional drugs due to its distinguished therapeutic properties and multiple effects on various systems of the body. Its role in the treatment of oral cancers and precancer lesion is very promising. It can be used alone or in combination with other conventional drugs for the treatment of



**Figs 8A and B:** Pretreatment and posttreatment change of color of oral mucosa in group III



**Fig. 9:** Percentage of cases with/without change in color of mucosa at the end of treatment

OSMF. Its topical use on affected sites in OSMF patients also proved safe, noninvasive, and effective treatment modalities in improving MO, reducing burning sensation, and changing the color of oral mucosa. No adverse effects of topical application of either gel were reported during the interventional period. This study also highlights the importance of multidrug regime especially including natural derivatives that help to reduce the dosage, in better and faster outcomes, and decrease the side effects of conventional therapy alone. In the present study, maximum utilization and enhanced drug delivery was achieved with the help of combining two other active drugs, namely, triamcinolone and hyaluronidase.

The present study does not consider subgroups based on the stages of OSMF, which should have been studied for more precise and stage-oriented results. Also patients were followed only for 6 weeks, which could have been extended for more duration. As far as sample size is concerned, it is optimum, but further studies should be conducted on larger sample size.

## REFERENCES

- Lambade P, Dawane P, Thorat P. Oral submucous fibrosis—a treatment protocol based on clinical study of 100 patients in central india. *Oral Maxillofac Surg* 2015;19(2):201–207. DOI: 10.1007/s10006-014-0478-x.
- Burde K. Oral submucous fibrosis-an overview. *Int J Dent Res Dev* 2014;4:1–6.
- Dayanarayana U. Non surgical approaches in treatment of OSF. *IOSR J Dent Med Sci* 2014;13(11):63–69. DOI: 10.9790/0853-131136369.
- Borle RM, Borle SR. Management of oral submucous fibrosis: a conservative approach. *J Oral Maxillofac Surg* 1991;49(8):788–791. DOI: 10.1016/0278-2391(91)90002-4.
- Gupta D, Sharma SC. Oral submucous fibrosis-a new treatment regimen. *J Oral Maxillofac Surg* 1988;46(10):830–833. DOI: 10.1016/0278-2391(88)90043-2.
- Kakar PK, Puri RK. Oral submucous fibrosis—treatment with hyalase. *J Laryngol Otol* 1985;99(1):57–59. DOI: 10.1017/S0022215100096286.
- Lai DR, Chen HR, Lin LM, et al. Clinical evaluation of different treatment methods for oral submucous fibrosis. A 10-year experience with 150 cases. *J Oral Pathol Med* 1995;24(9):402–407. DOI: 10.1111/j.1600-0714.1995.tb01209.x.
- Angadi PV, Rekha KP. Oral submucous fibrosis: a clinicopathologic 122 review of 205 cases in indians. *Oral Maxillofac Surg* 2011;15(1):15–19. DOI: 10.1007/s10006-010-0225-x.
- Nanavati S, Nanavati P, Nanavati M. Clinico-pathological study of 170 cases of oral sub-mucous fibrosis. *Int J Sci Study* 2015;3(9):137–144. DOI: 10.17354/ijss/2015/572.
- Maher R, Lee AJ, Warnakulasuriya KA, et al. Role of areca nut in the causation of oral submucous fibrosis: a case-control study in Pakistan. *J Oral Pathol Med* 1994;23(2):65–69. DOI: 10.1111/j.1600-0714.1994.tb00258.x.
- Rai B, Kaur J, Jacobs R, et al. Possible action mechanism for curcumin in pre-cancerous lesions based on serum and salivary markers of oxidative stress. *J Oral Sci* 2010;52(2):251–256. DOI: 10.2334/josnusd.52.251.
- Das AD, Balan A, KT S. Comparative study of the Efficacy of curcumin and turmeric oil as chemopreventive agents in oral submucous fibrosis: a clinical and histopathological evaluation. *J Indian Acad Oral Med Radiol* 2012;22(2):88–92. DOI: 10.5005/jp-journals-10011-1021.
- Yadav M, Aravinda K, Saxena VS, et al. Comparison of curcumin with intralesional steroid 119 injections in oral submucous fibrosis - A randomized, open-label interventional study. *J Oral Biol Craniofacial Res* 2014;4(3):169–173. DOI: 10.1016/j.jobcr.2014.11.003.
- Saran G, Umopathy D, Misra N, et al. Efficacy of lycopene and curcumin in oral submucous fibrosis patients. *Indian J Dent Res* 2018;29:303–312. DOI: 10.4103/ijdr.IJDR\_551\_16.
- Krishnaswamy K. Turmeric - A potential anti-cancer agent. *Amala Res Bull* 1998;18:23–28.
- Bar-Sela G, Epelbaum R, Schaffer M. Curcumin as an anti-cancer agent: review of the gap between basic and clinical applications. *Curr Med Chem* 2009;17(3):190–197. DOI: 10.2174/092986710790149738.

17. Cavallini M, Gazzola R, Metalla M., et al. The role of hyaluronidase in the treatment of complications from hyaluronic acid dermal fillers. *Aesthetic Surg J* 2013;33(8):1167–1174. DOI: 10.1177/1090820X13511970.
18. Singh M, Niranjana HS, Mehrotra R, et al. Efficacy of hydrocortisone acetate/hyaluronidase vs triamcinolone acetonide/hyaluronidase in the treatment of oral submucous fibrosis. *Indian J Med Res* 2010;131:665–669.
19. Panigrahi R, Maheshwari A. A prospective, randomized double blind study comparing intralesional triamcinolone acetonide and hyaluronidase combination versus triamcinolone acetonide alone in the treatment of oral submucosal fibrosis. *J Pharm Biomed Sci* 2014;04(04):365–370.
20. Sharma M, Kaur M, Dar MS. Efficacy of turmeric in reducing burning sensation in oral submucous fibrosis: an observational study. *Saudi J Oral Dent Res* 2017;2(11):271–274.
21. Virani D, Dangore S, Bhowate R. Assessment of utility of tulsi and turmeric in treatment of oral submucous fibrosis: a clinical study. *Int J Dent Res* 2018;3(1):30–33. DOI: 10.31254/dentistry.2018.3108.
22. Hazarey VK, Sakrikar AR, Ganvir SM. Efficacy of curcumin in the treatment for oral submucous fibrosis a randomized clinical trial. *J oral Maxillofac Pathol* 2015;19(2):145–153. DOI: 10.4103/0973-029X.164524.
23. Meshram M, Bhowate RR, Madke B, et al. Evaluation of the effect of ultrasound physiotherapy interventions in combination with local application of aloe-vera and turmeric gel in the management of oral submucous fibrosis. *J Dent Investig* 2018;1:16–33.
24. Elizabeth N, Gurumani S, Ganesh Bala A, et al. A comparative study between management of oral submucous fibrosis. *J Evol Med Dent Sci* 2015;3(47):11344–11348. DOI: 10.14260/jemds/2014/3484.
25. Sharma S, Pawar S, Jain UK. Development and evaluation of topical gel of curcumin from different combination of polymers formulation and evaluation of herbal gel. *Int J Pharm Pharm Sci* 2012;4(4): 452–456.

