

# Effectiveness of Artificial Intelligence Applications Designed for Endodontic Diagnosis, Decision-making, and Prediction of Prognosis: A Systematic Review

Nezar Boreak

## ABSTRACT

**Aim:** With advancements in science and technology, there has been phenomenal developments in the application of neural networks in dentistry. This systematic review aimed to report on the effectiveness of artificial intelligence (AI) applications designed for endodontic diagnosis, decision-making, and prediction of prognosis.

**Materials and methods:** Studies reporting on AI applications in endodontics were identified from the electronic databases such as PubMed, Medline, Embase, Cochrane, Google Scholar, Scopus, and Web of Science, for original research articles published from January 1, 2000, to June 1, 2020. A total of 10 studies that met our eligibility criteria were further analyzed for qualitative data. QUADAS-2 was applied for synthesis of the quality of the studies included.

**Results:** A wide range of AI applications have been implemented in endodontics. The neural networks employed were mostly based on convolutional neural networks (CNNs) and artificial neural networks (ANNs) in their neural architectures. These AI models have been used for locating apical foramen, retreatment predictions, prediction of periapical pathologies, detection and diagnosis of vertical root fractures, and assessment of root morphologies.

**Conclusion:** These studies suggest that the neural networks performed similar to the experienced professionals in terms of accuracy and precision. In some studies, these models have even outperformed the specialists.

**Clinical significance:** These models can be of greater assistance as an expert opinion for less experienced and nonspecialists.

**Keywords:** Artificial intelligence, Artificial neural networks, Convolutional neural networks, Deep learning models, Endodontic diagnosis, Endodontic prognosis, Machine learning.

*The Journal of Contemporary Dental Practice* (2020): 10.5005/jp-journals-10024-2894

## INTRODUCTION

The goal of endodontic treatment is to provide best quality treatment with an intention to retain the tooth in its functional state and to prevent any further complications. In the recent years, there have been tremendous advancements in the endodontic diagnosis, instrumentation designs, materials, and treatment procedures that mainly intend to achieve successful endodontic care.

To increase the clinical ease, efficiency, and performance of the clinician, it is very much essential to have a best clinical picture of the endodontic disease and therapy. Even with the availability of the various treatment modalities, epidemiological surveys have reported that the success rate is only 60–85% for the endodontic treatment in general practice.<sup>1,2</sup>

In order to achieve the best results, accuracy in the diagnosis and clinical decision-making is utmost important. With the advancements in the science and technology, there have been several diagnostics tools and treatment modalities that have provided new vistas in diagnosis, clinical decision-making, and planning a best therapy for endodontic diseases.

Artificial intelligence (AI) is a newer technology that has been widely used in applied in dentistry. Artificial intelligence technology is mainly composed of a neural network architecture similar to the human brains and which intern mimics the human thinking.<sup>3</sup> This neural architecture pattern is made up of neurons that have strong interconnections, which mainly operate as a data-processing systems to solve a specific problem.<sup>4</sup> With advancements in science

---

Department of Restorative Dental Sciences, College of Dentistry, Jazan University, Jazan, Kingdom of Saudi Arabia

**Corresponding Author:** Nezar Boreak, Department of Restorative Dental Sciences, College of Dentistry, Jazan University, Jazan, Kingdom of Saudi Arabia, Phone: +966 599016688, e-mail: nezarboreak@gmail.com

**How to cite this article:** Boreak N. Effectiveness of Artificial Intelligence Applications Designed for Endodontic Diagnosis, Decision-making, and Prediction of Prognosis: A Systematic Review. *J Contemp Dent Pract* 2020;21(8):926–934.

**Source of support:** Nil

**Conflict of interest:** None

---

and technology, there has been phenomenal developments in the application of neural networks in dentistry. Artificial intelligence technologies have been applied in dentistry mainly for diagnosis of dental diseases,<sup>5–8</sup> treatment planning, clinical decision-making,<sup>7–10</sup> and prediction its prognosis.<sup>11</sup>

These AI-based applications applied for the various tasks have displayed to be efficient in their performance. The authors have also reported that these models are reliable, and their performance is equivalent to that of the trained experts. Several studies have also reported on the application of this newer concept for the diagnosis and treatment planning of endodontic diseases. Hence, this systematic review aimed to report on the effectiveness of

AI applications designed for endodontic diagnosis, decision-making, and predicting the prognosis.

## MATERIALS AND METHODS

### Information Sources and Search Strategy

This systematic review was performed after implying the guidelines for Preferred Reporting Items for Systematic Reviews and Meta-Analyses extension for Diagnostic Test Accuracy (PRISMA-DTA).<sup>12</sup> Studies reporting on AI applications in endodontics were identified from the electronic databases such as PubMed, Medline, Embase, Cochrane, Google Scholar, Scopus, and Web of Science, for original research articles published from January 1, 2000, to June 1, 2020. A combination of index words like artificial intelligence; endodontic diagnosis; endodontic prognosis; machine learning; deep learning models; convolutional neural networks; and artificial neural networks were used in the search strategy. The search strategy was related to the PICO (problem/patient/population, intervention, comparison, and outcome) elements (Table 1).

At the preliminary search, the articles were retrieved pertaining to the title and abstract. Electronic databases were the main source followed by the hand searching of the articles in the scientific journals. The preliminary search yielded us 828 articles that were related to our topic of interest. Due to duplication of the data, 188 articles were eliminated, following which 640 articles were considered for the next stage, after which the following eligibility criteria's were applied.

### Eligibility Criteria

#### Inclusion Criteria

The article must have reported in the application of the AI model; some measurable or predictive values and data sets used for the evaluation of the model should be clearly mentioned.

#### Exclusion Criteria

Unpublished papers uploaded online, articles with only abstracts with no full text, and papers that were not in English.

### Study Selection

Fourteen articles qualified the eligibility criteria. The authors' identity and the article details were undisclosed before giving for

critical analysis among the panel members which was made up by four members: SP, SB, SK, AK. The authors followed the guidelines set by QUADAS-2 (Quality Assessment and Diagnostic Accuracy Tool), a standard tool implied for quality evaluation.<sup>13</sup> There was a disagreement among the authors for inclusion of 4 articles, and henceforth they were excluded. A total of 10 articles were finally considered for the quality synthesis (Flowchart 1).

## RESULTS

### Search Results

A total of 10 articles were assessed for the qualitative data in this systematic review. The trend shows that these studies were conducted in the last 8 years.

### Qualitative Synthesis

Studies reported on the application of AI in endodontics have mainly focused on applying the AI technology for determining the working length,<sup>14</sup> locating apical foramen,<sup>15</sup> retreatment predictions,<sup>16</sup> prediction of periapical pathologies,<sup>17-19</sup> detection and diagnosis of vertical root fractures,<sup>20,21</sup> and assessment of root morphologies<sup>22,23</sup> (Fig. 1).

The neural architecture of most models reported in these studies were based on ANNs<sup>14,15,17</sup> and CNNs.<sup>18,19,21-23</sup> One study reported of using paraconsistent artificial neural network (PANNs)<sup>20</sup> and Bayesian neural network (BNN).<sup>16</sup> These models assessed intraoral periapical radiographs,<sup>14-16</sup> CBCT images,<sup>20,22</sup> photographs,<sup>17</sup> and panoramic radiographs (OPGs)<sup>18,21</sup> (Table 2).

### Risk of Bias Assessment and Applicability Concerns

Risk of bias assessment and applicability concern were evaluated using QUADAS-2, which is designed for the studies evaluating diagnostic accuracy. Patient selection for both the domains showed low risk of bias in majority of the studies (risk of bias: 80%; applicability arm: 60%). However, cadaver samples (Sanghiri et al.) and extracted teeth (Sanghiri et al. and Johari et al.) were used in three studies and hence were regarded as high-risk bias in patient selection domain of applicability arm of the tool. Testing and validation were not carried out in a study by Mahmoud et al., and hence patient selection, reference test, and flow and timing were interpreted as unclear in both the arms of QUADAS-2. Human observations were used as reference standard in 5 studies, and hence 50% of studies observed high risk in bias assessment and applicability concern. All the studies have used highly standardized system of AI for training purpose, and hence index test was regarded as low risk in both the arms of QUADAS-2. The details of the risk of bias assessment and applicability concern of the included studies are mentioned in the Supplementary Tables 1 and 2 (Figs 2 and 3).

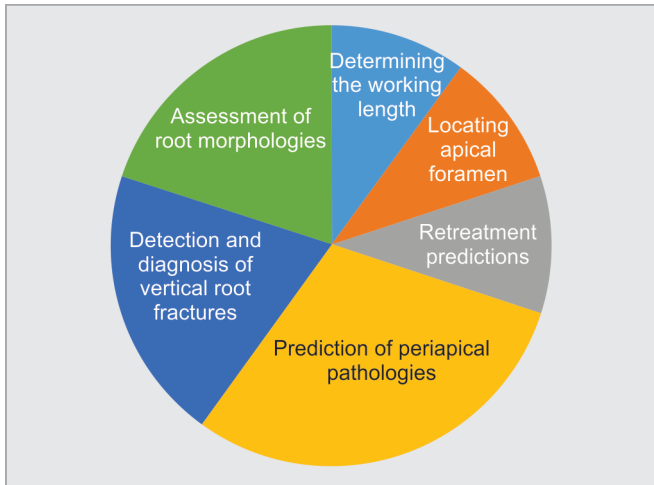
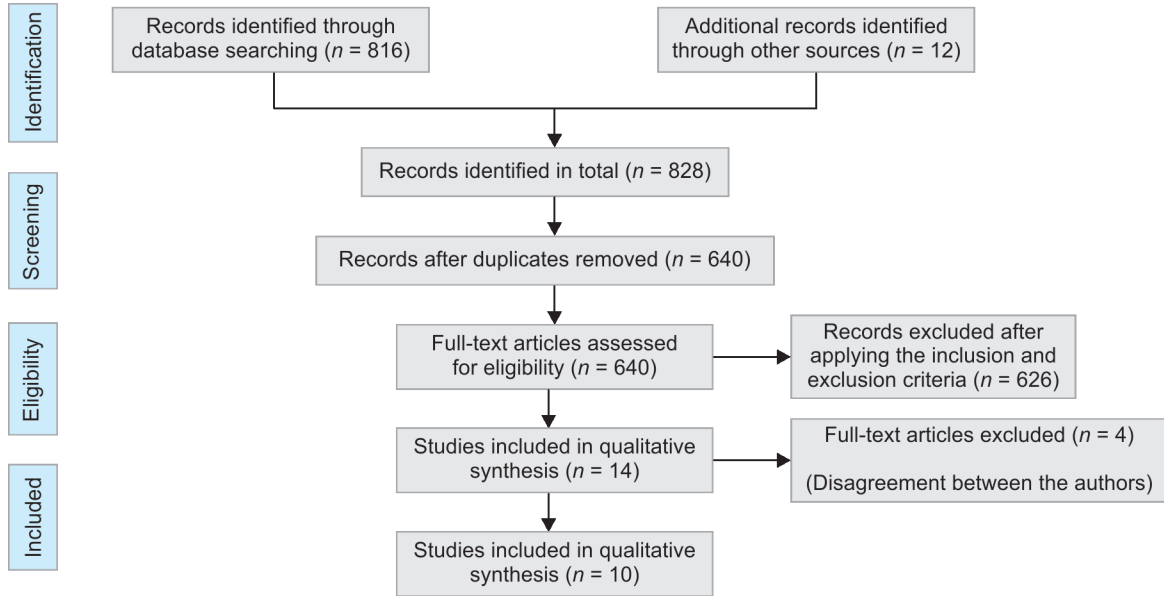
## DISCUSSION

The success in the endodontic treatment is based on many factors such as, exact diagnosis, clinical decision-making, treatment procedures, and postendodontic care. Dentists widely rely on the conventional radiographic techniques for diagnosis and treatment planning of the periapical pathologies.<sup>24</sup> With the advancements in technology, newer technologies such as artificial intelligence have been introduced in healthcare sectors for various purposes. Lately, they have also been introduced in dentistry for assisting in diagnosis, decision-making, assessing the need for treatment, treatment planning, and predicting of prognosis.

**Table 1:** Description of the PICO (P = population, I = intervention, C = comparison, O = outcome) elements

Research question	What is the effectiveness of artificial intelligence (AI) applications in endodontic diagnosis, decision-making and predicting the prognosis?
Population	Patients diagnostic images/radiographs related to teeth and surrounding structures (clinical images, radiographs, CBCT images)
Intervention	AI based models for diagnosis, clinical decision-making, and predicting the prognosis
Comparison	Expert opinions, reference standards
Outcome	Measurable or predictive outcomes such as accuracy, sensitivity, specificity, ROC = receiver operating characteristic curve, AUC = area under the curve, ICC = intraclass correlation coefficient, positive/negative predictive values (PPV/NPV), F-measure

**Flowchart 1:** Flowchart for screening and selection of articles



**Fig. 1:** Application of artificial intelligence (AI) in endodontics

This systematic review was planned to report on the effectiveness of AI applications in endodontic diagnosis, decision-making, and predicting the prognosis.

**AI for Working Length Determination**<sup>14,15</sup>

Determining a correct working length is a crucial step for a successful endodontic treatment. There are several techniques that have been widely adopted for locating the apical foramen and for determining the working length, which mainly includes radiographic methods, paper point method, and digital tactile sensation.<sup>25</sup> Radiographic methods are the most widely used techniques.<sup>26,27</sup> Recently, electronic apex locators and cone-beam computed tomography (CBCT) have been used as new adjuncts for locating the apical foramen.<sup>28,29</sup> A study reported on AI-based model being applied for determining the working length on single-rooted teeth on the dry skull. ANNs demonstrated excellent results with 93% of accuracy.<sup>14</sup> Similar results were reported in another article, where the authors evaluated the accuracy of ANNs in determining the working length on a human cadaver model. The AI-based model

demonstrated an accuracy of 96%, and these results were even better than the experienced endodontists who demonstrated 76% accuracy.<sup>15</sup> These results are suggestive that these AI-based models are very efficient in determining the apical foramen and working length. These models can be of great assistance for less experienced dentists and nonspecialists as these AI models can be used in clinical application when there is no availability of specialists.

**AI for Prediction of Periapical Pathologies**<sup>17,20,23</sup>

A dentist needs to gather all the necessary information to make a probable diagnosis for which he has to be very precise in recording the case history, performing a thorough clinical examination along with radiographic evaluation, and then confirm the diagnosis. Clinical and radiographic evaluations are sometimes nonconclusive. So it is very much important to have a reliable tool that can help a dentist in making correct decisions and proper planning of the treatment. Artificial intelligence technology is widely used in the diagnosis of periapical pathologies. A study reported on the application of AI-based CNN model for radiographic detection of periapical lesions. The model demonstrated quite satisfactory results, with high sensitivity and moderate specificity. This model could be of great use for assisting dentists in diagnosing and detecting periapical lesions.<sup>18</sup> Another study reported on application of AI model for detecting periapical lesions on CBCT images. The reliability of the model in detecting the periapical pathologies was quite amazing with a reliability of 92%. This model can be of greater assistance in clinical practice.<sup>23</sup> Another study reported on application of an AI based model for predicting the presence of a periapical lesion. The results were quite surprising, and authors reported that this model was not better than the reference standard, and the authors mentioned that the results could be enhanced in the future work using optimization technique.<sup>17</sup>

**AI for Detection and Diagnosis of Vertical Root Fractures**<sup>20,21</sup>

Vertical root fractures (VRFs) are quite rare events that we come across in the endodontically treated teeth. Studies have reported that the incidence of VRFs is 3.7–30.8% in the teeth that have



**Table 2:** Details of the studies that have used AI-based applications for endodontic diagnosis, decision-making and predicting the prognosis

Serial no.	Authors	Year of publication	Algorithm Architecture	Objective of the study	No. of images/ photographs for testing	Study factor	Modality	Evaluation accuracy/ average accuracy	Comparison if any	Results, (+) effective, (-) non-effective, (N) neutral	Outcomes	Authors suggestions/ recommendations
1	Saghiri et al. <sup>14</sup>	2012	ANNs	ANN-based AI model for determining the working length	50	Tooth	Periapical radiographs	Accuracy of 96% confidence interval 90.57-101.43	2 Endodontists using stereomicroscope	(+) Effective	The accuracy of ANN was more than the endodontists	The ANN model is an accurate method for working length determination
2	Saghiri et al. <sup>15</sup>	2012	ANNs	ANN system for locating the minor apical foramen (AF)	50	Tooth	Periapical radiographs	Accuracy of 93%	Not mentioned	(+) Effective	ANN can be useful for secondary opinion for locating the AF on radiographs and it can be helpful in enhancing the accuracy in determining the working length	ANN can be used for decision-making for similar clinical scenarios
3	Campo et al. <sup>16</sup>	2015	BNNs	Bayesian networks for predicting the need for performing a retreatment	205	Tooth	Periapical radiographs	Mean AUC was 0.87	12 Classifiers	(+) Effective	The proposed system with Bayesian networks was tested in a real environment and the results obtained are promising.	The system can reduce the number of unsuccessful retreatments as it predicts the rate of success or failure.
4	Mahmoud et al. <sup>17</sup>	2015	ANNs	AI based model for predicting whether the patient has teeth periapical lesion or not	229	Lesions	Radiographs were photo copied	Mean accuracy of 77.2%	Non-parametric algorithm K-Nearest Neighbor Classifier	(-) non effective	The K-Nearest Neighbor Classifier is better than Feed Forward Neural Network according to the results	Future work should concentrate on enhancing the results using optimization technique

Contd...

Contd...

Serial no.	Authors	Year of publication	Algorithm Architecture	Objective of the study	No. of images/ photographs for testing	Study factor	Modality	Evaluation accuracy/ average accuracy	Comparison if any	Results, (+) effective, (-) non-effective, (N) neutral	Outcomes	Authors suggestions/ recommendations
5	Johari et al. <sup>20</sup>	2017	PNNs	Probabilistic neural network (PNN) for diagnosing (VRFs) in intact and endodontically treated teeth	240	Tooth	CBCT and periapical radiographs	Accuracy of 96.6, sensitivity of 93.3 and specificity of 100%	Not mentioned	(+) Effective	The designed neural network can be used as a proper model for the diagnosis of VRFs on CBCT images of endodontically treated and intact teeth; CBCT images were more effective than periapical radiographs	None
6	Hatvani et al. <sup>22</sup>	2018	CNNs	To investigate the use of CNNs for resolution enhancement of 2-D CBCT dental images, using CT data of the same teeth as ground truth	1824 slices	Tooth morphology	CBCT-images	Peak signal-to-noise ratio, structure similarity index	Reconstruction-based super-resolution methods	(+) Effective	The results suggest the superiority of the proposed CNN-based approaches over reconstruction-based methods	Further progress could be achieved by implementing networks with 3-D inputs
7	Ekert et al. <sup>18</sup>	2019	CNNs	CNNs for detecting apical lesions (ALs) on panoramic dental radiographs	160	Apical lesions	Panoramic Radiographs	AUC of 0.85, Sensitivity of 0.65, specificity of 0.87, PPV was 0.49 (0.10), and NPV was 0.93	Not mentioned	(+) Effective	A moderately deep CNN showed satisfying discriminatory ability to detect ALs on panoramic radiographs	None
8	Fukuda et al. <sup>21</sup>	2019	CNNs	To evaluate the use of convolutional neural network (CNN) system for detecting vertical root fracture (VRF) on panoramic radiography	60	Tooth	Panoramic Radiographs	Recall was 0.75, precision 0.93, and F measure 0.83	2 radiologists and 1 endodontist	(+) Effective	The CNN learning model has shown promising results in detecting VRFs on panoramic images	None

Contd...



Contd...

Serial no.	Authors	Year of publication	Algorithm Architecture	Objective of the study	No. of images/photographs for testing	Study factor	Modality	Evaluation accuracy/average accuracy	Comparison if any	Results, (+) effective, (-) non-effective, (N) neutral	Outcomes	Authors suggestions/recommendations
9	Hiraiwa et al. <sup>23</sup>	2019	CNNs	CNNs for classification of the root morphology of mandibular first molars on panoramic radiographs	760	Tooth	CBCT images	Accuracy of 86.9%	Reference models	(+) Effective	CNN model showed high accuracy in the differential diagnosis of a single or extra root in the distal roots of mandibular first molars	None
10	Orhan et al. <sup>19</sup>	2020	CNNs	CNNs to detect periapical pathosis on cone-beam computed tomography (CBCT) images	153	Periapical lesions	CBCT images	Reliability of 92.8%	1 human observer	(+) Effective	The performance of humans and by AI systems were comparable to each other	AI method can be useful for detecting periapical pathosis on CBCT images for clinical application.

ANNs, artificial neural networks; CNNs, convolutional neural networks; DCNNs, deep convolutional neural networks; BN, Bayesian network; PNN, probabilistic neural network; AUC, area under the curve; ICC, intraclass correlation coefficient; F, F-measure, PPV/NPV, positive/negative predictive values

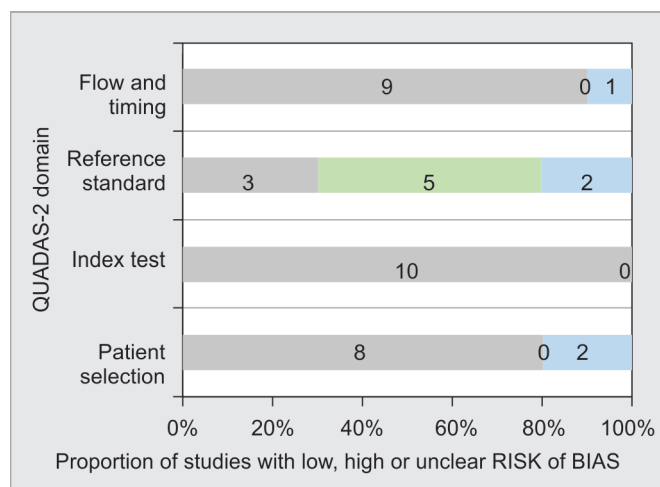


Fig. 2: Assessment of individual risk of bias domains

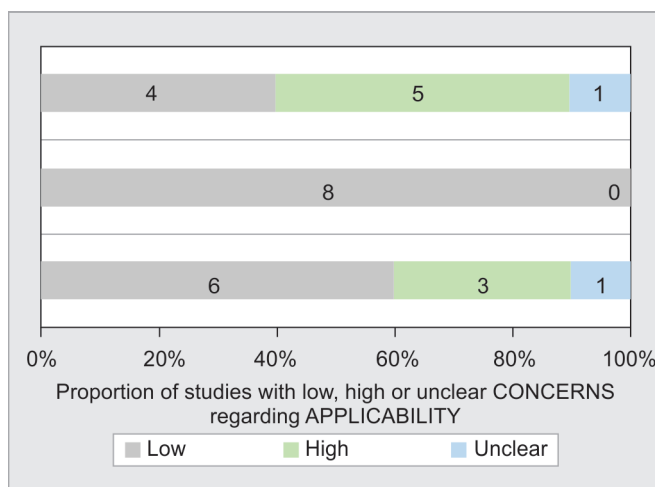


Fig. 3: Concerns regarding applicability

undergone endodontic treatment.<sup>30</sup> It is very much important to detect these root fractures at an initial stage in order to prevent damage to its supporting structures.<sup>31</sup> Most of the times, the VRFs go unnoticed, as they show only slight symptoms and most of the time with no symptoms.<sup>32</sup> A study reported on the application of AI-based model with a PNN architecture for the diagnosing the VRFs on the intact and the teeth that has undergone endodontic treatment, when applied on periapical radiographs and CBCT images. The model proved to be very efficient in diagnosing the VRFs on CBCT images in comparison to periapical radiographs.<sup>20</sup> A similar study reported application of CNNs for detecting VRFs on OPGs. The results were also quite promising, which suggests the accuracy and performance of these models in detecting VRFs is very promising and can be widely applied in clinical practice.

### AI for Assessment of Root Morphologies<sup>22,23</sup>

To achieve a successful endodontic treatment, a dentist needs to have a thorough knowledge of the root canal anatomy.<sup>33</sup> An untreated canal that might have been overlooked could lead to microbial colonization and ultimately result in the failure of the endodontic treatment.<sup>34,35</sup> Considering these things, it is a prerequisite for a dentist to have a thorough knowledge and to have an efficient diagnostic tool for identifying the root morphologies. A study reported of CNN-based AI model applied to identify the root morphologies on CBCT images. The model demonstrated superior quality results.<sup>22</sup> Similar results were reported in another study, where the authors reported on application of AI-based model for classifying the root morphologies on panoramic radiographs. The model performed exceptionally well with a higher accuracy.<sup>22</sup> These models can be used as a clinical diagnostic aid for accurate diagnosis in order to prevent eventful situations.

The major limitations of this review are that most of the reports mentioned here are based on experimental data sets, and there is a need for more explorative research in real-life scenarios. Few studies have used very few data sets for the experimentation, like the one used for determining VRFs used only single rooted teeth, where there is a need to determine the performance on multirouted teeth as well.

### CONCLUSION

Artificial intelligence technology has been widely applied in endodontics. The studies reported on the application of AI in

endodontics suggest that the neural networks performed similar to the experts with better accuracy and precision. In some studies, these models have even outperformed the specialists. Out of the 10 studies reported, only 1 study reported that the model did not match the performance of the reference standard. The studies stated that these applications can be of greater assistance as an expert opinion for less experienced and non-specialists.

### REFERENCES

- Ng Y-L, Mann V, Rahbaran S, et al. Outcome of primary root canal treatment: systematic review of the literature—part 1. Effects of study characteristics on probability of success. *Int Endodontic J* 2007;40(12):921–939. DOI: 10.1111/j.1365-2591.2007.01322.x.
- Eriksen HM, Kirkevang L-L, Petersson K. Endodontic epidemiology and treatment outcome: general considerations. *Endodontic Topics* 2002;2(1):1–9. DOI: 10.1034/j.1601-1546.2002.20101.x.
- Brickley MR, Shepherd JP, Armstrong RA. Neural networks: a new technique for development of decision support systems in dentistry. *J Dent* 1998;26(4):305–309. DOI: 10.1016/S0300-5712(97)00027-4.
- Tripathy M, Maheshwari RP, Verma HK. Power transformer differential protection based on optimal probabilistic neural network. *IEEE Trans Power Del* 2010;25:102–112. DOI: 10.1109/TPWRD.2009.2028800.
- Lee JH, Kim DH, Jeong SN, et al. Detection and diagnosis of dental caries using a deep learning-based convolutional neural network algorithm. *J Dent* 2018;77:106–111. DOI: 10.1016/j.jdent.2018.07.015.
- Lee JH, Kim DH, Jeong SN, et al. Diagnosis and prediction of periodontally compromised teeth using a deep learning-based convolutional neural network algorithm. *J Periodontal Implant Sci* 2018;48(2):114–123. DOI: 10.5051/jpis.2018.48.2.114.
- Casalegno F, Newton T, Daher R, et al. Caries detection with near-infrared transillumination using deep learning. *J Dent Res* 2019;98:1227–1233. DOI: 10.1177/0022034519871884.
- Kise Y, Ikeda H, Fujii T, et al. Preliminary study on the application of deep learning system to diagnosis of Sjögren’s syndrome on CT images. *Dentomaxillofac Radiol* 2019;48(6):20190019. DOI: 10.1259/dmfr.20190019.
- Zhang W, Li J, Li Z, et al. Predicting postoperative facial swelling following impacted mandibular third molars extraction by using artificial neural networks evaluation. *Sci Rep* 2018;8(1):12281. DOI: 10.1038/s41598-018-29934-1.
- Choi HI, Jung SK, Baek SH, et al. Artificial intelligent model with neural network machine learning for the diagnosis of orthognathic surgery. *J Craniofac Surg* 2019;30(7):1986–1989. DOI: 10.1097/SCS.0000000000005650.



11. Patcas R, Timofte R, Volokitin A, et al. Facial attractiveness of cleft patients: a direct comparison between artificial-intelligence-based scoring and conventional rater groups. *Eur J Orthod* 2019;41(4):428–433. DOI: 10.1093/ejo/cjz007.
12. McGrath TA, Alabousi M, Skidmore B, et al. Recommendations for reporting of systematic reviews and meta-analyses of diagnostic test accuracy: a systematic review. *Syst Rev* 2017;6(1):194. DOI: 10.1186/s13643-017-0590-8.
13. Whiting PF, Rutjes AWS, Westwood ME, et al. QUADAS-2: a revised tool for the quality assessment of diagnostic accuracy studies. *Ann Intern Med* 2011;155(8):529–536. DOI: 10.7326/0003-4819-155-8-201110180-00009.
14. Saghiri MA, Garcia-Godoy F, Gutmann JL, et al. The reliability of artificial neural network in locating minor apical foramen: a cadaver study. *J Endod* 2012;38(8):1130–1134. DOI: 10.1016/j.joen.2012.05.004.
15. Saghiri MA, Asgar K, Boukani KK, et al. A new approach for locating the minor apical foramen using an artificial neural network. *Int Endod J* 2012;45(3):257–265. DOI: 10.1111/j.1365-2591.2011.01970.x.
16. Campo L, Aliaga IJ, De Paz JF, et al. Retreatment predictions in odontology by means of CBR systems. *Comput Intell Neurosci* 2016;2016:7485250. DOI: 10.1155/2016/7485250.
17. Mahmoud YE, Labib SS, Hoda MO, Mokhtar Clinical Prediction of Teeth Periapical Lesion based on Machine Learning Techniques – An Experimental Study. Proceedings of Second International Conference on Digital Information Processing, Data Mining, and Wireless Communications (DIPDMWC2015), Dubai, UAE, 2015.
18. Ekert T, Krois J, Meinhold L, et al. Deep learning for the radiographic detection of apical lesions. *J Endod* 2019;45(7):917–922.e5. DOI: 10.1016/j.joen.2019.03.016.
19. Orhan K, Bayrakdar IS, Ezhov M, et al. Evaluation of artificial intelligence for detecting periapical pathosis on cone-beam computed tomography scans. *Int Endod J* 2020;53(5):680–689. DOI: 10.1111/iej.13265.
20. Johari M, Esmaili F, Andalib A, et al. Detection of vertical root fractures in intact and endodontically treated premolar teeth by designing a probabilistic neural network: an ex vivo study. *Dentomaxillofac Radiol* 2017;46(2):20160107. DOI: 10.1259/dmfr.20160107.
21. Fukuda M, Inamoto K, Shibata N, et al. Evaluation of an artificial intelligence system for detecting vertical root fracture on panoramic radiography. *Oral Radiol* 2019. DOI: 10.1007/s11282-019-00409-x.
22. Hatvani J, Andras H, Jérôme M, et al. Deep learning-based super-resolution applied to dental computed tomography. *IEEE Trans Rad Plasma Med Sci* 2019;3(2):120–128. DOI: 10.1109/TRPMS.2018.2827239. ISSN 2469-7311.
23. Hiraiwa T, Arijji Y, Fukuda M, et al. A deep-learning artificial intelligence system for assessment of root morphology of the mandibular first molar on panoramic radiography. *Dentomaxillofac Radiol* 2019;48(3):20180218. DOI: 10.1259/dmfr.20180218.
24. Caputo BV, Noro Filho GA, de Andrade Salgado DM, et al. Evaluation of the root canal morphology of molars by using cone-beam computed tomography in a Brazilian population: part I. *J Endod* 2016;42(11):1604–1607. DOI: 10.1016/j.joen.2016.07.026.
25. Seidberg B, Alibrandi B, Fine H, et al. Clinical investigation of measuring working lengths of root canals with an electronic device and with digital-tactile sense. *J Am Dent Assoc* 1975;90(2):379–387. DOI: 10.14219/jada.archive.1975.0059.
26. Powell-Cullingford AW, Pitt Ford TR. The use of E-speed film for root canal length determination. *Int Endod J* 1993;26(5):268–272. DOI: 10.1111/j.1365-2591.1993.tb00571.x.
27. Gutmann JL, Leonard JE. Problem solving in endodontic working-length determination. *Compend Contin Educ Dent* 1995;16(3):288–290.
28. Gordon MP, Chandler NP. Electronic apex locators. *Int Endod J* 2004;37(7):425–437. DOI: 10.1111/j.1365-2591.2004.00835.x.
29. Janner SF, Jeger FB, Lussi A, et al. Precision of endodontic working length measurements: a pilot investigation comparing cone-beam computed tomography scanning with standard measurement techniques. *J Endod* 2011;37(8):1046–1051. DOI: 10.1016/j.joen.2011.05.005.
30. Llana-Puy MC, Forner-Navarro L, Barbero-Navarro I. Vertical root fracture in endodontically treated teeth: a review of 25 cases. *Oral Surg Oral Med Oral Pathol Oral Radiol Endod* 2001;92(5):553–555. DOI: 10.1067/moe.2001.117262.
31. Mora MA, Mol A, Tyndall DA, et al. *In vitro* assessment of local computed tomography for the detection of longitudinal tooth fractures. *Oral Surg Oral Med Oral Pathol Oral Radiol Endod* 2007;103(6):825–829. DOI: 10.1016/j.tripleo.2006.09.009.
32. Tsesis I, Rosen E, Tamse A, et al. Diagnosis of vertical root fractures in endodontically treated teeth based on clinical and radiographic indices: a systematic review. *J Endod* 2010;36(9):1455–1458. DOI: 10.1016/j.joen.2010.05.003.
33. Felsypremila G, Vinothkumar TS, Kandaswamy D. Anatomic symmetry of root and root canal morphology of posterior teeth in indian subpopulation using cone beam computed tomography: a retrospective study. *Eur J Dent* 2015;9(4):500–507. DOI: 10.4103/1305-7456.172623.
34. Celikten B, Tufenkci P, Aksoy U, et al. Cone beam CT evaluation of mandibular molar root canal morphology in a Turkish cypriot population. *Clin Oral Investig* 2016;20(8):2221–2226. DOI: 10.1007/s00784-016-1742-2.
35. Zhang X, Xiong S, Ma Y, et al. A Conebeam computed tomographic study on mandibular first molars in a Chinese subpopulation. *PLoS One* 2015;10(8):e0134919. DOI: 10.1371/journal.pone.0134919.



**Supplementary Table 1:** Quality assessment (QUADAS 2) summary of risk of bias

	<i>Patient selection</i>	<i>Index test</i>	<i>Reference standard</i>	<i>Flow and timing</i>
Saghiri et al.	Low	Low	High	Low
Saghiri et al.	Low	Low	High	Low
Campo et al.	Low	Low	Low	Low
Mahmoud et al.	Unclear	Low	Unclear	Unclear
Johari et al.	Unclear	Low	Low	Low
Hatvani et al.	Low	Low	Unclear	Low
Ekert et al.	Low	Low	High	Low
Fukuda et al.	Low	Low	High	Low
Hiraiwa et al.	Low	Low	Low	Low
Orhan et al.	Low	Low	High	Low

**Supplementary Table 2:** Applicability concerns

	<i>Patient selection</i>	<i>Index test</i>	<i>Reference standard</i>
Saghiri et al.	High	Low	High
Saghiri et al.	High	Low	High
Campo et al.	Low	Low	Low
Mahmoud et al.	Unclear	Low	Unclear
Johari et al.	High	Low	Low
Hatvani et al.	Low	Low	Low
Ekert et al.	Low	Low	High
Fukuda et al.	Low	Low	High
Hiraiwa et al.	Low	Low	Low
Orhan et al.	Low	Low	High