

Assessment of Clinical and Radiographic Success Rate of Formocresol-based Pulpotomy versus Collagen-based Pulpotomy: An *In Vivo* Study

Vasanthakumari Anandan¹, Jaiganesh Inbanathan², Parthiban Saket³, Vivek Krishnamoorthy⁴, Shanmugavadivel Gandhi⁵, Vignesh Krishnapillai Chandrababu⁶

ABSTRACT

Aim: The aim of the study is (a) To use collagen as a pulpotomy material in comparison with the gold standard formocresol-based pulpotomy, (b) to assess the clinical and radiographic success rate of formocresol pulpotomy and collagen-based pulpotomy, and (c) to compare the success rate of formocresol-based pulpotomy and collagen-based pulpotomy over a definitive interval of time.

Materials and methods: Totally 30 primary first or second molars indicated for pulpotomy after confirming with the operative diagnosis were taken as samples for this study. This split-mouth technique consists of two groups: Group 1—formocresol pulpotomy ($n = 15$), and group 2—collagen-based pulpotomy ($n = 15$). Both the procedures were done in the same patient on regular appointments. Pre- and postoperative radiographs were taken. The children were recalled for clinical and radiographic follow-up at 2, 4, and 6 months. The success of the procedure was assessed based on clinical signs (pain, tenderness to percussion, abscess, swelling, fistula, and pathologic mobility) and radiographic findings (radicular radiolucency, internal and external root resorption, periodontal ligament (PDL) space widening, and furcation radiolucency). The Chi-square test was used to compare the differences between the groups.

Result: The overall success rate for formocresol pulpotomy ($n = 15$) was 14, 13, and 10 for the second-, fourth-, and sixth-month review period, respectively. For collagen pulpotomy group ($n = 15$), the overall success rate was 14, 14, and 14 for the second-, fourth-, and sixth-month review period, respectively. The obtained data from the overall success rate were subjected to statistical analysis, and chi-square test was used. The p -value less than 0.1 was considered a statistically significant result. The chi-square value for the fourth- and sixth-month review was 0.37 and 3.33, respectively.

Conclusion: Statistically significant value was obtained from the sixth-month review period ($p < 0.1$), which describes that the overall success rate was better for the collagen pulpotomy group when compared with the formocresol pulpotomy group.

Clinical significance: Collagen had proven to be a very good alternative for formocresol, its biocompatibility, and regenerative efficiency and is a benchmark for a better clinical success rate in dentistry. However, its implication in pulpotomy should be subjected to further comparative research study on mineral trioxide aggregate (MTA), Biodentine, etc.

Keywords: Collagen-based pulpotomy, Formocresol-based pulpotomy.

The Journal of Contemporary Dental Practice (2021): 10.5005/jp-journals-10024-3117

INTRODUCTION

Dental management in children not only restores their oral health but also installs a positive attitude in children toward dentistry. This entity solely depends on the success rate of the treatment rendered to a child, which puts a pediatric dentist to stand in the foremost position to select the most appropriate procedure and novel materials to accomplish the same.

Pediatric dental management is strictly time-dependent. So, before selecting a management protocol, all other factors like dental age, chronological age, growth, development, etc., should be taken into account.

Dental caries have a higher prevalence rate in children, especially in mixed dentition period due to their diet pattern change or lack in maintaining proper oral hygiene. In the case of dental caries with pulpal involvement, preserving the natural tooth by pulp therapy until its time of exfoliation is a vital aim in pediatric dental management, as they are said to be the most best space maintainers.

Among different pulp therapy strategies, vital pulpotomy is the topic of interest in this study. By definition, a pulpotomy is defined

^{1,2,4}Department of Pediatric and Preventive Dentistry, Adhiparasakthi Dental College and Hospital, Kanchipuram, Tamil Nadu, India

³Department of Periodontics, Adhiparasakthi Dental College and Hospital, Kanchipuram, Tamil Nadu, India

⁵Department of Pediatric and Preventive Dentistry, Sri Venkateshwaraa Dental College and Hospital, Ariyur, Puducherry, India

⁶Department of Pediatric and Preventive Dentistry, Sri Ramachandra Dental College and Hospital, Chennai, Tamil Nadu, India

Corresponding Author: Jaiganesh Inbanathan, Department of Pediatric and Preventive Dentistry, Adhiparasakthi Dental College and Hospital, Kanchipuram, Tamil Nadu, India

Phone: +91 8939292685, e-mail: jai131399@gmail.com

How to cite this article: Anandan V, Inbanathan J, Saket P, *et al.* Assessment of Clinical and Radiographic Success Rate of Formocresol-based Pulpotomy versus Collagen-based Pulpotomy: An *In Vivo* Study. *J Contemp Dent Pract* 2021;22(6):680–685.

Source of support: Nil

Conflict of interest: None

as partial removal of the pulp (coronal portion) and leaving radicular pulp intact, after establishing effective hemostasis restoration with biocompatible materials.

Collagen, a protein that is present abundantly in humans in the extracellular matrix and is an important component of connective tissues, performs multiple functions, including wound management.¹ It creates a conducive environment for wound healing by the deposition and organization of freshly formed fibers and granulation tissues in the wound bed.²

Collagen-based membranes are being widely used in periodontal and implant therapy as scaffolds for preventing the migration of epithelial cells and for encouraging wound repopulation by cells with high regenerative potential.³ Collagen, which is available for dental implication, is already sterilized and also reinforced with antibiotic particles to efficiently aid in regeneration and repair without any contaminations. The collagen particles can be sterilized by various methods like irradiation, dry heat, and ethylene oxide, among which irradiation is the most frequently used method as it does not affect the structural stability.⁴

Enamel and dentin consist of collagen as one of its composition in their organic ground matrix. So, in this study, collagen is used as the hemostatic and lining agent in pulpotomy when compared to the gold standard formocresol-based pulpotomy. The mechanism of formocresol in pulpotomy is the fixation of the radicular pulp, whereas collagen will aid in wound healing as well as repair as per the hypothesis.

The aim of the study is (a) To use collagen as a pulpotomy material in comparison with the gold standard formocresol-based pulpotomy, (b) to assess the clinical and radiographic success rate of formocresol pulpotomy and collagen-based pulpotomy, and (c) to compare the success rate of formocresol-based pulpotomy and collagen-based pulpotomy over a definitive interval of time.

MATERIALS AND METHODS

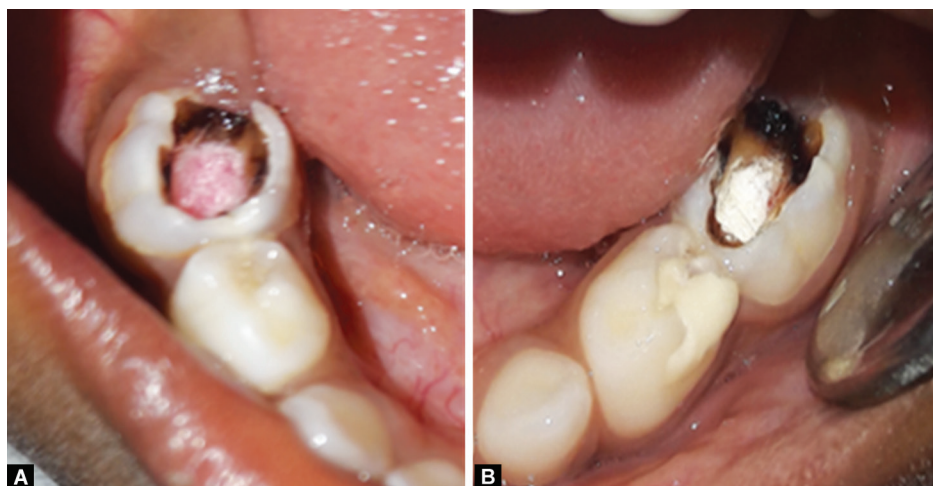
The source of samples for the study is from the children who visited the Department of Pediatric and Preventive Dentistry, Adhiparasakthi Dental College and Hospital. The children were first diagnosed, and candidates eligible for the study were selected. After obtaining the informed consent form, the patient or the guardian of the children was added to the group. The inclusion criteria included age between 4 and 8 years, primary molar tooth

not more than one-third of root resorption, and children with bilateral deep dental caries approximating the pulp in primary molars assessed both clinically and radiographically. Exclusion criteria include children with medical, physical, or mental conditions and primary molars with any congenital deformities. Totally 30 primary first or second molars indicated for pulpotomy after confirming with the operative diagnosis were taken as samples for this study. This split-mouth technique consists of two groups: Group 1—formocresol pulpotomy ($n = 15$), and group 2—collagen-based pulpotomy ($n = 15$). Both the procedures were done in the same patient on regular appointments.

According to the group classified, the treatment protocol was carried out. After administration of local anesthesia (2% xylocaine with adrenaline), the teeth were isolated with Opra Dam, Ivoclar, Germany. The soft carious lesions were first excavated using a spoon excavator, followed by which access opening was performed using a no-330 high-speed bur with the aerator. Following the initial drop into the pulp chamber, the tooth was reassured by operative diagnosis by analyzing the nature of the pulpal bleeding. If the nature of bleeding is cyanotic instead of inflammatory, then the teeth were dismissed for pulpectomy and were eliminated from the study. Satisfying the operatory diagnosis, the treatment was continued, the pulp chamber was completely deroofed, the coronal portion of the pulp was excised leaving behind the intact untouched radicular pulp, and finally, irrigation was done with saline to remove the dentinal debris. A cotton pellet dipped with saline was placed over the root canal orifice, and minimal pressure was applied to attain hemostasis, followed by which formocresol pulpotomy and collagen-based pulpotomy were carried in their respective groups.

For formocresol-based pulpotomy, a cotton soaked with Buckley's formocresol was placed over the amputated radicular pulp area over the root canal orifice for 15 minutes (Fig. 1A), and upon removal of the cotton pellet, a dark brown layer of fixation can be appreciated. Over this, a freshly prepared zinc oxide eugenol (ZOE) paste was placed, and access cavity restoration was done using glass ionomer cement (GIC) type II.

For collagen-based pulpotomy, the radicular pulp was covered with BioFil-AB Collagen Particles, Eucare Pharmaceuticals (Fig. 1B). Amalgam carrier was used to carry and transport the collagen particles to the prepared tooth from the sterile vials, followed by which ZOE and GIC type II cements were given as per standard



Figs 1A and B: Clinical procedure in formocresol pulpotomy (A) and collagen pulpotomy (B)

protocol. Most of the pulpectomized teeth in both the groups were given postendodontic restoration using 3M ESPE stainless steel crowns. Both the groups were subjected to periodic clinical and radiographic assessments. The criteria used for assessing the clinical success were based on the presence or absence of the clinical signs like pain, tenderness to percussion, abscess, swelling, fistula, and pathologic mobility. The radiographic success was assessed based on the presence or absence of radiographical findings like radicular radiolucency, internal and external root resorption, periodontal ligament (PDL) space widening, and furcation radiolucency.

Statistical Analysis

The chi-square test was used to compare the differences between the groups. All the statistical analyses were performed with the SPSS software version 15.0.

RESULTS

Clinical assessment of pain, tender on percussion, abscess, swelling, fistula, and mobility in the formocresol pulpotomy group and

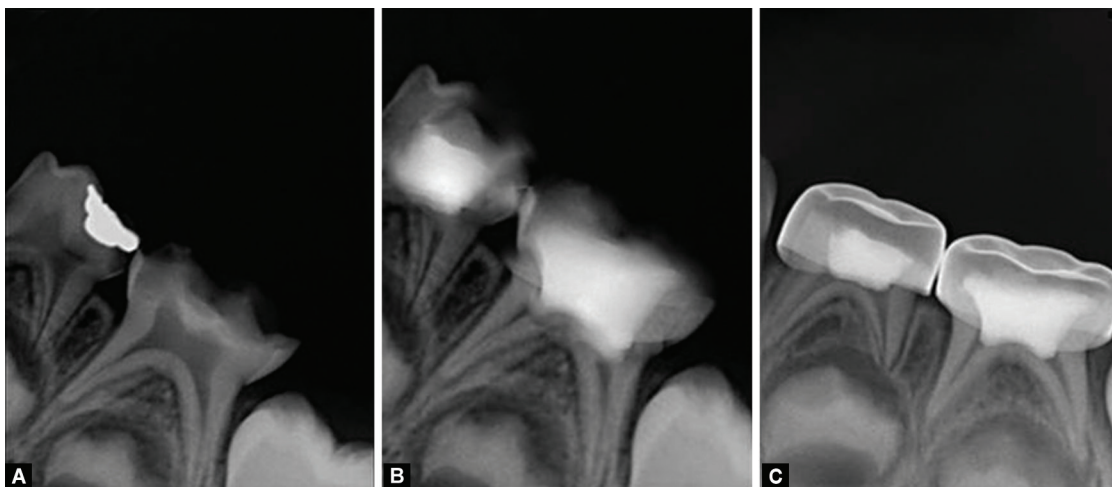
collagen pulpotomy group at two-, four-, and six-month intervals revealed no much clinical findings upon the regular recall periods, except pain was present in the patient belonging to collagen-based pulpotomy group (group 2) at second-month recall and in the patient belonging to formocresol pulpotomy group (group 2) at the sixth-month recall. Mobility was appreciated in the sixth-month review in formocresol pulpotomy group (Table 1).

Radiographical assessment of inter-radicular radiolucency, external and internal resorption, widening of PDL, and furcation radiolucency was checked through intraoral periapical (IOPA) radiographs at regular recall and review period of 2nd, 4th, and 6th month (Fig. 2 and 3). No much radiographical changes and findings were appreciated during the second- and fourth-month recall period, except for the inter-radicular radiolucency present in both the groups at this period. However, inter-radicular radiolucency, internal resorption, and widening of PDL were present in the IOPAs (Fig. 4) from formocresol pulpotomy group at the sixth-month interval review (Table 2).

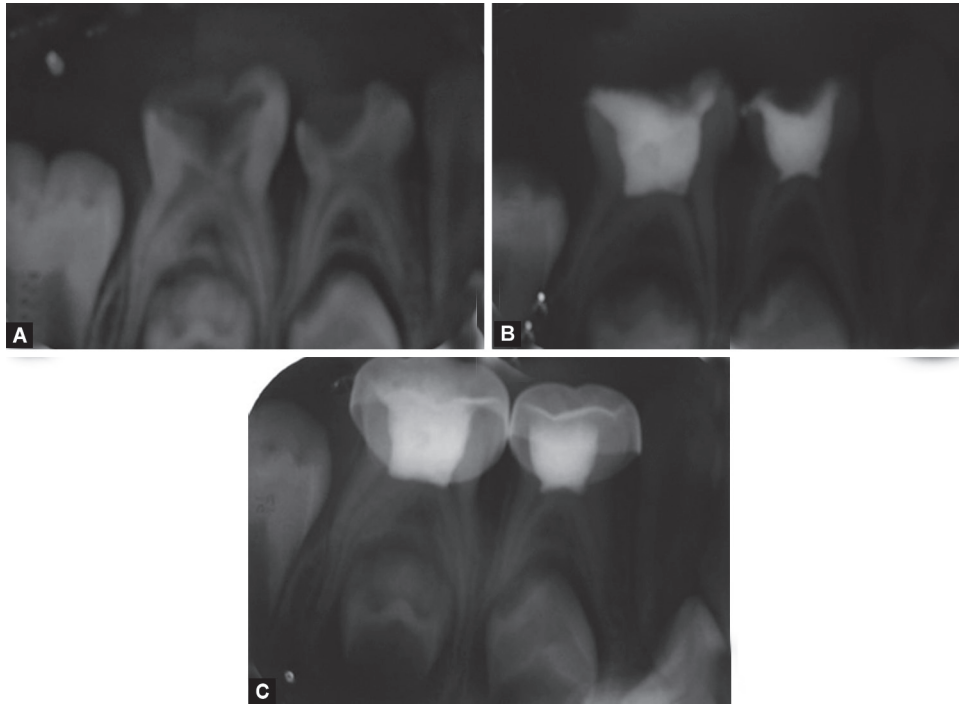
Collectively, the overall success rate was calculated based on the obtained clinical and radiographic assessment for each recall

Table 1: Clinical success rate in the formocresol pulpotomy group and collagen pulpotomy group at two-, four, and six-month intervals

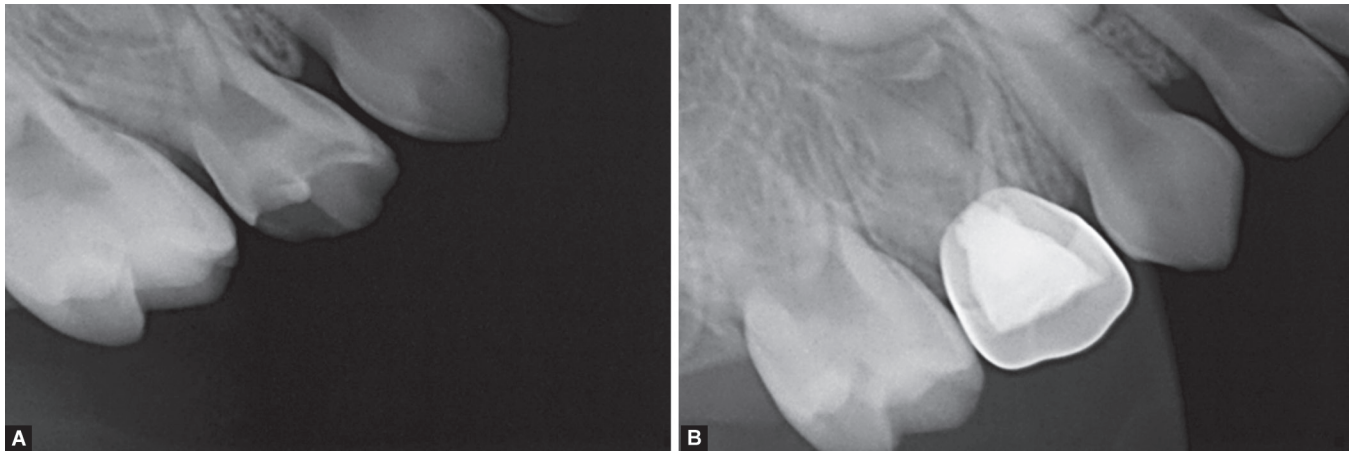
Clinical findings	Pulpotomy group	2 months		4 months		6 months	
		Absent	Present	Absent	Present	Absent	Present
Pain	Group 1	15	0	15	0	14	1
	Group 2	14	1	14	1	15	0
TOP	Group 1	15	0	15	0	15	0
	Group 2	15	0	15	0	15	0
Abscess	Group 1	15	0	15	0	15	0
	Group 2	15	0	15	0	15	0
Swelling	Group 1	15	0	15	0	15	0
	Group 2	15	0	15	0	15	0
Fistula	Group 1	15	0	15	0	15	0
	Group 2	15	0	15	0	15	0
Mobility	Group 1	15	0	15	0	12	3
	Group 2	15	0	15	0	15	0



Figs 1A to C: Periodic radiographic assessment of formocresol group—preoperative, at second-month review and sixth-month review



Figs 3A to C: Periodic radiographic assessment of collagen group—preoperative, at second-month review and sixth-month review



Figs 4A and B: Sixth-month radiographic assessment of formocresol group revealed internal and external resorption

Table 2: Radiographic success rate in the formocresol pulpotomy group and collagen pulpotomy group at two-, four, and six-month intervals

Radiographic findings	Pulpotomy groups	2 months		4 months		6 months	
		Absent	Present	Absent	Present	Absent	Present
Inter-radiolar radiolucency	Group 1	14	1	14	1	13	2
	Group 2	14	1	14	1	15	0
Internal/external resorption	Group 1	15	0	14	1	13	2
	Group 2	15	0	15	0	15	0
PDL widening	Group 1	15	0	15	0	14	1
	Group 2	15	0	15	0	15	0
Furcation radiolucency	Group 1	15	0	15	0	15	0
	Group 2	15	0	15	0	15	0

interval period. The overall success rate for formocresol pulpotomy ($n = 15$) was 14, 13, and 10 for the second-, fourth-, and sixth-month review period, respectively. For collagen pulpotomy group ($n = 15$), the overall success rate was 14, 14, and 14 for the second-, fourth-, and sixth-month review period, respectively.

The obtained data from the overall success rate were subjected to statistical analysis, and chi-square test was used. The p -value less than 0.1 was considered a statistically significant result. The chi-square value for the fourth- and sixth-month review was 0.37 and 3.33, respectively. The p -value was 0.54 and 0.067 for the 4th and 6th month, respectively (Table 3). Statistically significant value was obtained from the sixth-month review period ($p < 0.1$), which describes that the overall success rate was better for the collagen pulpotomy group when compared with the formocresol pulpotomy group.

DISCUSSION

Preservation of the primary teeth in the arch until its time of exfoliation is the need for the hour, and it not only retains the functional efficiency but also the esthetic harmony in the transition of mixed dentition period to permanent dentition period. Choosing the appropriate management strategies and identifying appropriate material of choice are always a greater challenge for the dentist.

When the carious process exposes the pulp, it reacts by inflammation that is limited to the area close to the carious lesion. If the pulp in the root canal seems to be unaffected, then pulpotomy is the treatment of choice.^{5,6} Failures in primary teeth can also be attributed to misdiagnosis of inflammation in the radicular pulp.^{6,7}

A wide range of materials was used for pulpotomy in the literature, such as formocresol, ferric sulfate, mineral trioxide aggregate (MTA), Biodentine, laser, glutaraldehyde, ZOE, calcium hydroxide, bone morphogenetic protein, enamel matrix derivatives, and sodium hypochlorite.⁸ Collagen-based pulpotomy was very scarce in the dental literature on pulpotomy clinical studies. Attaining hemostasis, biocompatibility, repair, and regeneration was the prime properties required for a noble pulpotomy material. Chemicals and their by-products inevitably disturb these properties. So, in this study, a material that satisfies all these properties, collagen derivatives, was used as study material and compared with the gold standard formocresol pulpotomy.

The collagen product used was BioFil®-AB Particles, which is primarily atype 1 collagen in lyophilized particle form with Mupirocin USP 2% w/w and Metronidazole IP 1% w/w of specified

volumes. It is gamma sterilized and supplied in convenient cold seal blister packing. Apart from other properties, the material also possesses antibacterial properties due to the presence of metronidazole and mupirocin incorporation.

Some of the pulpotomy material that has similar characteristics like collagen particles used in the dental literature on pulpotomy was Biodentine and MTA. Biodentine has been shown to have good marginal adaptation and strength to be used as a temporary restorative material for up to 6 months in a study conducted by Koubi et al. This could be an advantage while treating children in the clinical setting as it shortens the procedure time, eliminating the need to place a separate restoration.⁹ Laurent et al. showed in human entire tooth culture model that ProRoot MTA induced reparative dentin synthesis after direct pulp capping due to significantly increased TGF- β 1 secretion level that enables the pulpal tissues to induce cell proliferation and biomineralization.¹⁰

In the study, the pain present in the formocresol-based pulpotomy group revealed the presence of internal resorption at sixth-month radiographical assessment, which is in accordance with the study conducted by Eidelman and Magnusson. One probable reason is attributed to the reversible fixative effect of formocresol, and irritative pH, chemical, and physical effects of ZOE on connective pulp tissues.¹¹

In most of the published studies, as well as in this study, ZOE was used as sub-base, expecting to prevent the direct contact of any other restorative material. But on the contrary, studies have also shown that ZOE in direct contact with vital pulp tissues causes moderate to severe inflammatory responses that result in chronic inflammation and necrosis resulting in internal resorption.^{12,13} However, in the present study, collagen was sandwiched between amputated pulpal tissues and ZOE, so these adverse properties of ZOE if present can be minimized completely.

Host response to pulpotomy materials varies from individual to individual; the primary objective of formocresol-based pulpotomy is hemostasis by fixation of the connective tissues within the amputated pulp. But the extent of fixation cannot be assessed as well as the concentration and amount of formocresol used cannot be standardized.^{14,15} Excessive fixation of pulpal tissues leads to accelerated host response that results in increased physiological root resorption. Mobility present at sixth-month review in formocresol pulpotomy group can attribute to these factors.

Ultimately collagen-based pulpotomy group demonstrates a higher overall success rate when compared with formocresol pulpotomy group, which is evident from statistical analysis. Few studies or clinical trials in the dental literature on collagen-based pulpotomy limit the comparison and critical assessment of the results with the same materials used.

Table 3: Overall success rate (clinical and radiographic) in the formocresol pulpotomy group and collagen pulpotomy group at two-, four, and six-month intervals

		2 months		4 months		6 months	
		Absent	Present	Absent	Present	Absent	Present
Overall success rate	Formocresol pulpotomy group	1	14	2	13	5	10
	Collagen pulpotomy group	1	14	1	14	1	14
	Chi-square	–	–	0.37		3.33*	
	p -value ($p < 0.1$)	–	–	0.54		0.067*	

Chi square test gave the p -value of 0.54 and 0.067 in the fourth and sixth month review respectively. A statistical significant p -value ($p < 0.1$) was obtained, explaining that the overall success rate of collagen-based pulpotomy was better when compared to that of formocresol-based pulpotomy at the sixth month review.

The strength of the present study was as follows: Both formocresol pulpotomy and collagen-based pulpotomy was done in the same patient, to eliminate host response bias; single operative investigator was performing all treatment, to eliminate confounding bias; and case confirmation for pulpotomy was done after operative diagnosis to rule out sample bias.

Limitation of this study includes the less sample size, as it is a split-mouth protocol employed. The duration of clinical and radiographic success rate could have been extended beyond 6 months to attain more valuable details. There was difficulty in manipulating collagen particles as it was difficult to transport these collagen particles from the vials to the access cavity; however, it was overcome using an amalgam carrier to transport these particles.

CONCLUSION

It was clearly illustrated that collagen-based pulpotomy showed a higher overall success rate in both clinical and radiographic assessment when compared with that of formocresol-based pulpotomy. Collagen particles were proven to have the noble properties like attaining hemostasis, biocompatibility, repair, regeneration, and in addition antibacterial properties. However, it is always subjected to further research and development with other materials like MTA, Biodentine, and bone morphogenic protein to critically assess the overall success rate of collagen-based pulpotomy.

REFERENCES

1. Patino MG, Neiders ME, Andreana S, et al. Collagen as an implantable material in medicine and dentistry. *J Oral Implantol* 2002;28(5):220–225. DOI: 10.1563/1548-1336(2002)028<0220:CAAIMI>2.3.CO;2.
2. Bunyaratavej P, Wang HL. Collagen Membrane a review. *J Periodontol* 2001;72:215–229. DOI:10.1902/jop.2001.72.2.215
3. Rao KP. Recent developments of collagen-based materials for medical applications and drug delivery systems. *J Biomater Sci Polym Ed* 1995;7(7):623–645. DOI: 10.1163/156856295x00526.
4. Burg KJL, Shalaby SW. Radiation sterilization of medical device sand pharmaceuticals. Irradiation of polymers. *ACS Symp Ser* 1996;620:240–245. DOI: 10.1021/bk-1996-0620.ch018.
5. Hugar SM, Deshpande SD. Comparative investigation of clinical/ radiographical signs of mineral trioxide aggregate and formocresol on pulpotomized primary molars. *Contemp Clin Dent* 2010;1(3):146–151. DOI: 10.4103/0976-237X.72779.
6. Fuks AB. Pulp therapy for the primary dentition. In: Pinkham JR, Casamassimo PS, Fields HW Jr, et al., editors. *Pediatric dentistry: infancy through adolescence*. 5th ed. St. Louis, MO: Elsevier Saunders Co; 2013. p. 331–351.
7. Juneja P, Kulkarni S. Clinical and radiographic comparison of biodentine, mineral trioxide aggregate and formocresol as pulpotomy agents in primary molars. *Eur Arch Paediatr Dent* 2017 Aug;18(4):271–278. DOI: 10.1007/s40368-017-0299-3
8. Trairatvorakul C, Koothiratrakarn A. Calcium hydroxide partial pulpotomy is an alternative to formocresol pulpotomy based on a 3-year randomized trial. *Int J Paediatr Dent* 2012 Sep;22(5):382–389. DOI: 10.1111/j.1365-263X.2011.01211.x
9. Hugar SM, Deshpande SD. Comparative investigation of clinical/ radiographical signs of mineral trioxide aggregate and formocresol on pulpotomized primary molars. *Contemp Clin Dent* 2010 Jul;1(3):146–151. DOI: 10.4103/0976-237X.72779.
10. Koubi G, Colon P, Franquin JC, et al. Clinical evaluation of the performance and safety of a new dentine substitute, Biodentine, in the restoration of posterior teeth – a prospective study. *Clin Oral Investig* 2013;17(1):243–249. DOI: 10.1007/s00784-012-0701-9.
11. Laurent P, Camps J, About I. Biodentine (TM) induces TGF- β 1 release from human pulp cells and early dental pulp mineralization. *Int Endod J* 2012;45(5):439–448. DOI: 10.1111/j.1365-2591.2011.01995.x.
12. Airen P, Shigli A, Airen B. Comparative evaluation of formocresol and mineral trioxide aggregate in pulpotomized primary molars 2 year follow up. *J Clin Pediatr Dent* Winter 2012;37(2):143–7. DOI: 10.17796/jcpd.37.2.h427vr8157444462
13. Olczak-Kowalczyk D. et al. Ferric Sulfate and Formocresol pulpotomies in paediatric dental practice. A prospective retrospective study. *Eur J Paediatr Dent*. 2019 Mar;20(1):27–32. DOI: 10.23804/ejpd.2019.20.01.06
14. Hume WR. The pharmacologic and toxicological properties of zinc oxide-eugenol. *J Am Dent Assoc* 1986;113(5):789–791. DOI: 10.14219/jada.archive.1986.0256.
15. Chakraborty A, Dey B, Jana S. A nonconventional approach to formocresol pulpotomy. *Int J Clin Pediatr Dent* 2018;11(6):490–495. DOI: 10.5005/jp-journals-10005-1563.