

# Unsplinted Attachment Systems and Peri-implant Outcomes in Two-implant-retained Mandibular Overdentures: A Systematic Review of Randomized Controlled Trials

Pravinkumar G Patil<sup>1</sup>, Liang Lin Seow<sup>2</sup>, Ting Jing Kweh<sup>3</sup>, Smita Nimbalkar<sup>4</sup>

## ABSTRACT

**Aim:** The purpose of this review is to compare randomized clinical trials evaluating the peri-implant tissue outcomes using different unsplinted attachment systems in two implant-retained mandibular overdentures.

**Background:** Literature lacks information on various unsplinted attachment systems and their effect on peri-implant tissue health. A focus question (as per PICOS) was set as follows: Does one particular unsplinted attachment system (I) compared with another (C) results in better peri-implant outcomes (O) in two implant-retained mandibular overdentures (P) using randomized controlled trials (RCTs) (S)? The literature search was conducted in the PubMed, MEDLINE and Cochrane Central Register of Controlled Trials (CENTRAL) databases between January 2011 and December 2021. The keywords used were “denture, overlay,” “denture,” “overlay” AND “dental prosthesis, implant supported,” “dental implants,” “dental implant abutment design” AND “jaw, edentulous,” “mouth, edentulous” AND “mandible.” Only RCTs on two implant-retained mandibular overdentures using unsplinted attachment systems measuring peri-implant tissue outcomes with minimum 1-year follow-up were selected. In total, 224 studies were identified in initial search, and 25 were shortlisted for full-text evaluation. Four studies were included for systematic review upon considering inclusion and exclusion criteria. The risk of bias was evaluated using Cochrane Risk of Bias Tool 2.0 (RoB 2.0).

**Review results:** A total of 41 patients received ball attachments (in 3 studies), 36 patients received low-profile attachments (in 3 studies), 16 patients received magnet attachments (in 1 study), and 13 patients received telescopic attachments (in 1 study). All four studies used standard sized implants, however, differed in implant manufacturers. Two studies which compared ball attachments low-profile attachments revealed similar peri-implant tissue health parameters but differed in crestal bone-level changes. One study compared ball with telescopic attachments and revealed similar results in crestal bone-level changes and all four peri-implant tissue health parameters. Single study compared magnets with low-profile attachments and shown lesser bone loss with magnet attachments. Single study was judged to have low risk of bias, single with some concerns, and remaining two to have high risk of bias.

**Conclusion:** Gingival index and bleeding index of the patients were not influenced by any of the unsplinted overdenture attachment (stud, magnet, telescopic) system. Inconclusive results found among the studies evaluated comparing crestal bone loss and plaque index.

**Clinical significance:** This review manuscript has simplified comparative analysis of different unsplinted attachment systems used in two implant mandibular overdentures to help clinicians choose correct system in such situation.

**Keywords:** Edentulism, Geriatric dentistry, Implant dentistry, Mandibular overdenture.

*The Journal of Contemporary Dental Practice* (2021): 10.5005/jp-journals-10024-3228

## INTRODUCTION

### Background

Edentulism continues to represent an enormous global healthcare burden that is often neglected in both developed and developing countries.<sup>1</sup> Conventional complete dentures are one of the most widely used treatment modalities for edentulous patients. However, lack of retention and stability results in decrease in chewing ability in these patients.<sup>2</sup> Dental implants have provided varieties of fixed abutments and/or removable attachments systems in restoring completely edentulous arches in recent years to overcome the problem of retention and stability of complete dentures.<sup>3-5</sup> Large number of clinical studies in this area led a panel of experts (at the symposium in McGill University, Canada in 2002) to create a consensus statement that states: “The evidence currently available suggests that the restoration of the edentulous mandible with a conventional denture is no longer the most appropriate first choice prosthodontic treatment.<sup>6</sup> There is now overwhelming evidence that a two-implant overdenture should become the first choice of treatment for the edentulous mandible.” This statement was also supported by experts in

<sup>1-3</sup>Division of Restorative Dentistry, School of Dentistry, International Medical University, Kuala Lumpur, Malaysia

<sup>4</sup>Division of Clinical Oral Health Sciences, School of Dentistry, International Medical University, Kuala Lumpur, Malaysia

**Corresponding Author:** Pravinkumar G Patil, Division of Restorative Dentistry, School of Dentistry, International Medical University, Kuala Lumpur, Malaysia, e-mail: pravinandsmita@yahoo.co.in

**How to cite this article:** Patil PG, Seow LL, Kweh TJ, *et al.* Unsplinted Attachment Systems and Peri-implant Outcomes in Two-implant-retained Mandibular Overdentures: A Systematic Review of Randomized Controlled Trials. *J Contemp Dent Pract* 2021;22(11): 1346–1354.

**Source of support:** This project was supported by International Medical University, Kuala Lumpur, Malaysia, as a staff project. Project ID: IMU 496/2020.

**Conflict of interest:** None

England symposium in 2009 and US academic prosthodontic experts’ opinions survey carried out in 2011.<sup>7</sup>

### Types of Overdenture Attachments

There are four broad groups of attachment systems, namely bar, stud, magnetic, or telescopic.<sup>8,9</sup> Three basic types of attachments (stud, magnetic, or telescopic) were considered as unsplinted or free-standing attachments, and the bar attachments are considered as splinted attachments (Table 1). The bar attachment systems are made up of metallic casted or milled bars (usually semi-circular in cross section) joining two or more number of implants and the retentive components usually holding clips incorporated into the dentures with the help of metal housings. They provide splinting effect to all the implants, however, this requires more technical and clinical expertise to use. The usage remains limited in lesser inter-arch space. In patients with a decreased vertical dimension or reduced vertical restorative space, the free-standing or unsplinted attachment systems are used over splinted (bar-clip) type and are beneficial in terms of initial treatment cost, hygiene, and simplicity in manufacturing process.<sup>10,11</sup> The unsplinted attachments are more beneficial in terms of initial treatment cost, maintenance and ease of repair, hygiene, and simplicity of manufacture as compared with splinted bar-type of attachments. In recent years, the different stud attachment designs have been introduced as opposed to the conventional ball designs and are being named (and known) by their trade names [Locator (Zest Anchors), Equator (Rhein83), ERA (Sterngold)] rather than their basic category of stud attachments (Table 1).<sup>11-13</sup> These newer designs have a single common characteristic feature of their ability to accommodate limited inter-arch space and hence sometime also referred to as

low-profile attachments.<sup>11</sup> The Locator (introduced in 2001 by Zest Anchors), low-profile stud attachment, was one of the most widely used and studied system in recent years requires as low as 2.5 mm vertical height.<sup>11-13</sup> The Equator (introduced by Rhein83) was similarly designed newer low-profile stud attachment providing both castable and direct options for implant overdentures, which requires as low as 2.1 mm.<sup>13</sup>

### What is Already Known and What is the Need of this Review

Even though these newer low-profile stud attachments were in dental practice for almost two decades, these were not being compared enough against their conventional counterpart of ball attachments. Gonçalves et al.<sup>14</sup> performed a systematic review and evaluated 16 randomized clinical trials to compare overdentures supported by either bar and clip or ball and O-ring attachments for retention, masticatory efficiency, bone loss, and patient satisfaction. They concluded that both the bar and clip and ball and O-ring attachment systems presented similar clinical performance regarding mechanical and functional properties and patient satisfaction. Miler et al.<sup>15</sup> have carried out a systematic review of 10 clinical studies to evaluate the success rate, complications, maintenance, and patient satisfaction with implant-supported overdentures with the locator system and concluded that locator system provided acceptable patient satisfaction and appears to hold a good retention but required frequent maintenance visits. Keshk et al.<sup>16</sup> carried out a systematic review with three randomized clinical

**Table 1:** Details of unsplinted or free-standing overdenture attachments

Main type	Subtype or alternative names	Known by trade names	Advantages	Disadvantages
<b>Stud</b>	Ball, Retentive anchor, Dalla Bona, O-Ring  Low-profile, Self-aligning	Dalbo  Locator, Equator ERA	<ul style="list-style-type: none"> <li>• Simple and the most widely used</li> <li>• Low initial cost</li> <li>• Can be used with non-parallel implants.</li> <li>• Smaller in size and convenient in limited inter-arch space</li> <li>• Available in several vertical heights</li> <li>• Easy chairside fitting and repairs.</li> <li>• Easier hygiene access</li> <li>• Variety of designs and retentive strengths</li> <li>• Considerable stress-breaking/ stress relieving effect</li> </ul>	<ul style="list-style-type: none"> <li>• Long-term maintenance and repair costs</li> <li>• Not all accommodate angular discrepancies</li> <li>• Some designs get food and biofilm accumulation</li> <li>• Early loss of retention</li> </ul>
<b>Magnetic</b>	—	—	<ul style="list-style-type: none"> <li>• Offer the advantage of self-seating the prosthesis, which is especially suitable for elderly patients with limited manual dexterity or arthritis.</li> <li>• Attachment procedures are relatively simple</li> </ul>	<ul style="list-style-type: none"> <li>• Least retentive amongst all unsplinted attachments</li> <li>• Intraoral corrosion leading to rapid loss of retention and the replacement of the attachments becomes inevitable</li> </ul>
<b>Telescopic</b>	Non-resilient	Conus SynCone	<ul style="list-style-type: none"> <li>• Hygiene measures are much easier</li> <li>• Secondary telescopic crowns provide high retention and stability of the overdenture</li> </ul>	<ul style="list-style-type: none"> <li>• Metal display of the primary crowns when the overdenture is removed may influence esthetics</li> </ul>

trials (RCTs) comparing telescopic attachments vs other attachment systems for mandibular implant overdentures and concluded that there were no significant differences in prosthodontic maintenance and peri-implant tissue health between telescopic attachments and ball attachments. Many reviews published either comparing bar and clip attachment vs other unsplinted attachments. No systematic review has been carried out on RCTs directly comparing different unsplinted attachments regarding the crestal bone-level changes and peri-implant health parameters (namely plaque index, bleeding index, gingival index, and probing depth) in two implant-retained mandibular overdentures.

**Focus Question (PICOS)**

Does one particular unsplinted attachment system (I) compared with another (C) result in better peri-implant outcomes (O) in two implant-retained mandibular overdentures (P) using RCTs (S)?

**MATERIALS AND METHODS**

**Review Registry and Ethical Approval**

This systematic review and meta-analysis evaluate the randomized clinical trials comparing different unsplinted attachment systems for implant-retained mandibular overdentures. The study was registered in the Prospective Register of Systematic Reviews (PROSPERO) platform (CRD42020178103). The study was conducted according to the Preferred Reporting Items for Systematic Reviews and Meta-analyses (PRISMA) checklist. Institutional ethical approval has been obtained from authors' institute (Project ID: 496/2020).

**Eligibility of Studies**

Only those studies with RCTs with the following requirements were included in the present study: (1) Type of participants—completely edentulous patients treated with two implant-retained mandibular overdentures. (2) Type of intervention—two implants with only unsplinted attachments used with no limits on implant type, implant manufacturer, technique of placement, or loading protocols. (3) Comparison—between any two types of unsplinted attachments. (4) Outcome—crestal bone-level changes and peri-implant tissue health parameters including plaque/gingival/bleeding index and probing depth. The studies, in which only single type of attachments used with different comparators or any

unsplinted attachment system compared with splinted attachment system, were excluded. The clinical trials published in English language were taken into consideration.

**Search Strategy**

The electronic literature search was conducted independently by two researchers (PGP, TJK) in the PubMed MEDLINE and Cochrane Central Register of Controlled Trials (CENTRAL) between January 1, 2011, and December 31, 2021 (Table 2). A literature search was also performed in ClinicalTrials.gov and WHO International Clinical Trials Registry. Manual search was also performed which did not reveal any eligible study. Only RCTs on two implant-retained mandibular overdentures using unsplinted attachment systems measuring peri-implant tissue outcomes with minimum 1-year follow-up were selected.

**Risk of Bias**

The selected studies were appraised by two reviewers (TJK, SN) independently in the five domains namely randomization process, deviations from intended interventions, missing outcome data, measurement of the outcome and selection of the reported result using revised Cochrane Risk of Bias Tool 2.0 (RoB 2.0). Any disagreement was resolved after discussion with the third reviewer (SLL) with respect to individual five domains and overall bias. Individual studies were categorized as high, low, or some concerns. The studies with a high risk of bias were excluded for the qualitative and quantitative data synthesis. For clinical trials that evaluated the same study population, only the study with the higher observation time was included.

**Summary of Studies**

The data were extracted on the variables such as study method, participants, intervention, and outcome by two reviewers (TJK, PGP) and combined for analysis. The summary of selected information was tabulated based upon predetermined criteria to facilitate effect of attachment systems. Meta-analysis could not be performed as the crestal bone-level changes and peri-implant tissue outcomes were evaluated under vastly different conditions leading to heterogeneity amongst the articles selected. The level of agreement between the reviewers regarding relevant factors in the studies was determined using Cohen's kappa coefficient (κ).

**Table 2:** Search strategy

Database	Search strategy
PubMed MEDLINE (n = 172)	(((("denture, overlay" [MeSH Terms] OR "denture" [All Fields] OR "overlay" [All Fields]) OR "overlay denture" [All Fields] AND "dental prosthesis, implant supported" [MeSH Terms]) OR "dental implants" [MeSH Terms] OR "dental implant abutment design" [MeSH Terms]) AND "jaw, edentulous" [MeSH Terms]) OR "mouth, edentulous" [MeSH Terms]) AND "mandible" [MeSH Terms]
Cochrane Central Register of Controlled Trials (CENTRAL) (n = 52)	#1 MeSH descriptor: [Mouth, Edentulous] explode all trees 803 #2 MeSH descriptor: [Dental Prosthesis, Implant-Supported] explode all trees 813 #3 MeSH descriptor: [Denture, Overlay] explode all trees 355 #4 MeSH descriptor: [Denture Precision Attachment] explode all trees 31 #5 locator* or ball* or magnet* or telescopic* or equator* or unsplinted* 60,392 #6 (#1 or #2 or #3 or #4) and #5 174 #7 MeSH descriptor: [Alveolar Bone Loss] explode all trees 1,350 #8 MeSH descriptor: [Peri-implantitis] explode all trees 207 #9 MeSH descriptor: [Periodontal Index] explode all trees 2,033 #10 MeSH descriptor: [Dental Plaque Index] explode all trees 1,989 #11 #6 and (#7 or #8 or #9 or #10) 52



## RESULTS

### Study Selection

In total, 224 studies were identified in initial search, and 25 were shortlisted for full-text evaluation (Flowchart 1). A total of 21 studies out of 25 selected studies<sup>17-35,38,40</sup> were excluded due to different reasons listed in Table 3. Four studies<sup>36,37,39,41</sup> were included for systematic review. The studies excluded<sup>17-35,38,40</sup> mainly because of either of the unsplinted attachments were compared directly with splinted attachments or only unsplinted or splinted attachments were used to study clinical parameters not related to the attachments. One study, Maniewicz et al.,<sup>18</sup> excluded due to its *in vitro* study type. The kappa coefficient value ( $\kappa = 0.81$ ) indicated a high level of agreement between the reviewers for the study selection process.

### Summary and Characteristics of the Study

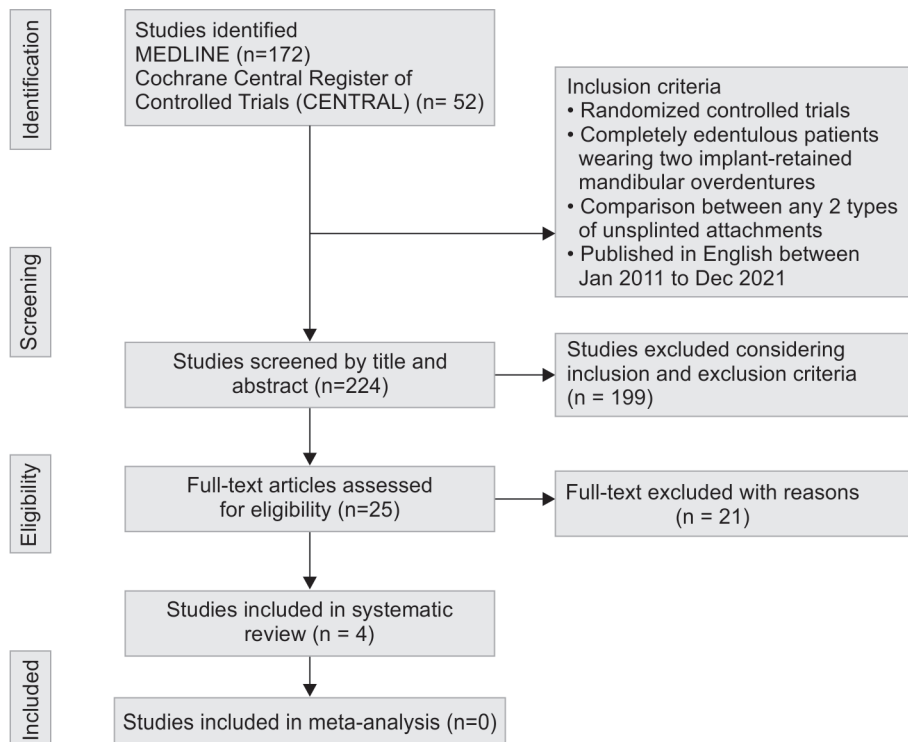
In total, 41 patients received ball attachments (in 3 studies),<sup>36,39,41</sup> 36 patients received low-profile attachments (in 3 studies),<sup>36,37,39</sup> 16 patients received magnet attachments (in 1 study),<sup>37</sup> and 13 patients received telescopic attachments (in 1 study).<sup>41</sup> The details of all included studies have been summarized in Table 4 under different headings. Three<sup>37,39,41</sup> studies have included 1-year follow-up data. One study, Akça et al.,<sup>36</sup> has included 5 years follow-up data. All four studies have included standard sized implants, however, differs in implant systems or manufacturers. Different prosthetic loading protocols (immediate, early, and delayed) were observed in selected four studies.<sup>36,37,39,41</sup> These factors were not considered as potential exclusion criteria due to limited number of clinical studies. Three of four studies were RCTs; however, Krenmair et al.<sup>39</sup> study was crossover clinical trial. Single study, Cepa et al.,<sup>41</sup> considered maxillary arch with three different types of prostheses including complete denture, overdenture,

or removable dental prosthesis, rest all three studies considered only complete dentures in maxillary arch.<sup>36,37,39</sup> Single study<sup>37</sup> included both vertical and horizontal bone-level changes, and remaining three studies<sup>36,39,41</sup> have included only vertical bone-level changes measured on either intraoral periapical radiograph (IOPA) or orthopantomograph or both. Cepa et al.<sup>41</sup> mentioned crestal bone-level changes on mesial and distal side separately for each attachment group, and the results interpreted by taking average of these measurements. Two studies<sup>36,39</sup> compared ball attachments and low-profile attachments, and the results revealed similar peri-implant tissue health parameters namely plaque index, gingival index, and bleeding index (Table 4).

### Radiographic Measurement Techniques Used and Crestal Bone-level Changes

Technique used in measurement of radiographic crestal bone-level changes could be considered as one of the quality components of the study especially in overdentures. Two studies<sup>36,37</sup> used intraoral periapical (IOPA) radiographic method, one<sup>39</sup> study used both IOPA and Orthopantomograph (OPG), and one<sup>41</sup> study used only OPG to evaluate crestal bone-level changes. Two studies<sup>36,37</sup> those used IOPA radiograph have also used either paralleling device or a film holder to maintain standardization in film positioning during each recall time point. The details of the radiographic techniques used for crestal bone-level changes have been mentioned in one of the columns in summary Table 4. The ball attachments exhibit higher crestal bone loss compared with low-profile attachments in single study<sup>36</sup> and comparable in another.<sup>39</sup> Another study<sup>39</sup> compared ball attachments with telescopic attachments and revealed similar results in crestal bone-level changes, and all four tissue health parameters were evaluated. Single study<sup>37</sup> comparing magnet attachments vs low-profile attachment shown lesser bone loss with magnet attachments.

Flowchart 1: Study selection process (PRISMA) checklist



**Table 3:** Excluded studies with reasons

Sl. No.	Authors	Year	Reason for exclusion
1	Kutkut et al. <sup>17</sup>	2019	Only locator attachments compared
2	Maniewicz et al. <sup>18</sup>	2017	Study type <i>in vitro</i>
3	Elsyad et al. <sup>19</sup>	2016	Compared directly with splinted attachments
4	Zygiannidis et al. <sup>20</sup>	2017	Compared directly with splinted attachments
5	Stoker et al. <sup>21</sup>	2012	Compared directly with splinted attachments
6	Schincaglia et al. <sup>22</sup>	2016	Only locator attachments compared
7	Ma et al. <sup>23</sup>	2016	No implant-related outcome
8	Ter Gunne et al. <sup>24</sup>	2016	Only splinted attachments
9	Elsyad et al. <sup>25</sup>	2014	Only locator attachments compared
10	Elsyad et al. <sup>26</sup>	2012	Only ball attachments compared
11	Gadallah et al. <sup>27</sup>	2012	Only ball attachments compared
12	Mumcu et al. <sup>28</sup>	2012	Only ball attachments compared
13	Srinivasan et al. <sup>29</sup>	2020	Compared directly with splinted attachments
14	Akoglu et al. <sup>30</sup>	2011	Only ball attachments compared
15	Turkyilmaz et al. <sup>31</sup>	2012	Only ball attachments compared
16	Muller et al. <sup>32</sup>	2015	Only locator attachments compared
17	Reis et al. <sup>33</sup>	2019	Only splinted attachments
18	Quirynen et al. <sup>34</sup>	2015	Only locator attachments compared
19	Salman et al. <sup>35</sup>	2019	Only locator attachments compared
20	Aunmeungtong et al. <sup>38</sup>	2017	Third group compared with four implants
21	ElSyad et al. <sup>40</sup>	2018	Third group compared with splinted attachment

### Risk of Bias

The final risk of bias assessment of the included studies is illustrated in Figures 1 and 2. One study<sup>37</sup> was judged to have low risk of bias, one<sup>39</sup> with some concerns, and remaining two<sup>39,41</sup> were judged to have high risk of bias based on the RoB 2.0 analysis (Fig. 1). All four studies were found to be at low risk of bias in two domains namely randomization process and deviations from intended interventions domains (Figs 1 and 2).

### DISCUSSION

The crestal bone level and the peri-implant tissue health were not affected by different unsplinted attachment systems in two implant-retained mandibular overdentures. Greater number of studies can be suggested in this area as some of the parameters either have not been recorded or have shown inconsistencies in the results. High risk of bias recorded in either domain for three studies indicated that the results must be interpreted with caution.

#### Radiographic Methods and their Influence on Crestal Bone-level Measurements

Radiographic crestal bone-level measurement could be one of the most challenging tasks especially while taking PA radiographs. As the intraoral film must be in the same position, angulation, and distance during each time point of recall appointments to maintain uniformity in crestal bone level changes. Three out of four studies have used intraoral periapical radiographic method and two have used film holders or paralleling device of different kinds to ensure same film position during each recall time point. Two studies have used OPG for radiographic evaluation of crestal bone-level changes. One study<sup>36</sup> revealed higher crestal bone loss with ball attachments

than low-profile attachments, one study<sup>37</sup> revealed higher vertical bone loss with low-profile attachment than magnets, however, indicated similar horizontal bone loss. Two studies revealed no difference in bone loss between ball and low-profile attachments<sup>39</sup> and between ball and telescopic attachment.<sup>41</sup> Varied outcome measurements among the studies were observed regarding the crestal bone loss and plaque index leading to inconclusive results. Conventionally, the distance between the first screw thread to the top of the alveolar crest in the parallel periapical radiograph has been measured to assess crestal bone changes.<sup>42</sup> Alternate technique demonstrated the crestal bone-level measurement from tip of the implant and calculating effective changes by normalizing the values using actual implant length and radiographic implant length.<sup>43,44</sup> This technique effectively minimizes the measurement error and can be recommended in addition to use of paralleling device or film holder technique. Further research is required to evaluate the effect of different radiographic methods on effective crestal bone-level measurements especially in implant overdenture patients.

#### Potential Confounding Factors

Although all four studies have used standard implants, many confounding factors can possibly affect the results namely different implant manufacturers, different implant surface topography/design, and different loading protocols. These factors may also potentially influence the crestal bone-level changes and peri-implant outcome parameters and should be taken into consideration before interpreting the results.<sup>45</sup> In this regard, Cehreli et al.<sup>45</sup> performed a systematic review to evaluate the effects of implant design and attachment type on marginal bone loss in implant-retained/supported overdentures with a total of 4,200 implants from 13 manufacturers and concluded that there

**Table 4:** Summary of selected studies

Authors	Year	Types of attachments and (no. of patients)	No. of follow-up years	Implant manufacturer	Implant types	Maxillary arch prosthesis	Loading protocols	Crestal bone loss	Plaque index	Gingival index	Bleeding index	Probing depth	Crestal bone level measurement technique
Akça et al. <sup>36</sup>	2013	Ball (n = 19) LOCATOR (n = 10)	5	Straumann SLA surface	Standard	Complete denture	Early (5–6 weeks)	Ball >LOCATOR (p = 0.012)	No difference	No difference	No difference	Not mentioned	Intraoral periapical radiograph using a paralleling device (Dentsply Rinn) Radiographs were digitized at 2,400 dpi using a scanner (Epson Perfection 2400 Photo, Seiko Epson), and linear measurements of the distance from first bone to implant contact to the implant shoulder on the mesial and distal sides of the implants
Elsyad et al. <sup>37</sup>	2016	Magnetic (n = 16) LOCATOR (n = 16)	1	tiologic, Dentaaurum	Standard	Complete denture	Immediate	Vertical bone loss: LOCATOR >Magnet (p <0.05) Horizontal bone loss: No difference	Magnet >LOCATOR (p <0.05)	Not mentioned	No difference	No difference	Intraoral periapical radiograph using film holder: Modification was done by drilling a hole above implant's position, and the holder was secured in position by the long screw of the impression coping
Krenmair et al. <sup>39</sup> (crossover trial)	2012	Ball (n = 10) LOCATOR (n = 10)	1	Camlog	Standard	Complete denture	Delayed (3 months)	No difference	No difference	No difference	No difference	No difference	Digital intraoral periapical radiograph and OPG No standardization technique mentioned for intraoral periapical radiographs
Cepa et al. <sup>41</sup>	2017	Ball (n = 12) Conus (n = 13)	1, 2, 3	Ankylos	Standard	Complete denture or overdenture or removable partial dental prosthesis	Early (10 days)	No difference	No difference	No difference	No difference	No difference	Digital orthopantomogram

	Randomization process	Deviations from intended interventions	Missing outcome data	Measurement of the outcome	Selection of the reported result	Overall
Akca 2013	●	●	●	●	?	●
Elsyad 201	●	●	●	●	●	●
Krenmair 2012	●	●	●	●	?	!
Cepa 2017	●	●	●	?	●	●

Fig. 1: Risk of bias of each selected study

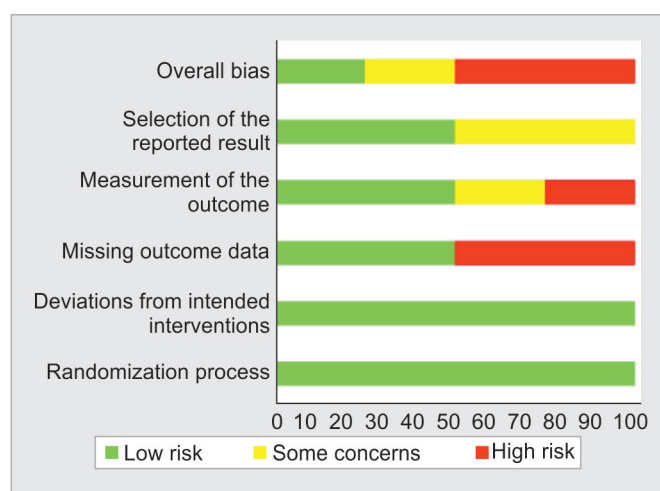

Fig. 2: Overall type of risk of bias of included studies

was no difference in marginal bone loss around implants retaining/supporting mandibular overdentures relative to implant type or attachment designs. Intra- and inter-examiner agreement could also be another influencing factor when assessing radiographic measurement of crestal bone levels.<sup>46</sup>

**What this Review Adds**

This systematic review provided understanding among the RCTs carried out with direct comparison between two different unsplinted attachments systems studied with any pair of combination used in two implant mandibular overdentures. This will help clinicians choose correct system in edentulous mandible.

**The Limitations and Future Directions**

The outcomes are not being affected by the language of the patients using the overdentures. Regarding the crestal bone-level changes, limited number of studies have indicated different results with different unsplinted attachment pairs of comparison (ball vs low-profile, ball vs telescopic, and low-profile vs magnet) under different study conditions (implant manufacturers, loading

protocols, follow-up periods) leading researchers to make no conclusive remarks. Nonetheless, two peri-implant tissue health parameters namely gingival and bleeding indices indicated similar results under all varied conditions and pairs of attachment comparison. Probing depth was not mentioned in one study,<sup>36</sup> and those mentioned<sup>37,39,40</sup> indicated similar results between different attachment systems. As the peri-implant health parameters could also be influenced by other confounding factors such as implant system, implant surface treatment, loading protocols, method of bone-level measurement, intraoperator, and interoperator agreement reporting the results of the study, the results of this systematic review should be interpreted cautiously.

**CONCLUSION**

Within the limitations of this systematic review, the following conclusions were drawn. Gingival index and bleeding index of the patients were not influenced by any of the unsplinted overdenture attachment (stud, magnet, telescopic) system. Inconclusive results found among the studies evaluated comparing crestal bone loss and plaque index. Results of this systematic review should be carefully interpreted in clinical practice.

**REFERENCES**

1. Felton DA. Edentulism and comorbid factors. *J Prosthodont* 2009;18(2):88–96. DOI: 10.1111/j.1532-849X.2009.00437.x.
2. van Waas MA. Determinants of dissatisfaction with dentures: a multiple regression analysis. *J Prosthet Dent* 1990;64(5):569–572. DOI: 10.1016/0022-3913(90)90130-5.
3. Rocuzzo M, Bonino F, Gaudio L, et al. What is the optimal number of implants for removable reconstructions? A systematic review on implant-supported overdentures. *Clin Oral Implants Res* 2012;23 Suppl 6:229–237. DOI: 10.1111/j.1600-0501.2012.02544.x.
4. Daudt Polido W, Aghaloo T, Emmett TW, et al. Number of implants placed for complete-arch fixed prostheses: a systematic review and meta-analysis. *Clin Oral Implants Res* 2018;29 Suppl 16:154–183. DOI: 10.1111/clr.13312.
5. Kern JS, Kern T, Wolfart S, et al. A systematic review and meta-analysis of removable and fixed implant-supported prostheses in edentulous jaws: post-loading implant loss. *Clin Oral Implants Res* 2016;27(2):174–195. DOI: 10.1111/clr.12531.
6. Feine JS, Carlsson GE, Awad MA, et al. The McGill consensus statement on overdentures. Mandibular two-implant overdentures as first choice standard of care for edentulous patients. *Int J Oral Maxillofac Implants* 2002;17(4):601–602. PMID: 12182304.
7. Das KP, Jahangiri L, Katz RV. The first-choice standard of care for an edentulous mandible: a Delphi method survey of academic prosthodontists in the United States. *J Am Dent Assoc* 2012;143(8): 881–889. DOI: 10.14219/jada.archive.2012.0292.
8. Prieskel HW. Telescopic prostheses. In: Prieskel HW, editor. Precision attachments in prosthodontics: overdentures and telescopic prostheses. vol. 2. Chicago: Quintessence Publishing Co. Inc.; 1985. p. 307–328.
9. Prieskel HW. Overdentures made easy: a guide to implant and root supported prostheses. 1st ed. Chicago, Illinois, USA: Quintessence Publishing Co. Inc.; 1996.
10. Ahuja S, Cagna DR. Classification and management of restorative space in edentulous implant overdenture patients. *J Prosthet Dent* 2011;105(5):332–337. DOI: 10.1016/S0022-3913(11)60064-4.
11. Bhargava A, Sehgal M, Gupta S, et al. Classification system on the selection of number of implants and superstructure design on the basis available vertical restorative space and interforaminal distance for implant supported mandibular overdenture. *J Indian Prosthodont Soc* 2016;16(2):131–135. DOI: 10.4103/0972-4052.176541.



12. Scherer MD, McGlumphy EA, Seghi RR, et al. Comparison of retention and stability of two implant-retained overdentures based on implant location. *J Prosthet Dent* 2014;112(3):515–521. DOI: 10.1016/j.prosdent.2014.03.003.
13. Hegazy SA, El Mekawy N, Emera RMK. Impact of implants number and attachment type on the peri-implant stresses and retention of palateless implant-retained overdenture. *Indian J Dent Res* 2020;31(3):414–419. DOI: 10.4103/ijdr.IJDR\_772\_18.
14. Gonçalves F, Campestrini VLL, Rigo-Rodrigues MA, et al. Effect of the attachment system on the biomechanical and clinical performance of overdentures: a systematic review. *J Prosthet Dent* 2020;123(4):589–594. DOI: 10.1016/j.prosdent.2019.03.024.
15. Miler AMQP, Correia ARM, Rocha JMC, et al. Locator® attachment system for implant overdentures: a systematic review. *Stomatologija* 2017;19(4):124–129. PMID: 29806650.
16. Keshk AM, Alqutaibi AY, Algabri RS, et al. Prosthodontic maintenance and peri-implant tissue conditions for telescopic attachment-retained mandibular implant overdenture: systematic review and meta-analysis of randomized clinical trials. *Eur J Dent* 2017;11(4):559–568. DOI: 10.4103/ejd.ejd\_23\_17.
17. Kutkut A, Rezk M, Zephyr D, et al. Immediate loading of unsplinted implant retained mandibular overdenture: a randomized controlled clinical study. *J Oral Implantol* 2019;45(5):378–389. DOI: 10.1563/aaid-joi-D-18-00202.
18. Maniewicz S, Buser R, Duvernay E, et al. Short dental implants retaining two-implant mandibular overdentures in very old, dependent patients: radiologic and clinical observation up to 5 years. *Int J Oral Maxillofac Implants* 2017;32(2):415–422. DOI: 10.11607/jomi.5361.
19. Elsyad MA, Khirallah AS. Circumferential bone loss around splinted and nonsplinted immediately loaded implants retaining mandibular overdentures: a randomized controlled clinical trial using cone beam computed tomography. *J Prosthet Dent* 2016;116(5):741–748. DOI: 10.1016/j.prosdent.2016.03.005.
20. Zygogiannis K, Aartman IH, Parsa A, et al. Implant mandibular overdentures retained by immediately loaded implants: a 1-year randomized trial comparing the clinical and radiographic outcomes between mini dental implants and standard-sized implants. *Int J Oral Maxillofac Implants* 2017;32(6):1377–1388. DOI: 10.11607/jomi.5981.
21. Stoker G, van Waas R, Wismeijer D. Long-term outcomes of three types of implant-supported mandibular overdentures in smokers. *Clin Oral Implants Res* 2012;23(8):925–929. DOI: 10.1111/j.1600-0501.2011.02237.x.
22. Schincaglia GP, Rubin S, Thacker S, et al. Marginal bone response around immediate-and delayed-loading implants supporting a locator-retained mandibular overdenture: a randomized controlled study. *Int J Oral Maxillofac Implants* 2016;31(2):448–458. DOI: 10.11607/jomi.4118.
23. Ma S, Tawse-Smith A, De Silva RK, et al. Maxillary three-implant overdentures opposing mandibular two-implant overdentures: 10-year surgical outcomes of a randomized controlled trial. *Clin Implant Dent Relat Res* 2016;18(3):527–544. DOI: 10.1111/cid.12325.
24. Ter Gunne LP, Dikkes B, Wismeijer D, et al. Immediate and early loading of two-implant-supported mandibular overdentures: three-year report of loading results of a single-center prospective randomized controlled clinical trial. *Int J Oral Maxillofac Implants* 2016;31(5):1110–1116. DOI: 10.11607/jomi.4561.
25. Elsyad MA, Elsayh EA, Khairallah AS. Marginal bone resorption around immediate and delayed loaded implants supporting a locator-retained mandibular overdenture. A 1-year randomised controlled trial. *J Oral Rehabil* 2014;41(8):608–618. DOI: 10.1111/joor.12182.
26. Elsyad MA, Al-Mahdy YF, Fouad MM. Marginal bone loss adjacent to conventional and immediate loaded two implants supporting a ball-retained mandibular overdenture: a 3-year randomized clinical trial. *Clin Oral Implants Res* 2012;23(4):496–503. DOI: 10.1111/j.1600-0501.2011.02173.x.
27. Gadallah AA, Youssef HG, Shawky YM. A comparative study between early occlusal loading at 1 and 6 weeks in implant-retained mandibular overdentures. *Implant Dent* 2012;21(3):242–247. DOI: 10.1097/ID.0b013e31824eeaa5.
28. Mumcu E, Bilhan H, Geckili O. The influence of healing type on marginal bone levels of implants supporting mandibular overdentures: a randomized clinical study. *Indian J Dent Res* 2012;23:514–518. DOI: 10.4103/0970-9290.104961.
29. Srinivasan M, Schimmel M, Buser R, et al. Mandibular two-implant overdentures with CAD-CAM milled bars with distal extensions or retentive anchors: a randomized controlled trial. *Clin Oral Implants Res* 2020;31(12):1207–1222. DOI: 10.1111/clr.13668.
30. Akoglu B, Ucakale M, Ozkan Y, et al. Five-year treatment outcomes with three brands of implants supporting mandibular overdentures. *Int J Oral Maxillofac Implants* 2011;26(1):188–194. PMID: 21365055.
31. Turkyilmaz I, Tozum TF, Fuhrmann DM, et al. Seven-year follow-up results of TiUnite implants supporting mandibular overdentures: early versus delayed loading. *Clin Implant Dent Relat Res* 2012;14 Suppl 1:e83–e90. DOI: 10.1111/j.1708-8208.2011.00365.x.
32. Müller F, Al-Nawas B, Storelli S, et al. Small-diameter titanium grade IV and titanium-zirconium implants in edentulous mandibles: five-year results from a double-blind, randomized controlled trial. *BMC Oral Health* 2015;15(1):123. DOI: 10.1186/s12903-015-0107-6.
33. Reis R, Nicolau P, Calha N, et al. Immediate versus early loading protocols of titanium-zirconium narrow-diameter implants for mandibular overdentures in edentulous patients: 1-year results from a randomized controlled trial. *Clin Oral Implants Res* 2019;30(10):953–961. DOI: 10.1111/clr.13502.
34. Quirynen M, Al-Nawas B, Meijer HJ, et al. Small-diameter titanium Grade IV and titanium-zirconium implants in edentulous mandibles: three-year results from a double-blind, randomized controlled trial. *Clin Oral Implants Res* 2015;26(7):831–840. DOI: 10.1111/clr.12367.
35. Salman A, Thacker S, Rubin S, et al. Immediate versus delayed loading of mandibular implant-retained overdentures: a 60-month follow-up of a randomized clinical trial. *J Clin Periodontol* 2019;46(8):863–871. DOI: 10.1111/jcpe.13153.
36. Akça K, Çavuşoğlu Y, Sağırkaya E, et al. Early-loaded one-stage implants retaining mandibular overdentures by two different mechanisms: 5-year results. *Int J Oral Maxillofac Implants* 2013;28(3):824–830. DOI: 10.11607/jomi.2994.
37. Elsyad MA, Mahanna FF, Elshahat MA, et al. Locators versus magnetic attachment effect on peri-implant tissue health of immediate loaded two implants retaining a mandibular overdenture: a 1-year randomised trial. *J Oral Rehabil* 2016;43(4):297–305. DOI: 10.1111/joor.12368.
38. Aunmeungtong W, Kumchai T, Strietzel FP, et al. Comparative clinical study of conventional dental implants and mini dental implants for mandibular overdentures: a randomized clinical trial. *Clin Implant Dent Relat Res* 2017;19(2):328–340. DOI: 10.1111/cid.12461.
39. Krennmair G, Seemann R, Fazekas A, et al. Patient preference and satisfaction with implant-supported mandibular overdentures retained with ball or locator attachments: a crossover clinical trial. *Int J Oral Maxillofac Implants* 2012;27(6):1560–1568. PMID: 23189311.
40. Elsyad MA, Denewar BA, Elsayh EA. Clinical and radiographic evaluation of bar, telescopic, and locator attachments for implant-stabilized overdentures in patients with mandibular atrophied ridges: a randomized controlled clinical trial. *Int J Oral Maxillofac Implants* 2018;33(5):1103–1111. DOI: 10.11607/jomi.6363.
41. Cepa S, Koller B, Spies BC, et al. Implant-retained prostheses: ball vs conus attachments – a randomized controlled clinical trial. *Clin Oral Implants Res* 2017;28(2):177–185. DOI: 10.1111/clr.12779.
42. Gholami H, Mericske-Stern R, Kessler-Liechti G, et al. Radiographic bone level changes of implant-supported restorations in edentulous and partially dentate patients: 5-year results. *Int J Oral Maxillofac Implants* 2014;29(4):898–904. DOI: 10.11607/jomi.3042.



43. Patil PG, Nimbalkar-Patil S. A radiographic measurement technique for crest bone changes related to dental implants. *J Prosthet Dent* 2015;113(4):350–351. DOI: 10.1016/j.prosdent.2014.11.002.
44. Patil PG, Seow LL. Crestal bone-level changes and patient satisfaction with mandibular overdentures retained by one or two implants with immediate loading protocols: a randomized controlled clinical study. *J Prosthet Dent* 2020;123(5):710–716. DOI: 10.1016/j.prosdent.2019.07.015.
45. Cehreli MC, Karasoy D, Kökat AM, et al. A systematic review of marginal bone loss around implants retaining or supporting overdentures. *Int J Oral Maxillofac Implants* 2010;25(2):266–277. PMID: 20369084.
46. Walton TR, Layton DM. Intra- and inter-examiner agreement when assessing radiographic implant bone levels: differences related to brightness, accuracy, participant demographics and implant characteristics. *Clin Oral Implants Res* 2018;29(7):756–771. DOI: 10.1111/clr.13290.