

Effectiveness of Gelatin Sponge Along with i-PRF in Endodontically Involved Tooth with Grade II Furcation Defects: A Clinical and Radiographic Study

Annapurna Ahuja¹, Vipin Ahuja², Abhirup Saha³, Adya Singhal⁴, Tannu Priya⁵, Avishek Bhattacharjee⁶

ABSTRACT

Aim: To evaluate the effectiveness of gelatin sponge [Abgel] with injectable platelet-rich fibrin (i-PRF) in the surgical treatment of mandibular Grade II furcation defects in endodontically involved teeth.

Materials and methods: The present study was a single-center clinical trial wherein 20 mandibular grade II furcation defects were treated with gelatin sponge combined with i-PRF results were compared both clinically and radiographically at baseline, 3, and 6 months postoperatively. Statistical analysis was done using Statistical package for social sciences (SPSS) we software. For pre and post comparison, paired t-test, analysis of variance (ANOVA) and Wilcoxon test were used.

Results: There was a statistically highly significant improvement seen in all the clinical parameters vertical clinical attachment level (V-CAL), horizontal clinical attachment level (H-CAL) and probing pocket depth (PPD) and radiographic parameters at baseline and 6 months postoperatively $p < 0.01$.

Conclusion: Open flap debridement along with Abgel combined with i-PRF is an effective treatment modality in reducing the horizontal and vertical component of grade II furcation defects.

Clinical significance: Gelatin sponge with i-PRF is a cost-effective treatment modality in achieving periodontal regeneration.

Keywords: Absorbable surgical gelatin sponge, Endodontically involved tooth, Furcation defect, Grade II furcation, Injectable platelet-rich fibrin, Regeneration of Bone.

The Journal of Contemporary Dental Practice (2022): 10.5005/jp-journals-10024-3449

INTRODUCTION

Periodontitis is a chronic inflammatory disease caused by microbial infection which affects the supporting tissues of teeth eventually leading to loss of alveolar bone and the supporting structures of the teeth.¹

The goal of periodontal therapy is to arrest the progression of the ongoing periodontal destruction and the regeneration of structures lost due to pre-existing disease processes. Conventional clinical therapy aims at eliminating infectious sources and reducing inflammation to arrest disease progression, which cannot achieve the regeneration of bone loss and other periodontal tissues. Regeneration is a complex process, which involves multiple cells and growth factors.² Several treatment modalities like open flap debridement with autograft, allograft, alloplastic, and guided tissue regeneration (GTR) membrane have been tried to treat bony defects like vertical defects, furcation involvement, etc., caused by periodontal diseases. However, recently, attention has shifted to the use of growth factors which are biologically active mediators that can regulate the proliferation, chemotaxis, and differentiation of the locally derived progenitor cells in the defect site. This helps in achieving bone regeneration and new attachment. Recently extensively studied and tested among these growth factors are autologous various preparations like platelet-rich plasma [PRP]/platelet-rich fibrin [PRF]. Platelet rich plasma (PRP) has been employed in reformative dentistry as a marvel. Platelet-rich fibrin preparations are in use in periodontics like titanium-prepared platelet-rich fibrin (T-PRF) and concentrated platelet-rich fibrin (C-PRF), etc., but in latest use of injectable platelet-rich fibrin (i-PRF) in periodontal

^{1,3-6}Department of Periodontology and Oral Implantology, Hazaribhag College of Dental Sciences & Hospital, Hazaribhag, Jharkhand, India

²Department of Pediatric and Preventive Dentistry, Government Dental College, Jamnagar, Gujarat, India

Corresponding Author: Annapurna Ahuja, Department of Periodontology and Oral Implantology, Hazaribhag College of Dental Sciences & Hospital, Hazaribhag, Jharkhand, India, Phone: +91 9910281333, e-mail: annapurna.ahuja@yahoo.com

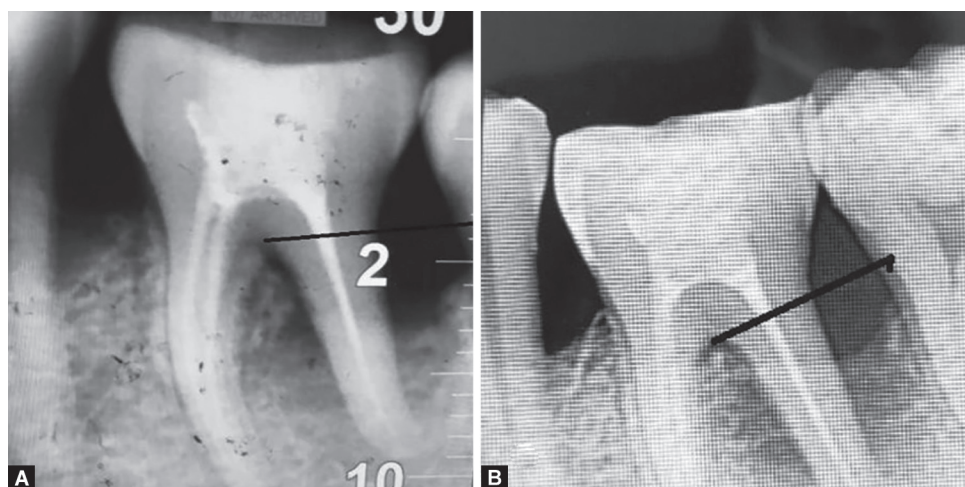
How to cite this article: Ahuja A, Ahuja V, Saha A, *et al.* Effectiveness of Gelatin Sponge Along with i-PRF in Endodontically Involved Tooth with Grade II Furcation Defects: A Clinical and Radiographic Study. *J Contemp Dent Pract* 2022;23(12):1199–1202.

Source of support: Nil

Conflict of interest: None

regeneration has drawn the attention of various researchers. Injectable platelet-rich fibrin is an autologous second-generation fibrin, with three dimensional fibrin meshwork resembling that of a PRF clot. Injectable platelet-rich fibrin predominantly has collagen type-1, lymphocytes along with its growth factors.³

Latest studies claim that hemostatic representatives endorse periodontal regeneration and can act as active bone graft alternative. Absorbable surgical gelatin sponge (Abgel) has proven to be a good and clinically safe biomaterial for the controlled release of growth factors, e.g., Bone morphogenetic protein (BMP), platelet derived growth factor (PDGF), and transforming growth factor beta (TGF- β) in the blood clot which may exert biological



Figs 1A and B: IOPA radiograph (A) Preoperative radiograph at baseline (B) Postoperative radiograph after 6 months

activities and promote tissue regeneration at surgical sites. Absorbable gelatin is a water-insoluble, off-white, nonelastic, porous, pliable product prepared from purified porcine skin.⁴ But there is the scarcity of published data proving the same on furcation defects, which are difficult to treat because of their complex anatomy. Hence, the present study has been undertaken to evaluate the effectiveness of an Abgel with i-PRF in the surgical treatment of mandibular grade II furcation defects in endodontically involved mandibular molars.

MATERIALS AND METHODS

This single-center trial was conducted from January 2022 to December 2022. Institutional ethical board approval was taken prior to the commencement of the study. Patients, aged between 25 and 55 were recruited from the outpatient section of the Department of Periodontology and Oral Implantology, Hazaribag College of Dental Sciences & Hospital, Hazaribagh. Patients were selected based on the American Academy of Periodontology Criteria 1999, 15 Patients with a minimum of 20 teeth and having an endodontically involved first or second molar tooth in mandibular arch showing the periodontal probing depth of >3 mm with radiographic evidence of horizontal and vertical inter-radicular bone loss were selected for the study. Before recruiting patients, informed consent was taken. Patients with systemic diseases, lactating mothers, pregnant ladies, smokers, and patients with aggressive periodontitis were excluded. Stent was prepared for the selected endodontically involved mandibular molar tooth with grade II furcation defect and vertical clinical attachment level (V-CAL) and probing pocket depth (PPD) were measured with UNC 15 probe, horizontal clinical attachment level (H-CAL) was measured with graduated Naber's probe⁵ and intra oral periapical radiograph (IOPA) was taken at baseline. After complete endodontic treatment, baseline plaque index (Silness and Loe) was recorded. The case was prepared by doing thorough ultrasonic scaling for the entire mouth and root planing (SRP) of endodontically involved tooth with the horizontal and vertical bone loss (test site). After 2 weeks of basic therapy, open flap debridement was done. Anesthesia was achieved by using 2% lignocaine with adrenaline (1:200,000). The mucoperiosteal flap was elevated for the test site. The Abgel was cut into small pieces (less than 1 mm²) and kept in a sterile dampen dish.

Preparation of i-PRF

Injectable platelet-rich fibrin was prepared as per the protocol put forth by Chokroun et al. A total of 10 mL venous blood was

drawn from the antecubital fossa, and transferred to a plastic tube without any anticoagulants, tube containing the blood was centrifuged at 700 rpm for 3 minutes at 60 × g at room temperature in a centrifugal machine, to get top liquid layer of injectable PRF.⁶ This liquid was collected with a 2 mL syringe and mixed with gelatin sponge pieces (Abgel Healthium Medtech Pvt Ltd) kept in a sterile dampen dish. Wait until i-PRF gets absorbed completely by sponge, then after thorough debridement of grade II furcation defect, irrigate the area with normal saline, mucoperiosteal flaps were pre-sutured with 3-0 black silk sutures, and then gelatin sponge pieces with i-PFR were condensed into the furcation defects until the entire furcation area was covered. Knots were tied, a flap was secured. The periodontal dressing was given. Oral hygiene instructions were given, and patients were instructed about the use of mouthwash 0.12% chlorhexidine 10 mL twice a day and the use of a soft toothbrush for teeth cleaning. Antibiotics were prescribed (Amoxycillin 500 mg, twice a day) for five days. Patients were recalled after eight days for suture removal and for re-evaluation. After that patients were again recalled after 3 and 6 months for clinical and radiographic evaluation. According to the study protocol "long cone paralleling technique using intraoral direct digital periapical Radio-visiograph" (Fig. 1). Surgical treatment and follow-up recording were done by two allotted investigators to avoid any bias.

Statistical Analysis

Statistical package for social sciences (SPSS) was used for analysis. Paired t-test was used to compare all the parameters between different time frames within the group.

RESULTS

About 20 endodontically involved mandibular molar teeth with grade II furcation defects were recruited in this study. There were 6 male and 7 female patients among the selected subjects. There was a statistically highly significant reduction observed in H-CAL (Table 1) from baseline to 3 and 6 months, with mean values of 2.85 ± 0.57, 2.4 ± 0.56, and 1.75 ± 0.42 respectively. The mean reduction in H-CAL from baseline to 3 and baseline to 6 months was statistically highly significant with the *p*-value of 0.0003 (< 0.001).

Table 2 shows (V-CAL) in mm with the mean values of 6.3 ± 0.82, 4.7 ± 1.05, and 3.3 ± 1.15 at baseline, 3 months, and 6 months

Table 1: Comparison of mean horizontal clinical attachment (H-CAL in mm) at baseline, after 3 months and after 6 months after applying ANOVA test

Group	Mean percentage of completely occluded dentinal tubules (Mean ± SD)	F value	p-value
At baseline	2.85 ± 0.57	10.93	0.0003
After 3 months	2.4 ± 0.56		(<0.001)
After 6 months	1.75 ± 0.42		Very highly significant

Table 2: Comparison of mean vertical clinical attachment (V-CAL in mm) at baseline, after 3 months and after 6 months after applying ANOVA test

Group	Mean Percentage of Completely occluded dentinal tubules (Mean ± SD)	F value	p-value
At baseline	6.3 ± 0.82		0.000
After 3 months	4.7 ± 1.05	21.49	(<0.001)
After 6 months	3.3 ± 1.15		Very highly significant

Table 3: Comparison of mean probing pocket depth (PPD in mm) at baseline, after 3 months and after 6 months after applying ANOVA test

Group	Mean percentage of completely occluded dentinal tubules (Mean ± SD)	F value	p-value
At baseline	6.3 ± 0.82		0.001
After 3 months	4.4 ± 0.84	40.03	(<0.001)
After 6 months	3.0 ± 0.81		Very highly significant

respectively, with *p*-value of 0.003 (<0.001) which was statistically highly significant.

Table 3 shows a comparison of mean PPD in mm at the baseline, after 3 months, and after 6 months after applying the analysis of variance (ANOVA) test. There were statistically highly significant results were seen from baseline to 6 months, with mean values of 6.3 ± 0.82, 4.4 ± 0.84, and 3.0 ± 0.81, at baseline, 3 months, and at 6 months respectively, which was statistically highly significant with the *p*-value of 0.001 (<0.001) radio graphically bone fill was observed. Figure 1A showing preoperative radiograph at baseline showing grade II furcation involvement with a bone loss involving inter-radicular space and distal root.

Figure 1B shows postoperative radiograph after 6 months showing bone fill, covering the inter-radicular area and distal root, which was similar and correlates to the clinical findings. The mean plaque index scores (Fig. 2) before intervention were 1.53 at the baseline. Six months post-intervention shows a significant reduction, i.e., 0.99.

Results of this present single-center comparative evaluation study were based on data obtained from baseline, 3 and 6 months. This shows a statistically significant improvement in all-encompassed clinical parameters like V-CAL, PPD, and H-CAL. There

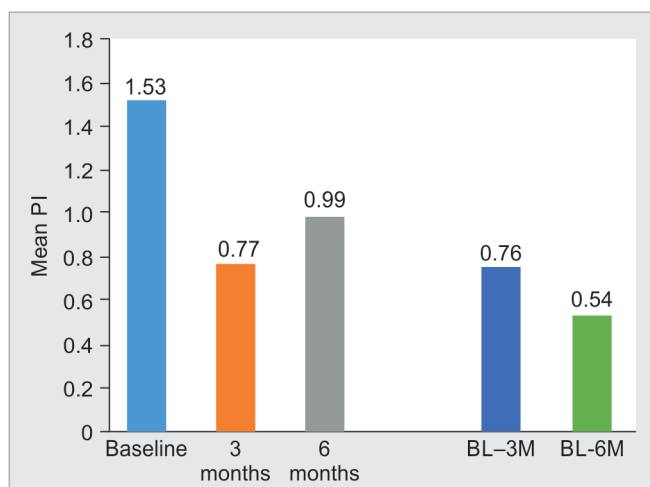


Fig. 2: Comparison of mean scores in plaque index at baseline, 3 months and 6 months

was radio graphically evident bone regeneration from baseline to 6 months after the surgical procedures.

DISCUSSION

Among the various periodontal defects, the management of furcation involvement is the most difficult and complex, because of the anatomical characteristics and morphological structure. The ultimate goal of furcation therapy is to completely close the furcation, thereby returning the tooth to anatomic normalcy, facilitating long-term maintenance, and thus improving the likelihood of tooth retention.

Bone grafting has been widely used in reconstructive periodontal surgery, to fill osseous defects and enable regeneration. Now recently researchers are trying to use alternative material for this purpose. One among them is gelatin sponge hemostatic. The clinical results of various published case reports suggest that Abgel might function as a scaffold for growth factors, and act as a filler to prevent the growth of soft tissue into the periodontal defect Kabashima et al.,⁷ in another case report it was documented that, satisfactory defect fill was achieved with the use of Abgel.⁸ Another study was done by Sunil S and Babu HM⁹ to evaluate the bone regeneration in endodontically involved tooth where root resection was done, and the combined effects of Abgel mixed with hydroxyapatite and β-tricalcium phosphate (β-TCP) showed radiologically evident defect fill after 6 months. This was similar to the present study.

In another study done by Thirumala Sriya¹⁰ a statistically significant improvement in clinical parameters was observed. Absorbable surgical gelatin sponge (Abgel) and β-TCP were effective in improving regenerative outcomes when used in human intra-bony defects.

Studies have proven that a bone graft when used with platelet concentrates yields better regeneration in intra-bony defects. Platelet-rich plasma (PRP) has been utilized in regenerative dentistry as an autologous growth factor capable of stimulating tissue regeneration. Despite this, concerns have been expressed regarding the use of anti-coagulants. A liquid formulation of PRF termed i-PRF without the use of anti-coagulants is gaining popularity to overcome the shortcoming of Standard PRP. In a study done by Miron RJ et al. Standard PRP and i-PRF were compared for growth

factor release. Injectable platelet-rich fibrin showed significantly higher levels of total long-term release of growth factors after ten days. It also induced higher fibroblast migration.⁶

An *in-vitro* study conducted by Wang X et al. where human primary osteoblasts were cultured with either i-PRF or PRP. Investigations were done for migration assay as well as a cell adhesion/proliferation assay. A significant increase in messenger RiboNucleic Acid (mRNA) levels of alkaline phosphatase (ALP), Runx2, and osteocalcin, as well as immunofluorescent staining of osteocalcin was also observed in the i-PRF group when compared to PRP. This proves the regenerative potential of i-PRF.¹¹

Uma P Nair et al.¹² published their clinical study data, done on furcation defects using i-PRF with a nano-hydroxyapatite bone graft, and nano hydroxyapate alone. They concluded that i-PRF incorporated bone graft showed better results, in terms of clinical attachment gain, probing pocket depth reduction, and radiographic bone fill after 9 months. This was similar to this current study.

Studies have shown that i-PRF is rich in growth factors, antimicrobial proteins, complement-binding proteins, and antimicrobial peptides.¹³

Raj et al. used a “sticky bone” mixture of the graft with i-PRF in an endodontic periapical lesion case along with a collagen membrane for regeneration. The result showed a reduction in the probing depth by 5 mm and satisfactory bone formation at the end of 6 months, this was also comparable to the present study.¹⁴

Another study done by Sonale M et al.¹⁵ concluded that Abgel group when compared with β -TCP showed a statistically significant mean increase in bone height after 5 months postoperative evaluation in immediate implant placement.

To date no published data are available on i-PRF mixed with Abgel on endodontically involved teeth with furcation defects. The study looked at the regenerative adequacy of i-PRF with Abgel in the treatment of mandibular grade II furcation. The outcomes showed a greater clinical as well as radiographical improvement from baseline to 6 months. This study concludes that i-PRF along with Abgel can be viewed as a promising material in advancing periodontal tissue regeneration.

The limitations of the study included the small sample size, no histological determination of the new bone regeneration and no long-term follow-up. Within these limitations, the results of this study suggested that Abgel is quite predictable when used with i-PRF. However, further investigation with a larger sample size on a prolonged postoperative follow-up is required to conclusively establish the outcome of this study. Along with bone regeneration, any evidence of cementogenesis and regeneration of the attachment apparatus should be taken up in future studies.

CONCLUSION

This current study gives us a new cost-effective treatment modality for endodontic periapical lesions. Achieving bone regeneration in the furcation region is technique sensitive because of its complex anatomy. Previous studies using bone grafts and GTR membranes did achieve periodontal regeneration, but this present study used

cost-effective and easily available materials that can be considered in day-to-day practice, to render the regenerative treatment to people to cannot afford costly surgical procedures.

REFERENCES

1. Porciuncula HF, da Porciuncula MM, Zuza EP, et al. Biometric analysis of the maxillary permanent molar teeth and its relation to furcation involvement. *Braz Oral Res* 2004;18(3):187–191. DOI: 10.1590/s1806-83242004000300002.
2. Gotlow J, Nyman S, Karring T, et al. New attachment formation in human periodontium by guided tissue regeneration. *J Clin Periodontol* 1984;13(6):494–503. DOI: 10.1111/j.1600-051x.1986.tb00854.x.
3. Hamid O, Quinlan DJ, Seemann R, et al. Injectable platelet-rich fibrin for perioral rejuvenation as assessed by 3D lip volume imaging. *J Cosmet Dermatol* 2021;20(10):3270–3277. DOI: 10.1111/jocd.14394.
4. Kabashima H, Sakai T, Mizobe K, et al. The usefulness of an autologous blood clot combined with gelatin for regeneration of periodontal tissue. *J of Oral Sci* 2013;55(4):363–366. DOI: 10.2334/josnusd.55.363.
5. Carranza FA, Takei HH, Newman MG, et al. *Carranza's Clinical Periodontology*, 10th edition. United Kingdom: Saunders Elsevier; 2006. p. 1286.
6. Miron RJ, Fujioka-Kobayashi M, Hernandez M, et al. Injectable platelet rich fibrin (i-PRF): Opportunities in regenerative dentistry? *Clin Oral Investig* 2017;21(8):2619–2627. DOI: 10.1007/s00784-017-2063-9.
7. Kabashima H, Sakai T, Mizobe K, et al. The usefulness of an autologous blood clot combined with gelatin for regeneration of periodontal tissue. *J Oral Sci* 2013;55(4):363–366. DOI: 10.2334/josnusd.55.363.
8. KI Vandana, Ryana H, Dalvi PJ. Autologous periodontal stem cell assistance in periodontal regeneration technique (SAI-PRT) in the treatment of periodontal intrabony defects: A case report with one-year follow-up. *J Dent Res Dent Clin Dent Prospects* 2017;11(2): 123–126. DOI: 10.15171/joddd.2017.022.
9. Sunil S, Babu HM. A modified method for bone regeneration using gelatin sponge with bone graftin treating an osseous defect after root resection. *J Health Sci Res* 2017;8(2):80–83. DOI:10.5005/jp-journals-10042-1055.
10. Sriya T, Koduganti RR, Gireddy H, et al. “Efficacy of gelatin sponge vs beta tricalcium phosphate as regenerative materials in periodontal intra bony defects - An interventional clinical and radiological”. *IJDSIR* 2021;4(4):431–441. ISSN: 2581-5989.
11. Wang X, Zhang Y, Choukroun J, et al. Effects of an injectable platelet-rich fibrin on osteoblast behavior and bone tissue formation in comparison to platelet-rich plasma. *Platelets* 2018;29(1):48–55. DOI: 10.1080/09537104.2017.1293807.
12. Nair UP, Shivamurthy R, Nagate RR, et al. Effect of injectable platelet-rich fibrin with a nano-hydroxyapatite bone graft on the treatment of a grade II furcation defect. *Bioengineering (Basel)* 2022;9(11):602. DOI: 10.3390/bioengineering9110602.
13. Blair P, Flaumenhaft R. Platelet alpha-granules: Basic biology and clinical correlates. *Blood Rev* 2009;23(4):177–189. DOI: 10.1016/j.blre.2009.04.001.
14. Raj R, Gayathri GV, Shejali J, et al. Injectable platelet-rich fibrin-“A quicker therapeutic aid” in the treatment of combined endo-perio lesion: A case report. *Int J Med Dent Case Rep* 2020;7(1): 1–4. DOI:10.15713/ins.ijmdcr.134.
15. Sonale MN Sushma, Krishnappa Ranganath, Shetty Vibha, Prasad Kavitha, Lalitha RM. Absorbable gelatin sponge vs alloplastic graft material as adjuvants in direct sinus lift procedures – A comparative study. *J of Dent Oro fac Res* 2018;14(1):7–17.