



## Comparative Evaluation of Guided Tissue Regeneration with use of Collagen-based Barrier Freeze-Dried Dura Mater Allograft for Mandibular Class 2 Furcation Defects (A Comparative Controlled Clinical Study)

Sandeep Patel, Ajay Kubavat, Brijesh Ruparelia, Arvind Agarwal, Anup Panda

### ABSTRACT

**Aim:** The aim of periodontal surgery is complete regeneration. The present study was designed to evaluate and compare clinically soft tissue changes in form of probing pocket depth, gingival shrinkage, attachment level and hard tissue changes in form of horizontal and vertical bone level using resorbable membranes.

**Materials and methods:** Twelve subjects with bilateral class 2 furcation defects were selected. After initial phase one treatment, open debridement was performed in control site while freeze-dried dura mater allograft was used in experimental site. Soft and hard tissue parameters were registered intrasurgically. Nine months reentry ensured better understanding and evaluation of the final outcome of the study.

**Results:** Guided tissue regeneration is a predictable treatment modality for class 2 furcation defect. There was statistically significant reduction in pocket depth as compared to control ( $p < 0.01$ ). There is statistically significant increase in periodontal attachment level within control and experimental sites showed better results ( $p < 0.01$ ). For hard tissue parameter, significant defect fill resulted in experimental group, while in control group, less significant defect fill was found in horizontal direction and nonsignificant defect fill was found in vertical direction.

**Conclusion:** The results showed statistically significant improvement in soft and hard tissue parameters and less gingival shrinkage in experimental sites compared to control site.

**Clinical significance:** The use of FDDMA in furcation defects helps us to achieve predictable results. This cross-linked collagen membrane has better handling properties and ease of procurement as well as economic viability making it a logical material to be used in regenerative surgeries.

**Keywords:** FDDMA, Collagen membrane, Periodontal regeneration.

**How to cite this article:** Patel S, Kubavat A, Ruparelia B, Agarwal A, Panda A. Comparative Evaluation of Guided Tissue Regeneration with use of Collagen-based Barrier Freeze-Dried

Dura Mater Allograft for Mandibular Class 2 Furcation Defects (A Comparative Controlled Clinical Study). *J Contemp Dent Pract* 2012;13(1):11-15.

**Source of support:** Nil

**Conflict of interest:** None declared

### INTRODUCTION

The aim of periodontal surgery is removal of inflammatory component of periodontal disease. Previous periodontal surgical procedures resulted in healthy but compromised situation. With the advent of new surgical procedures and biomaterials, we now aim at not only arresting periodontal disease activity, but also regeneration of periodontium in normal anatomical and functional relationship.<sup>1,2</sup>

The goal of periodontal therapy is redefined now as complete regeneration of lost periodontal support (world workshop of clinical periodontics 1989), the regeneration requires three tissues to be finely integrated namely cementum periodontal ligament and alveolar bone. This selective repopulation of cells was termed by Gottlow as guided tissue regeneration (GTR).<sup>3-5</sup>

The GTR technique required biologically inert materials which did not hamper the healing process.<sup>6</sup> The first generation material used was ePTFE (expanded poly tetra fluoro ethylene).<sup>3</sup> This material was nonresorbable and surgical reentry was required which would disturb the delicate healing process.<sup>7-9</sup>

This prompted the introduction of second generation resorbable membranes. Although other second generation materials are available,<sup>3</sup> their use is restricted by high cost, especially in a third world country like India. On the other hand collagen-based allograft like freeze-dried dura mater

allograft (FDDMA) is easily available from suitable donors at various mortuaries of general hospitals. Based on these considerations, a study was designed to evaluate clinically FDDMA in human furcation defect. Furcation maintenance can be tricky and unpredictable and hence we need to aim at complete obliteration of the defect.<sup>4,10</sup>

## AIMS AND OBJECTIVES

1. To evaluate and compare clinically soft tissue changes in form of probing pocket depth, gingival shrinkage, vertical attachment level, horizontal attachment level using GTR in mandibular class 2 molar furcations.
2. To evaluate and compare clinically hard tissue changes in the form of vertical and horizontal bone level using GTR in mandibular class 2 molar furcations.

## MATERIALS AND METHODS

In the present clinical study, 12 patients were selected for the study who had bilateral furcation defect in mandibular molars. Six female and male subjects participated in the study with the age ranging from 30 to 47 years.

In the present study, soft and hard tissue parameters were measured at initial and 9 months reentry.<sup>11</sup>

A silver amalgam restoration on the buccal surface along with cemento-enamel junction (CEJ) was used as a reproducible reference point.

Soft tissue parameters are in form of as follows:<sup>12</sup>

- a. Probing pocket depth (PPD)
- b. Gingival shrinkage (GS)
- c. Probing attachment levels (vertical)—PAL-V
- d. Probing attachment levels (horizontal)—PAL-H

## SURGICAL PROCEDURE

In patients with bilateral defects, left side was assigned as experimental and right side as control. The control site was treated with open debridement while experimental sites were treated with collagen-based membrane FDDMA.

The material used in this study was procured from tissue bank associated with Tata Memorial Hospital, Mumbai.

After local anesthesia, sulcular incisions were given to raise mucoperiosteal flap.<sup>13</sup> This was followed by defect preparation which includes removal of granulation tissue, scaling and root planing.

*Intrasurgical measurement:* After bleeding was arrested the horizontal bone level was recorded using an endodontic rubber stopper on the periodontal probe and vertically measured from reference point to the base of the defect.<sup>14,15</sup>

The placement of the membrane is such that it covers the buccal entrance of furcation at CEJ, mesiobuccal line angle of mesial root and distobuccal line angle of distal root and approximately 5 mm of alveolar bone apical to alveolar crest. The suturing of the membrane was carried out using sling suturing technique.<sup>12</sup>

Coronal positioning of the flap was carried out to cover the membrane by performing horizontal releasing incision through the periosteum on the inner aspect of the flap.<sup>12</sup>

Surgical reentry was done at the end of the study to expose the defects for direct visualization and assessment of the repair. Hard tissue measurements were taken following the previous guidelines.<sup>16,17</sup>

## RESULTS

For studying, the changes in various parameters from baseline to 9 months paired t-test was used. For between the groups comparison from base line to 9 months student t-test was used.

The Table 1 shows mean and standard deviation of preoperative and postoperative and change scores of probing pocket depth for both treatment groups. The above data shows that there is statistically significant decrease in probing depth from preoperative to 9 months in both the treatment groups. Between the groups comparison is also statistically significant.

The Table 2 shows mean and standard deviation in control and experimental groups at preoperative and

**Table 1:** Comparison of mean change of PPD (probing pocket depth) from preoperative to 9 months

Group	Preoperative (Mean ± SD)	9 months (Mean ± SD)	Mean change	
Control	3.8 ± 0.788	2.6 ± 0.516	1.3 ± 0.67	**
Experiment	4.4 ± 0.516	2.1 ± 0.316	2.3 ± 0.483	**

\*\* : P < 0.01 (Highly significant)

**Table 2:** Comparison of mean change in clinical probing attachment level vertical (PAL-V)

Group	Preoperative (Mean ± SD)	9 months (Mean ± SD)	Mean change	
Control	2.7 ± 0.483	2.1 ± 0.567	0.7 ± 0.674	* **
Experiment	2.8 ± 0.421	1.4 ± 0.516	1.5 ± 0.527	**

\* : P < 0.05 (Significant); \*\* : P < 0.01 (Highly significant)

9 months. Within the group comparison shows significant gain in clinical probing attachment—vertical in both control and experimental groups. The gain in clinical attachment level (CAL) is significant when two groups were compared.

The Table 3 shows mean and SD of gingival shrinkage at preoperative and 9 months and mean change for treatment groups. The above observation reveals that GS in both the groups is statistically significant. Comparison between the groups also shows significant change. The inference is that gingival shrinkage is significantly less in experimental group.

Table 4 shows mean and SD of probing attachment gain at 9 months in control and experimental sites. There is statistically significant gain in probing attachment level in both groups. Also between the groups comparison is statistically significant.

The Table 5 shows mean and SD of vertical defect fills at initial and surgical reentry. There is statistically significant gain in experimental site and insignificant gain in experimental sites. Between the groups comparison is statistically significant.

The Table 6 shows mean and SD of horizontal defect fill at initial and surgical reentry. There is statistically significant gain in experimental site and insignificant gain in experimental sites. Between the groups comparison is statistically significant.

Graph 1 shows comparison of mean change of PPD, PAL-V, PAL-H and gingival shrinkage while Graph 2 shows comparison of mean change of vertical and horizontal defect fill. All the parameters were recorded at baseline and finally at the end of 9 months .

## DISCUSSION

Collagen being a natural structural protein has always remained an attractive option in biotechnology. Collagen membranes possess unique properties that make them ideal for GTR procedures. These properties are in form of hemostasis, chemotaxis, ease of manipulation and integration with gingival connective tissue.<sup>18-20</sup>

Collagen used in periodontal regeneration are cross-linked. Cross-linking between fibrils helps the delay of resorption to 6 to 8 weeks thus fulfilling the criteria of an augmentation material.<sup>21-24</sup> The present study compared the use of FDDMA in comparison with open debridement procedure. The closure of the flap was coronally displaced to ensure least exposure of the barrier membrane.<sup>9</sup>

In the present study, the reduction in probing depth was  $2.3 \pm 0.483$  mm in experimental site while  $1.3 \pm 0.67$  mm on control site. This results are in agreement with Wang et al<sup>15</sup> who observed a reduction of  $2.84 \pm 0.41$  mm in experimental sites. Gingival shrinkage, reduced inflammation or improvement in the soft tissue attachment

**Table 3:** Comparison of mean gingival shrinkage from preoperative to 9 months

Group	Preoperative (Mean $\pm$ SD)	9 months (Mean $\pm$ SD)	Mean change	
Control	3.6 $\pm$ 0.516	4.9 $\pm$ 0.561	1.3 $\pm$ 0.483	** , *
Experiment	3.4 $\pm$ 0.516	4.3 $\pm$ 0.674	0.9 $\pm$ 0.316	**

\*: P < 0.05 (Significant); \*\*: P < 0.01 (Highly significant)

**Table 4:** Comparison of mean change in horizontal probing attachment gain (PAL-H)

Group	Preoperative (Mean $\pm$ SD)	9 months (Mean $\pm$ SD)	Mean change	
Control	4.2 $\pm$ 0.788	3.4 $\pm$ 0.699	0.8 $\pm$ 0.632	* , **
Experiment	4.2 $\pm$ 1.135	2.4 $\pm$ 0.843	1.8 $\pm$ 0.788	**

\*: P < 0.05 (Significant); \*\*: P < 0.01 (Highly significant)

**Table 5:** Comparison of mean change in vertical defect fill from preoperative to 9 months

Group	Preoperative (Mean $\pm$ SD)	9 months (Mean $\pm$ SD)	Mean change	
Control	8.5 $\pm$ 0.707	8 $\pm$ 0.816	0.5 $\pm$ 0.527	**
Experiment	8.5 $\pm$ 1.080	7.4 $\pm$ 0.966	1.1 $\pm$ 0.316	*

\*: P < 0.05 (Significant); \*\*: P < 0.01 (Highly significant)

**Table 6:** Comparison of mean change in horizontal defect fill from preoperative to 9 months

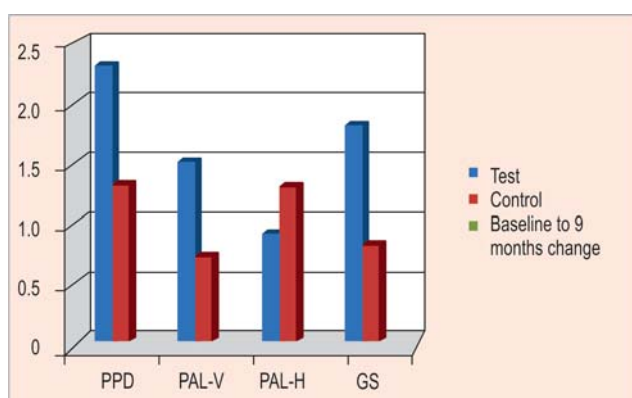
Group	Preoperative (Mean $\pm$ SD)	9 months (Mean $\pm$ SD)	Mean change	
Control	4.4 $\pm$ 0.516	3.7 $\pm$ 0.674	0.7 $\pm$ 0.483	* , **
Experiment	4.9 $\pm$ 0.567	2.8 $\pm$ 0.918	2.1 $\pm$ 0.737	**

\*: P < 0.05 (Significant); \*\*: P < 0.01 (Highly significant)

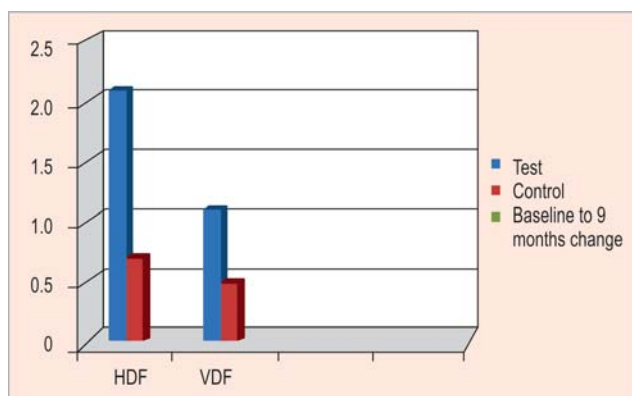
may have contributed in the results. Gingival recession is an unavoidable outcome of any procedure and it was measured at  $0.9 \pm 0.316$  mm which was better than the control site at  $1.3 \pm 0.48$  mm. Wang et al<sup>31</sup> noted a shrinkage of  $0.83 \pm 0.29$  mm in a 12 months study and our results were comparable with other researchers.<sup>7,8,16,26</sup>

Attachment level gains were significant at the experimental site and were comparable with other studies.<sup>15,16,25,27-29</sup> Horizontal furcation measurement proved to be important indicator of success of furcation treatment. Horizontal attachment was measured with the help of Nabers probe and the gain of attachment was  $1.8 \pm 0.788$  mm and  $0.8 \pm 0.632$  in experimental and control sites respectively. Vertical gain was in the form of  $1.5 \pm 0.527$  mm. Here, the use of pressure sensitive probe as well as stents would have increased the reproducibility of the measuring parameters.<sup>30</sup>

Clinical hard tissue measurements can be placed between noninvasive soft tissue measurements and hard tissue biopsies. The reentry is generally quick, less invasive and provides to the operator with direct visualization and assessment of the site. Thus a combination of soft and hard tissue measurements provide us with substantial information about the possible outcome.



**Graph 1:** Comparison of mean change of PPD, PAL-V, PAL-H and gingival shrinkage



**Graph 2:** Comparison of mean change of vertical and horizontal defect fill

The effect of collagen membrane was quite evident and the results were comparable with other researchers and substantial horizontal and vertical gain was observed. The positive effect of collagen was evident in form of  $2.1 \pm 0.737$  mm which was in agreement with results seen by others,<sup>20,23</sup> vertical defect fill was in form of  $1.1 \pm 0.316$  mm. In hard tissue measurements, factors that may contribute in the result variation are, probing methods, force used, time of reentry, alveolar crest resorption. Here, the last factor may be miscalculated as defect fill rather than actual gain.

## CONCLUSION

The following conclusions were drawn from the present study:

1. GTR is a realistic and predictable treatment modality for grade 2 furcations.
2. There was gingival shrinkage in both experimental and control sites.
3. There was statistically significant reduction in pocket depth as compared to control ( $p < 0.01$ ).
4. There is statistically significant increase in periodontal attachment level within control and experimental sites showed better results ( $p < 0.01$ ) for hard tissue parameter significant defect fill resulted in experimental group while in control group less significant defect fill was found in horizontal direction and nonsignificant defect fill was found in vertical direction.
5. The findings of this study yielded significantly greater improvement of parameters in experimental sites compared to open debridement.

## REFERENCES

1. Page RC. Periodontal therapy, prospects for future. *Journal of Periodontology* 1993;64:744-53.
2. Pontoriero R, Nyman S, Lindhe J, Rosenberg E. Guided tissue regeneration in treatment of furcation defects in man. *Journal of Clinical Periodontology* 1987;14:618-20.
3. Ellegard B, Karring TA, Loe H. New periodontal attachment procedure based on retardation of epithelia's migration. *Journal of clinical periodontology* 1974;1:75-88.
4. Glickman IC. Clinical periodontology classification of furcation involvement. WB Saunders Co 595-98.
5. Nyman, Karring, Lindhe, Rylander. New attachment following surgical treatment of human periodontal disease. *Journal of clinical periodontology* 1982;7:394-401.
6. Garrett S. Early wound healing stability and its importance in periodontal regeneration in periodontal regeneration. *Periodontal regeneration current status and Direction* 1995 (1st ed). Quintessence Publishing Co Inc.
7. Gottlow J, Laurell L. Treatment of furcation degree II involving human with bioresorbable and nonresorbable GTR devices. *J Dent Res* 1993;72:825.
8. Gottlow J. GTR using bioresorbable and nonresorbable devices initial healing and long-term results. *Journal of Periodontology* 1993;64:1157-65.

9. Poison A. Periodontal regeneration: Current status and direction (1st ed). Quintessence Publishing Co Inc 1995.
10. Donald Newell H. Current status of the management of teeth with furcation invasions. *Journal of Periodontology* 1981;52: 559-68.
11. Becker W, Becker B, Berg L. New attachment after treatment with root isolation procedure. Report of treated class III and class II furcation and vertical osseous defects. *Int J Perio Res Dent* 1988;8(3):9-23.
12. Caffesse RG, Quinones CR. GTR biological rationale, surgical technique and clinical results. *Compendium Conti Edu Dent* 1992;13:168.
13. Becker W, Caffesse Becker B. Root isolation for new attachment procedure a surgical and suturing method three case reports. *Journal of Periodontology* 1987;58:819-26.
14. Luepke, Mellonig, Burnsvold. A clinical evaluation of a bioresorbable barrier with or without DFBA in treatment of molar furcations. *JCP* 1997;24:440-46.
15. Wang, O'Neal. Evaluation of an absolute collagen membrane in treating class II furcation defects. *Journal of Periodontology* 1994;65:1029-36.
16. Lekovic, Koveevic. Evaluation of guided tissue regeneration in class 2 furcation defects: A clinical reentry study. *JOP* 1989;60: 694-98.
17. Lynch SE. Methods of evaluation of regenerative procedures.
18. Metzler, Mellonig, Gher. Clinical evaluation of GTR in the treatment of maxillary class 2 molar furcation invasions. *JOP* 1991;62:352-60.
19. Pintippa Bunyaratavej, Hom-Lay wang. Collagen membranes: A review. *Journal of Periodontology* 2001;72:215-29.
20. Von Swol, Ellinger RL, Pfeiffer, Blumenthal. Collagen membrane barrier therapy of GTR in class II functions in humans. *Journal of Periodontology* 1993;64:622-29.
21. Busschop J, De Boever J. Clinical and histological characteristics of lyophilized allogenic dura mater. Periodontal bony defects in humans. *Journal of Clinical Periodontology* 1983;10:399-411.
22. Minabe. A critical review of the biologic rationale of GTR. *JOP* 62:171-78.
23. Yukna RA. Clinical human comparison of ePTFE barrier membrane and freeze dried dura mater allograft for guided tissue regeneration of lost periodontology. 1992;63:431-41.
24. Yukna, Yukna. Multicenter evaluation of bio-absorbable collagen membrane for guided tissue regeneration in human class II furcations. *Journal of Periodontology* 1996;67:650-57.
25. Blumenthal. A clinical comparison of collagen membrane with ePTFE in the treatment of human class II furcation defects. *Journal of Periodontology* 1993;64:925-33.
26. Gottlow J, Nyman S, Lindhe J, Karring T. New attachment formation in the human periodontium by guided tissue regeneration case reports. *Journal of Clinical Periodontology* 1986;13:604-16.
27. Black BS, Gher Recharadson. Comparative study of collagen and ePTFE membrane in the treatment of human class II furcation defects. *Journal of Periodontology* 1994;65:598-604.
28. Bouchard, Nilveus RE. ePTFE and connective tissue grafts support bone regeneration for closing mandibular class II furcation. *Journal of Periodontology* 1993;64:1193-98.
29. Bower GM, Mellonig JT. Regenerating in clinical periodontal JADA 1990;121:497-502.
30. Philstrom. Measurement of attachment levels in clinical trials probing methods. *Journal of Periodontology* 1992;63:1072-77.

## ABOUT THE AUTHORS

### Sandeep Patel (Corresponding Author)

Professor and Head, Department of Periodontology, Narsinbhai Patel Dental College, Visnagar, Gujarat, India, Phone: +912765-222272 Fax: +912765-233008, e-mail: docsandip@yahoo.com

### Ajay Kubavat

Professor and Head, Department of Orthodontics, Narsinbhai Patel Dental College, Visnagar, Gujarat, India

### Brijesh Ruparelia

Professor and Head, Department of Prosthodontics, Narsinbhai Patel Dental College, Visnagar, Gujarat, India

### Arvind Agarwal

Professor and Head, Department of Oral and Maxillofacial Surgery Narsinbhai Patel Dental College, Visnagar, Gujarat, India

### Anup Panda

Professor, Department of Pedodontia, Padmashree DY Patil Dental College, Navi Mumbai, Maharashtra, India