



Increased Vertical Dimension of Occlusion: Signs, Symptoms, Diagnosis, Treatment and Options

José Augusto César Discacciati, Eduardo Lemos de Souza, Walison Arthuso Vasconcellos, Sérgio Carvalho Costa, Vinícius de Magalhães Barros

ABSTRACT

During the planning of oral rehabilitation, the vertical dimension of occlusion (VDO) is one of the first parameters to be measured since its improper restoration can lead to the failure of any prosthetic rehabilitation. A decreased VDO can lead to the appearance of lesions, such as angular cheilitis, facial disharmony, and temporomandibular disorders; meanwhile, an increased VDO may lead to the onset of joint and muscle pain, tension in functional speech, difficulty in swallowing, impaired chewing, tooth sensitivity due to traumatogenic forces, pathologic bone resorption, abnormal wearing of teeth, the appearance of an elongated face, and a facial expression of fatigue. Most scientific articles deal with methods and techniques for re-establishing VDO in edentulous patients or those who have lost their tooth reference due to prosthetic preparations. However, patients with increased VDO are also found in everyday practice. One treatment option for these patients is occlusal adjustment by selective tooth wear; it is still possible to perform orthodontic intrusion and/or orthognathic surgery in severe cases. The aim of this study was to discuss signs, symptoms, diagnosis, and treatment, and to report a clinical case of a patient with increased VDO.

Keywords: Vertical dimension, Facial pain, Occlusal adjustment.

How to cite this article: Discacciati JAC, de Souza EL, Vasconcellos WA, Costa SC, Barros VM. Increased Vertical Dimension of Occlusion: Signs, Symptoms, Diagnosis, Treatment and Options. *J Contemp Dent Pract* 2013;14(1): 123-128.

Source of support: Nil

Conflict of interest: None declared

INTRODUCTION

Good dentistry practice requires knowledge of diverse areas, such as semiotics, periodontics, esthetics, occlusion and dental materials. The establishment of the correct occlusal pattern is of utmost importance in the planning and management of patients undergoing oral rehabilitation. Before starting any treatment, the practitioner must consider

all physiological factors related to the occlusion: Vertical dimension, centric relation and anterior guidance.¹

During the planning of oral rehabilitation, the vertical dimension of occlusion (VDO) is one of the first parameters to be established; its determination is one of the most important stages of treatment since inadequate restoration can lead to the failure of prosthetic treatments.²⁻⁴

VDO is defined as the distance between the arches with the teeth in the centric or noncentric intercuspal position; it should be measured between 2 points—for example, from the nasion to the gnathion.⁵

According to Alonso et al⁶ changes in VDO can suppress or exacerbate the functional freeway space (FFS), which is the difference between the vertical dimension of rest position (VDR) and VDO and must be present in all situations. The FFS can vary between 1 and 9 mm depending on the occlusal pattern. In totally edentulous patients, VDO is estimated by subtracting the FFS from the VDR.

Decreased VDO may lead to the development of lesions such as angular cheilitis, disharmony of facial esthetics, and temporomandibular disorders; mean while an increase in VDO may lead to the onset of joint and muscle pain, difficulty in phonation and swallowing, impaired chewing, tooth sensitivity due to traumatogenic forces, pathologic bone resorption, abnormal wearing of the teeth, an elongated face, and a tired facial expression.^{7,8}

The development of methods for determining the correct distance from jaws remains a controversial topic in the literature. There are several proposed techniques regarding the restoration of the VDO; however, most of them are not scientifically accurate and none seem to be considered superior to the others.⁹

Most of these studies deal with methods and techniques for re-establishing the VDO of edentulous patients or those who have lost their reference tooth depending on the

prosthetic preparations. Furthermore, although patients with increased VDO are also encountered in everyday practice, they are not widely discussed in the literature. The aim of this study was to discuss signs, symptoms, diagnosis, and treatment of increased VDO, as well as present a clinical case report of a patient with this condition.

LITERATURE REVIEW

The VDO is established when occlusal contact occurs between the first deciduous molars at around 16 months of age. During growth, the muscular action balances the physiological eruption of teeth. Nevertheless, this balance may be disturbed by muscle growth, migration of muscle insertions, variations in neuromuscular function, functional problems, such as mouth breathing, and morphological or embryological problems such as short lingual frenum.¹⁰

The VDO can be divided into 3 classes according to the classification of Matsumoto.¹¹ Class I: the VDO is maintained by tooth contact; this situation extends from complete dental arches to the most extreme situation where only two antagonistic teeth are in contact. Class II: despite the presence of teeth, none of them come in contact with their antagonist; thus, the VDO cannot be maintained because there is no inter-arch contact. Class III: occlusal contact is totally absent as one of the arches is completely edentulous. Patients who use removable partial dentures (RPD) should also have their VDO evaluated without them.

Increased VDO can be established in two different ways: after the installation of dentures or due to the extrusion of posterior teeth, leading to an anterior open bite. After the diagnosis of increased VDO through a detailed examination assessing signs and symptoms including mounting casts in a semi-adjustable articulator (SAA), one of the treatment options is occlusal adjustment by selective grinding. In addition to occlusal stability in the centric relation position, this technique can provide a good disocclusion pattern since it favors the closure of anterior open bite as it decreases the VDO. Currently, orthodontic intrusion of molars with mini-plate or mini-implant anchorage can be an alternative treatment. In more severe cases, orthognathic surgery can produce good results.¹²

In general, the VDO of patients is increased during dental treatment to relieve pain and myofascial dysfunction, hide facial wrinkles, and treat deep overbite in cases of severe attrition or iatrogenesis.¹ Nevertheless, Ramjord and Ash¹³ state that this practice should be used with great caution because small or moderate increases in VDO may not produce significant changes in the stomatognathic system.

CASE REPORT

A 49-year-old patient reported masticatory muscle pain symptoms, constant headache, difficulty sleeping, phonetic

difficulty, and great difficulty chewing and swallowing. The patient reported being a mouth breather and having recurrent sinusitis. On clinical examination, we observed an elongated face and a tired facial expression (Fig. 1). He used 2 RPDs made 10 years earlier. Upon intraoral examination, teeth 14, 12, 11, 21, 22, 26, 37, 36, 35, 46 and 47 were absent. The patient also presented with an anterior open bite and the absence of anterior guidance (Fig. 2). In the centric occlusion, there was a single interocclusal contact occurring between teeth 18 and 48 and the complete absence of contacts on the left side (Figs 3 and 4). Without the RPD, there were only contacts on the right side (18 and 17 × 48) (Figs 5 and 6). During periodontal examination, teeth 18 and 17 presented deep pockets, furcation lesions, tooth mobility grade 3, and substantial bone loss (Fig. 7). In these teeth were also observed signs of occlusal trauma. The association of periodontitis and occlusal trauma lead to teeth migration because of lack of bone support resulting major occlusal discrepancies between centric relation and centric occlusion and alteration of VDO. The other teeth did not

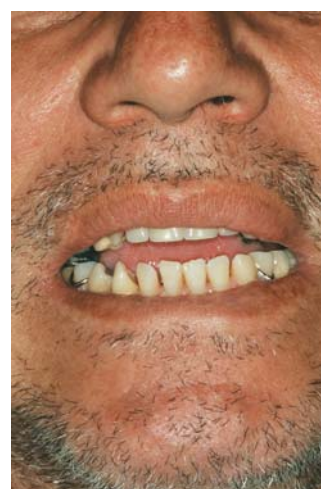

Fig. 1: Initial situation: Face too elongated and expression of tiredness

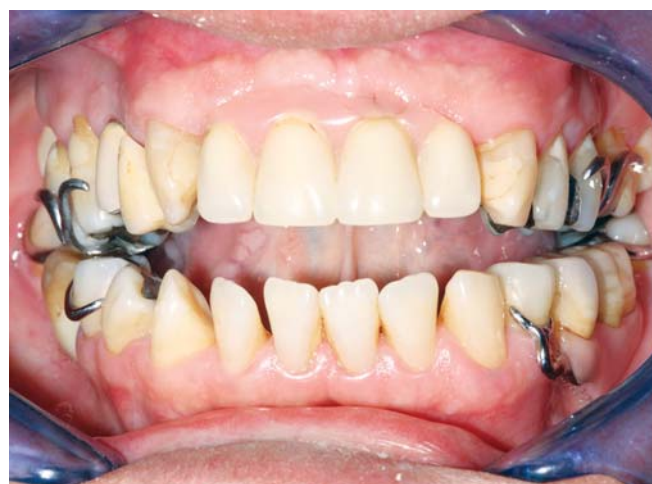

Fig. 2: Open anterior bite and absence of anterior guidance

present any sign of periodontitis: Increased probing depth, bleeding on probing or tooth mobility. To confirm the diagnosis and clinical definition of an appropriate treatment plan, dental casts were mounted on an SAA in centric relation following the principles of the philosophy employed.¹ With the casts as well as the exams, all of the variables measured in the mouth could be re-evaluated

(Fig. 8). An occlusal adjustment was then performed by the selective grinding of the casts, and good occlusal stability in the centric relation and anterior guidance within a new VDO were achieved. The final diagnosis of increased VDO class I¹¹ was confirmed with great pain symptoms and periodontal involvement in upper-right hemiarch. We decided to restore the physiological principles of occlusion

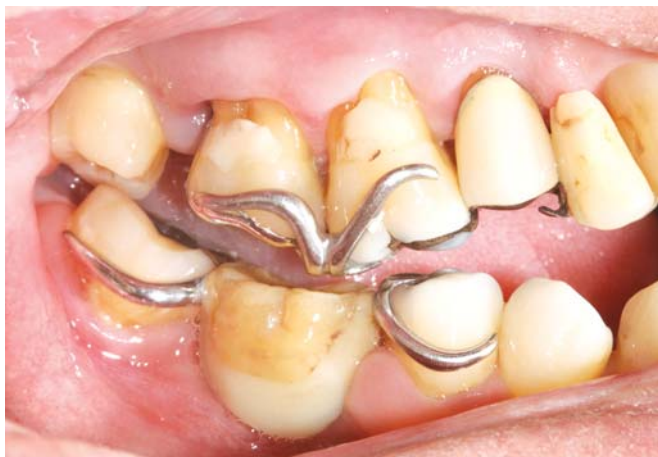

Fig. 3: Single interocclusal contact in centric occlusion (between 18 and 48)

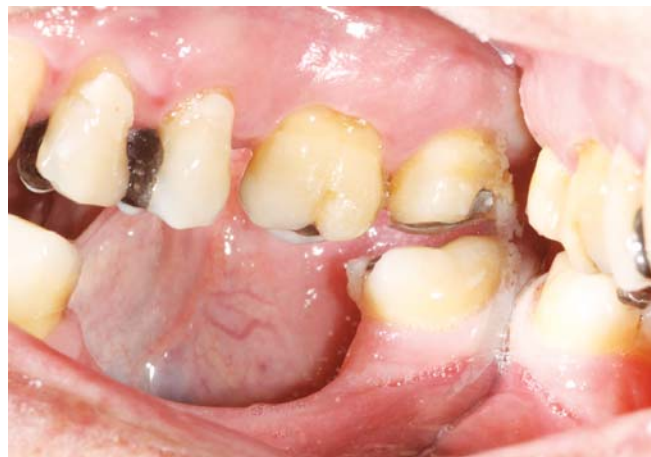

Fig. 6: Without the RPD, absence of contacts on the left side

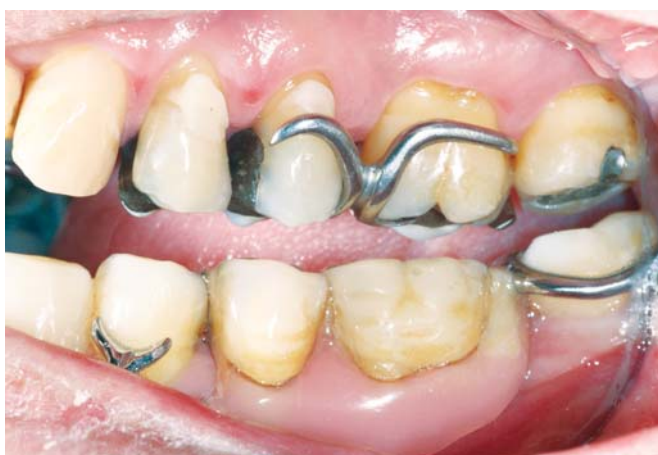

Fig. 4: Absence of contacts on the left side

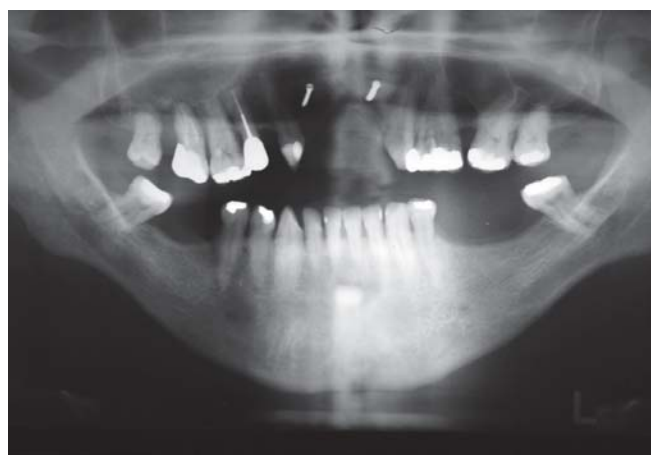

Fig. 7: Great bone loss on the right posterior

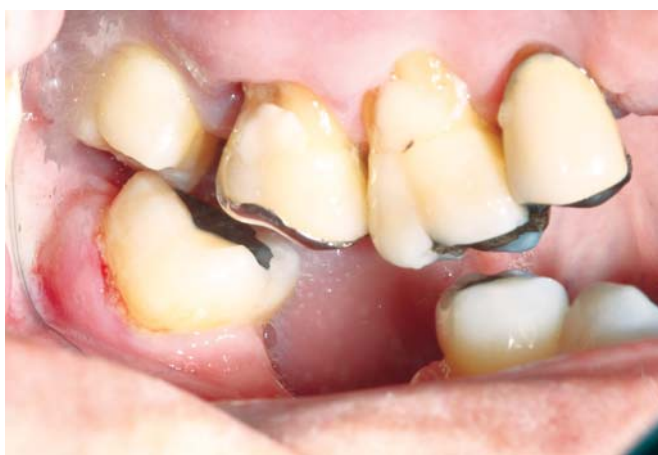

Fig. 5: Without the RPD, only contacts on the right side were observed (18 and 17 × 48)

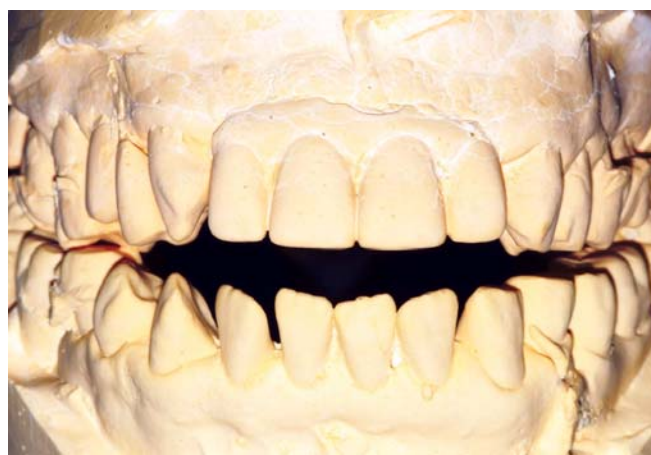

Fig. 8: Dental casts mounted in a semi-adjustable articulator

starting with decreasing the VDO while improving esthetics, function and comfort. Depending on the condition presented, teeth 18 and 17 were extracted and the clamp right of the RPD was partially removed since, this appliance would continue to be used by the patient for esthetic reasons. After this intervention, there was an immediate significant reduction in VDO (Fig. 9). After 7 days, the patient reported a significant improvement in pain symptoms. Fifteen days

later, we conducted an occlusal adjustment by selective grinding to reduce the anterior open bite and increase the occlusal stability (Fig. 10) as been simulated in the casts. In addition, the right clasp of the RPD was completely removed (Figs 11 to 13). With these procedures, the coupling of the anterior teeth was possible, which provided anterior guidance and stability in the centric occlusal relation in the patient (Figs 14 and 15). After these procedures, the

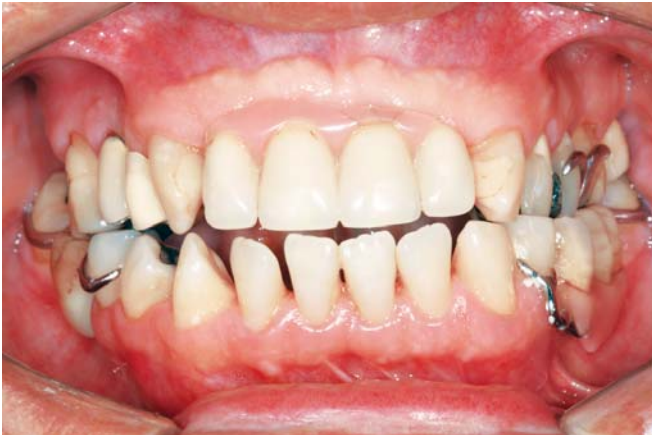

Fig. 9: Significant reduction in VDO after the extraction of 18 and 17 and partial removal of the RPD clamp

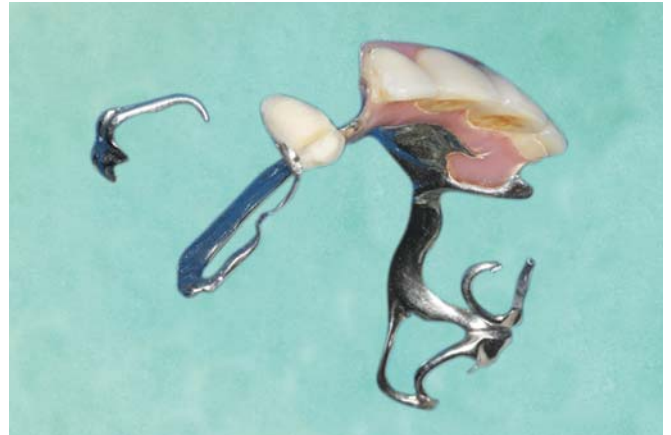

Fig. 12: Complete removal of the right superior RPD clamp

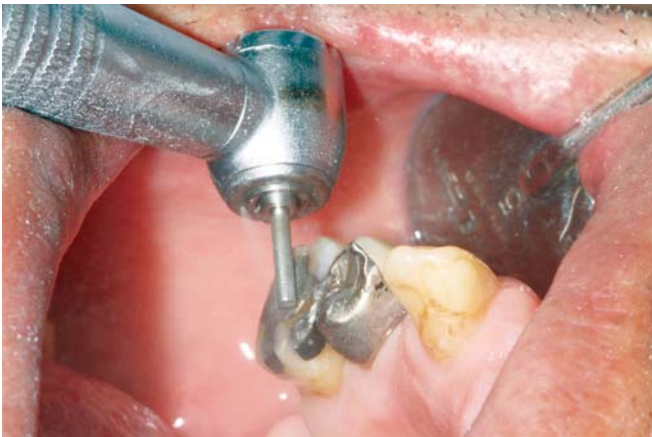

Fig. 10: Occlusal adjustment by selective grinding

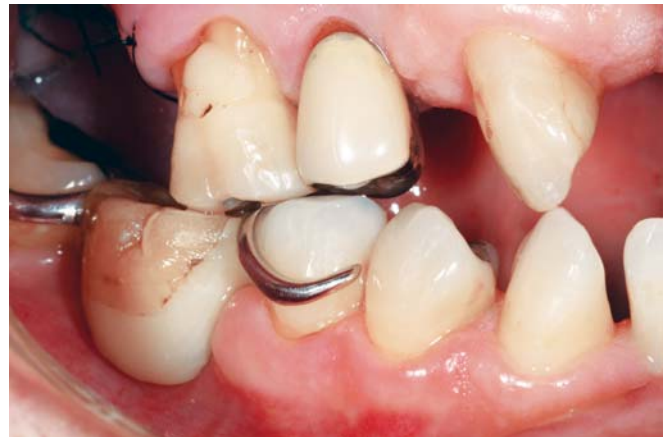

Fig. 13: Mandibular closing in the new VDO after removal of the right superior RPD clamp

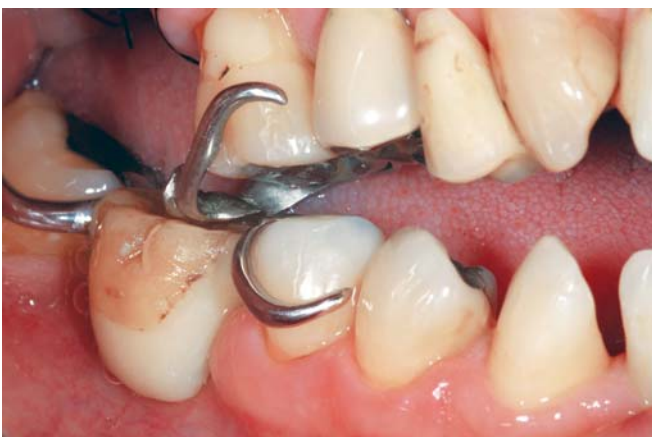

Fig. 11: Interference of RPD clamp during mandibular closing

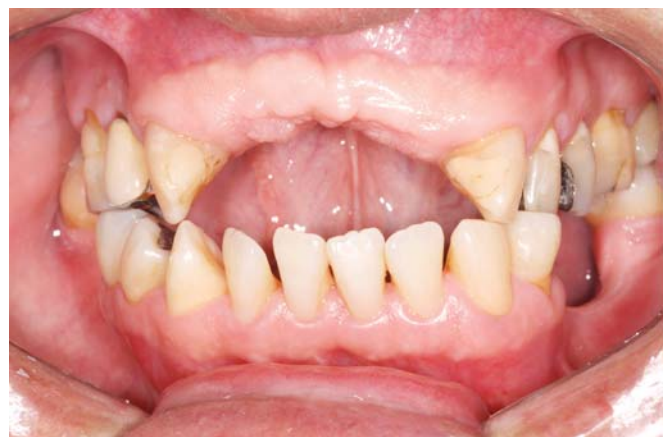

Fig. 14: Intraoral view of occlusal stability in the centric occlusal relation and new VDO

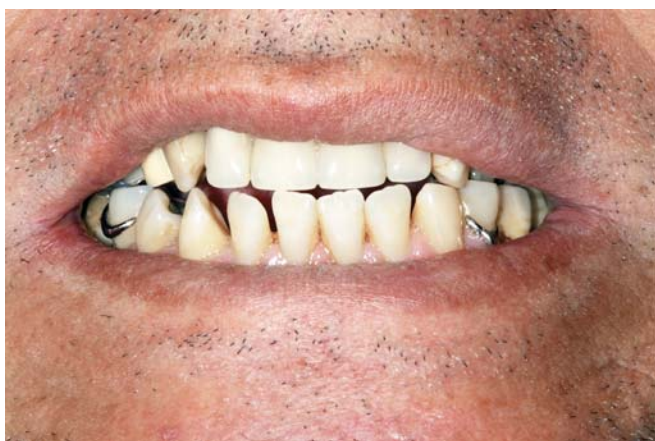

Fig. 15: Extraoral view of anterior guidance and occlusal stability in the centric occlusal relation and new VDO

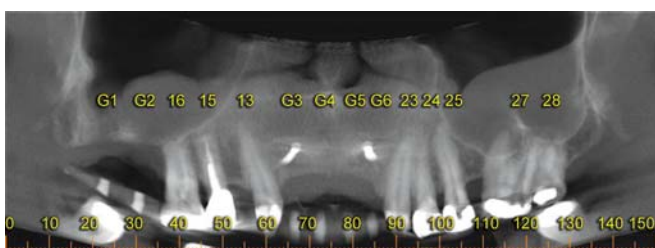


Fig. 16: CT using a guide with radiopaque artefacts

patient was evaluated every 15 days. The patient consistently reported improvement in facial pain, chewing, swallowing, phonation and quality of sleep. Over the course of 90 days, we observed the patient's adaptation to the new conditions as well as muscle accommodation on the new centric occlusion relation and VDO. The occlusal contacts were always checked, and refinement was performed when necessary always in the centric relation. After this period, there was complete remission of initially reported symptoms. On this occasion, the patient underwent computed tomography (CT) using a guide with radiopaque artefacts (Fig. 16) for planning oral rehabilitation involving dental implants. CT findings were suggestive of bilateral thickening of the sinus membranes, and the patient was referred for evaluation and treatment with an otolaryngologist. Consequently, it was proposed that the patient undergo surgical and prosthetic rehabilitation involving maxillary sinus lifting and bone graft, osseointegrated implants, and partial conventional and implant-fixed prostheses with respect to the new VDO, which presented itself as esthetically and functionally more comfortable than the previous VDO.

DISCUSSION

This case is not a straightforward supereruption case, but a complex series of advanced dental conditions. However, the association of periodontitis and occlusal trauma may result in major occlusal discrepancies between centric

relation and centric occlusion and alteration of VDO. Given this clinical situation and the patient's complaints, we find relevant discuss the importance of VDO in oral rehabilitation.

The occlusal adjustment by selective grinding performed in the casts was important to ensure that it was possible to provide the patient with anterior guidance and occlusal stability. Only then could we make an accurate diagnosis and plan the best treatment modality. It should be emphasized that not all cases can be treated by the removal of tooth structures and then considering the need for orthognathic surgery and/or orthodontics.¹² When performing the dental extractions, removing the clasp of an RPD and performing occlusal adjustment by selective grinding guided by the simulation performed in the casts mounted in a semi-adjustable articulator, all physiological principles of the occlusion were restored. This gave the patient a more comfortable VDO and anterior guidance, which is associated with occlusal stability and resulted in the gradual remission of initial symptoms. In subsequent consultations, the adjustment was always refined, accommodating the dental occlusion to progressive muscle relaxation until the complete disappearance of symptoms. For proper definitive oral rehabilitation, the patient was instructed to continue treatment by considering dental implants for a better distribution of occlusal loads, especially in the anterior guidance.

The necessity of sinus lift and the presence of sinus disease must be emphasized. Although sinus disease can be the result of untreated dental diseases, especially on the right side, where there were teeth with signs of chronic apical periodontitis and occlusal trauma, the same change is observed in the left maxillary sinus, which is not observed teeth with periapical or periodontal involvement. For this reason patient was referred for evaluation and treatment with an otolaryngologist who made the diagnosis and did not opposed to sinus lifting. According to literature, there may not be a contraindication for sinus augmentation surgery, if there was no clinical diagnosis of acute sinusitis, which is characterized by a typical triad of symptoms: Nasal congestion, pathologic secretion or obstruction and headache. Beside that, a successful treatment after extraction of periodontally involved molar with chronic sinus inflammation followed by sinus lift and dental implants is described in the literature.¹⁴⁻¹⁶

After discussing the signs and symptoms of cases of increased VDO, establishing the correct diagnosis using all available means, and considering the available forms of treatment, we concluded that the determination of an esthetic and functional VDO should be regarded as a basic and fundamental procedure that should be considered at the beginning of all dental rehabilitations.

REFERENCES

1. Dawson PE. Evaluation, diagnosis and treatment of occlusal problems (2nd ed). St Louis: Mosby 1989; p. 632.
2. Silverman MM. The speaking method in measuring vertical dimension. *J Prost Dent* 1953;3(2):193-99.
3. Toolson LB, Smith DE. Clinical measurement and evaluation of vertical dimension. *J Prosthet Dent* 2006;95(5):335-39.
4. Bissasu M. Pre-extraction records for complete denture fabrication: A literature review. *J Prosthet Dent* 2004;91:55-58.
5. Chou TM, Moore DJ, Young L Jr, Glaros AG. A diagnostic craniometric method for determining occlusal vertical dimension. *J Prosthet Dent* 1994;71:568-74.
6. Allonso AA, Albertini JS, Bechelli AH. Oclusión y diagnóstico en rehabilitación oral. Buenos Aires: Médica Panamericana 2004:652.
7. Hansen CA, Dubois LM. A diagnostico mandibular denture to evaluate occlusal vertical dimension. *Gen Dent* 1995;43(1): 36-38.
8. Mohindra NK. A preliminary report on the determination of the vertical dimension of occlusion using the principle of the mandibular position in swallowing. *Brit Dent J* 1996;180(9): 344-38.
9. Feltrin PP, Philippi AG, Moretti J Jr, Machado CC, Astolf JA. Dimensões verticais, uma abordagem clínica: revisão de literatura. *Revista de Odontologia da Universidade Cidade de São Paulo* 2008;20(3):274-79.
10. Oliveira MA. Análise e estudo dos métodos e dos fundamentos fisiológicos para a determinação da dimensão vertical na oclusão humana em prótese. [Mestrado]. Faculdade de Odontologia da Universidade de São Paulo 1990: p. 85.
11. Zarb GA, Bergman BO, Clayton JA, Mackay H. Prosthodontic treatment for partially edentulous patients. St Louis: Mosby 1978: p. 619.
12. Cardoso AC. Oclusão. Para você e para mim. In: Baratieri LN (ed). *Dentística: Procedimentos Preventivos e Restauradores*. São Paulo: Santos 1989:12-22.
13. Ramfjord SP, Ash MM. *Occlusion* (3rd ed). Philadelphia: WB Saunders Co. 1983: p. 472.
14. Kara IM, Küçük D, Polat S. Experience of maxillary sinus floor augmentation in the presence of antral pseudocysts. *J Oral Maxillofac Surg* 2010;68(7):1646-50.
15. Mardinger O, Manor I, Mijiritsky E, Hirshberg A. Maxillary sinus augmentation in the presence of antral pseudocyst: A clinical approach. *Oral Surg Oral Med Oral Pathol Oral Radiol Endod* 2007;103(2):180-84.
16. Tözüm TF, Dursun E, Tulunoğlu I. Sinus floor elevation from a maxillary molar tooth extraction socket in a patient with chronic inflammation. *J Periodontol* 2009;80(3):521-26.

ABOUT THE AUTHORS

José Augusto César Discacciati (Corresponding Author)

Professor, Department of Restorative Dentistry, Federal University of Minas Gerais, Minas Gerais, Brazil, e-mail: jacdiscacciati@uol.com.br

Eduardo Lemos de Souza

Professor, Department of Restorative Dentistry, Federal University of Minas Gerais, Minas Gerais, Brazil

Walison Arthuso Vasconcellos

Professor, Department of Restorative Dentistry, Federal University of Minas Gerais, Minas Gerais, Brazil

Sérgio Carvalho Costa

Professor, Department of Restorative Dentistry, Federal University of Minas Gerais, Minas Gerais, Brazil

Vinícius de Magalhães Barros

Professor, Department of Dentistry, Dental School, Pontifical Catholic University of Minas Gerais, Minas Gerais, Brazil