



Use of Clinical Bleaching with 35% Hydrogen Peroxide in Esthetic Improvement of Fluorotic Human Incisors *in vivo*

Raghavendra Shanbhag, R Veena, Girish Nanjannawar, Jaykumar Patil, Santosh Hugar, Hemanth Vagralli

ABSTRACT

Aim: The aim of the study was to evaluate esthetic improvement with the use of 35% hydrogen peroxide clinical bleaching as related to the different grades of enamel fluorosis *in vivo* and to study adverse effect of clinical bleaching with 35% hydrogen peroxide on teeth and gingiva.

Materials and methods: A total of 60 children of different grades of fluorosis were included in the study. With 35% hydrogen peroxide-based dual activated bleaching system, in-office vital teeth bleaching was carried out for each subject. Clinical evaluation for improvement in esthetics, effect on teeth and gingiva were performed for each child during preoperative, immediate postoperative and later 6 months postoperative period. For evaluation and comparison, all the collected data were subjected to statistical analysis.

Results: Although in all the subjects, partial shade relapse was seen over a period of time, good homogeneous and esthetic results were seen in very mild and mild cases. A total of 35% hydrogen peroxide in-office bleaching has no adverse effect on teeth and gingiva.

Conclusion: Comparing all the three groups who participated in the study, 35% hydrogen peroxide in-office bleaching seems to be very effective in very mild and mild forms of fluorosis.

Clinical significance: In very mild and mild forms of fluorosis, in-office vital tooth bleaching with 35% hydrogen peroxide is the most conservative and effective approach in esthetic improvement.

Keywords: Fluorosis, Randomized clinical trial, 35% hydrogen peroxide in-office bleaching.

How to cite this article: Shanbhag R, Veena R, Nanjannawar G, Patil J, Hugar S, Vagralli H. Use of Clinical Bleaching with 35% Hydrogen Peroxide in Esthetic Improvement of Fluorotic Human Incisors *in vivo*. J Contemp Dent Pract 2013;14(2): 208-216.

Source of support: Nil

Conflict of interest: None declared

INTRODUCTION

Dental fluorosis is the specific disturbance of tooth formation caused by excessive intake of fluoride during the

formative period of dentition. The manifestation of this form of chronic fluoride intoxication depends upon, the amount ingested, the duration of exposure and age of the subject.¹ Endemic dental fluorosis formerly called 'mottled enamel' is a form of enamel hypoplasia clinically characterized by white opacities and moderate to severe staining of the tooth surface. White opacities vary from minor striation to extensive areas of lusterless enamel, typically in the form of lines or bands extending across the crown of the teeth from the proximal surface. The stained areas appear posteruptively and are often characterized as irregular in outline and varied in shape. The changes are symmetrically distributed within the oral cavity but severity varies among the different types of teeth.^{2,3}

Black and McKay gave the first clinical description of this disorder in 1916. They reported that mottling has a color ranging from paper white to yellow; light or dark brown or black.⁴ The mottling becomes clinically significant when the patient has a prolonged history of ingesting substance containing more than 1 ppm of fluoride ion. As the concentration of fluoride ion increases, the condition becomes more severe. At present, it is believed that this hypoplasia is caused by the metabolic alteration of the ameloblast during formation of enamel with subsequent defective matrix and calcification.

Fluorotic areas of discoloration on permanent teeth often create an esthetically compromised appearance that influences self-image. Discoloration of teeth has a tremendous impact on the psychology of the patient. Sometimes the discoloration may be a contributing factor in the psychological makeup of an individual who displays antisocial behavior. This is particularly true in children and teens who struggle with the difficulties of growing up, socializing process and have much concern about anything that brings negative attention to them. No youngster wants an unattractive smile because of discolored teeth.⁵

So, making the discovery of an adequate remedy becomes all the more urgent. A variety of treatment approaches including bleaching, macroabrasion, microabrasion, direct and indirect composite laminate, veneers, porcelain veneers and crowns have been proposed and discussed to address the esthetic concern of discolored teeth.^{6,7} The most conservative approach involves bleaching of the teeth. This can be accomplished by using a variety of materials that are mostly based on chemicals that generate peroxide ions. Bleaching can be done in the dental office or at home, either on vital or nonvital teeth.

In-office vital tooth bleaching has been used for many years in dentistry and is known to be a reliable technique for quickly lightening discolored teeth. In-office technique uses a series of chemical agents; among them is hydrogen peroxide at 35%, a bleaching agent used in dentistry for years to remove or modify blemishes associated with fluorosis. The reaction of the tooth to 35% hydrogen peroxide is based on the liberation of the oxidants which will penetrate enamel and dentinal tubule and enable dental bleaching. Various application techniques of 35% hydrogen peroxide have been employed, such as with usage of lamps, heat or laser to enhance the bleaching effect of hydrogen peroxide and to obtain faster results.⁸

The main safety advantage of the in-office vital bleaching technique are that, although it uses caustic chemicals, it is totally under the dentist control. Soft tissue is generally protected from the process and bleaching agent has the potential for bleaching quickly with satisfactory results. The only disadvantage of using peroxide-based bleaching material is that they can cause dental sensitivity and gingival irritation.⁹ A majority of clinical studies have evaluated tooth whitening product among adult subjects. Although many clinical case presentations are reported among children, only limited clinical research exists for the bleaching of fluorotic stains.

The objectives of this study are as follows:

1. To evaluate esthetic improvement of fluorosed teeth with the use of 35% hydrogen peroxide clinical bleaching as related to the different grades of enamel fluorosis *in vivo*.
2. To study adverse effects of clinical bleaching with 35% hydrogen peroxide on teeth and gingiva.

MATERIALS AND METHODS

Subjects

A total of 60 children between the age group of 14 to 17 years, reporting to the Department of Pediatric and Preventive Dentistry, PMNM Dental College, Bagalkot, with the chief complaint of unsightly appearance of upper permanent incisors secondary to fluorosis were selected for the study using the following criteria.

Inclusion Criteria

1. Children residing in the city of Bagalkot.
2. Children with all four permanent incisors completely erupted.
3. Children showing grades 2, 3 and 4 [according to Dean's fluorosis index (DFI)] fluorosis lesions on maxillary incisors.

Exclusion Criteria

1. Children with history of systemic diseases or any gross pathology in the oral cavity.
2. Children with unerupted or partially erupted permanent incisors.
3. Children with questionable diagnosis.
4. Children with restorations with permanent incisors.

Selected children and their parents were explained regarding the nature and the purpose of the study. Informed consent was obtained from the parents to allow their children to participate in the study.

Experimental Design

Study design was of a comparative type and includes three groups, depending on the modified DFI or WHO fluorosis classification,¹⁰ so that each group contained 20 children (total 60 children). Three groups included in our study were as follows:

- *Group 1* (2—very mild fluorosis, DFI): Children with small, opaque, paper white area scattered irregularly over the tooth, but involving less than 25% of tooth surface.
- *Group 2* (3—mild fluorosis, DFI): Children with opaque, paper white area scattered more extensively over the tooth, but involving less than 50% of tooth surface.
- *Group 3* (4—moderate fluorosis, DFI): Children with opaque, paper white area scattered all over the tooth, with brown stains disfiguring the tooth.

Pretreatment Clinical Assessment

Each child was subjected to thorough intraoral examination. Data including oral hygiene index—simplified and gingival index were recorded according to the WHO criteria.¹⁰ Oral prophylaxis was carried out for each child using ultrasonic scaler, prophylaxis brush and pumice paste to remove calculus and extrinsic stains (Fig. 1). Each child was then assigned to one of the three groups according to the modified DFI as discussed above. Baseline shade of the teeth was recorded with the help of a Vita shade guide (Fig. 2). Baseline sensitivity of the teeth was recorded with the heat and cold test. Photographic records were then obtained.

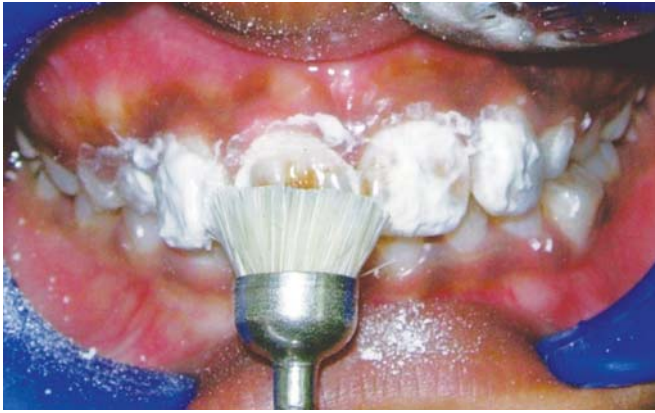

Fig. 1: Extrinsic stains removal using prophy brush and pumice paste following oral prophylaxis

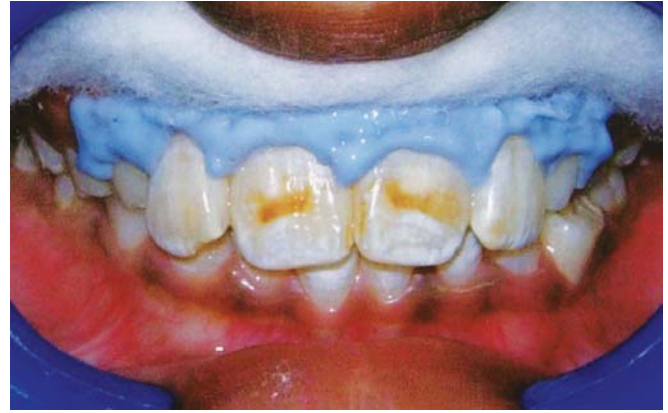

Fig. 3: Gingival barrier overlapping 0.5 mm of enamel and sealing all pink tissue

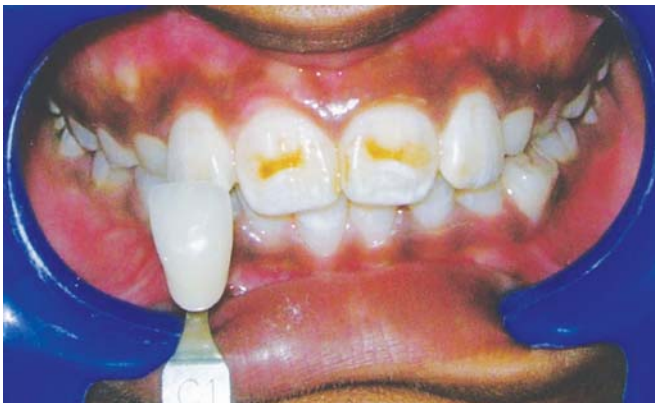

Fig. 2: Recording of baseline shade of the teeth using Vita shade guide

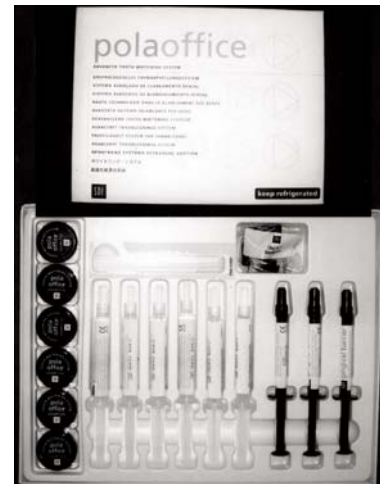

Fig. 4: Bleaching agent, 35% hydrogen peroxide (Polaoffice—dual activated advanced tooth whitening system, SDI Limited, Australia)

Bleaching Procedure

Gingival barrier provided by the manufacturer was applied to the gingival tissue after drying the teeth so that the barrier overlaps 0.5 mm of enamel and seals all pink tissue. Then it was cured for 30 to 40 seconds to ensure complete polymerization (Fig. 3). A rubber dam was then applied to isolate the affected incisors and protect the soft tissue. Only in severely stained cases, all four incisors were etched by using 37% phosphoric acid for 15 seconds. Each tooth surface was thoroughly washed by water spray for 30 seconds and dried with air spray. For selected cases, wherever required a thin layer of bonding agent was applied and was cured for 10 seconds with photopolymerizer to avoid bleaching of these areas so that more uniform appearance of the tooth could be achieved.

Bleaching with the dual activation process (photo/chemical) with 35% hydrogen peroxide [polaoffice-dual activated advanced tooth whitening system, SDI Limited Australia, was used as a bleaching agent (Fig. 4)]. According to the manufacturers instructions, one part of powder and three parts of liquid were dispensed in a plastic dispenser

and mixed thoroughly with brush applicator (provided by manufacturer) to get bluish green-colored gel. The gel was then applied to each tooth at least 2 mm in depth ensuring no enamel is visible (Fig. 5). Immediately after application, gel was exposed to photopolymerizing light for 30 seconds for each tooth (Fig. 6).

The gel was kept on the tooth for additional 3 minutes till it was completely cured. Bleaching agent was then removed with the suction. No rinsing was done. The same procedure was repeated till desired shade was obtained. After the last application, copious amount of water spray was used to properly clean the tooth (Fig. 7).

After all bleaching procedures, fluoride varnish was applied (fluor protector) over bleached tooth for remineralization and reduce tooth sensitivity. If required bleaching was carried out after 1 week, this procedure was continued till the patient was satisfied with the esthetic appearance of the teeth or maximum of seven procedures which ever was the least. After completion of all bleaching procedures, again a photographic record was obtained.

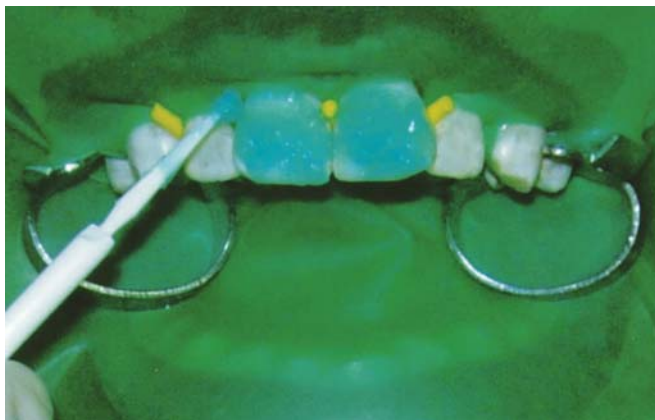

Fig. 5: The bleaching gel application to each tooth at least 2 mm in depth

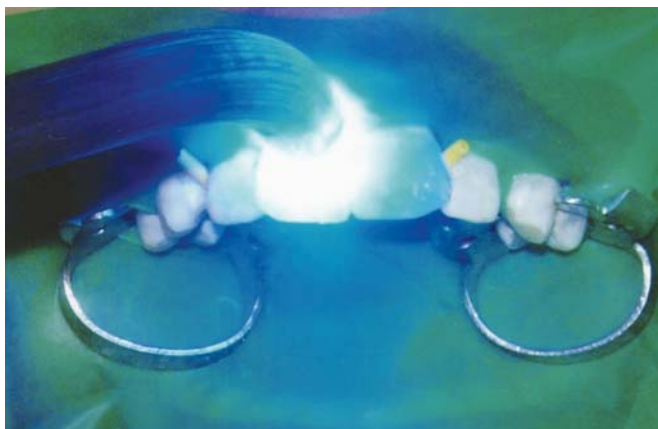


Fig. 6: Exposure of gel to photopolymerizing light for 30 seconds for each tooth

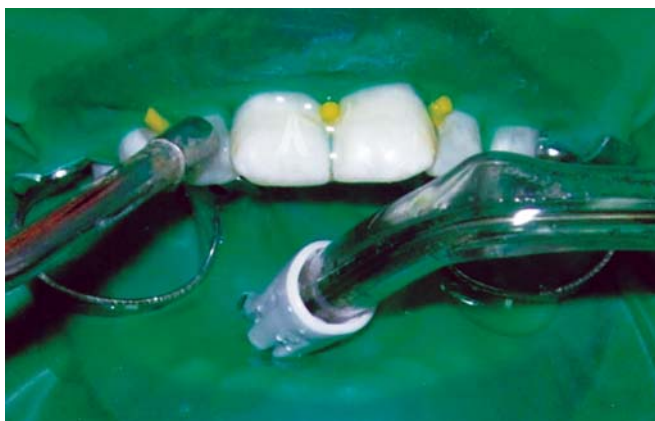

Fig. 7: After last application of bleaching gel copious amount of water spray was used to properly clean the tooth

CLINICAL EVALUATION

Clinical evaluation for each child was performed before, immediately after procedure and after 6-month of post-treatment period.

Esthetics

Improvement in esthetics was evaluated by recording tooth shade with the help of shade guide and modified DFI.

Patient's satisfaction and operator satisfaction regarding improvement in esthetics was separately recorded as yes or no. For the convenience of the operator, in evaluating the esthetic results of treated teeth, the grade 4—moderate fluorosis (DFI) was further divided into three categories as follows:

- *Grade 4a:* Children with opaque, paper white area scattered all over the tooth, with mild brown stains disfiguring the tooth.
- *Grade 4b:* Children with opaque, paper white area scattered all over the tooth, with moderate brown stains disfiguring the tooth.
- *Grade 4c:* Children with opaque, paper white area scattered all over the tooth, with severe brown stains disfiguring the tooth.

Effect on Gingiva

Change in the gingival status due to bleaching procedure was evaluated by recording gingival index. This was recorded according to WHO criteria (1991)¹⁰ at the baseline, 1 week after each bleaching session and 6 months post-treatment. Gingival pain during bleaching: This was assessed as present or absent by operator during or immediately after bleaching procedure as complained by the patient. Post-treatment gingival pain and bleaching: It was recorded as present for the number of days after each bleaching procedure from a specially designed questionnaire filled by the patient for 1 week post-bleaching treatment. Gingival bleeding as experienced by the patient: This was recorded as present for the number of days after each bleaching procedure from same questioner filled by the patient for 1 week post-treatment.

Effect on Teeth

Effect on teeth due to bleaching procedure was evaluated by recording: Sensitivity of teeth during bleaching: This was clinically assessed by the operator during or immediately after bleaching procedure with the help of hot and cold pulp test. Post-treatment sensitivity of teeth: This was recorded as present for the number of days after each bleaching procedure from a specially designed questioner filled by the patient for 1 week post-bleaching treatment.

Reproducibility Test of Clinical and Photographic Examination and Statistical Analysis

Single examiner carried out examination and recording of the data for all children included in the study. Intraexaminer reliability of shade and photographic evaluation as well as OHI-S was determined by recording data from nine children of different group twice with an interval of 1 week. To

compare the difference between the groups, obtained results were statistically analyzed. Data were described as mean, standard deviation (SD) and mean/standard deviation difference values. Paired t-test was used for the same group comparisons. Paired t-test followed by Mann Whitney U-test for different groups. A p-value of 0.05 or less was considered for statistical significance.

RESULTS

Compared to baseline tooth shade to 6 months postoperative period shade, maximum improvement was noticed in group 1 with mean difference (MD) 1.5 followed by groups 2 and 3. The improvement noticed in shade was found to be statistically significant in all the three groups (Tables 1 to 3).

DFI between preoperative and 6 months postoperative period showed maximum reduction in group 3 with MD 1.65 followed by groups 2 and 1. The improvement noticed in DFI was found to be statistically significant in all the three groups (Tables 4 to 6).

Oral hygiene indicator OHI-S showed improvement in scores in all three groups. No significant changes noted in gingival health. Gingiva pain and bleeding is not found in any subjects during immediate postoperative or 6 months postoperative period.

Operator tooth sensitivity all the three groups showed statistically significant tooth sensitivity in immediate postoperative period but no subject experienced sensitivity after 6 months of postoperative period.

Maximum amount of patient satisfaction during 6 months postoperative period was noted in subjects of groups 1 and 3 (70%) followed by group 2 (65%). This value compared to immediate postoperative period is lower side and is still statistically significant. Comparing operator satisfaction after 6 months postoperative period maximum satisfaction was noted in group 1 followed by groups 2 and 3.

Subject in all three groups experienced tooth sensitivity in mild to severe forms. Maximum sensitivity was experienced by group 3 subjects, which is statistically significant compared to groups 2 and 1. Comparing number of days tooth sensitivity experienced by the patient after bleaching sessions; group 3 subjects showed an average of 7.65 days sensitivity followed by group 2 of 3.6 days. Group 1 subjects experienced least tooth sensitivity with an average of 2.95 days. The difference noted between the values of groups 3 and 1 is found to be statistically significant.

On an average 7.6 procedures of 5 minutes, each (38 minutes) were used by groups 1 and 2 subjects as compared to 14.3 procedures (71.5 minutes) for group 3 which was statistically found to be significant.

DISCUSSION

Esthetic dental procedures in pediatric dentistry represents source of satisfaction and realization both for professional and patient. Blemishes produced by fluorosis especially in child and adolescent patients appear as a challenge to the pediatric dentist and alternatives for treatment are desired. Among the treatment alternatives discussed for the dental fluorosis, bleaching seems to be one of the most conservative approaches.^{8,11-13}

Meanwhile, a greater number of pediatric patients have been reportedly requesting tooth bleaching in recent years. Sales of the over, the counter tooth whitening products showed a growth of 57% in the year 2004 and after.^{11,14-16} Although peroxide has been deemed safe and effective tooth whitener in dentistry for adults, a much smaller number of safety and efficacy studies have been conducted in children. Also there is a dearth of reports in the literature relating efficacy and safety of in-office bleaching to blemishes produced by fluorosis in pediatric patients.

So, present study was designed with the primary objective of evaluating esthetic improvement with use of 35% hydrogen peroxide clinical bleaching as related to the different grades of enamel fluorosis *in vivo* and to study the adverse effect of clinical bleaching with 35% hydrogen peroxide on teeth and gingiva.

So far, there are no commonly accepted or agreed upon approaches for children's tooth whitening. Such treatments, however, are being practiced increasingly. Therefore, it is imperative to establish proper approaches for maximum benefits and minimum side effects.

One of the suggested approaches by Lee et al (2005) is that tooth bleaching should be done only under strict supervision of the dentist and parent. Compliance problem in younger children discourages at-home tooth whitening. So, it is recommended to delay dispensing at-home use whitening agents to adolescents until the age of 14 to 15 years, if possible, to avoid potential toxicity risk via abuse.^{11,17,18}

Considering the above-mentioned points, in present study, children between the age group of 14 and 17 years with different grades of fluorotic stains were selected. The 35% hydrogen peroxide based dual activated in-office bleaching agent strictly under dentist supervision and through isolation was used as bleaching material. Also, parents of selected children were informed regarding the nature and purpose of the study and informed consent were obtained from the parents before commencement of the study.

Thirty-five percent hydrogen peroxide is an effective agent in removing superficial enamel stains associated with

Table 1: Group 1—comparison of tooth shade by paired t-test

| Period | Mean | SD | Mean diff | SD diff | Paired t-test | p-value | Significance |
|-------------------|--------|--------|-----------|---------|---------------|---------|--------------|
| Pretreatment | 5.2500 | 1.8028 | 2.2500 | 1.3717 | 7.3356 | 0.0000 | S |
| Post-treatment | 3.0000 | 0.8584 | | | | | |
| Post-treatment | 3.0000 | 0.8584 | -0.7500 | 0.7164 | -4.6822 | 0.0002 | S |
| 6-month follow-up | 3.7500 | 0.7864 | | | | | |
| Pretreatment | 5.2500 | 1.8028 | 1.5000 | 1.2354 | 5.4298 | 0.0000 | S |
| 6-month follow-up | 3.7500 | 0.7864 | | | | | |

Table 2: Group 2—comparison of tooth shade by paired t-test

| Period | Mean | SD | Mean diff | SD diff | Paired t-test | p-value | Significance |
|-------------------|--------|--------|-----------|---------|---------------|---------|--------------|
| Pretreatment | 4.6500 | 1.4965 | 2.2000 | 1.1965 | 8.2230 | 0.0000 | S |
| Post-treatment | 2.4500 | 0.6863 | | | | | |
| Post-treatment | 2.4500 | 0.6863 | -0.9000 | 0.4472 | -9.0000 | 0.0000 | S |
| 6-month follow-up | 3.3500 | 0.6708 | | | | | |
| Pretreatment | 4.6500 | 1.4965 | 1.3000 | 1.0311 | 5.6384 | 0.0000 | S |
| 6-month follow-up | 3.3500 | 0.6708 | | | | | |

Table 3: Group 3—comparison of tooth shade by paired t-test

| Period | Mean | SD | Mean diff | SD diff | Paired t-test | p-value | Significance |
|-------------------|--------|--------|-----------|---------|---------------|---------|--------------|
| Pretreatment | 5.0000 | 1.8064 | 2.6000 | 1.8180 | 6.3957 | 0.0000 | S |
| Post-treatment | 2.4000 | 0.5026 | | | | | |
| Post-treatment | 2.4000 | 0.5026 | -1.3000 | 0.5712 | -10.1775 | 0.0000 | S |
| 6-month follow-up | 3.7000 | 0.6569 | | | | | |
| Pretreatment | 5.0000 | 1.8064 | 1.3000 | 1.5594 | 3.7283 | 0.0014 | S |
| 6-month follow-up | 3.7000 | 0.6569 | | | | | |

Table 4: Group 1—comparison of DFI by paired t-test

| Period | Mean | SD | Mean diff | SD diff | Paired t-test | p-value | Significance |
|-------------------|--------|--------|-----------|---------|---------------|---------|--------------|
| Pretreatment | 1.0000 | 0.0000 | -0.6000 | 0.8208 | -3.2692 | 0.0040 | S |
| Post-treatment | 1.6000 | 0.8208 | | | | | |
| Post-treatment | 1.6000 | 0.8208 | 1.2500 | 0.7864 | 7.1086 | 0.0000 | S |
| 6-month follow-up | 0.3500 | 0.5871 | | | | | |
| Pretreatment | 1.0000 | 0.0000 | 0.6500 | 0.5871 | 4.9509 | 0.0001 | S |
| 6-month follow-up | 0.3500 | 0.5871 | | | | | |

Table 5: Group 2—comparison of DFI by paired t-test

| Period | Mean | SD | Mean diff | SD diff | Paired t-test | p-value | Significance |
|-------------------|--------|--------|-----------|---------|---------------|---------|--------------|
| Pretreatment | 2.0000 | 0.0000 | -0.3000 | 0.4702 | -2.8563 | 0.0102 | S |
| Post-treatment | 2.3000 | 0.4702 | | | | | |
| Post-treatment | 2.3000 | 0.4702 | 1.5000 | 1.1002 | 6.0970 | 0.0000 | S |
| 6-month follow-up | 0.8000 | 1.0563 | | | | | |
| Pretreatment | 2.0000 | 0.0000 | 1.2000 | 1.0563 | 5.0805 | 0.0001 | S |
| 6-month follow-up | 0.8000 | 1.0563 | | | | | |

Table 6: Group 3—comparison of DFI by paired t-test

| Period | Mean | SD | Mean diff | SD diff | Paired t-test | p-value | Significance |
|-------------------|--------|--------|-----------|---------|---------------|---------|--------------|
| Pretreatment | 4.0500 | 0.8256 | 1.0500 | 0.8256 | 5.6878 | 0.0040 | S |
| Post-treatment | 3.0000 | 0.0000 | | | | | |
| Post-treatment | 3.0000 | 0.0000 | 0.6000 | 1.2312 | 2.1794 | 0.0421 | S |
| 6-month follow-up | 2.4000 | 1.2312 | | | | | |
| Pretreatment | 4.0500 | 0.8256 | 1.6500 | 1.4609 | 5.0510 | 0.0001 | S |
| 6-month follow-up | 2.4000 | 1.2312 | | | | | |

fluorosis as compared to other chemical agents. It is more selective in its stain removing action and therefore is less destructive. So, 35% hydrogen peroxide has a wider scope of application. Thirty-five percent hydrogen peroxide is an oxidizing agent which diffuses through the interprismatic substance of the enamel and dentin and converts highly pigmented double-bond carbon ring compounds to hydroxyl groups (alcohol like) which are usually colorless. As these processes continue the bleached teeth are lightened.^{5,19-26}

In present study, improvement in esthetic was evaluated by recording tooth shade, Dean's modified fluorosis index, patient's satisfaction and operator's satisfaction.

For each subject preoperative, immediate postoperative and 6 months postoperative changes observed in the tooth shade were recorded with the help of a value-oriented shade guide. The sequence of light to dark shade tabs were ordered by the manufactures and numbered from 1 to 16 as mentioned in a study carried out by Bizhang et al in 2003.¹²

Present study showed improvement in tooth shade in all the three groups which had participated. Immediate postoperative results showed maximum shade change in group 3 subjects. The reason for this may be attributed to removal of most of the intrinsic yellowish brown stains and presence of more amounts of chalky white blemished areas in group 3 subjects compared to groups 1 and 2.

After 6 months postoperative period, all the three groups showed partial relapse in shade and then maximum shade improvement was noticed in group 1 subjects.

The spectacular whitening effect achieved at the end on immediate postoperative period significant partial relapse of the shade of teeth over the days following bleaching and shift in the maximum improvement noted in tooth shade from groups 3 to 1 during 6 months postoperative period are important factors that should be considered.

The whitening effect of the product combined with the dehydration suffered by the tooth, caused by isolation, could explain the lightness in shade observed at the end of bleaching sessions. The subsequent rehydration of dental tissue and hypothesized neo-reaction of coloring molecules (previously oxidized during the bleaching process) may explain the partial relapse and shift in maximum tooth shade noticed as reported by Lorenzo et al in 1996.^{13,27-32}

Preoperative and 6 months postoperative index for each subject were recorded. Results showed maximum reduction in fluorosis grading in group 3 subjects during immediate postoperative period. This may be attributed to the clinical observations suggesting that the brown staining associated with moderate fluorosis lesion appear to be confined to a superficial zone within the hypomineralized outer enamel.^{4,33,34} So, most of the stains were removed within

initial few bleaching procedures, leaving behind white blemishes and showing drastic improvement in the fluorosis grading.

According to Train et al, mildly fluorotic teeth show the best esthetic results having an extremely normal appearance because in this form of fluorosis porosity and hypomineralized areas were found only in the outermost layers of enamel.^{2,35-38} Also a study by Coll et al (1996) reported that usually the brown stains were placed superficially but the white stains may penetrate entire depth of enamel.⁵ So, removal of brown stains is easier as compared to white blemishes.

In present study no, subject experienced pain or gingival bleeding during bleaching procedure and in follow-up period. The use of resin-based gingival barrier good isolation and extreme precaution during the treatment procedure to prevent contact of bleaching agent to any soft tissue of oral cavity may have contributed to this result. In contrast to our results, a study by Shetri et al (2003) reported slight gingival irritation in some participants after the use of in-office bleaching procedure.^{14,15,39-41}

In present study, we have evaluated tooth sensitivity experienced by the patient during bleaching and after 15 days postoperatively was noted. In our study, all the patients of group 3 experienced sensitivity followed by groups 2 (90%) and 1 (80%). In postoperative period, group 3 experienced maximum amount of sensitivity of an average 7.65 days followed by groups 2 (3.6 days) and 1 (2.95 days). Shetri et al (2003) reported that tooth sensitivity experienced by in-office procedure for few days post-treatment may be related to the acute exposure to high concentration of hydrogen peroxide. So, bleaching procedure followed by a week of break was recommended to allow sensitivity to abate. In present study, we also followed similar pattern of bleaching schedule. Also to reduce sensitivity subjects were advised to avoid extreme hot and cold food during treatment period and fluoridated toothpaste was advised which also helps in remineralization. Fluoride varnish applied after the last bleaching session also helped to reduce the sensitivity to some extent.

CONCLUSION

Comparing all the three groups which participated in the study, 35% hydrogen peroxide in-office bleaching seems to be very effective in very mild and mild forms of fluorosis after 6 months postoperative period. In moderately fluorosed subjects although brown stains were removed, masking effect of white blemishes were not satisfactory even after 14 to 15 bleaching procedures. A total of 35% hydrogen peroxide in-office bleaching has no adverse effect on teeth

and gingiva. Most of the subjects although experienced tooth sensitivity for 3 to 6 days postoperatively, the condition was reversible without any further complications. Although in all the subjects partial shade relapse was seen over a period of time, a good homogeneous and esthetic result was seen in very mild and mild cases.

CLINICAL SIGNIFICANCE

In very mild and mild forms of fluorosis, in-office vital tooth bleaching with 35% hydrogen peroxide is the most conservative and effective approach in esthetic improvement.

REFERENCES

- Cutress TW, Suckling GW. Differential diagnosis of dental fluorosis. *J Dent Res* 1990;69(Spec Iss):714-20.
- Bonifacio da Silva SM, Sodre de Oliveira F, Moreira Lanza CR, Moreira Machado MA. Esthetic improvement following enamel microabrasion on fluorotic teeth: A case report. *Quintessence Int* 2002;33(5):366-69.
- McEvoy SA. Chemical agents for removing intrinsic stains from vital teeth. II. Current technique and their application. *Quintessence Int* 1989;20(6):379-84.
- Bailey RW, Christen AG. Bleaching of vital teeth stained with endemic dental fluorosis. *Oral Surg* 1968;26(6):871-78.
- Croll TP, Segura A. tooth color improvement for children and teens: Enamel microabrasion and dental bleaching. *J Dent Child* 1996;49:17-22.
- Belkhir MS, Douki N. A new concept for removal of dental fluorosis stains. *J Endodon* 1991;17(6):288-92.
- Zekonis R, Matis BA, Cochran MA, Shethri SA, Eckert GJ, Carlson TJ. Clinical evaluation of in-office and at-home bleaching treatments. *Oper Dent* 2003;28(2):114-21.
- McKay FS, Black GV. Investigation of mottled teeth: An endemic imperfection of the enamel of teeth heretofore unknown in literature of dentistry. *Dent Cosmos* 1916;58:129-56;477-84;627-34;781-92;894-904.
- Fejerskov O, Kidd AM. Dental caries the disease and its management. Clinical use of fluoride (1st ed). United Kingdom: Blackwell Munksgaard 2003:189-202.
- WHO. Oral health surveys (4th ed). Delhi: AITBS Publication and Distributors 1999:39-45.
- Dean HT. Classification of mottled enamel diagnosis. *J Am Dent Assoc* 1934;21:1421-26.
- Dean HT, McKay FS. Production of mottled enamel halted by a change in common water supply. *Am J Public Health* 1939;29:590-96.
- Shortt WE. Endemic fluorosis in Nellore district, South India. *Indian Med Gazette* 1937;72:396.
- Handa BK. Geochemistry and genesis of fluoride containing ground waters in India. *Ground Water* 1975;13:275-81.
- Mariappan P. Studies on the defluoridation of water. PhD thesis. Alagappa University, Karaikudi 2001.
- Meenakshi, Maheswari RC. Fluoride in drinking water and its removal. *J Hazmat* 2006;137:456-63.
- Fejerskov O, Johnson NW, Silverstone LM. The ultrastructure of fluorosed human dental enamel. *Scand J Dent Res* 1974;82:357-72.
- Richards A, Kragstrup J, Josephsen K, Fejerskov O. Dental fluorosis developed in post-secretory enamel. *J Dent Res* 1986;65:1406-09.
- Thylstrup A, Fejerskov O. Clinical appearance of dental fluorosis in permanent teeth in relation to histologic changes. *Community Dent Oral Epidemiol* 1978;6:315-28.
- Aoba T, Fejerskov O. Dental fluorosis: Chemistry and biology. *Crit Rev Oral Biol Med* 2002;13:155-70.
- Horowitz HS, Driscoll WS, Meyers RJ, Heifetz SB, Kingman A. A new method for assessing the prevalence of dental fluorosis-the tooth surface index of fluorosis. *J Am Dent Assoc* 1984;109:37-41.
- Pendrys DG. The fluorosis risk index: A method for investigating risk factors. *J Public Health Dent* 1990;50:291-98.
- Akapata ES. Occurrence and management of dental fluorosis. *Int Dent J* 2001;51:325-33.
- McInnes JW. Removing brown stain from teeth. *Arizona Dent J* 1966;12:13-14.
- Roberson T, Heymann HO, Swift EJ. Sturdevant's art and science of operative dentistry. Additional conservative esthetic procedures (4th ed). Missouri: Mosby 2002:610-20.
- Grossman L, Oliet S, Del Rio C. Endodontic practice. Bleaching of discolored teeth (11th ed). India: Varghese Publication 1991:276.
- Limeback H, Viera AP, Lawrence H. Improving esthetically objectionable human enamel fluorosis with simple microabrasion technique. *Eur J Oral Sci* 2006;114:123-26.
- Ash SP, Ramfjord MM. Occlusion in operative and restorative dentistry (4th ed). Philadelphia: WB Saunders Company 1995:409-22.
- Mohl N, Zarb GA, Carlsson GE, Rugh JD. A textbook of occlusion. Prosthodontic, operative and orthodontic therapy. Illinois: Quintessence Books 1988:305-24.
- Shillingburg JR, Hobo S, Whitsett LD. Fundamentals of fixed prosthodontics. Interocclusal records (3rd ed). Illinois: Quintessence Books 1997:38-40.
- Krishna MG, Rao KS, Goyal K. Prosthodontic management of severely worn dentition: Including review of literature related to physiology and pathology of increased vertical dimension of occlusion. *J Ind Prosth Soc* 2005;5:89-93.
- Greenwall L. Bleaching techniques in restorative dentistry. An illustrated guide. New York: Martin Dunitz 2001:244-50.
- Seale NS, Thrash WJ. Systematic assessment of colour removal following vital bleaching of intrinsically stained teeth. *J Dent Res* 1985;64:457-61.
- Wong FS, Winter GB. Effectiveness of microabrasion technique for improvement of dental aesthetics. *Br Dent J* 2002;193:155-58.
- Sarrett DC. Tooth whitening today. *J Am Dent Assoc* 2002;133:1535-38.
- Susheela AK. Fluorosis management program in India. *Curr Sci* 1999;77:1250-55.
- Harikumar R, Khandare AL, Brahmam GN, Venkiah K. Assessment of current status of fluorosis in north-western districts of Tamil Nadu using community index for dental fluorosis. *J Hum Eco* 2007;21:27-32.
- Peter JM, Crawford MA. Agnes Bloch-Zupan. Amelogenesis Imperfecta *Rev* 2007;2:17-28.
- Watts A, Addy M. Tooth discoloration and staining: A review of literature. *Br Dent J* 2001;190:309-16.

40. Ardu S, Stayridakis M, Krejci I. A minimally invasive treatment of severe dental fluorosis. *Quintessence Int* 2007;38:455-58.
41. Manton DJ. Aesthetic management of severely fluorosed incisors in an adolescent female. *Aust Dent J* 2007;52:243-48.

ABOUT THE AUTHORS

Raghavendra Shanbhag

Assistant Professor, Department of Pedodontics, Bharati Vidyapeeth Dental College, Sangli, Maharashtra, India

Correspondence Address: C/O U Subray Shanbhag, Nandishwar Nagar, Mundgod 581349, Uttara Kannada, Karnataka, India, Phone: 9945112080, e-mail: drraghu.kiddoc@gmail.com

R Veena

Private Practitioner, Department of Orthodontics, Sangli, Maharashtra India

Girish Nanjannawar

Assistant Professor, Department of Endodontics, Bharati Vidyapeeth Dental College, Sangli, Maharashtra, India

Jaykumar Patil

Professor, Department of Endodontics, Bharati Vidyapeeth Dental College, Sangli, Maharashtra, India

Santosh Hugar

Assistant Professor, Department of Endodontics, Bharati Vidyapeeth Dental College, Sangli, Maharashtra, India

Hemanth Vagrati

Reader, Department of Endodontics, Bharati Vidyapeeth Dental College, Sangli, Maharashtra, India