



Shaping Potential of Manual NiTi K-File and Rotary ProTaper and Analyzing the Final Outcome of Shaped Canals using CT

Surbhi Kakar, Anil Dhingra, Himanshu Sharma

ABSTRACT

Aim: To assess and compare the shaping potential of manual NiTi K-files and Rotary ProTaper instruments in narrow canals using CT.

Objective: To assess the shaping potential of manual NiTi K-files and Rotary ProTaper and analyzing the final outcome of shaped canals using CT and determining different variables, like

- Working time
- Change in volume
- Change in cross-sectional area.

Materials and methods: From a pool of fifty freshly extracted permanent maxillary molars (1st and 2nd), 30 were selected with curvatures (20 to 40°) (Schneider 1971). Tissue fragments and calcified debris were removed from the teeth by scaling. The teeth were then stored in normal saline until used.

All the mesiobuccal canals were scanned by CT to obtain preinstrumented images. Teeth were scaled and stored in normal saline. This study was divided in two groups with 15 samples each.

Group I (ProTaper Rotary): Canals were instrumented with Protaper Rotary instruments using crown down technique according to manufacturer's instructions.

Group II (NiTi K-file): Were instrumented by NiTi K-files using step back technique with a quarter turn/pull motion.

Evaluations of working time: Comparative evaluations of working time was done for both the experimental groups.

CT analysis and measurements: The samples were analyzed and evaluated for:

- Postinstrumentation change in volume.
- Postinstrumentation change in cross-sections area.

Result: From the observations and statistical analysis carried out in this study, it was found that:

There was a statistically significant difference between all the parameters judged for the present study that is:

1. Instrumentation with ProTaper Rotary system took significantly less time than instrumentation with manual NiTi K-file.

2. Change in the canal volume following instrumentation with ProTaper Rotary was significantly greater than that produced by manual NiTi K-file.
3. a. Change in cross-section area at 2 and 3 mm from the apex was significantly greater with manual NiTi K-file as compared to ProTaper Rotary.
b. Change in cross sections at 4.5, 6 and 7.5 mm from the apex with ProTaper Rotary was significantly greater than that produced by manual NiTi K-file.

Conclusion: This clearly establishes that there is a drastic difference in the shaping ability of manual and Rotary NiTi instruments used with step back and crown down technique respectively with the rotary instrumentation being faster and producing greater changes in the canal anatomy.

Keywords: Shaping Potential, NiTi K-file, ProTaper rotary, Working time, Change in volume, Change in cross-section area.

How to cite this article: Kakar S, Dhingra A, Sharma H. Shaping Potential of Manual NiTi K-File and Rotary ProTaper and Analyzing the Final Outcome of Shaped Canals using CT. J Contemp Dent Pract 2013;14(3):451-455.

Source of support: Nil

Conflict of interest: None declared

INTRODUCTION

Root canal preparation aims to remove infected pulp and microbial debris from the root canal system. Shaping the root canal provides more efficient disinfection by removing infected dentin and creating space for irrigants, medicaments and inert root canal filling.¹ Inadvertent procedural errors can occasionally occur during the instrumentation of narrow curved canals. One major advancement is the development and use of nickel titanium alloys for manufacture of endodontic instruments.

Recently, techniques that allow the teeth to be evaluated for shaping ability without destroying the specimens have been suggested to compare root shape prior to and after

instrumentation. With the use of computed tomography (CT), appropriate and measurable sections can be prepared and 3D images can be reconstructed. Root canal instruments and preparation methods can be compared by using CT.¹

The aim of the present study was to compare the shaping potential of manual NiTi K-files and rotary ProTaper in narrow canals using CT.

MATERIALS AND METHODS

For this study from a pool of 50 freshly extracted permanent maxillary molars (1st and 2nd), 30 were selected based on measurement of root canal curvature (20 to 40°) from preoperative radiographs after insertion of a size 15 K Flexofile (Schneider 1971).² Tissue fragments and calcified debris were removed from teeth by scaling and the teeth were stored in normal saline until further use. After the access cavity preparations, radiographs were taken buccolingually and mesiodistally of each canal with size 15K-flexofile (Dentsply Maillefer) *in situ*. The more strongly curved canals were scheduled for preparation by the (ProTaper Rotary) Group I. The less strongly curved canal were scheduled for preparation with (NiTi K-files) Group II.⁵ To determine the working length (WL), a size 10 K-Flexofile was inserted into the mesiobuccal canals until it was visible at the apical foramen. The working length of each canal was calculated to be 1 mm less than the length obtained with this initial file.

The samples were now mounted on circular wax stumps. All teeth were scanned by multidetector multislice GE lightspeed proscanner. The purpose of scanning was to acquire the preinstrumented images. The images were scanned at an isotropic resolution of 50 microns. The volume data set was analyzed on Advantage Windows 4.2 software release and the 3D reconstructional volumetric and cross-sectional area analysis was performed on this software.

Group I (ProTaper)

Mesiobuccal canals of all 15 samples in this group were instrumented with Rotary ProTaper instruments using crown down technique, according to manufacturers recommendation. Instrumentation was done at a speed of 300 rpm using an 1/64 reduction hand piece (Anthogyr) powered by Marathon NSK micromotor. Master apical file was F2 ProTaper Rotary instruments.³

Group II (NiTi K-File)

All the samples of this group were manually instrumented using quarterturn and pull movement in a step back manner. Master apical files in group II were size 25, from which

point the canals were stepped-back, 1 mm per file, to a size 45.^{5,6} The root canals were irrigated with 2 ml of 5% NaOCl solution. The teeth were then scanned postoperatively under the same conditions as the initial scans. Data was stored on Advantage Windows 4.2 Workstation.

Evaluation for Working Time

Comparative evaluation was done for the working time for both the experimental groups.

CT Analysis and Measurements

The samples were analyzed and evaluated for

- Postinstrumentation change in volume
- Postinstrumentation change in cross-section area.

After the volume data set acquisition from the samples, 3D analysis of the data was done for ProTaper group first. The volumetric analysis was done using advantage windows 4.2 software release on Advantage Windows Workstation. The volume analysis of the data was performed using 0.625 mm thin slice stack. The volume of the MB canals were calculated both for the preinstrumented and post instrumented images of all 15 samples. Change in cross-section area was calculated from the 5 predetermined (2, 3, 4.5, 6, 7.5 mm from apex) where 2 and 3 mm denotes the apical region, 4.5 mm middle, 6 and 7.5 mm coronal third of the canal respectively. Change in cross-section area was evaluated for each canal from both the pre and post-instrumented image (Fig. 1). In the same manner, change in volume and cross-section area is calculated for group II and comparative evaluation done.

RESULTS AND OBSERVATIONS

Formula used for Statistical Analysis

On completion of the study of the obtained values were statistically analyzed to find the level of significant using mean, standard deviation (SD), standard error mean (SEM), etc. statistical analysis was further done using Paired 't' test, unpaired 't' test, percentage increase and Z test.

Since statistically significant difference in the volume was seen after instrumentation in both the groups, percentage increase was calculated for both the groups to evaluate the percentile increase in the volume of each group. Thereafter, Z test was applied to find the level of significance between the volume changes.

There was a statistically significant difference between all the parameters judged for the present study that is:

1. Instrumentation with ProTaper Rotary system took significantly less time than instrumentation with manual NiTi K-file.

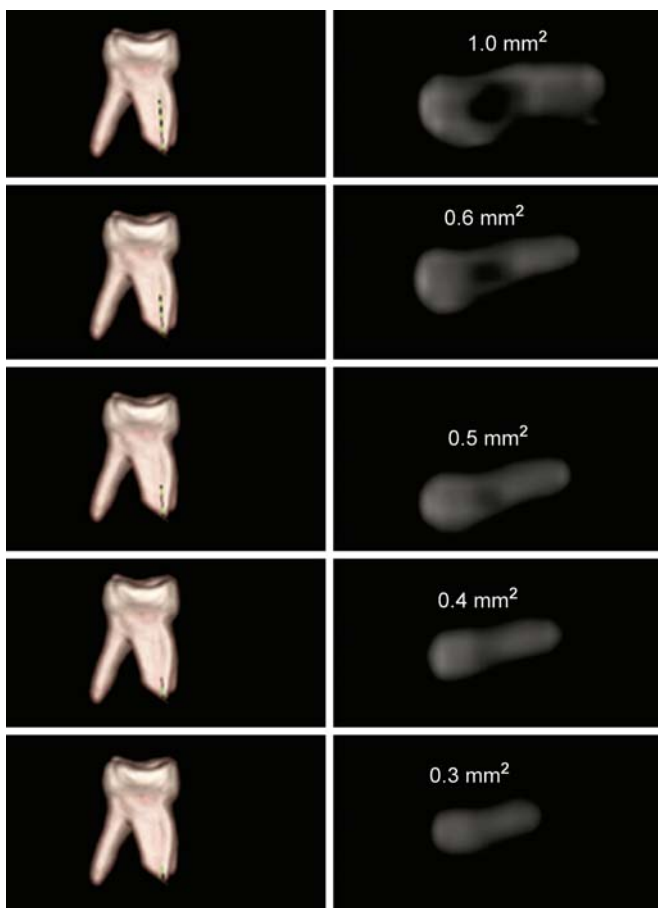
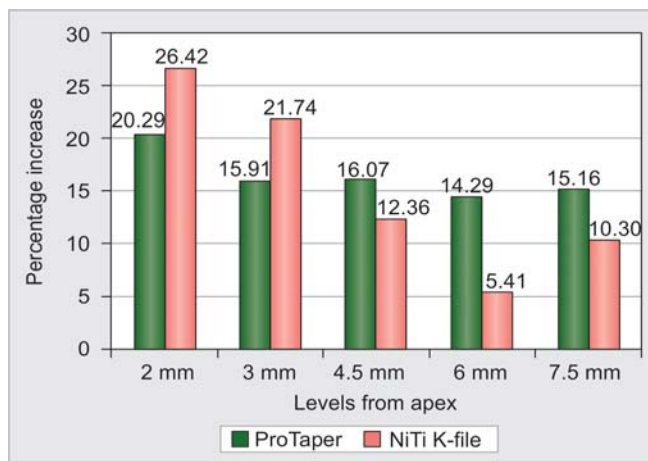


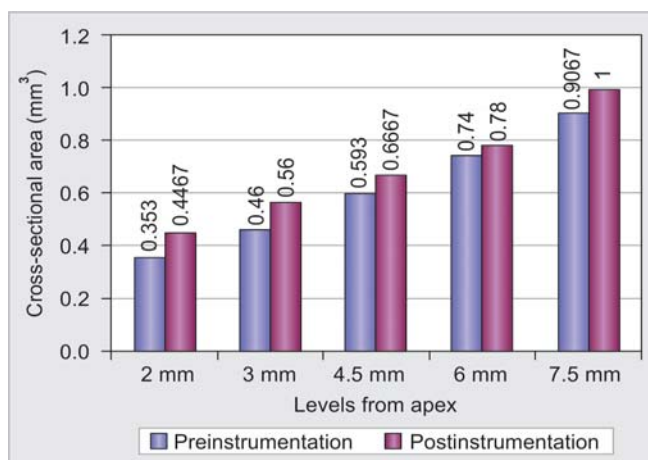
Fig. 1: Sample prepared with ProTaper Rotary Preinstrumentation cross-sectional area at predetermined levels from the apex (CT scan)

2. Change in the canal volume following instrumentation with ProTaper Rotary was significantly greater than that produced by manual NiTi K-file (Table 1).
3. a. Change in cross-section area at 2 mm and 3 mm from the apex was significantly greater with manual NiTi K-file as compared to ProTaper Rotary (Graphs 1 to 3).
- b. Change in cross sections at 4.5, 6 and 7.5 mm from the apex with ProTaper Rotary was significantly greater than that produced by manual NiTi K-file (Graphs 1 to 3).

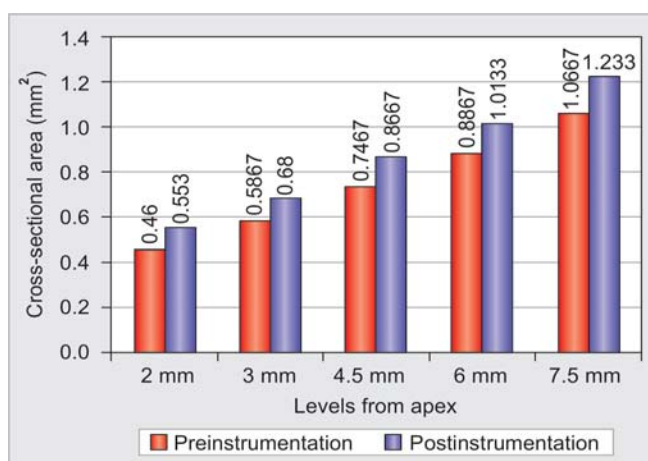
Based on the results, it was concluded that there is a drastic difference in the shaping ability of manual and rotary NiTi instruments used with step back and crown down technique respectively with the rotary instrumentation being faster and producing greater changes in the canal anatomy.



Graph 1: The percentage increase in cross-sectional area between proTaper and NiTi K-file at various predetermined levels



Graph 2: The mean value of pre- and postinstrumentation cross-sectional areas at different predetermined levels for NiTi K-file group



Graph 3: The mean values of cross-sectional areas at different predetermined levels for ProTaper Rotary group

Table 1: t-values using unpaired 't' test for comparison of pre- and postinstrumentation volume with the respective mean and standard deviation values for both groups

Materials	Pre-inst	SEM	Post-inst	SEM	t _{cal}	t _{tab}	p-value
ProTaper Rotary	0.032 ± 0.007973	0.002059	0.048067 ± 0.007842	0.002024	5.5788	t (28, 0.05) 1.701 t (28, 0.01) 2.47	<0.05 <0.01
NiTi K-file	0.024 ± 0.007946	0.002052	0.030533 ± 0.008228	0.00212	2.21	t (28, 0.05) 1.701 t (28, 0.01) 2.47	<0.05 >0.01

DISCUSSION

For the evaluation of root canal preparation of different instruments, two experimental models often use are simulated root canals in clear resin blocks or root canals in extracted human teeth. Another reason for its use was to simulate *in vivo* conditions.¹⁹ The shaping ability of progressive versus constant paper instruments was compared previously insulated canals (Yang et al).⁹

The ProTaper Rotary system consisting of three 'shaping' and three 'finishing' files. The distinguishing features of the ProTaper system (Dentsply/Tulsa Dental) a 'progressive preparation' in both vertical and horizontal directions. The file blades engage a smaller area of dentin, thus reducing torsional load that leads to instrument fatigue and file separation. During rotation, there is also an increased tactile sense when compared with traditionally shaped rotary instruments.⁸

- An S1 file (shaping files no. 1, Taper 0.02-0.11; size 17) was used to one-third of the working length
- An SX (auxillary shaping file; Taper 0.035-0.19; size 19) used to one-half of the working length.
- An S1 file was used to one-half to two-thirds of the working length.
- An S2 file (shaping file no. 2; Taper 0.04-0.115; size 20) was used to two-thirds of the working length.
- An F1 file (finishing file no. 1; Taper 0.07-0.055; size 20) was used to the full working length.
- An F2 file (finishing file no. 2; Taper 0.08-0.055; size 25) was used to the full working length.^{6,7}

In this study, canals prepared with ProTaper instruments had larger cross-sectional areas in the coronal and middle parts, (4.5, 6, 7.5 mm from apex) as compared to NiTi K-file. This could be attributed to the larger diameters of the instrument F2. A study that suggests the same is one in which manual technique using hand NiTi K-file maintained greater dentine thickness then the Rotary ProTaper technique at middle and coronal third (Nagaraja Shruti et al).¹⁵ Another study which supports this results is the shaping ability of progressive versus constant taper instruments in curved root canals of extracted teeth (GB Yang et al 2007).⁹ In the progressive ProTaper system (Dentsply Maillefer), the shaping files (S) have an increasing taper from tip to coronal, whereas the finishing files (F) have a decreasing taper. It has been claimed that the increasing taper instruments have enhanced flexibility in the middle region and at the tip, and that the decreasing taper instruments provided a larger taper in the important apical resin but make them stiff (Bergmens et al 2003).¹⁰ Various other studies have been conducted comparing the shaping ability of progressive taper (ProTaper) versus

Constant Taper (Hero 642) instruments in simulated root canals (Yang et al 2006).⁹

There was significant change increase in volume detected in this study confirming finding reported in another study in which relative performance of ProTaper NiTi instruments were evaluated in shaping root canals of varying preoperative canal geometry.⁷

In another study, NiTi K-file showed maximum volume increase in apical 4 mm alongwith profile as compare to ProTaper and least volume was seen with GT Rotary on Micro-CT analysis.¹⁸

In this study, in order to introduce the technique as variable 0.02 tapered NiTi K-file was used with a step-back technique. The advantage of this alloy's performance over stainless steel files have been reported to be less straightening the original canal shape, less development of ledges, apical zipping, canal transportation and perforations.²¹

NiTi instruments function differently than those made of stainless steel, even when cross-section design, taper, flutes and tip are identical.⁸

Furthermore, both rotary and hand NiTi instruments retained the original form in all instrumented canals with curvatures varying from 20 to 40°, compared with stainless steel instruments.¹¹

This study found that change in cross-section area at 2 and 3 mm from the apex was significantly greater with manual NiTi K-file as compared to ProTaper Rotary. This study corroborates the results of another study in which apical preparations of Lightspeed Rotary and nickel-titanium were compared and was seen that at distances 1.25 and 3.25 mm from apex. The NiTi K-files increased the, cross-sectional area of the prepared canal so much that it corresponded to the cross-sectional area of a size 70 file although the Master Apical File was only a size 45. Whereas lightspeed preparations increased the cross-sectional area to that of a size 62.5 instrument, although instrument no. 52.5 was used at that level (Pia Deplazes et al 2001).¹²

Instrumentation with ProTaper Rotary system took significantly less time than instrumentation with manual NiTi K-file. Other studies carried out which support this observation and establish that instruments with progressive taper can shape canals more quickly than constant taper instruments (Veltri et al 2005).²⁰

The use of the CT scan at 50 micron resolution proves a practical and nondestructive technique for assessment of canal morphology before and after shaping.¹³ The volume data set was analyzed using Advantage Windows 4.2 software on Advantage Windows Workstation.

The CT scans were an improvement over the technique designed by Bramante et al (1987)¹⁴ and enhanced by other subsequent investigators. No destructive sectioning of the specimens is required and there is no loss of root material during sectioning which could effect instrumentation outcomes. The CT scans allow easy measurement of canal changes, as each image has an accurate scale, decreasing the potential of a radiographic or photographic transfer error^{16,17} and helps to overcome safely and effectively some other problems associated with conventional radiograph.¹⁹

The cost of scanning procedure is also a consideration that currently inhibits the universal utilization of this methodology.¹³

There are various studies in accordance with the results of this study (GB Yang et al 2007)⁹, (OA Peters et al 2003)⁴ and (Pia Deplazes et al 2001).¹²

REFERENCES

1. Tasdemir T, Aydemir H, Inan U, Ünal O. Canal preparation with Hero 642 rotary NiTi instruments compared with stainless steel hand K-file assessed using computed tomography. *Int Endodontic Journal* 2005;38:402-408.
2. Versumer J, Hülsman M, Schafers F. A comparative study of root canal preparation using Profile. 04 and Lightspeed rotary NiTi instruments. *Int Endodontic Journal* 2002;35:37-46.
3. Walia H, Brantley WA, Gerstein. An initial investigation of the bending and torsional properties of nitinol root canal files. *JOE* 1988;14:346-351.
4. Peters OA, Schönenberger K, et al. Effects of four NiTi preparation techniques on root canal geometry assured by micro computed tomography. *Int Endodontic Journal* 2001;34:221-230.
5. Calberson FLG, et al. Shaping ability of ProTaper Nickel-Titanium files in simulated resin root canal. *Int Endodontic Journal* 2004;37:613-623.
6. Mario V, Aniello M, et al. In vitro comparison of shaping abilities of ProTaper and GT Rotary files. *J Endodon* 2004 Mar; 30(3):163-166.
7. Peters OA, Peters CI, et al. ProTaper rotary root canal preparation: effects of canal anatomy on final shape analysed by micro CT. *Int Endodontic Journal* 2003;36:86-92.
8. Ingle, Bakland. *Endodontics*, 5th ed. Elsevier: 405-570.
9. Yang GB, Zhou XD, et al. Shaping ability of progressive versus constant taper instruments in curved root canals of extracted teeth. *Int Endodontic Journal* 2007;40:707-714.
10. Bergmens L, et al. Progressive versus constant tapered shaft design using NiTi. Rotary instruments. *Int Endodontic Journal* 2003;35:820-828.
11. Tepel J, et al. Properties of endodontic hand instruments used in rotary motions (Part 3). Resistance to bending and fracture. *JOE* 1997;23:141.
12. Deplazes P, et al. Comparing apical preparations of root canals shaped by nickel-titanium hand instruments. *JOE* 2001; 27: 197-202
13. Gluskin AH, Brown DC. A reconstructed computerized tomographic comparison of NiTi rotary GTTM files versus traditional instruments in shaped canals by novice operators. *Int. Endodontic Journal* 2001;34:476-484.
14. Bramante CM, Berber A. A methodology for evaluation of root canal instrumentations. *JOE* 1987;13:243-245.
15. Shruthi N, Murthy Srinivasa BV. CT evaluation of canal preparation using rotary and hand NiTi instruments: an in vitro study. *J Conserv Dent* 2010 Jan-Mar;13(1):16-22.
16. Nair KM, Nair U. Digital and advanced imaging in endodontics: a review. *JOE* 2007 Jan;33(1):1-6.
17. Rhodes JS, Pittford TR. Microcomputed tomography: a new tool for experimental endodontology 1999;32:165-170.
18. Frank P, Genahi D, Peters OA. Effects of root canal preparation on apical geometry assessed by micro-computed tomography. *JOE* 2009 July;35(7):1056-1059.
19. Patel S, Dawood A, Whaites E, Pitt T. New dimensions in endodontics imaging: Part 1. Conventional and alternative radiographic systems, *Int Endodontic Journal* 2009 June; 42(60):447-462.
20. Veltri M, Mollo A, Mantovani L. A comparative study of endo flare-Heroshaper and M two NiTi instruments in the preparation of curved canals, *Int Endodontic Journal* 2005;38:610-616.
21. Pettiette MJ, Martin T. Evaluation of success root of endodontic treatment performed by students with stainless steel K-file and NiTi hand files. *JOE* 2000;27:124-126.

ABOUT THE AUTHORS

Surbhi Kakar

Senior Resident, Department of Endodontics, Maulana Azad Institute of Dental Sciences, New Delhi, India

Correspondence Address: 106, Nilgiri Apartments, Alaknanda New Delhi-110019, India, Phone: 9871603152, 011-42143096, e-mail: kakarsurbhi@gmail.com

Anil Dhingra

Professor, Department of Conservative and Endodontics, Subharti Dental College, Meerut, Uttar Pradesh, India

Himanshu Sharma

Reader, Department of Conservative and Endodontics, Subharti Dental College, Meerut, Uttar Pradesh, India