



Histometric Study of Resorption on Replanted Teeth with Enamel Matrix-derived Protein

Marcelo Tomas de Oliveira, Luiz Guilherme Bentregani, Braulio Pasternak, Fabio Dagostin Cancelier, Diego Rocha de Jesus, Gustavo Otoboni Molina

ABSTRACT

Background: Enamel matrix-derived proteins (Emdogain) stimulate the proliferation of periodontal ligament cells, contributing to their regeneration.

Aim: This study was to perform histometric assessment of root surface resorption in replanted teeth with the use of Emdogain®.

Materials and methods: Male Wistar rats (*Rattus norvegicus*), weighing 180 to 200 gm, were anesthetized, subjected to extraction of the upper right incisor tooth, which was then replanted into the alveoli with the following treatment: (a) control group - tooth with root canal filled with calcium hydroxide paste and (b) treated group - tooth with root canal filled with enamel matrix-derived protein. The animals were sacrificed 25 days after tooth replantation. The maxilla was processed to obtain thin sections (6 μ) and stained with hematoxylin and eosin. The resorption volume percentage of each dental element was calculated from the cemento-enamel junction to the apex.

Results: Quantification of resorption revealed that Emdogain-treated teeth showed a lower percentage of resorption (31.58%) compared to controls (80.48%) (statistically significant values – t-test p-value = 0.0431).

Conclusion: It was concluded that Emdogain used as root canal filling has properties capable of showing a lower percentage of resorption in replanted teeth.

Keywords: Resorption, Enamel matrix-derived proteins, Emdogain, Replantation, Avulsion.

How to cite this article: de Oliveira MT, Bentregani LG, Pasternak B, Cancelier FD, de Jesus DR, Molina GO. Histometric Study of Resorption on Replanted Teeth with Enamel Matrix-derived Protein. J Contemp Dent Pract 2013;14(3):468-472.

Source of support: Nil

Conflict of interest: None declared

INTRODUCTION

Dental replantation has been the subject of much research in the dental field because of the large number of tooth

losses caused by traumatic avulsions. Despite several studies, failures in dental replantation techniques are still very numerous. Most often, root resorption is the main cause, which can lead to complete destruction of the root portion.^{1,2}

For most authors, the success of tooth replantation depends on maintaining the vitality of the periodontal ligament.³⁻¹³ Without the biological protection of the periodontal ligament, cementum becomes replaced by bone tissue, and the root can be replaced completely by this tissue.^{13,14} On the other hand, remaining necrotic periodontal ligament can be replaced by bone or initiate a process of resorption.¹³⁻¹⁵

When most of the periodontal ligament appears degenerated, even in the presence of a vital radicular pulp tissue or necrotic but sterile tissue, the occurrence of ankylosis is inevitable.^{16,17}

In order to reduce dental root resorption and ankylosis, several substances have been used for the treatment of the root surface of teeth to be replanted, such as simple or acidulated fluoride solution,^{18,19} thyrocalcitonin,²⁰ calcium hydroxide paste associated with para-mono-chlorophenol methylcellulose,²¹ polylactic acid,²² but without significant results.

In this context, enamel matrix-derived proteins have shown good results in periodontal regeneration techniques, promoting the formation of new bone, periodontal ligament and cementum.²³⁻²⁷

When applied on the root surface, these proteins provide a niche for mesenchymal cells and stimulate cell differentiation into cementoblasts, osteoblasts and fibroblasts, thus promoting periodontal regeneration.²⁵

The aim of this study was to analyze histometrically the effect of EMD application on replantation-associated resorption.

MATERIALS AND METHODS

All procedures were conducted in accordance with the ethical principles of animal experimentation (register number 05186402-III). For this study, we used 16 Wistar male rats (*Rattus norvegicus*), aged 50 to 70 days and weighing between 180 and 200 gm, from the vivarium of the Unisul University Dental School. The rats were housed in individual cages and kept under controlled lighting conditions (12 hours light/dark cycle) and temperature (21-25°C), and fed with balanced food pellets and water *ad libitum*.

The animals were anesthetized with sodium thiopental injected intraperitoneally at a dose of 0.3 ml per 100 gm of body weight. They were divided into control group (CG) and treated group (TG) as follow:

Group I (Control-CG)

After extraction of the right upper incisor of each animal, using instruments specially adapted for that purpose, the teeth were placed in containers with a saturated solution of sodium chloride. After 45 minutes, they were involved in gauze soaked with saline solution, and the tooth canals were retrograde instrumented with a #15 Kerr file (Les Fils d'Auguste Maillefer SA, Switzerland). Then, they were retrofilled with calcium hydroxide paste and immediately replanted in the alveoli. None drugs, analgesics or antibiotics, postreplantation were used.

Group II (Treatment with Enamel Matrix Protein-GT)

The same procedures were followed for this group, and tooth canals were filled with enamel matrix-derived proteins [Emdogain® (EMD), Biora AB, Ideon/Malmö, SE-205 12 Malmö, Sweden].

The commercially available formulation shows that these proteins are made up of 90% amelogenin and 10% of other proteins derived from pig enamel matrix.^{24,27} In addition to these proteins, it has propylene glycol alginate as a vehicle, which turns into viscous substance at room temperature and acidic pH. After application, at body temperature and neutral pH, the enamel matrix-derived protein precipitates in the form of insoluble spherical complexes that remain at the application site for 2 weeks.

Twenty-five days after surgery, the animals were sacrificed by an anesthetic overdose of thiopental sodium. Their mandibles were separated from the maxillae with the use of scissors, and the right maxilla was separated from the left through an incision at the midsagittal plane following the intermaxillary suture. A cut tangent to the distal surface of molars using a straight scissors allowed the collection of the portion of the replanted tooth and its associated

structures. The right hemimaxillae were immersed in 10% formalin for fixation, decalcified for 4 days in a 20% sodium citrate solution and 30% formic acid, washed in running tap water for 24 hours, dehydrated, cleared, embedded in paraffin and positioned so as to permit longitudinal cuts at a thickness of 6 µ, stained with hematoxylin and eosin. Twenty sections were obtained at 50 mm intervals apart from each other.

Histometric Analysis

The sections were examined using a stereoscope (Carl Zeiss, Gottingen, Germany); image capture and quantitative analysis of the periodontal tissues were performed using Image J® system (Research Services Branch, National Institute of Mental Health, Bethesda, Maryland, USA). For histometric analysis, we selected a picture of each animal by determining the amount (perimeter) of resorption of each dental element from the cemento-enamel junction to the apex.

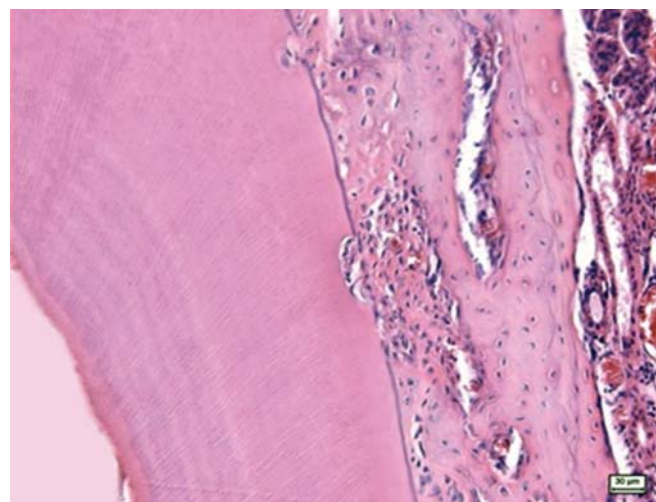


Fig. 1: Calcium hydroxide: histological picture showing the surface of root resorption in teeth filled with calcium hydroxide. Hematoxylin and eosin staining

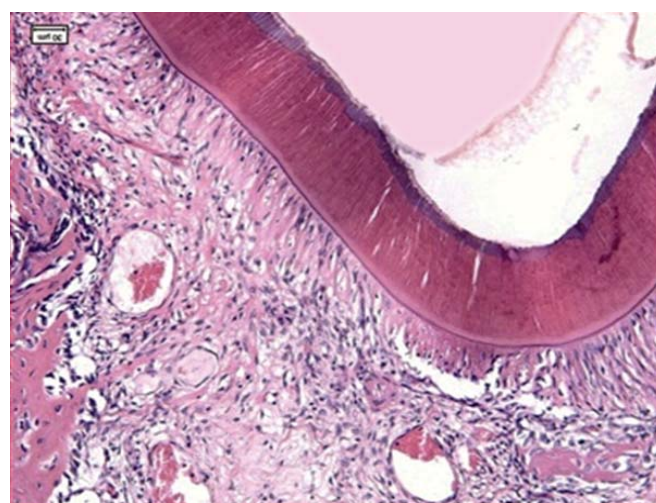


Fig. 2: Emdogain group: histological picture of intact root surface in teeth filled with Emdogain. Hematoxylin and eosin staining

Comparisons of data obtained in the histometric analysis were performed using parametric t-test (p-value = 0.0431).

RESULTS

The histological evaluation demonstrated extensive tooth resorption on the root surfaces of teeth that were filled with calcium hydroxide (Fig. 1) and less extensive resorption when intracanal Emdogain was applied (Fig. 2).

Table 1: Descriptive statistics of the resorption percentage of the total root surface perimeter: for each group (N = 8), mean, standard error (SE) and result of the significance test (a, b)

Group	N	Mean	SE	p-value
Emdogain	8	31.58 ^a	3.123	0.0006
Calcium hydroxide	8	80.48 ^b	6.266	

*In mean column; different letters are statistical significance at 5%

The histometric analysis provided quantitative data of the root resorption process following the use of intracanal calcium hydroxide and EMD. As showed in Table 1, quantification of resorption revealed that EMD-treated teeth showed a lower percentage of resorption (31.58%) compared to controls (80.48%) (statistically significant values– t-test p-value = 0.0431).

The percentage of root surface resorption of analyzed teeth for each animal in the different groups can be observed in Table 2, where Emdogain group have the best behavior in all of them.

DISCUSSION

Emdogain is a commercial compound derived from amelogenin, a protein that is the main component of the enamel matrix. It was suggested as an alternative to bone grafts and membranes in the treatment of periodontal defects¹⁴ and has shown good results in periodontal regeneration techniques, promoting the formation of new bone, periodontal ligament and cementum.^{22,27}

EMD has shown to be effective in stimulating the formation of acellular cementum on traumatized root,^{24,25} and the proliferation of periodontal ligament cells, thus promoting periodontal ligament regeneration.^{2,23,26}

The histological results of this study showed that, when applied intracanal, EMD has biocompatibility and was integrated into the periodontal tissue, decreasing the production of dental resorption compared with the use of calcium hydroxide. These results suggest that matrix

proteins in EMD have characteristics that make it capable of interfering with the resorption process of replanted teeth,^{28,29} probably by acting on clasts in a still unclear mechanism. However, further studies are needed to better understand the properties of this material and its interaction with the cell bodies in which they are intended to be used.

What can be suggested is that due to the ability of EMD to stimulate the proliferation of periodontal ligament cells on the root surface as well as the differentiation of mesenchymal cells into osteoblasts and cementoblasts, the inflammatory process may have decreased, and consequently, the root resorption. This interaction can be explained by cell adhesion that is mediated by cell surface receptors interacting with EMD proteins, forming a monoadhesive layer. Then, macrophages are activated to produce growth factors of cytokines that are important to induce the tissue repair process. The platelet-derived growth factor (PDGF), transforming growth factors (TGF), interleukin (IL)-1 and other stimulators of cell migration exacerbate the inflammatory process at the lesion site, while the fibroblast growth factor (FGF) and vascular endothelial growth factor (VEGF) induce the angiogenesis process.

Have been suggest that EMD promotes proliferation of mesenchymal cells and inhibits epithelial cell, and that the release of autocrine growth factors in periodontal ligament cells exposed to EMD, among which TGF-β1, IL-6 and PDGF-AB, contributes to periodontal tissue repair and regeneration in a process similar to what occurs during normal root development.^{28,29}

Calcium hydroxide was chosen as one of the filling materials because it reduces resorption and stimulates bone formation, due to its bactericidal potential. It also inactivates osteoclast stimulation due to the increase in the pH that in some situations can go up to as high as 10,³⁰ being a good parameter for comparison with EMD, not yet used as filling material.

Although EMD has been placed inside the root canal simulating an intracanal medication, it has not similar action to calcium hydroxide, which, due to dissociation of the hydroxyl ions, reaches the resorption area through the dentinal tubules.³¹ Because EMD was placed as the apical foramen when the specimens were replanted, there was a leakage of the material that settled in the space between the cementum and alveolar bone, thus explaining its action in the periodontal ligament and cementum.

The results showed a lower percentage of resorption in the EMD group than in the CG, possibly due to the property

Table 2: Percentage of root surface resorption of analyzed teeth for each animal in the different groups

	R1	R2	R3	R4	R5	R6	R7	R8
Emdogain	48.45	47.31	27.92	30.23	32.92	26.26	27.92	38.16
Calcium hydroxide	80.32	75.67	94.66	81.33	100.00	100.00	54.08	57.79

to stimulate the proliferation of periodontal ligament cells, allowing the formation of new cementum and bone tissue,²³ and then suggest that the enamel matrix-derived proteins have properties that can reduce root resorption of replanted teeth. However, the study does not explain exactly the intrinsic mechanisms involved in this process.

CONCLUSION

It was concluded that Emdogain used as root canal filling has properties capable of showed a lower percentage of resorption in replanted teeth.

REFERENCES

- Andreasen JO, Hjorting-Hansen E. Replantation of teeth II. Histological study of 22 replanted anterior teeth in humans. *Acta Odontol Scand* 1996 Nov;24(3):287-306.
- Andreasen JO. The effect of splinting upon periodontal healing after replantation of permanent incisors in monkeys. *Acta Odontol Scand* 1975;33(6):313-323.
- Hammarstrom L, Lindskog S. General morphological aspects of resorption of teeth and alveolar bone. *Int Endod J* 1985 Apr;18(2):93-108.
- Loe H, Waerhaug J. Experimental replantation of teeth in dogs and monkeys. *Arch Oral Biol* 1961 Apr;3:176-184.
- Deeb E, Prietto PP, McKenna RC. Reimplantation of luxated teeth in humans. *J South Calif Dent Assoc* 1965 Apr;33(4):194-206.
- Nordeman A, Bang G, Anneroth G. A histopathologic study of replanted teeth with superficially demineralized root surface in java monkeys. *Scand J Dental Res* 1973 Oct;81(4):294-302.
- Barbakow FH, Austin JC, Cleanton-Jones PE. Experimental replantation of root canal filled and untreated teeth in the vervet monkeys. *J Endod* 1977 Mar;3(3):89-93.
- Andreasen JO, Reinholdt J, Riis I, Dybdahl R, Söder PO, Otteskog P. Periodontal and pulpal healing of monkey incisors preserved in tissue culture before replantation. *Int J Oral Surg* 1978 Apr;7(2):104-112.
- Nevins AJ, Laporta RF, Borden BG, Lorenzo P. Replantation of enzymatically treated teeth in monkeys. Part I. *Oral Surg Med Oral Pathol* 1980 Sep;50(3):277-281.
- Oswald RJ, Harrington GW, Van Hassel HJ. A postreplantation evaluation of air-dried and saliva stored avulsed teeth. *J Endod* 1980 May;6(5):546-551.
- Andreasen JO. Periodontal healing after replantation and autotransplantation of incisors in monkey. *Int J Oral Surg* 1981 Feb;10(1):54-61.
- Leite MC, Okamoto T. The influence of extra oral time upon healing after replantation: a histological study in rat incisors. *J Nihon Univ Sch Dent* 1984 Dec;26(4):316-330.
- Nyman S, Houston F, Sarned G, Lindhe J, Karring T. Healing following replantation of teeth subjected to root planing and citric acid treatment. *J Clin Periodontol* 1985 Apr;12(4):295-305.
- Hammarstrom L, Blomlof L, Lindskog S. Dynamics of dentoalveolar ankylosis and associated root resorption. *Endod Dent Traumatol* 1989 Aug;5(4):163-175.
- Andreasen JO. Relationship between cell damage in the periodontal ligament after replantation and subsequent development of root resorption. A time-related study in monkeys. *Acta Odontol Scand* 1981;39(1):15-25.
- Andreasen JO. Relationship between surface and inflammatory resorption and the changes in the pulp after replantation of permanent incisors in monkeys. *J Endod* 1981 Jul;7(7):294-301.
- Coccia CT. A clinical investigation of root resorption rates in reimplanted young permanent incisors: a five-year study. *J Endod* 1980 Jan;6(1):413-420.
- Mahajan SK, Sidhu SS. Effect of fluoride on root resorption of autogenous dental replants. Clinical study. *Aust Dent J* 1981 Feb;26(1):42-45.
- Shulman LB, Kallis P, Goldhaber P. Fluoride inhibition of tooth-replant root resorption in Cebus monkeys. *J Oral Ther Pharmac* 1968 May;4(5):331-337.
- Barbakow FH, Cleaton-Jones PE, Austin JC, Vieira E. Healing of replanted teeth following topical treatment with fluoride solutions and systemic admission of thyrocalcitonin: a histometric analysis. *J Endod* 1981 Jul;7(7):302-308.
- Hardy LB, O'neal RB, Del Rio CE. Effect of polylactic acid on replanted teeth in dogs. *Oral Surg* 1981 Jan;51:86-92.
- Mellonig J. Enamel matrix derivative for periodontal reconstructive surgery: technique and clinical and histologic case report. *Int J Periodont Rest Dent* 1999 Feb;19(1):9-19.
- Gestrelus S, Anderson C, Johansson AC, Person E, Brodin A, Rydhag L, Hammarström L. Formulation of enamel matrix derivative for surface coating-kinetics and cell colonization. *J Clin Periodontol* 1997 Sep;24(9 Pt 2):678-684.
- Araújo MG, Lindhe J. GTR treatment of degree III furcation defects following application of enamel matrix proteins. An experimental study in dogs. *J Clin Periodontol* 1998 Jun;25(6):524-530.
- Kanazashi M, Gomi K, Nagano T, Tanabe T, Arai T, Fukae M. The 17-kDa sheath protein in enamel proteins induces cementum regeneration in experimental cavities created in a buccal dehiscence model of dogs. *J Periodontal Res* 2006 Jun;41(3):193-199.
- Gestrelus S, Andersson C, Lidström D, Hammarström L, Somerman M. In vitro studies on periodontal ligament cells and enamel matrix derivative. *J Clin Periodontol* 1997 Sep;24(9 Pt 2):685-692.
- Van der Pauw MT, Van den Bos T, Everts V, Beerstsen W. Enamel matrix-derivative protein stimulates attachment of periodontal ligament fibroblasts and enhances alkaline phosphatase activity and transforming growth factor β 1 release of periodontal ligament and gingival fibroblasts. *J Periodontol* 2000 Jan;71(1):31-43.
- Molina GO, Brentegani LG. Use of enamel matrix protein derivative before dental reimplantation: a histometric analysis. *Implant Dent* 2005 Sep;14:267-273.
- Filippi A, Pohl Y, von Arx T. Treatment of replacement resorption with Emdogain—a prospective clinical study. *Dent Traumatol* 2002 Jun;18(3):138-143.
- Tronstad L, Andreasen JO, Hasselgren G, Kristerson L, Riis I. pH changes in dental tissues after root canal filling with calcium hydroxide. *J Endod* 1981 Jan;7(1):17-21.
- Siqueira JF Jr, Lopes HP. Mechanisms of antimicrobial activity of calcium hydroxide: a critical review. *Int Endod J* 1999 Sep;32(5):361-369.

ABOUT THE AUTHORS

Marcelo Tomas de Oliveira (Corresponding Author)

Professor, Department of Health Master Program-Dental Materials, University of Southern Santa Catarina, SC, Brazil, Phone: 4884264754, e-mail: marcelo.oliveira@unisul.br

Luiz Guilherme Bentregani

Professor, Department of Histology, USP, São Paulo, Brazil

Braulio Pasternak

Professor, Department of Endodontics, ABO SC, SC, Brazil

Fabio Dagostin Cancelier

Undergraduate, Department of Dentistry, Universidade do Sul de Santa Catarina, SC, Brazil

Diego Rocha de Jesus

Undergraduate, Department of Dentistry, Universidade do Sul de Santa Catarina, SC, Brazil

Gustavo Otoboni Molina

Professor, Department of Periodontics, Universidade do Sul de Santa Catarina, SC, Brazil