



A Cephalometric Study to Determine the Center of Anteroposterior Curve of Occlusion in the Cranium

Thota Kiran Kumar, Vivek Thomas, Sanjay Nilawar, R Balamurugan, Baldeep Singh Marwaha, V Vinod

ABSTRACT

Proper management of the occlusal plane is an essential consideration when multiple long span posterior restorations are designed. When restorations are added to an existing tooth arrangement characterized by rotated, tipped or extruded teeth, excursive interferences may be incorporated. The curve of Spee which exists in natural dentition, allows harmony to exist between the anterior teeth and the condylar guidance. Broadrick flag or occlusal plane analyzer is used to assist in the reproduction of tooth morphology that is commensurate with the curve of Spee when posterior restorations are designed; its use prevents the introduction of protrusive interferences. The current study determines the relationship of the center of anteroposterior curve of occlusion in the cranium and its relationship to other cephalometric landmarks and also evaluates the relationship of anteroposterior curve of occlusion to the condyle.

Keywords: Nasion, Orbitale, Lachryma, Curve of occlusion, Condylar axis.

How to cite this article: Kumar TK, Thomas V, Nilawar S, Balamurugan R, Marwaha BS, Vinod V. A Cephalometric Study to Determine the Center of Anteroposterior Curve of Occlusion in the Cranium. *J Contemp Dent Pract* 2013;14(5):836-841.

Source of support: Nil

Conflict of interest: None declared

INTRODUCTION

The configuration of the occlusal plane is one of the most beautiful examples of design that can be found in nature. The form of occlusal plane is directly related to specific functional requirements. In addition to alignment of teeth in relationship to the arc of closure for best resistance to loading, it should permit ease of access for positioning of the food on the occlusal surfaces. If these two functional requirements are met, an occlusal plane is acceptable if it permits the anterior guidance to do this job.¹

The term 'plane of occlusion' refers to an imaginary surface that theoretically touches the incisal edges of the

incisors and the tips of the occluding surfaces of the posterior teeth. The curvatures of the anterior teeth are determined by the establishment of an esthetically correct smile line on the upper and lower incisal edges and phonetic requirements.⁷

The morphological arrangement of teeth in the sagittal plane has been related to the slope of the articular eminence, incisor vertical overlap, molar cusp height and the amount of posterior contact. A matched interaction between these features and the curve of Spee ensures balanced occlusal function.^{2,3} More recently, it has been also suggested that the curve of Spee has a biomechanical function during food processing by increasing the crush shear ratio between the posterior teeth and the efficiency of occlusal forces during mastication.⁴

The Broadrick occlusal plane analyzer permits reconstruction of the curve of Spee in harmony with the anterior and the condylar guidance, allowing total posterior tooth disocclusion on mandibular protrusion. The Broadrick occlusal plane analyzer is a valuable tool in prosthodontics and restorative dentistry, in that it locates the center of the curve of Spee. Extensive restorations designed with this tool permit mandibular excursions free from posterior interferences. With use of the Broadrick occlusal plane analyzer, the prosthodontist can predictably produce high quality restorations in harmony with the anterior and condylar guidance.⁵ But, there have been no relevant clinical and cephalometric studies to determine the center of antero- posterior curve and thereby its radius in Indian population.

MATERIALS AND METHODS

Sixty subjects were selected for the study that included dental student volunteers of VS Dental College and Hospital and the out patients who visited to the hospital for the treatment purpose. The subjects were selected based on the following criteria and its relation to the condyle.

Inclusion Criteria

1. Age group: 18 to 30
2. Full complement of permanent teeth
3. Individuals with skeletal class 1 occlusion with minor malocclusion like crowding, spacing and rotation are acceptable.

Exclusion Criteria

1. Previous orthodontic treatment
2. Extensive restoration, cast restoration and cuspal coverage restoration
3. Anterior and posterior crossbite and deep bite
4. Pathological periodontal conditions
5. Temporomandibular joint disorder.

Armamentarium Required (Fig. 1)

1. Lateral cephalogram X-ray machine (Planmeca, 80 kvp, 15 mA, 1 sec).
2. Lateral cephalogram X-ray films (KODAK – TMAT, Green sensitive).
3. Automatic X-ray film processor (Durr Dental X R 25s).
4. Tracing sheets (One side Matte, 50 microns thick).
5. Dome's template.
6. 4H pencil and eraser.
7. Paper clips.
8. X-ray viewer.
9. Compass.
10. Set squares.
11. Metal scale.

Lateral cephalograms of the subjects were obtained; a single sided tracing sheet (50 microns) was secured to the film with the help of paper clips.

All the lateral cephalograms were traced and the following anatomical landmarks were identified:

1. Nasion
2. Orbitale
3. Porion — superior most point of the ear rod
4. The anterior border of the condyle was determined as a tangent to the condyle parallel to the anterior limit of the mandibular canal within the ascending ramus.
5. A distal interocclusal point was established where the occlusal surface of maxillary third molar met the distal surface of the mandibular third molar in occlusion or where the distal surface of the mandibular second molar occluded with mandibular second molar.
6. The mesial interocclusal point was established where the mesial portion of the maxillary first molar met the mesial portion of mandibular first molar.
7. The tip of the lower incisor was established as close as possible halfway between the labioincisal and linguoincisal angles.
8. Lachryma was established halfway between the nasion and orbitale.

Initially an arc was sketched tentatively from the tip of the lower incisor to the anterior border of the condyle. Either mesial or distal inter occlusal point form a part of the arc and at any given point both the mesial and distal interocclusal points do not form a part of the arc.

Chords were drawn from the tip of the lower incisor to the mesial / distal interocclusal point and from mesial/distal inter occlusal point to the anterior border of the condyle. Midpoint of the chords was identified and perpendicular lines are drawn from the midpoint. The center was identified where the two perpendicular lines met. The arc was made more definitive by using a compass. Thus the center was determined.

The subjects were then divided in to two groups based on the arc which was passing either through the mesial interocclusal point or through the distal interocclusal point.



Fig. 1: Armamentarium used for the study

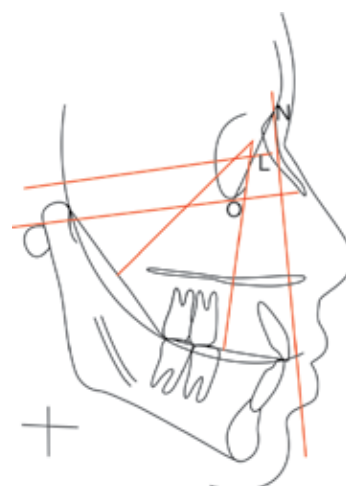


Fig. 2: Lateral Cephalometric tracing of group I subjects

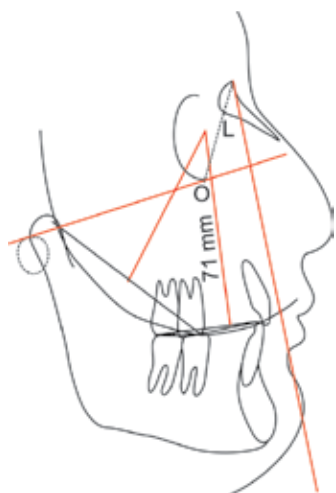


Fig. 3: Lateral Cephalometric tracing of group II subjects

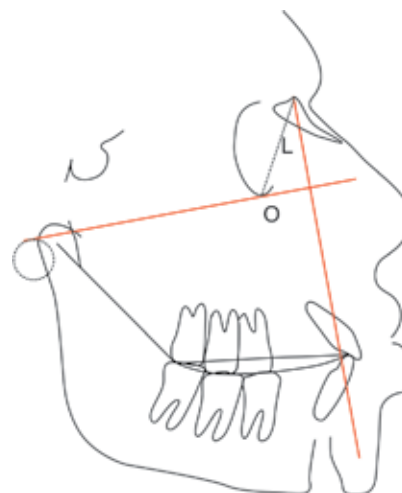

Fig. 4: Lateral Cephalometric tracing shows the relationship of curve of occlusion to the condylar axis

Group 1: The arc was passing through the tip of the lower incisor, distal interocclusal point and anterior border of the condyle (Fig. 2).

Group 2: The arc was passing through the tip of the lower incisor, mesial interocclusal point and anterior border of the condyle (Fig. 3).

Measurements were made from the center of anteroposterior curve of occlusion to the nasion, lachryma and orbitale of all sixty subjects. The radius of the arc was also measured.

To evaluate the relationship of curve of occlusion to the condylar axis, the depth of curve of occlusion was measured for all the sixty subjects. The depth of curve of occlusion was measured by connecting incisal, mesial interocclusal point and distal interocclusal points. A chord was drawn between incisal and distal points. The distance was measured from the chord to the deepest point of the curve of occlusion (Fig. 4).

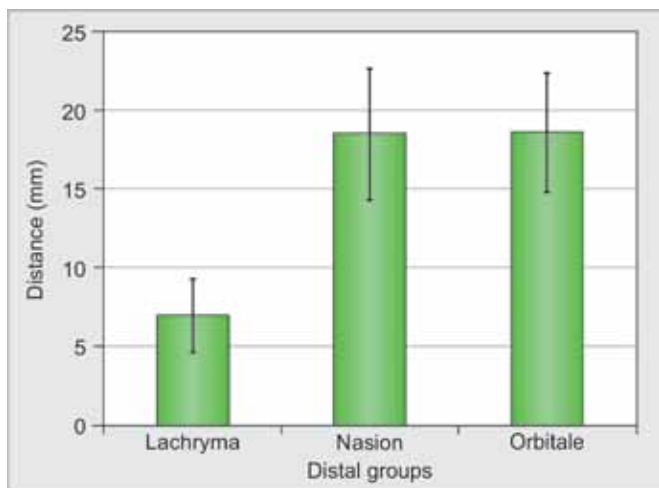
The distance from the distal point of curve of occlusion to the condylar axis was calculated for each subject.

The subjects are divided into six groups based on the depth of curve of occlusion.

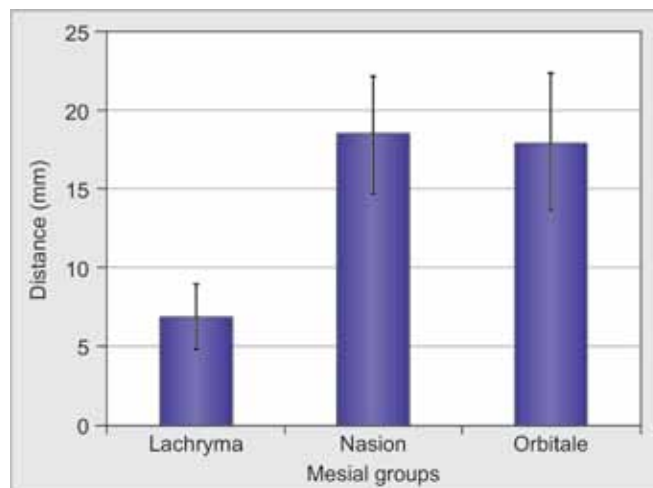
RESULTS (GRAPHS 1 TO 3)

From the above ANOVA (Table 2), it was noticed that there is a significant difference between the three anatomical landmarks to the center of curve of occlusion with respect to the mean distance from center ($p < 0.001$). To find out among which locations there is a significant difference; we carry out multiple comparisons (posthoc) test using Bonferroni method (Table 3).

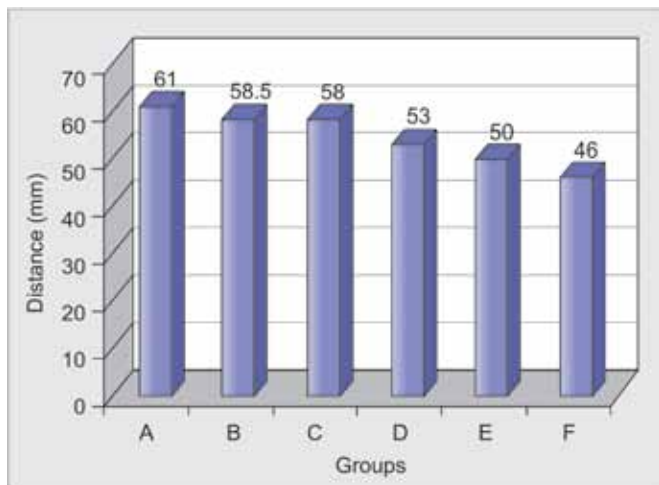
From the multiple comparisons, it was found that there is a significant difference in the mean distance from the center between lachryma and nasion locations as well as lachryma and orbitale ($p < 0.001$). But no significant difference is observed between nasion and orbitale ($p > 0.05$). The mean distance from the center is found to be lowest in lachryma when compared to nasion and orbitale and this difference is found to be statistically significant. Therefore, we



Graph 1: Mean linear distance from the center of curve of occlusion to various cephalometric landmarks included in the study group I



Graph 2: Mean linear distance from the center of curve of occlusion to various cephalometric landmarks included in the study group II



Graph 3: Median distance from distal point to condylar axis in various groups

conclude that lachryma is the nearest location to the center (Tables 4 and 5).

From the above ANOVA table, it was noticed that there is a significant difference between the three locations with respect to the mean distance from center ($p < 0.001$). To find out among which locations there is a significant difference; we carry out multiple comparisons (post-hoc) test using Bonferroni method (Table 6).

From the multiple comparisons it was found that there is a significant difference in the mean distance from the center between lachryma and nasion locations as well as lachryma and orbitale ($p < 0.001$). But no significant difference is observed between nasion and orbitale ($p > 0.05$). The mean distance from the center is found to be

lowest in lachryma when compared to nasion and orbitale and this difference is found to be statistically significant. Therefore we conclude that lachryma is the nearest location to the center of occlusion.

To evaluate the relationship of curve of occlusion to the condyle, the depth of the anteroposterior curve of occlusion is measured for all sixty subjects and compared with the distance from the distal interocclusal point to the condylar axis.

Group A: Out of 60, number of subjects having 0 mm depth of curve of occlusion are: 5.

Group B: Out of 60, number of subjects having 1 mm depth of curve of occlusion are: 24

Group C: Out of 60, number of subjects having 2 mm depth of curve of occlusion are: 18

Group D: Out of 60, number of subjects having 3 mm depth of curve of occlusion are: 5

Group E: Out of 60, number of subjects having 4 mm depth of curve of occlusion are: 5

Group F: Out of 60, number of subjects having 5 mm depth of curve of occlusion are: 3.

As the depth of curve of occlusion increases, the distance from the distal point to condylar axis decreases. That means that the curve is becoming steeper from group A to group F. i.e. the curve of occlusion for group A is almost flat and it forms a circle with long radius. So the curve will be passing far away from the condyle. The curve of occlusion for group F is steeper and it forms a circle with small radius when compared to group A, so the curve will be passing near to the condyle or almost through the condyle.

Table 1: Descriptive statistics for linear measurement from the center of curve of occlusion to various cephalometric landmarks included in the study (group I)

Measurement from the center of curve of occlusion to	N	Mean	Std Dev	95% confidence interval for mean		Min	Max
				Lower bound	Upper bound		
Lachryma	36	6.97	2.32	6.19	7.76	3.00	12.00
Nasion	36	18.44	4.13	17.05	19.84	11.00	27.00
Orbitale	36	18.53	3.76	17.26	19.80	12.00	26.00

Table 2: ANOVA –comparison of the three anatomical landmarks to the center of curve of occlusion (Group II)

	Sum of squares	Mean square	F	Significance
Between groups	3181.796	002	1590.898	130.418
Within groups	1280.833	105	12.198	
Total	4462.630	107		

Table 3: Posthoc test of Bonferroni for group I

Parameter (I)	Parameter (J)	Mean difference	Standard error	Significance	95% confidence interval	
					Lower bound	Upper bound
Dist. from Lachrym:	Dist. from nasion	-11.472*	0.823	0.000	-13.48	-9.47
	Dist. from orbitale	-11.556*	0.823	0.000	-13.56	-9.55
Dist. from Nasion:	Dist. from lachrym	11.472*	0.823	0.000	9.47	13.48
	Dist. from orbitale	-0.083	0.823	1.000	-2.09	1.92
Dist. from Orbitale:	Dist. from nasion	11.556*	0.823	0.000	9.55	13.56
	Dist. from lachrym	0.083	0.823	1.000	-1.92	2.09

Table 4: Descriptive statistics for linear measurement from the center of curve of occlusion to various cephalometric landmarks included in the study (group II)

Measurement from the center of curve of occlusion to	N	Mean	Std dev.	95% Confidence interval for mean		Min.	Max.
				Lower bound	Upper bound		
Lachryma	24	6.79	2.04	5.93	7.65	3.00	10.00
Nasion	24	18.25	3.72	16.68	19.82	12.00	27.00
Orbitale	24	17.75	4.30	15.94	19.56	12.00	29.00

Table 5: ANOVA: Comparison of the three anatomical landmarks to the center of curve of occlusion group II

	Sum of squares		Mean square	F	Significance
Between groups	2013.028	002	1006.514	82.781	0.000
Within groups	838.958	069	12.159		
Total	2851.986	071			

Table 6: Posthoc of Bonferroni for group II

Parameter (I)	Parameter (J)	Mean difference	Standard error	Significance	95% confidence interval	
					Lower bound	Upper bound
Dist. from Lachryma:	Dist. from nasion	-11.458*	0.823	0.000	-13.48	-9.47
	Dist. from orbitale	-10.958*	0.823	0.000	-13.56	-9.55
Dist. from Nasion:	Dist. from lachryma	11.458*	0.823	0.000	9.47	13.48
	Dist. from orbitale	0.500	0.823	1.000	-2.09	1.92
Dist. from Orbitale:	Dist. from nasion	10.958*	0.823	0.000	9.55	13.56
	Dist. from lachryma	-0.500	0.823	1.000	-1.92	2.09

DISCUSSION

Arrangement of the posterior teeth to follow the curve of Spee permits posterior tooth disclusion on the mandibular protrusion with given proper anterior tooth guidance. Extension of the occlusal curve through the mandibular condyle is essential when designing proper posterior disclusion. It will be appreciated that when posterior restorations are being designed, these should permit posterior disocclusion in an anteroposterior and lateral direction.⁸

The anteroposterior curve of occlusion was first described by Graf von Spee German anatomist, in 1890. So it is also called curve of Spee. He used skulls with abraded teeth to define a line of occlusion.⁹

Anteroposterior curve is defined as (GPT 2005) the anatomic curve established by the occlusal alignment of the teeth, as projected on to the median plane, beginning with the cusp tip of the mandibular canine and following the buccal cusp tips of the premolar and molar teeth, continuing through the anterior border of the mandibular ramus, ending with the anterior most portion of the mandibular condyle.¹⁰

The center of curve of occlusion is in the mid orbital plane both in groups I and II subjects. The distance of the center from lachryma is 6.79 to 6.97 mm, i.e. 2.6 to 2.7 inches. The distance of the center from nasion is 18.25 to 18.44 mm, i.e. 7.3 to 7.4 inches and from orbitale it is 17.75 to 18.53 mm, i.e. 7.1 to 7.5 inches. Therefore, it can be concluded that lachryma is closest to the center of curve of occlusion compared to nasion and orbitale.⁶

Median distance from distal interocclusal point to condylar axis was calculated for all groups and is shown in the bar graph (Fig. 4). It was shown that the median distance from distal interocclusal point to condylar axis in group A is 61 mm, group B is 58.5 mm, group C is 58 mm, group D is 53 mm, group E is 50 mm and in group F is 46 mm.

Therefore it was concluded that, as the depth of curve of occlusion increases, the distance from the distal interocclusal point to condylar axis decreases. That means the curve is becoming steeper from groups A to F, i.e. the curve of occlusion for group A is almost flat. It can be inferred that it forms a circle with long radius. The curve of occlusion for group F is steeper. It means that it forms a circle with small radius when compared to group A. So the curve will be passing near to the condyle or almost through the condyle.

Proper management of the occlusal plane is essential consideration when multiple long span posterior restorations are designed. When restorations are added to an existing tooth arrangement characterized by rotated, tipped or extruded teeth, excursive interferences may be incorporated. The curve of Spee which exists in natural dentition, allows harmony to exist between the anterior teeth and the condylar guidance. An instrument called the Broadrick flag has been used to assist in the reproduction of tooth morphology that is commensurate with the curve of Spee when posterior restorations are designed; its use prevents the introduction of protrusive interferences.⁵



LIMITATIONS OF THE STUDY

The subjects with Angles class I occlusion (molar relationship) were only studied. Subjects with Angles class II and III (molar relationship) relationship were not considered.

The length of the face was not standardized cephalometrically. As the subjects were selected at random, the facial type was not considered. (short, long and average).

CONCLUSION

The center of anteroposterior curve of occlusion is located in the mid orbital plane and lachryma is closest to the center of curve of occlusion in both groups I and II subjects. Nasion is closest to the center of curve of occlusion in group I subjects when compared to the orbitale. Orbitale is closest to the center of curve of occlusion in group II subjects when compared to the nasion.

As the depth of the curve of occlusion increases, the distance from the distal interocclusal point to condylar axis decreases. That means, the curve is becoming steeper from groups A to F.

This proves that steeper anteroposterior curve of occlusion, closer it is to the condyle and *vice versa*, i.e. shallower the anteroposterior curve of occlusion, farther it is from the condyle.

REFERENCES

1. Dawson PE. Functional occlusion from TMJ to smile design. 2nd ed. Mosby Elsevier. 2007.p.199-206.
2. Hui XU, et al. An evaluation of the curve of Spee in the maxilla and mandible of human permanent healthy dentitions. J Prosthet Dent 2004;92:536-539.
3. Shannon KR, Nanda RS. Changes in the curve of Spee with treatment and at 2 years post-treatment. Am J Orthod Dentofacial Orthop 2004;125:589-596.
4. Farella M, Michelotti A, Van Eijden TM, Martina R. The curve of Spee and craniofacial morphology: a multiple regression analysis. Eur J Oral Sci 2002;110:277-281.
5. Lynch CD, McConnell RJ. Prosthodontic management of curve of Spee: use of broadrick flag. J Prosthet Dent 2002;87: 593-597.
6. Ferrario VF, et al. Mathematical definition of the curve of Spee in permanent healthy dentitions in man. Arch Oral Biol 1992; 37:691-694.
7. Dawson PE. Evaluation, diagnosis and treatment of occlusal problems, 2nd ed. Mosby 1989;85-91.
8. Craddock HL, et al. A study of the proximity of the broadrick ideal occlusal curve to the existing occlusal curve in dentate patients. J Oral Rehab 2005;32:895-900.
9. Spee FG, Biedenbach MA, Hitchcock HP. The gliding path of the mandible along the skull. J Am Dent Assoc 1980;100:670-675.
10. Academy of Prosthodontics. Glossary of prosthodontic terms. J Prosthet Dent 2005;94(1):14.

ABOUT THE AUTHORS

Thota Kiran Kumar

Lecturer, Department of Prosthodontics, Kamineni Institute of Dental Sciences, Nalgonda, Andhra Pradesh, India

Vivek Thomas

Professor and Head, Department of Prosthodontics, Vananchal Dental College, Ranchi, Jharkhand, India

Sanjay Nilawar

Professor, Department of Prosthodontics, Krishnatheja Institute of Dental Sciences, Thirupathi

R Balamurugan

Reader, Department of Oral and Maxillofacial Surgery, Vananchal Dental College and Hospital, Ranchi, Jharkhand, India

Baldeep Singh Marwaha

Senior Lecturer, Department of Orthodontics, Vananchal Dental College, Ranchi, Jharkhand, India

V Vinod

Lecturer, Department of Prosthodontics, The Oxford Dental College and Hospital, Bengaluru, Karnataka, India