



## Impeded Eruption of Mandibular Canine

Gauri S Lele, Darshan Modi

### ABSTRACT

Odontome, tumor of odontogenic origin, is associated with disturbances in the eruption of teeth such as impaction, delayed eruption or retention of permanent teeth. It is seen on radiographic examination as a radiopaque lesion which may be single or multiple. Morphologically, odontomes are of two types—compound or complex and can be found at any age with high prevalence in maxilla than in mandible. In this case report, lack of eruption of permanent mandibular canine owing to presence of associated compound odontome is presented.

**Keywords:** Odontome, Compound odontome, Impacted Mandibular canine, Impeded eruption.

**How to cite this article:** Lele GS, Modi D. Impeded Eruption of mandibular Canine. *J Contemp Dent Pract* 2013;14(5):963-967.

**Source of support:** Nil

**Conflict of interest:** None declared

### INTRODUCTION

‘Odontoma’ by definition refers to any tumor of odontogenic origin. The term odontoma was coined by Broca in 1868.<sup>1</sup> The World Health Organization (WHO) defines odontomas as of two types:<sup>2</sup> Complex Odontomas, in which all dental tissues are present, but arranged in a more or less disorderly pattern; and compound odontomas, in which all of the dental tissues are represented in a pattern that is more orderly than that of the complex type. Thus, in compound odontomes, enamel, dentine, cementum and pulp are arranged as they would be in the normal tooth.<sup>3</sup> Compound odontomes are found more frequently than complex odontome.<sup>4,5</sup>

Though the factors responsible for development or formation of odontomes are unknown, it may be because of local infection or trauma,<sup>6</sup> while genetic component has also been suggested as probable etiology.<sup>7</sup> Compound odontome commonly occurs in the incisor-canine region of the maxilla and complex odontome is frequently located in the premolar and molar region of both jaws.

Most odontomes are asymptomatic; occasionally signs and symptoms relating to their presence do occur. These consist of disturbances in the eruption of teeth, such as impaction, delayed eruption or retention of primary teeth. In the following case report, lack of eruption of permanent mandibular right canine owing to presence of associated compound odontome is presented.

### CASE REPORT

A healthy 14-year-old male patient reported to department of Pedodontics and Preventive Dentistry with a chief complaint of over retained deciduous teeth. His medical history was noncontributory with no history of trauma to the orofacial region. There was no family history of retained primary or unerupted permanent teeth or hypodontia. Intraoral examination revealed presence of following over retained teeth: 55, 54, 53, 63, 64, 65,

85, 84, 83, 73, 74, 75.

A panoramic radiograph was made to assess the presence and status of development of the succedaneous teeth (Fig. 1). It showed presence of unerupted permanent

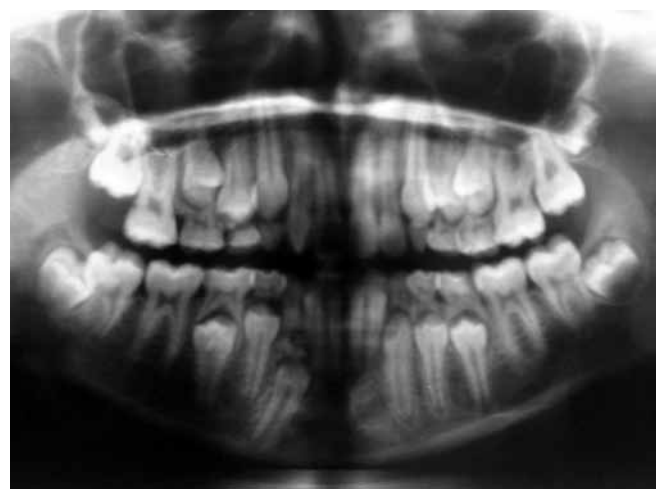
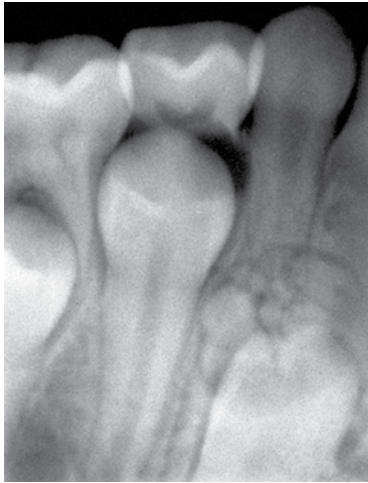
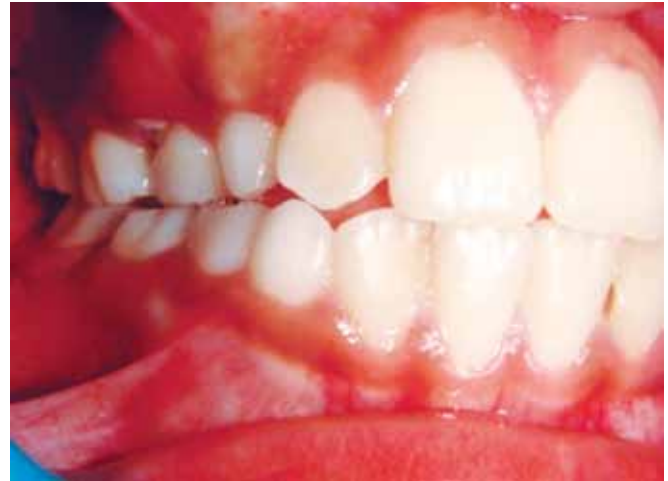
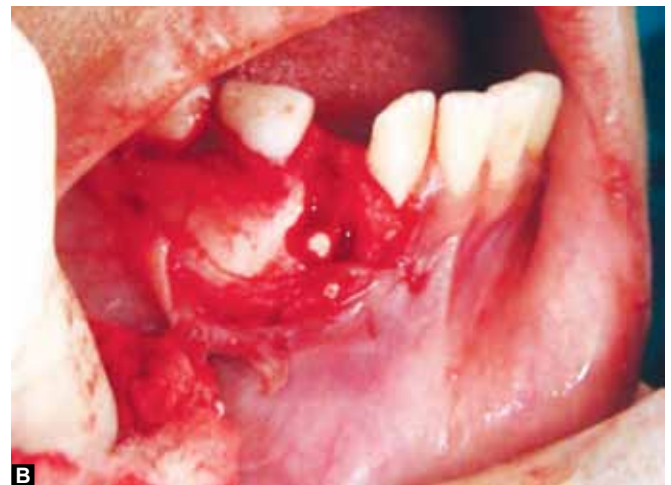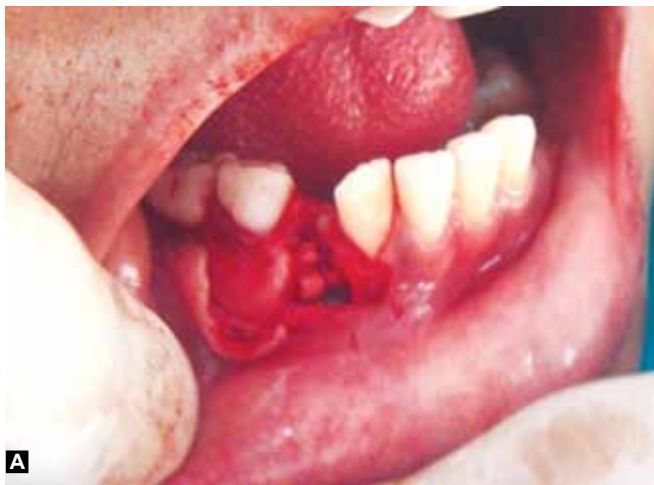Fig. 1: Panoramic radiograph



**Fig. 2:** Intraoral periapical radiograph (preoperative)



**Fig. 3:** Intraoral preoperative image



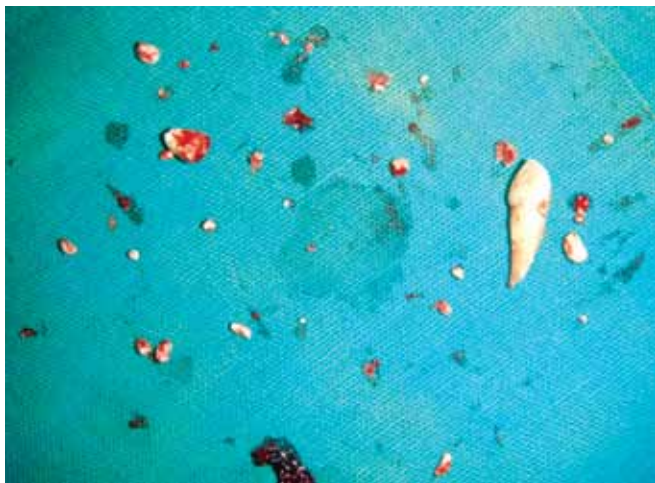**Figs 4A and B:** View of the odontomes after buccal mucoperiosteal flap was raised

canines and premolars with almost two thirds root development. Interestingly, the radiograph also revealed multiple radiopaque masses around the crown of permanent mandibular right canine. Intraoral periapical radiographs for the same region helped in arriving at provisional diagnosis of an odontome (Fig. 2). Clinically, all the retained primary teeth were firm and asymptomatic (Fig. 3). But since there seemed to be lack of eruptive forces of the succedaneous teeth and the resultant inadequate root resorption, extraction of all retained primary teeth was planned. Also, the patient was scheduled for surgical removal of odontome in relation to permanent mandibular right canine. Prior to this, the procedure with possible discomfort and risks was explained to the parent and informed consent was obtained. Routine hematological examination was done. The surgical procedure was carried out under local anesthesia. Primary mandibular right canine was extracted to facilitate access to the lesion. Buccal mucoperiosteal flap was raised in the canine region

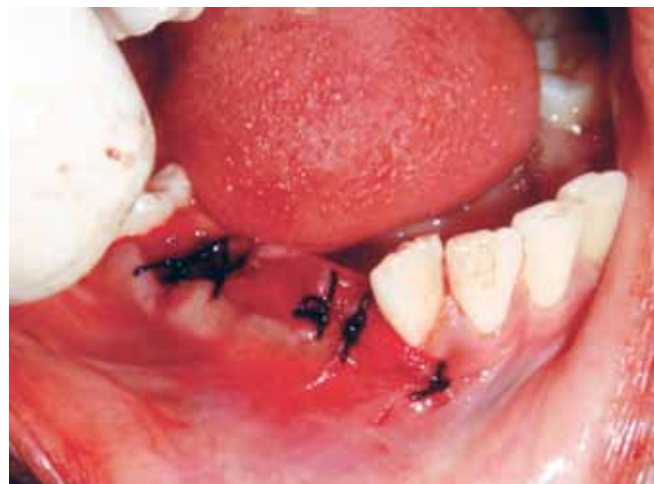(Figs 4A and B). Bone was removed by drilling from the buccal alveolar ridge to remove the scattered hard tissue mass. The multiple hard tissue masses were removed from canine region with the help of curettes, tweezers and forceps (Fig. 5). Subsequently, another radiograph of the same region was made to verify complete removal of all the radiopaque mass (Fig. 6). The surgical area was closed with the help of catgut suture (Fig. 7). The samples obtained were sent for histological evaluation, which then confirmed the diagnosis as compound odontome (Figs 8A and B). The patient has been evaluated regularly to check for the eruption of the permanent teeth.

## DISCUSSION

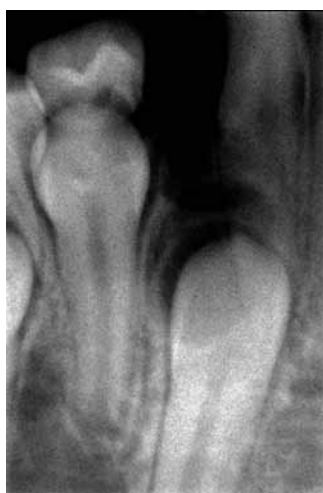Odontomes account for 30 to 40% of all the odontogenic tumors and show similar predilection of occurrence in either maxilla or mandible.<sup>1-6</sup> Trauma, infection and hereditary factors are possible causes of development of these kinds of lesions.



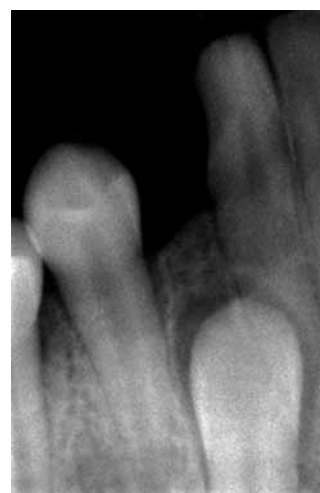**Fig. 5:** Multiple odontomes



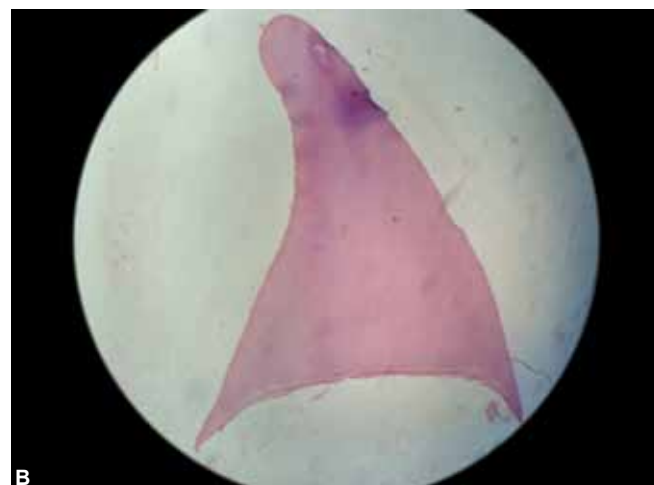
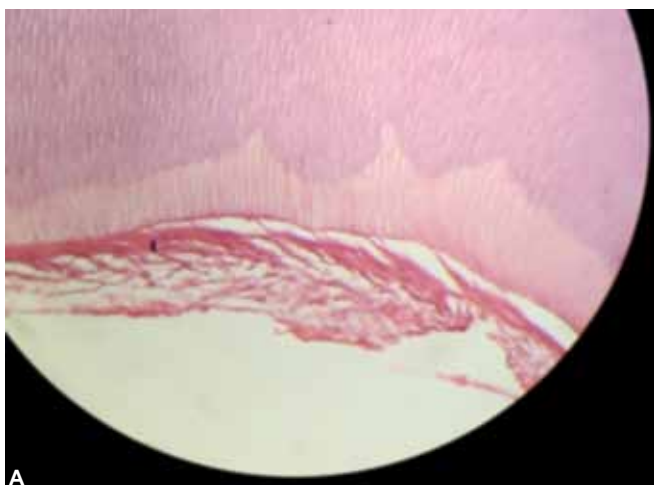
**Fig. 7:** Postoperative image



**Fig. 6:** Postoperative intraoral periapical radiograph



**Fig. 9:** Six months postoperative intraoral periapical radiograph

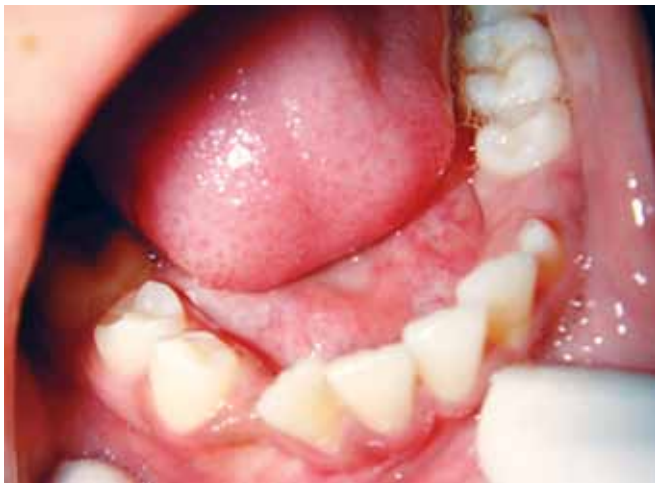

**Figs 8A and B:** Histological appearance of the lesion

According to Budick,<sup>8</sup> odontomes occur at any age and in either arch, i.e. maxillary or mandibular. Compound odontome is observed more in the maxillary anterior region (61%) and is more commonly observed on the right

side of the jaw. But in the present case it was observed in the mandibular arch, was asymptomatic and the lesion was diagnosed on routine radiographic examination. It appeared as irregular mass of calcified material surrounded





**Fig. 10:** Six months postoperative intraoral appearance

by narrow radiolucent bands with smooth outer periphery or as a variable number of tooth like structures with the same peripheral outline.

The differential diagnosis for this could be ameloblastic fibroma, ameloblastic fibro-odontoma and odontoameloblastoma.<sup>5,9,10</sup> Odontomes can also manifest as part of syndromes, such as basal cell nevus syndrome, Gardner syndrome, familial colonic adenomatosis, Tangier disease or Hermann syndrome.<sup>5</sup> Thus, after surgical removal of the lesion, it was evaluated histologically and the diagnosis as that of compound odontome was confirmed.

In the present case, there was delay in exfoliation of the primary teeth and lack of eruption of succedaneous teeth. Many permanent teeth with 2/3 root development were seen as unerupted in the panoramic radiograph, in this patient 14-year-old patient. There could be associated eruptive forces being inherently less in the canine premolar area, with the odontomes causing further delay in the region of 83. Tooth impaction<sup>11</sup> refers to situations where failure to erupt appears to be due to a mechanical blocking and the tooth remains unerupted beyond the normal time of eruption. When there is enough space for impacted permanent teeth to erupt in the dental arch and primary teeth have already exfoliated, surgical exposure with removal of the overlying gingiva or orthodontic traction is the treatment option. When there is insufficient space for the tooth to erupt, it may be necessary to increase the space by uprighting inclined neighboring teeth. In the present case, lack of eruptive forces of the permanent teeth and resultant inadequate root resorption of primary teeth was responsible for the noneruption of permanent teeth. The presence of odontome had further led to impaction of the permanent mandibular canine in this case.

Management of odontomes consists of surgery<sup>4-6,12</sup> with good prognosis and less chances of relapse. It has

been observed that chances of relapse are high if non-calcified tissue lesion is removed.<sup>5,13</sup> Relapse of the lesion has been observed by Tomizawa et al.<sup>10</sup> Thus after surgical management it is necessary to remove the lesion and enveloping soft tissue with curettage. This is to prevent the possibility of cystic degeneration as dentigerous cysts, odontogenic keratocysts and calcifying odontogenic cysts have been associated with odontomes.<sup>3,14</sup> Once odontome is removed surgically along with any lining epithelium, there is usually no recurrence. In this patient's case, even though there was no evidence of cyst formation, the surgical area was thoroughly debrided by curettage and radiographic confirmation was made to ascertain removal of all hard tissue masses.

In the case of this patient, impacted permanent mandibular canine tooth started to erupt spontaneously at 1 month, as seen radiographically. By the end of 6 months, on radiographic observation, slightly delayed eruption of this tooth was observed (Fig. 9). Following extractions of the retained primary teeth, other permanent canines and premolars had already begun to erupt in the oral cavity (Fig. 10). The patient continues to be kept under clinical and radiographic follow-up.

## REFERENCES

1. Marcin B, Tomasz T, Beata D. Compound odontoma: a case report. *Annales Universitatis Mariae Curie-Skłodowska Lubin-Polonia*. 2006;51(2):211.
2. Phillippsen H, Reichardt P, Praetorius F. Mixed odontogenic tumors and odontomas. Considerations on interrelationship. Review of literature and presentation of 134 new cases of odontomas. *Oral Oncol* 1977;33:86-99.
3. Kramer I, Pindborg J. *Histological typing of odontogenic tumors*. New York: Springer-Verlag 1992.
4. Amado Cuesta S, Gargallo Albiol J, Berini Aytés L, Gay Escoda C. Review of 61 cases of odontoma. Presentation of an erupted complex odontoma. *Med Oral* 2003 Nov-Dec;8(5):366-373.
5. Furst I, Pharoah M, Phillips J. Recurrence of an ameloblastic fibro-odontoma in a 9-year-old boy. *J Oral Maxillofac Surg* 1999 May;57(5):620-623.
6. Garcia-Consuegra L, Junquera LM, Albertos JM, Rodriguez O. Odontomas. A clinical-histological and retrospective epidemiological study of 46 cases. *Med Oral* 2000 Nov;5(5):367-372.
7. Hitchin AD. Etiology of the calcified composite odontome. *Br Dent J* 1971;130:475.
8. Budnick SD. Compound and complex odontoma. *Oral Surg* 1976;42:503.
9. Martín-Granizo-López R, López-García-Asenjo J, De-Pedro-Marina M, Domínguez-Cuadrado L. Odontoameloblastoma: a case report and a review of the literature. *Med Oral* 2004 Aug-Oct; 9(4):340-344.
10. Ledesma-Montes C, Perez-Bache A, Garcés-Ortiz M. Gingival compound odontoma. *Int J Oral Maxillofac Surg*. 1996 Aug; 25(4):296-297.

11. Kaugers G, Miller M, Abbey L. Odontomas. *Oral Surg Oral Med Oral Pathol* 1989;67:172-176.
12. Ferrer Ramirez M, Silvestre Donat F, Torres-Gomez FJ, Avella-Vecino F, Salazar-Fernandez C. Recurrent infection of a complex odontoma following eruption in the mouth. *Med Oral* 2001; 6:269-275.
13. Tomizawa M, Otsuka Y, Noda T. Clinical observations of odontomas in Japanese children: 39 cases including one recurrent case. *Int J Paediat Dent* 2005 Jan;15(1):37-43.
14. Yıldırım-Oza G, Tocsins G, Kızıloğlu D, Durmuş E, Senere Y. An unusual association of odontomas with primary teeth. *European Journal of Dentistry* January 2007;45-49.

## ABOUT THE AUTHORS

### Gauri S Lele (Corresponding Author)

Professor, Department of Pedodontics and Preventive Dentistry  
Sinhagad Dental College and Hospital, Pune, Maharashtra, India  
Phone: 9860677782, e-mail: gaurislele@yahoo.co.in

### Darshan Modi

Lecturer, Department of Pedodontics and Preventive Dentistry, Shri  
Guru Gobind Singh Dental College and Research Centre, Burhanpur  
Madhya Pradesh, India