



## C-Arm Fluoroscopy: A Reliable Modality for Retrieval of Foreign Bodies in the Maxillofacial Region

Deepak Pandyan, N Nandakumar, Burhanuddin N Qayyumi, Santosh Kumar

### ABSTRACT

The anatomic complexity of the maxillofacial region makes the retrieval of foreign bodies a daunting task for the maxillofacial Surgeon. Moreover the inability of 2-dimensional imaging to precisely locate foreign bodies makes it challenging. The anatomic proximity of critical structures and esthetic considerations limits the access and thus poses a greater challenge for the surgeon in cases of foreign body retrieval. Hereby we propose a simple technique and a case report to support, the retrieval of small (<5 mm greatest dimension) objects from the maxillofacial region. The present technique uses a 2 dimensional mobile C arm Fluoroscopy and a needle triangulation method to precisely locate a loosened miniplate screw in the mandibular angle region.

**Keywords:** C-Arm, Foreign body, Localization, Retrieval of foreign bodies, Broken instruments, Lost implants, Needle guide.

**How to cite this article:** Pandyan D, Nandakumar N, Qayyumi BN, Kumar S. C-Arm Fluoroscopy: A Reliable Modality for Retrieval of Foreign Bodies in the Maxillofacial Region. *J Contemp Dent Pract* 2013;14(6):1193-1196.

**Source of support:** Nil

**Conflict of interest:** None

### INTRODUCTION

The present day maxillofacial surgery involves intense instrumentation using fine instruments. With the availability of better materials with improved physical properties there is an increased use of finer dental/endodontic/periodontal instruments.<sup>11</sup> The procedures of the maxillofacial region often require placement of delicate implant materials. The usual drawback of such fine instrumentation is the high risk of foreign body entrapment in maxillofacial region.

Foreign materials in the maxillofacial region can be of various origins; broken instrument tips, parts of maxillofacial and dental implants, needles used for local anesthesia, endodontic files and reamers and loosened or failed implant materials.<sup>8,10</sup>

Many of the procedures are office based with a conscious patients, thus an inadvertent patient movement or the very technique sensitive nature of the operative procedure can pose an increased iatrogenic risk of foreign body entrapment in the maxillofacial region. In most of the cases the retrieval is immediate without complications and does not require specialist complex maneuvering.<sup>1</sup> This retrieval is usually augmented with the use of routine imaging modalities available like the OPG, dental digital X-rays and CT (conventional or Cone Beam) images whichever deemed necessary for the accurate localization.<sup>1,8,13</sup>

Intraoperatively the complex three dimensional maxillofacial anatomy, proximity to critical structures, risk of injury to the facial nerve branches, limitation of intraoral access and the esthetic considerations of an extraoral access sometimes makes this retrieval a blind task. In addition to the above mentioned constrains the local inflammation, cellulitis or abscess can make the foreign body retrieval a painstakingly long procedure.<sup>13</sup>

These reasons have made clinicians use various real time imaging methods for detection of foreign body entrapments in the maxillofacial region. In this regard the use of mobile digital dental X-rays, C-arm fluoroscopy, intraoperative CT imaging and navigation show promise.<sup>7</sup>

Intraoperative CT is by far one of the gold standards but is still not clinically very accessible and has limitation of high costs and increased risk of radiation exposure.<sup>10,14</sup> Digital dental X-rays though very accessible are good for intraoral placement and have a limited application for the complete maxillofacial region.<sup>7</sup> Intraoperative ultrasonography is not of much benefit as the foreign bodies are very fine at times and difficult to generate accurate images to help retrieve them.<sup>7</sup> Intraoperative navigation systems of the present day are the most promising aid for the surgeon and the probable 'Pole star' for the surgeons in the future, but the technical

complexities, increased costs and the still experimental nature of its use defer it from being the preferred choice.<sup>3</sup>

Mobile C-arm fluoroscopy (Image intensifier with X-ray tube) has long been used in Cardiology, Urology and Orthopedics. In orthopedic surgeries it has been used to visualize the adequacy of fracture reduction/fixation of long bones.<sup>5</sup> This avoids the use of postoperative CT or X-rays and thus reduces the total ionizing radiation exposure. The simplicity of its use, the wide range of movements, the low dose radiation and the easy accessibility in a trauma setting has made it a time tested modality for intraoperative imaging.

C-Arm fluoroscopy has been used in the maxillofacial surgery for intraoperative evaluation of the adequate reduction in treatment of zygomatic complex fractures and have been effective.<sup>5</sup> Few reports of the use of C-arm fluoroscopy in the foreign body retrieval from the maxillofacial region exits in English language literature.<sup>6,11,14</sup> The present technique is a simple method to gain 3 dimensional localization while using the C arm intraoperative.

### TECHNIQUE

The technique involves use of a mobile C-Arm with a screen and two 18 gauge straight needles. The present technique is a simplified modification of the stereotactic technique originally published by Ariyan S 1977.<sup>2</sup> The C Arm provides a real time image and a freeze image which helps in localization of the foreign body. The idea of using two needles is to localize the plane of dissection in order to retrieve the said foreign body.<sup>6</sup> The C Arm provides a 2 dimensional image of the 3 dimensional structures and thus achieving the correct plane to dissect is still arbitrary. We propose this simple technique of sequential insertion of two needles and followed by changing angulation of the C arm as a method to localize the plane of dissection. The brief steps involved are:

1. A base line image is generated to know the relation of the foreign body (Point-A Red color) to the adjacent bony landmarks (e.g. gonial angle, tooth, etc.)
2. The first 18 gauge needle (black color) with a safety hub is gradually inserted till the needle tip (Point-P) lies very close/adjacent/superimposed over Point-A (Fig. 1).
3. The C Arm angulation is changed 15° and image is generated to know the superior/inferior relation between point A and Point P by applying the tube shift technique. The subsequent image is frizzed (Fig. 1).
4. Re position the C Arm and insert the second needle (Olive color) till its tip (Point—Q) lies close to the said Point A (Fig. 2).
5. The C Arm angulation is again changed and the spatial relation of Point Q and Point A is accessed.
6. The Points A, P and Q form a triangular plane (see Fig. 2).

7. The extraoral puncture points form a reference for the surgeon to access this plane.

The surrounding tissues may have severe inflammation, cellulitis or an abscess and thus an inadvertent hunt for the foreign body might dislodge it deeper into inaccessible areas. The above mentioned steps accurately help in guiding the plane of dissection and thus aid in easy retrieval of small foreign objects with <5 mm greater dimension.

### CASE REPORT

A 28 years old male reported to our department with the chief complaint of pain and swelling over the right side of his lower jaw since past 1 week. He also complained of inability to clench his teeth correctly. On further questioning it was revealed that patient had a history of a road traffic accident 1 month back and had sustained injury to his face. He was subsequently treated at a different hospital and was referred to our department for further management.

His past medical history revealed no known comorbid conditions. On general examination his vitals, and systemic examination revealed no abnormalities. Routine investigations revealed no abnormal values. Local examination revealed facial asymmetry with a diffuse extraoral swelling over the right mandibular angle and submandibular region. The swelling was tender on palpation and brawny (Fig. 3). There was paresthesia of the bilateral lower lip region. Mouth opening was satisfactory with a right anterior and posterior open bite (Fig. 4). An X-ray

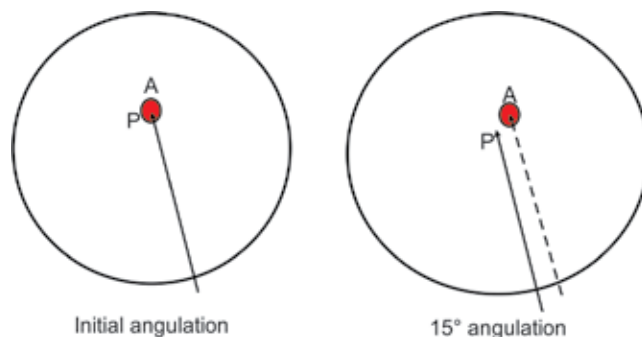


Fig. 1: 1st needle (black) and the change in the needle position (dashed line original position) in relation to the foreign body (red)

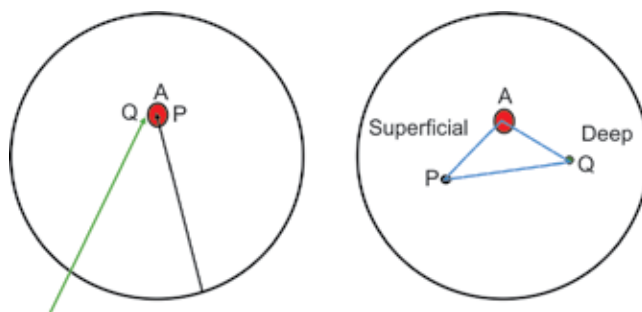


Fig. 2: Spatial localization of the 3 points which appear to overlap on a 2 dimensional image, but form a triangle instead. Note olive needle is the 2nd needle

OPG was advised and revealed fixation with a 3D miniplate and two miniplates at the fractured right angle and left parasymphysis of mandible respectively (Fig. 5). There was a loosened screw from the right mandibular angle region lying below the lower border of mandible. The diagnosis of infected and loosened implants was made and patient was planned for implant removal and re ORIF under general anesthesia.

The planned procedure involved an intraoral vestibular incision for removal of the miniplates at the left parasymphysis and an extraoral incision for the removal of the infected plate at the right angle region. The right side plate was removed but the loosened screw lying in the submandibular region was not retrieved with usual dissection due to the cellulitis. The above-mentioned technique was used (Figs 6 and 7) to accurately locate the screw and as mentioned a plane of dissection was achieved.

## DISCUSSION

The present method of localization using needle as a guide and has been published previously.<sup>2,6,9</sup> Nevertheless the purpose of this article was to simplify the use of needles as guides and help in establishing the surgical plane for dissection with the use of C Arm fluoroscopy. The simple diagrams represent this and provides steps for the amateur surgeons. This method as we propose can be more worthwhile in cases when there is severe inflammation or cellulitis and the altered normal anatomy which makes the retrieval by blind methods difficult. Few authors have suggested the possible risk of needles injuring the lingual nerve or vessels but no reported cases of such injury while retrieval have been published till date.<sup>11</sup> However we suggest that the needle insertion should be extremely slow and all precautions to prevent the injury to critical structures should be taken. One report suggested the use of periosteal elevators to prevent such injuries but due to their heavy nature it might not be possible to use in all areas of the maxillofacial region.<sup>11</sup>

This method of 3 dimensional localization is not the only method for retrieval but a more reliable and efficient technique.<sup>9</sup> The current case is testimonial in this regard. The use of newer methods like Dental C-Arm has been tried for retrieval of broken tips of instruments and has shown promise.<sup>11</sup> Intraoperative CT has the advantage of 3 Dimensional view of the foreign bodies but the images are historic and the very manipulation or retraction at surgical site can cause changes in its location.<sup>10,11</sup> Recently, C Arm CBCT has been used for intraoperative evaluation of reduction and fixation of maxillofacial fractures and thus could be used effectively for foreign body retrieval.<sup>4</sup> O-Arm (Medtronic) has both 2D and 3D fluoroscopy modes and thus could be a better imaging modality for such purposes.

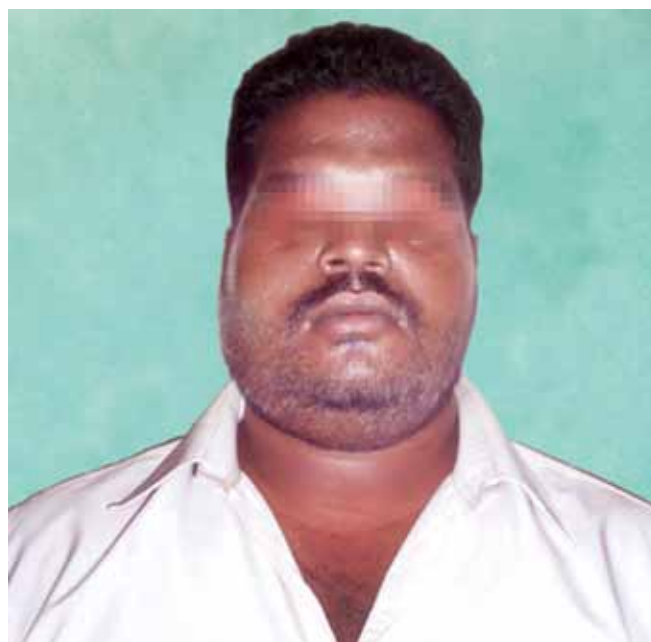

Fig. 3: Cellulitis of the right submandibular region

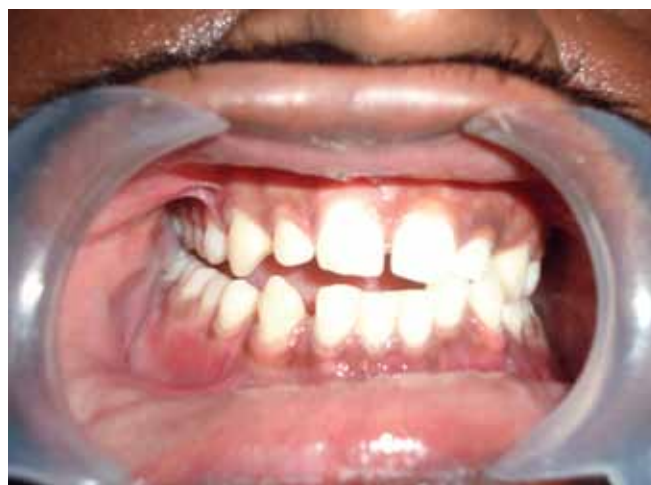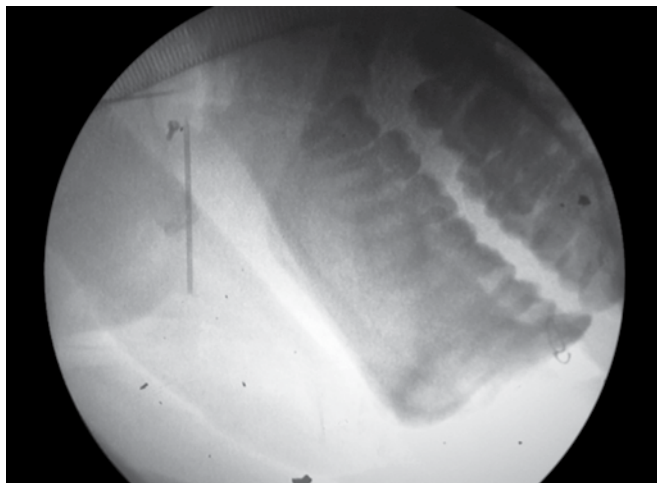


Fig. 4: Malocclusion due to inadequate reduction of fractures

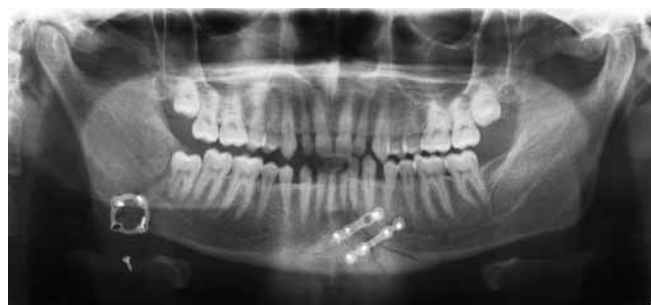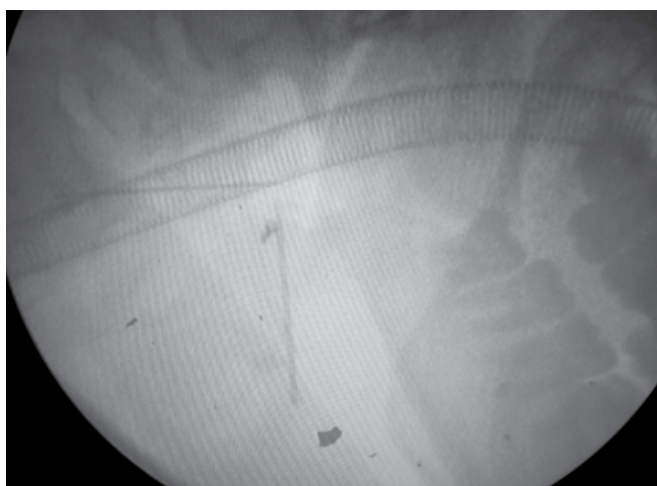


Fig. 5: OPT showing the dislodged screw from the fixation site at the right angle

Computer assisted surgery (CAS) using navigation has been used for removal of foreign bodies and provides assistance in difficult retrievals.<sup>9,12</sup> The use of metal detectors has been long reported, it can be used along with 3D navigation systems of the current day and make foreign body retrieval state of art.<sup>3,12</sup> Though the amount of radiation in all of



**Fig. 6:** C-arm image of the relation of the foreign body to the 1st needle



**Fig. 7:** C-Arm image after insertion of the 2nd needle, thus establishing a plane to explore the foreign body

the newer intra-operative imaging modalities is far less than conventional spiral CT, proper patient and personnel protection with Lead Aprons is imperative.<sup>5,15</sup>

To conclude a systematic approach of 3D localization using needles improves the efficiency and precision of retrieval using the conventional C Arm fluoroscopy and the knowledge of this technique can lead us till we completely enter into the era of 3D navigation guided systems.<sup>9</sup>

## REFERENCES

1. Ho KH. A simple technique for localizing a broken dental needle in the pterygomandibular region. *Aust Dent J* 1988;33:308-309.
2. Ariyan S. A simple stereotactic method to isolate and remove foreign bodies. *Arch Surg* 1977;112:857e859.
3. Zwingmann J, Konrad G, Kotter E, et al. Computer-navigated iliosacral screw insertion reduces malposition rate and radiation exposure. *Clin Orthop Relat Res* 2009;467:1833-1838.

4. Pohlenz, et al. CBCT of zygomaticomaxillary complex fractures. *J Oral Maxillofac Surg* 2009.
5. Badjate SJ, Cariappa KM. C-Arm for accurate reduction of zygomatic arch fracture—a case report. *Br Dent J* 2005;199:275-277.
6. Nezafati S, Shahi S. Removal of broken dental needle using mobile digital C-arm. *J Oral Sci* 2008;50:351-353.
7. Imai, et al. Closed reduction of mandibular condyle fractures using C-arm fluoroscopy: a technical note. *Oral Surg Oral Med Oral Pathol Oral Radiol* 2013;115:e4-e9.
8. Holmes PJ, Miller JR, Gutta R, Louis PJ. Intraoperative imaging techniques: a guide to retrieval of foreign bodies. *Oral Surg Oral Med Oral Pathol Oral Radiol Endod* 2005;100:614-618.
9. Siessegger M, Mischkowski RA, Schneider BT, Krug B, Klesper B, Zöllner JE. Image guided surgical navigation for removal of foreign bodies in the head and neck. *J Craniomaxillofacial Surg* 2001;29:321-325.
10. Ethunandan M, Tran AL, Anand R, Bowden J, Seal MT, Brennan PA. Needle breakage following inferior alveolar nerve block: implications and management. *Br Dent J* 2007;202:395e397.
11. Park SS, et al. *Journal of Craniomaxillofacial Surgery* 2012;40:572e578.
12. Wei R, Xiang-Zhen L, Bing G, Da-Long S, Ze-Ming T. Removal of a foreign body from the skull base using a customized computer-designed guide bar. *J Craniomaxillofacial Surg* 2010;38:279e283.
13. Malamed. *Handbook of Local Anesthesia*. 6th ed.
14. Sencimen, et al. Removal of the retained suture needle under C-arm fluoroscopy: a technical note. *Dental Traumatology* 2010;26:527-529.
15. Lee, et al. Measurements of surgeons exposure to ionizing radiation dose during intraoperative use of C-Arm fluoroscopy. *Spine* 37(14):1240-1244.

## ABOUT THE AUTHORS

### Deepak Pandyan (Corresponding Author)

Senior Lecturer, Department of Oral and Maxillofacial Surgery, Faculty of Dental Sciences, Sri Ramachandra University, Chennai, Tamil Nadu India, Phone: +91 9884314123, e-mail: dr.deepakpandyan@gmail.com

### N Nandakumar

Professor, Department of Oral and Maxillofacial Surgery, Faculty of Dental Sciences, Sri Ramachandra University, Chennai, Tamil Nadu India

### Burhanuddin N Qayyumi

Postgraduate Trainee, Department of Oral and Maxillofacial Surgery Faculty of Dental Sciences, Sri Ramachandra University, Chennai Tamil Nadu, India

### Santosh Kumar

Senior Lecturer, Department of Oral and Maxillofacial Surgery Faculty of Dental Sciences, Sri Ramachandra University, Chennai Tamil Nadu, India