

CASE REPORT



Mandibular First Premolars with One Root and Three Canals: A Case Series

¹Farzaneh Daneshvar, ²Hani Baziar, ³Hamed Karkehabadi, ⁴Hamid Jafarzadeh, ⁵Shilpa Bhandi, ⁶Shankargouda Patil

ABSTRACT

The possibility of extra canals in mandibular premolars is quite low; however, it must be taken into account in clinical and radiographic evaluations during root canal treatment. This case series describes the presence of one root and three canals in mandibular premolars in three patients. The case series underlines the importance of complete knowledge about root canal morphology and possible variations to increase the ability of clinicians to treat difficult cases.

Keywords: Mandibular premolar, Anatomical variation, Endodontic treatment.

How to cite this article: Daneshvar F, Baziar H, Karkehabadi H, Jafarzadeh H, Bhandi S, Patil S. Mandibular First Premolars with One Root and Three Canals: A Case Series. J Contemp Dent Pract 2015;16(6):519-522.

Source of support: Nil

Conflict of interest: None

INTRODUCTION

For a successful treatment, a true diagnosis followed by an appropriate treatment by complete cleaning and shaping is necessary. It has been demonstrated for a long

time that a root with a tapered canal and a single apical foramen is an exception, but not a rule, because the pulp canal system is complex and unpredictable. The canals may diverge into branches and recombine together.¹ The most important point is that an untreated canal/root may be a cause of treatment failure.²

Mandibular premolar teeth represent high levels of diversity and complexity of the root canal system.^{3,4} Slowey stated that these teeth are the hardest ones in endodontic treatment.⁵ Enormous diversity of canal morphology and abnormal anatomy as well as limited access to the second canal are all among possible causes for big failure in endodontic treatment of these kinds of teeth.¹ In different studies, the prevalence rates of three-canal mandibular first premolars have been reported as 0.5 to 5.7.⁶⁻⁹ The presence of three canals with three separate apical foramens is very rare and Vertucci estimated its prevalence rate as 0.5% in the first premolars and zero in the second premolars.⁷

This case series represents three cases of successful non-surgical treatment of mandibular first premolars with three separate canals.

CASE REPORTS

Case 1

A 16-year-old male patient complaining of pain in the lower left first premolar area was referred to our dental clinic; his medical history was non-contributory. On the clinical examination, deep caries in the distal of tooth 21 was observed. Tooth reaction to vitality tests (cold, heat and electric tests) was negative; however, sensitivity to percussion was observed. The tooth in question had no mobility and no periodontal pocket in probing. In preoperative diagnostic radiograph, periodontal ligament-widening and a complex structure of the root were observed (Fig. 1). The clinical diagnosis of necrotic pulp with acute apical periodontitis was made and non-surgical endodontic treatment was scheduled.

¹⁻³Department of Endodontics, Faculty of Dentistry, Zahedan University of Medical Sciences, Zahedan, Iran

⁴Department of Endodontics, Dental Research Center Faculty of Dentistry, Mashhad University of Medical Sciences Mashhad, Iran

⁵Department of Conservative Dentistry and Endodontics Faculty of Dental Sciences, MS Ramaiah University of Applied Sciences, Bengaluru, Karnataka, India

⁶Department of Oral and Maxillofacial Pathology, Faculty of Dental Sciences, MS Ramaiah University of Applied Sciences Bengaluru, Karnataka, India

Corresponding Author: Hamid Jafarzadeh, Associate Professor, Department of Endodontics, Dental Research Center, Faculty of Dentistry, Mashhad University of Medical Sciences, Vakilabad Blvd Mashhad, Po Box: 91735-984, Iran Phone: +98-511-8829501, e-mail: hamid_j365@yahoo.com JafarzadehBH@mums.ac.ir

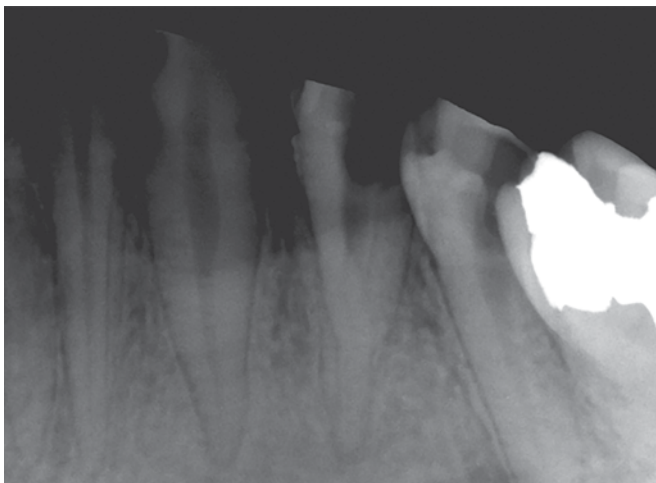


Fig. 1: Initial radiograph, showing the possible existence of three canals in one root

After local anesthesia with 1.8 ml lidocaine containing 1:80,000 epinephrine, the tooth was isolated by rubber dam and access cavity was prepared. Initial investigation was conducted by a #10 K-File (Dentsply Maillefer, Baillaigues, Switzerland). Two files were initially placed in the canals and we suspected a third canal while placing the second file in the apical third of the root. After the expansion of the access cavity and coronal flaring by #2 and #3 gates—glidden drills, a better apical access was provided. Making a severe pre-curve at the end of a #15 K-file, we conducted a search for the third canal and found it. Then, radiograph was made for working length determination (Fig. 2).

Three canals clearly existed. All three canals were prepared up to #30, whereas rotary ProTaper system (Dentsply, Maillefer, Baillaigues, Switzerland) was used for more flaring. Calcium hydroxide dressing was applied in the canal and the access cavity was sealed by Zonalin. Recalling the patient after 1 week, calcium hydroxide was removed with ultrasonic activation (NSK, Japan) of 2.5% sodium hypochlorite and 17% ethylenediaminetetraacetic

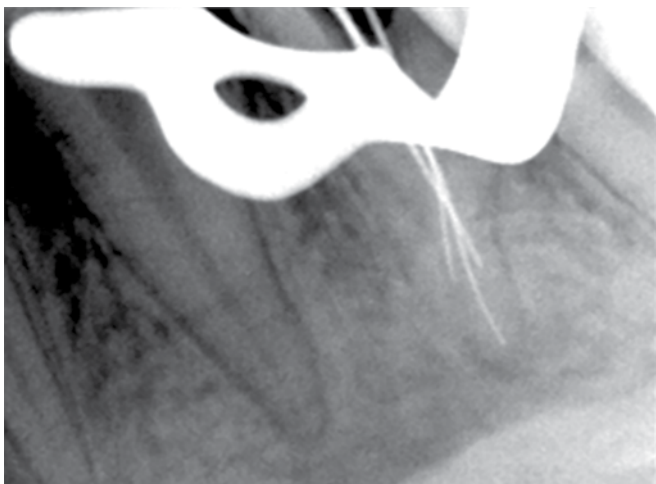


Fig. 2: Working length determination, confirms the independent trajectory of the three canals

acid (EDTA). Finally, the canals were washed by sterile normal saline, dried by sterile paper point. Canals were obturated by lateral condensation technique using gutta-percha and AH-Plus sealer. Access cavity was sealed by Zonalin paste and the patient was referred for crown restoration (Fig. 3).

Case 2

A 32-year-old female patient with irrelevant medical history was referred to our dental office. The chief complaint of the patient was severe pain in the left first premolar. Intraoral examination revealed deep caries in tooth 21. Radiographic examination showed aberrant anatomy in the apical region of root and periodontal ligament-widening (Fig. 4). The tooth was not tender on percussion. Abnormal responses to vitality tests (cold, heat, and electric tests) indicated that irreversible pulpitis had occurred, thus non-surgical endodontic treatment was selected.

The patient was anesthetized with 2% lidocaine accompanied by 1:80,000 epinephrine. After isolation

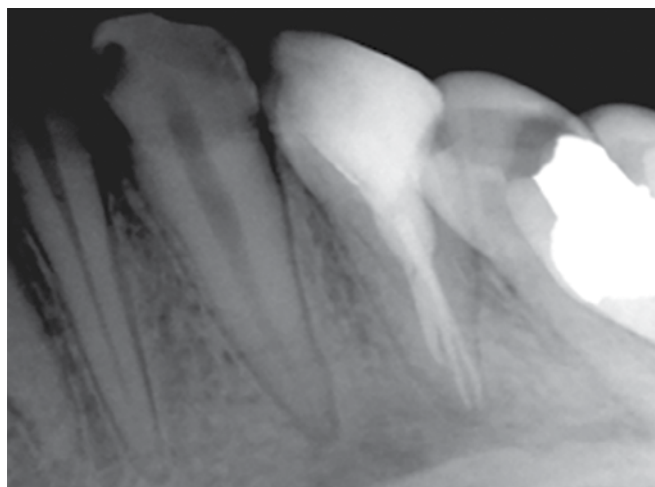


Fig. 3: Final radiograph, showing the obturation of three root canals

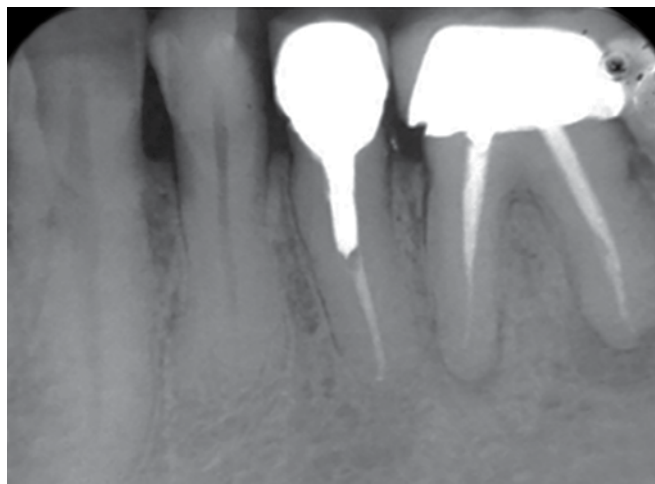


Fig. 4: Initial radiograph, showing the possible existence of three canals in one root

with rubber dam, endodontic access cavity was made with more extension. Primary inspection of the root canal system was performed with a #10 K-file (Dentsply, Maillefer, Baillaigues, Switzerland). Pulp chamber was repeatedly flushed with 2.5% sodium hypochlorite for better visualization. Rotary Sx ProTaper instrument was used for more coronal flaring. Three canals were detected in the apical one third by making a severe pre-curve at the end of #15 K-file (Fig. 5). Radiographic image was taken to estimate working length. All three canals were instrumented with a crown-down technique using ProTaper system and 2.5% sodium hypochlorite. Debridement of the apical parts of the canals was performed by severe pre-curved hand instruments up to #30. Smear layer was removed by 17% EDTA. At the end, the canals were flushed by sterile normal saline, dried by paper point and filled by lateral condensation technique with gutta-percha and AH-Plus sealer. Then, access cavity was sealed and the patient was referred for definite restoration (Fig. 6).

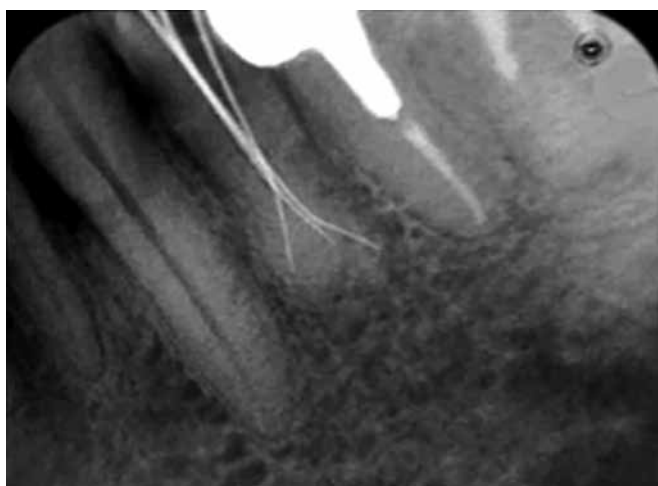

Fig. 5: Working length determination, confirms the independent trajectory of the three canals

Case 3

A 37-year-old male patient with non-contributory medical history was referred to our dental clinic. The patient complained of severe pain in the mandibular left first premolar. Clinical examinations revealed extensive caries in the mesial margin of the tooth #21. Vitality tests (cold, heat, and electric tests) showed no response, whereas percussion test was positive. Preoperative radiograph demonstrated periodontal ligament-widening and one canal that split into two canals in the mid-root area (Fig. 7). Diagnosis of pulp necrosis and acute apical periodontitis was made and two-visit non-surgical endodontic treatment was scheduled with calcium hydroxide as intracanal medicament. After pulp extirpating and applying calcium hydroxide, the access cavity was sealed with cavite.

At the next appointment, the patient's pain was ceased. Calcium hydroxide was removed and access cavity was modified. Careful inspection of the pulpal walls with a pre-curved #8 K-file revealed three canals which were located at the apical region. Working lengths were confirmed by radiography (Fig. 8). Sodium

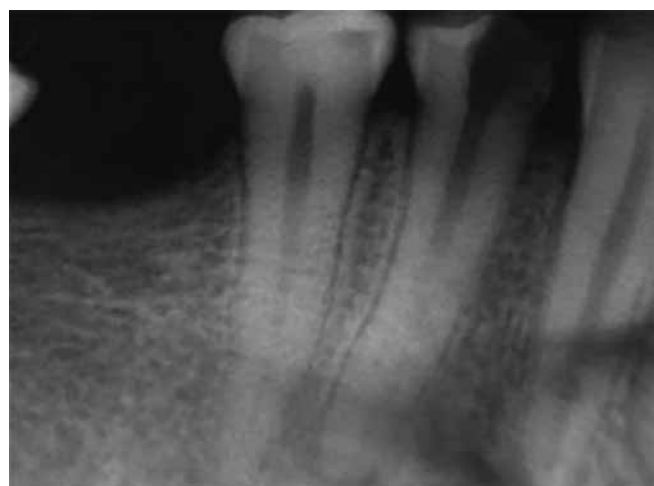

Fig. 7: Initial radiograph, showing the possible existence of three canals in one root

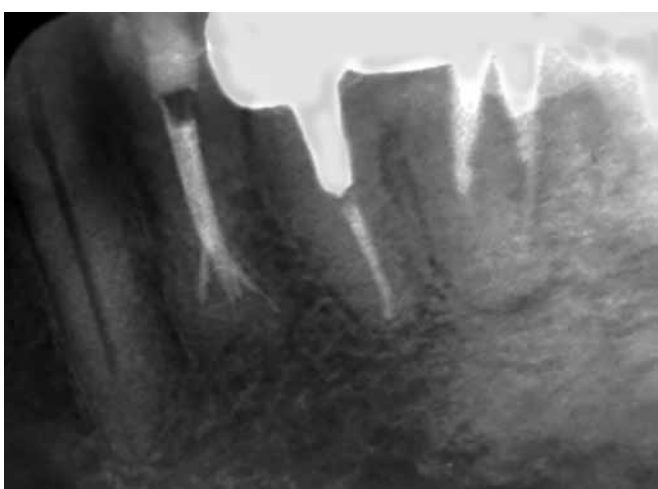

Fig. 6: Final radiograph, showing the obturation of three root canals

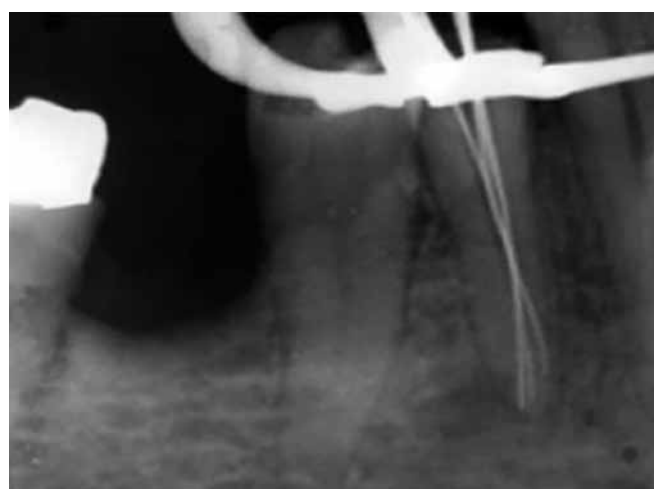

Fig. 8: Working length determination, confirms the independent trajectory of the three canals

hypochlorite was used during instrumentation by ProTaper system. After drying canals by sterile paper points, the canals were obturated with gutta-percha and AH-Plus sealer using the lateral condensation technique. Then, access cavity was sealed the patient was referred for crown restoration (Fig. 9).

DISCUSSION

The lower premolars are the hardest teeth in endodontic treatment.¹⁰ There are several reports indicating the existence of three, four, and five canals in these teeth.¹¹ While providing access cavities, morphological changes in pulp chamber may be diagnosed using binocular microscope and cone beam computer tomography.¹² Furthermore, the rules developed by Kranser and Rankow may help to find location of orifices where there is an additional canal in pulp chamber area.¹³

Intraoral radiographies with X-ray angle change of 20 and 40° in the mandibular first premolar is more accurate than direct radiography in diagnosing the real number of canals.¹² In addition to radiography, which may be a key to initial diagnosis for extra canals, the microscope and optical loupes and clinician's sense of touch during the initial placement of a file are also very helpful in finding additional canals. The consistency of periodontal ligament space in radiograph may also work as a supplement in finding extra-canals. A canal suddenly narrowed in radiographic cliché could represent an extra-canal or extra-root.⁷ Initial file suddenly getting stuck either somewhere except the main canal or in the main canal

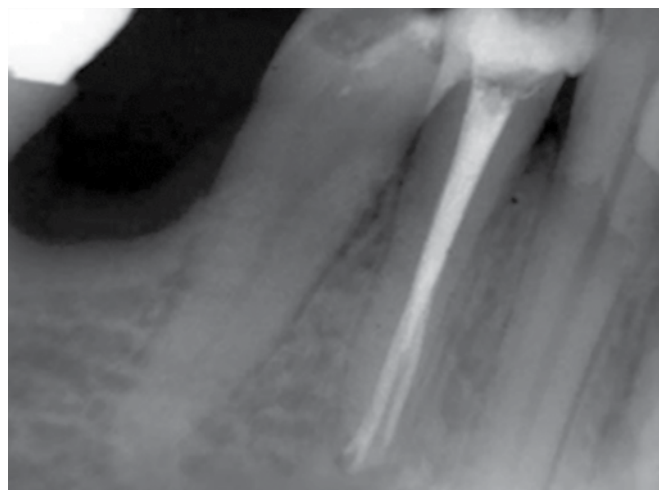


Fig. 9: Final radiograph showing the obturation of three root canals

but shorter than a working length will make a skillful clinician doubt the existence of an additional canal.

It is very important where canals are isolated from the main canal because the more apical is the location of canals' isolation, the more difficult will be cleaning and obturation. Modern dental tools including loupe and microscope used currently in endodontic treatment help to locate canals in pulp chamber and coronal areas. The cases reported in this study involved successful non-surgical treatment of three cases of premolar teeth with three separate canals isolated in the apical half of the root trunk. In such cases, the clinician's sense of touch and radiographic images during the treatment will take on further importance.

REFERENCES

- Hargreaves KM, Cohen S. Cohen's pathways of the pulp. Missouri: Mosby; 2011.
- Hoehn MM, Pink FE. Contemporary endodontic retreatments: an analysis based on clinical treatment findings. *J Endod* 2002;28(12):834-836.
- Nallapati S. Three canal mandibular first and second premolars: a treatment approach. *J Endod* 2005;31(6):474-476.
- Poorni S, Karumaran CS, Indira R. Mandibular first premolar with two roots and three canals. *Aust Endod J* 2010;36(1):32-34.
- Slowey RR. Root canal anatomy. Road map to successful endodontics. *Dent Clin North Am* 1979;23(4):555-573.
- Calışkan MK, Pehlivan Y, Sepetçioğlu F, Türkün M, Tuncer SS. Root canal morphology of human permanent teeth in a Turkish population. *J Endod* 1995;21(4):200-204.
- Vertucci FJ. Root canal anatomy of the human permanent teeth. *Oral Surg Oral Med Oral Pathol* 1984;58(5):589-599.
- Pineda F, Kuttler Y. Mesiodistal and buccolingual roentgenographic investigation of 7,275 root canals. *Oral Surg Oral Med Oral Pathol* 1972;33(1):101-110.
- Yoshioka T, Villegas JC, Kobayashi C, Suda H. Radiographic evaluation of root canal multiplicity in mandibular first premolars. *J Endod* 2004;30(2):73-74.
- Cleghorn BM, Christie WH, Dong CC. Anomalous mandibular premolars: a mandibular first premolar with three roots and a mandibular second premolar with a C-shaped canal system. *Int Endod J* 2008;41(11):1005-1014.
- De Moor RJ, Calberson FL. Root canal treatment in a mandibular second premolar with three root canals. *J Endod* 2005;31(4):310-313.
- Martínez-Lozano MA, Forner-Navarro L, Sánchez-Cortés JL. Analysis of radiologic factors in determining premolar root canal systems. *Oral Surg Oral Med Oral Pathol Oral Radiol Endod* 1999;88(6):719-722.
- Krasner P, Rankow HJ. Anatomy of the pulp-chamber floor. *J Endod* 2004;30(1):5-16.