

REVIEW ARTICLE



Extraction Planning in Orthodontics

¹Mustafa Harith Al-Ani, ²Adil Osman Mageet

ABSTRACT

Introduction: Planning extraction of teeth for orthodontic treatment is one of the challenging factors for successful functional and esthetic orthodontic results and for the long-term stability.

Aim: The aim of this study is to document possible extraction guidelines for planning of orthodontic treatment for space deficiency cases related to excess tooth material.

Results: The guidelines are written as patterns to facilitate the decision of extraction of teeth for class I, class II division 1, class II division 2, and class III malocclusions, for crowding, overjet reduction, or correcting the buccal segment relationship. The decision for extraction of teeth for orthodontic treatment is enforced by the oral hygiene, carious teeth, periodontal involvement, impacted teeth, supernumeraries, hypodontia, or for orthognathic purposes. Also, planning the decision for accurate extraction pattern is the main factor in the success of the orthodontic treatment and for the long-term stability of the results.

Conclusion: Orthodontic tooth extraction should always be planned with consideration of the width and length of the face, the oral hygiene, carious activity, periodontal involvement, malformed crowns, length and health of the root of the teeth, prognosis of impacted teeth, supernumeraries, and hypodontia.

Clinical significance: Accurate diagnosis and treatment planning following orthodontic extraction guidelines lead to a long-term stability of the corrected results.

Keywords: Crowding, Extraction of teeth, Hypodontia, Long-term stability, Supernumerary.

How to cite this article: Al-Ani MH, Mageet AO. Extraction Planning in Orthodontics. *J Contemp Dent Pract* 2018;19(5):619-623.

Source of support: Nil

Conflict of interest: None

INTRODUCTION

The main goal of orthodontic treatment is to obtain a normal relationship of the teeth with facial structures. Angle¹ emphasized that the preservation of all dental units was necessary to achieve facial balance.² However, there are soft tissue constraints that limit the amount of alteration that can be performed orthodontically, which necessitates the need for extraction.³

The controversies regarding whether to extract or not that has been occurring for many years were often linked to personal preferences rather than scientific criteria.⁴

Extractions in orthodontics were reintroduced scientifically in 1930s and with the advent of Begg's technique reached its peak in 1960s. Different extraction protocols have been followed for successful orthodontic treatment⁵ and accordingly in this study the need for extraction has been elaborated.

Extraction of specific teeth is required in different types of malocclusions, and the decision to extract depends on the patient's medical history, the attitude to treatment, oral hygiene, caries rate, and the quality of teeth.⁶

The aim of this study is to provide guidelines or protocols of when to extract and what to extract in cases of class I, class II/1, class II/2, and class III malocclusion.

There are many factors that enforce extraction of teeth for orthodontic treatment: Increased tooth size in relation to the arch size (crowding), supernumeraries, hypodontia (if decided to close the space, may need extraction), carious teeth, increased overjet, open bite cases, impacted teeth, camouflage orthodontic treatment, correction of the

¹Department of Orthodontics, Mageet Orthodontic Training Centre, Khartoum, Sudan

²Department of Orthodontics, Mohammed Bin Rashid University of Medicine and Health Sciences, Hamdan Bin Mohammed College of Dental Medicine, Dubai, United Arab Emirates
Department of Orthodontics, Mageet Orthodontic Training Centre, Khartoum, Sudan; Department of Orthodontics, Faculty of Dentistry, University of Gezira, Wad Madani, Sudan

Corresponding Author: Adil Osman Mageet, Department of Orthodontics, Mohammed Bin Rashid University of Medicine and Health Sciences, Hamdan Bin Mohammed College of Dental Medicine, Dubai, United Arab Emirates; Department of Orthodontics, Mageet Orthodontic Training Centre, Khartoum Sudan, Department of Orthodontics, Faculty of Dentistry, University of Gezira, Wad Madani, Sudan, Phone: +971553378730, e-mail: adil.mageet@MBRU.ac.ae

buccal segment, malformed teeth, periodontally involved teeth, orthognathic surgery, cleft lip, and palate.

Guidelines for Extraction in Class I Malocclusion

Class I malocclusion is defined by the British Standard institute in year 1983 by its incisor relationship, which is the lower incisal edge that lies on or below the cingulum plateau of the palatal surface of the upper incisors. Its incidence among the Caucasian population was found to be the highest among other types of malocclusion with 60% according to Todd and Dodd, whereas in the Sudanese population it was found to be 49%,⁷ which is still highest among the other malocclusions but less compared with Caucasians.

Treatment of class I with crowding has several different modalities: interproximal reduction (stripping), expansion, derotation, uprighting, distalization, and extraction.

Table 1 simplifies and briefs the options of extraction for general dentist, orthodontic residents, and specialists.

Extraction of all first premolars is usually indicated in moderate to severe crowding in the labial segment to create space for relieving of crowding. It is the commonest pattern of extraction done by the orthodontist, as it is cantered between the anterior and posterior region of the jaw, and it provides good anchorage in the posterior region to retract the six anterior teeth.⁸ In case one of the second premolars is carious, consider leaving the neighboring first premolar with anchorage enforcement (Table 1, pattern 1).

Extraction of all second premolars is usually indicated in grossly carious, largely filled, or periodontally compromised second premolars and first premolars in good condition; moderate crowding in the labial segment and a degree of crowding in the posterior region; anterior open bite, as extraction of second premolar helps in deepening the bite and for centerline correction.

It is preferred over first premolar extraction if the facial profile is wanted to remain unchanged.⁹ In case one of the first premolars is carious, consider leaving the neighboring second premolar (Table 1, pattern 2).

Molar extraction is not a recent practice. It was first introduced in 1939 by Chapin.¹⁰ First permanent molars are extracted in case of poor prognosis, such as presence of large restorations, pulpal necrosis, or severe hypoplasia. If space is required to correct the incisal or canine

relationship, then an attempt should be made to preserve the first permanent molar until the second molar erupts. A Nance is used to enforce the anchorage. Extraction of all first molars is advocated in these conditions: minimum space requirement needed with absolute no change in profile, to correct anterior crowding or mild proclination; grossly decayed/periodontally compromised molar with poor prognosis; impacted molar.¹¹

Extraction of all first permanent molars should be timed at 10 years of age, bifurcation of the second permanent molars just formed and presence of the third molars (Table 1, pattern 3).

Extraction of all second permanent molars is indicated in relieving of possible impaction of second premolar due to mesial drift of first molar occurring after premature extraction of deciduous second molar; severely carious, rotated, or ectopically erupted second permanent molars. Extraction allows eruption of third molar (keeping in mind their favorable position). This will help to prevent and relieve minor lower incisor crowding sometimes, also will help in closing an anterior open bite; impacted permanent second molar against the first permanent molar;¹¹ to distalize the first permanent molars to correct buccal segment relationship. Avoid this pattern of extraction in cases where there is missing third molars (Table 1, pattern 4).

Extraction of right upper and lower first premolars and left upper and lower second premolars (or *vice-versa*), extraction of one side upper and lower first premolars with extraction of upper and lower first permanent molars on the opposite side and extraction of one side upper and lower second premolars with extraction of upper and lower first permanent molar on the opposite side. It is indicated that symmetrical extraction cannot be done due to poor prognosis of one or more teeth in different sides; for example, badly carious first premolar on the right and another badly carious second premolar on the left. This enforces the extraction choice (Table 1, pattern 5).

Extraction of lower second premolars in case of hypodontia of upper lateral incisors: This extraction pattern is indicated when upper lateral incisors are missing or poor prognosis peg-shaped lateral. So they will be extracted with presence of crowding in upper and lower jaw. Tooth of choice to be extracted in the lower arch is the second premolar, because usually molar relation will be class II/1 and class II/2 unit, which is not a stable

Table 1: Patterns of extraction for class I malocclusion

Class I	Patterns																		
	1		2		3		4		5						6		7		
4	4	5	5	6	6	7	7	4	5	4	6	5	6	2	2				
4	4	5	5	6	6	7	7	4	5	4	6	5	6	5	5	1			1



occlusion. Extraction of lower second premolars will help to correct this relation to class I (Table 1, pattern 6).

Extraction of lower left or right central incisor is rarely carried out and indicated in severely malpositioned incisor excluded from the arch with good buccal segment relationship. Poor prognosis in case of trauma, caries, or bone loss. Lower canines are severely distally inclined and lower incisor is fanned. Most upright incisor will be extracted, so others will be tipped into position¹¹ (Table 1, pattern 7).

Guideline for Extraction in Class II Division 1 Malocclusion

Class II is defined by the British Standard Institute as the lower incisor edges lying posterior to the cingulum plateau of the upper incisors. In cases of class II division 1 malocclusion, there is increase in the overjet and the upper central incisors are usually proclined.¹²

Class II division 1 is considered to affect approximately 15 to 20% of Caucasians, and around 38% of Sudanese population, while class II division 2 affects approximately 10% of the Caucasian and 3% of the Sudanese population.⁷

Treatment of class II has several different modalities: growth modification, orthodontic camouflage, surgical correction.

In this study we will be concerned of providing a guideline or protocol of when to extract and what to extract in cases of class II division 1 incisor relationship malocclusion.

Table 2 presents class II division 1 to simplify and brief the options of extraction in class II division 1.

Extraction of first premolars is considered to be one of the most commonly extracted teeth in orthodontics around 59%, followed by second premolars 13% and permanent molars 19% (1st permanent molars 12% and 2nd permanent molars 7%). Only 1% extracted permanent incisors.¹³

The high percentage of first premolar extraction is thought to be related to their position in the arch and the timing of their eruption. They are often ideal in the relief of anterior and posterior crowding. However, each case is treated according to its need.

Extraction of all first premolars is usually indicated in the management of increased overjet associated with a class I or mild class II skeletal pattern with severe upper

and lower crowded arches. According to Fink and Smith, treatment is increased by 0.9 months for each extracted premolar, thus this should be taken into consideration in the treatment planning¹⁴ (Table 2, pattern 1).

Extraction of maxillary first premolars and mandibular second premolars is usually the extraction of choice in the management of increased overjet associated with a class I or mild class II skeletal pattern with moderately crowded arches. This tends to favor forward movement of the lower molar to aid in the correction of the molar relationship and retraction of the upper labial segment¹⁵ (Table 2, pattern 2).

When treating class II in the absence of crowding with extraction of upper first premolars, the anterior segment of the upper arch is distalized to the extent of a premolar width (7 mm) so that cuspids can establish a class I relationship, while molars correct to class II full unit¹⁶ (Table 2, pattern 3).

Extraction of maxillary first permanent molars only is indicated in cases of badly decayed first molars and severe crowding in the upper arch with mild crowding in the lower arch. Also in cases where there are ectopic maxillary canines, care should be taken to wait till the eruption of the maxillary second permanent molars, then a Nance appliance is used to enforce the anchorage.

Removal of second permanent molars for correction of class II division 1¹⁷⁻¹⁹ is suggested in case of excessive buccal inclination of the incisors, no diastema, minimal overjet, presence of conveniently positioned and shaped third molars, patients with a dolichocephalic facial pattern, a tendency toward vertical growth, and the need for first permanent molar retraction. Extraction is recommended to decrease the likelihood of open bites and in cases of existing pathologies, such as buccal eruption, crown or root anomalies, caries or extensive restorations, and enamel defects²⁰ (Table 2, pattern 3).

The best age to assess the third molars is between 12 and 14 years of age when their crowns are almost completely calcified and their position relative to the second molar has been established. This is usually assessed radiographically.²¹⁻²⁴

Second permanent molar extraction for the correction of class II division 1 malocclusions often streamlines therapy and significantly shortens treatment time by making first molar distalization easier and faster²³⁻²⁵ (Table 2, pattern 3).

Table 2: Patterns of extraction for class II division 1 malocclusion

Class II/1	Patterns													
	1		2		3						4			
4	4	4	4	4	4	6	6	7	7	2	2	2	2	
4	4	5	5									5	5	

Sometimes in increased overjet with peg laterals, removal of the deformed teeth is advised to correct the overjet (Table 2, pattern 3). In cases of congenitally missing upper lateral incisors or if they are peg shaped, extraction is preferred with lower second premolars, closure of the space with upper canines, and correcting the buccal segment to class I (Table 2, pattern 4).

Guideline for Extraction in Class II Division 2 Malocclusion

Class II division 2 is defined as when the upper central incisors are retroclined and the laterals are proclined, or when all upper incisors are retroclined. The overjet is usually minimal but could be increased.¹² A recent study elaborated the definition as class II division 2a for the retroclination of the upper incisor, either the central or all incisors with decreased overjet and class II division 2b for the retroclination of upper incisors with increased overjet.²⁶

Class II division 2 is considered to affect approximately 10% of the Caucasian population and around 3% of the Sudanese population.^{7,15}

When treating class II division 2 cases, it is best to avoid extraction. If crowding is marked, extractions will be required¹⁵ (Fig. 1).

Extraction in the upper buccal segment with distalization is beneficial in cases where the incisor relationship needs correction and relief of crowding without affecting the overbite.¹⁴ It could also be used to correct buccal segment crowding in cases of class II division 2. As most of class II/2 are low-angle cases, no extraction is advised and distalization or stripping is preferred.

If there is crowding which cannot be solved by these methods, then extraction is advocated, but when extraction is decided, upper and lower second premolars are preferred, while some other cases benefit from extraction of the second permanent molars and distalization with a Nudger and headgear.

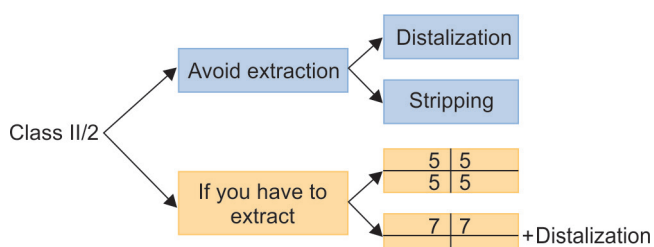


Fig. 1: Patterns of extraction for class II division 2 malocclusion

Extraction of upper and lower second premolars is preferred to first premolars in cases of severe crowding to prevent the excessive movement of the lower incisors lingually, which leads to deepening of the bite¹⁵ (Fig. 1).

Guideline for Extraction in Class III Malocclusion

The British Standard definition of class III incisor relationship includes those malocclusion where the lower incisor edge occludes anterior to the cingulum plateau of the upper incisors.

Class III malocclusion affects around 3% of Caucasian, 10% of Sudanese sample.⁷

- Treatment of class III has several different modalities:
- Early orthopedic treatment (rapid palatal expansion + face mask);
 - Orthodontic camouflage (extraction/nonextraction);
 - Orthognathic surgery.

In this study, we will be concerned about providing a guideline or protocol of when to extract and what to extract in class III malocclusion cases (Table 3).

The extraction pattern for class III malocclusion could be of either camouflage or orthognathic surgery.

The extraction of choice for camouflage is extraction of lower first premolars and upper second premolars. This is considered to resolve large mandibular crowding or no crowding but edge-to-edge incisor relationship, and include significant tipping of mandibular arch. Maxillary arch has no or mild crowding (Table 3, pattern 1).

The second pattern is to extract one central incisor either right or left. It is the tooth of choice in situations where crowding is not large or situation of Bolton discrepancy.²⁷ The only disadvantage could be of upper/lower midline mismatch and the need for permanent rigid lingual retainer as mandibular arch with three incisors has a tendency for lingual collapse and deep bite (Table 3, pattern 2).

Extraction of all first premolar is carried out sometimes in severe crowding or in cases of class III complicated with anterior open bite (Table 3, pattern 3).

In high angle cases with presence of third molars, the extraction of the first permanent molars might be a good option to solve the problems of anterior-inferior crowding and vertical growth, as well as to attain class I molar relationship²⁸ (Table 3, pattern 4).

In cases where the one side is a class I and the other is class III, extraction of either first premolar/first

Table 3: Patterns of extraction for class III malocclusion

Class III	Patterns													
	1		2		3		4		5				6	
5	5			4	4	6	6	5	4	5	6	4	4	
4	4		1	4	4	6	6	4	4	4	6	5	5	

permanent molars on the class I side, and extraction of first lower premolar and upper second premolar is advocated to correct the anterior and posterior occlusion to finish in a class I incisor, canine, and molar relationship (Table 3, pattern 5).

In cases that requires orthognathic surgery, decompensation is required, and is done in the presurgical orthodontic phase (Table 3, pattern 6). It is to make the class III look more prominent (worse). Here extraction of upper first premolars and lower second premolars is required, which resemble the camouflage extraction for class II/1 malocclusion.

CONCLUSION

Extraction of teeth for orthodontic treatment is just a tool, not necessarily good or bad. When used right they improve the stability and quality of the treatment, used wrong they can create devastating functional and esthetic results. Orthodontic tooth extraction should always be planned with consideration of the width and length of the face. Success of Orthodontic treatment will depend on detailed medical and dental history, extraoral/intraoral examination, diagnosis and treatment planning following a systematic way approach for treatment, looking at the oral hygiene, carious activity, periodontal involvement, prognosis of impacted teeth, supernumeraries, and hypodontia.

Mageet Orthodontic Training Centre designed these guidelines for their postgraduate orthodontic residents to prepare them for the membership of the Royal College of Surgeons of Edinburgh. A national level study is required to verify the applicability of these guidelines for all the postgraduate programs.

REFERENCES

1. Angle, EH. Treatment of malocclusion of the teeth and fractures of the maxilla: Angle's system. Philadelphia (PA): S. S. White Dental Mfg. Co.; 1900. p. 6.
2. Hulsey CM. An aesthetic evaluation of lip-teeth relationships present in the smile. *Am J Orthod* 1970 Feb;57(2):132-144.
3. Ackerman JL, Proffit WR. Soft tissue limitations in orthodontics: treatment planning guidelines. *Angle Orthod* 1997 Feb;67(5):327-336.
4. Weintraub JA, Vig PS, Brown C, Kowalski CJ. The prevalence of orthodontic extractions. *Am J Orthod Dentofacial Orthop* 1989 Dec;96(6):462-466.
5. Janson G, Maria FR, Bombonatti R. Frequency evaluation of different extraction protocols in orthodontic treatment during 35 years. *Prog Orthod* 2014 Aug;15(1):51.
6. Travess H, Roberts Harry D, Sandy J. Orthodontics part 8: extractions in orthodontics. *Br Dent J* 2004 Feb;196(4):195-203.
7. Todd J, Dodd T. Children's dental health in the United Kingdom. London: Office of Population Census and Surveys, 1985. 14.
8. Williams R, Hosila FJ. The effect of different extraction sites upon incisor retraction. *Am J Orthod* 1976 Apr;69(4):388-410.
9. Thompson FG. Second premolar extraction in Begg technique. *J Clin Orthod* 1977 Sep;11(9):610-613.
10. Singh, G. Textbook of orthodontics. 2nd ed. New Delhi: Jaypee; 2007. pp. 250-254.
11. British Standard Institute. Glossary of dental terms. BS 4492. London: BSI; 1983.
12. Bradbury AJ. The influence of orthodontic extraction on the caries indices in schoolchildren in the United Kingdom. *Comm Dent Health* 1985 Jun;2(2):75-82.
13. Janson G, Fernando J, Alvares E, Rodrigues K. Class II subdivision treatment success rate with symmetric and asymmetric extraction protocols. *Am J Orthod Dentofacial Orthop* 2003 Oct;64:339.
14. Mitchell, L. An introduction to orthodontics. 4th ed. Oxford: Oxford University Press; 2013. pp. 120-124.
15. Chapin WC. The extraction of maxillary second molars to reduce growth stimulation. *Am J Orthod Oral Surg* 1939 Nov;25(11):1072-1078.
16. Janson G, Barros S, Simao T, Freitas M. Relevant variables of class II malocclusion treatment. *R Dental Press Ortodon Ortop Facial* 2009 Jul;14(4):149-157.
17. Basdra EK, Stellzig A, Komposch G. Extraction of maxillary second molars in the treatment of Class II malocclusion. *Angle Orthod* 1996 Feb;66(4):287-291.
18. Graber TM. The role of upper second molar extraction in orthodontic treatment. *Am J Orthod* 1955 May;41(5):354-361.
19. Rondeau BH. Second molar extraction technique: overrated or underutilized? *Funct Orthod* 1999 Oct-Dec;16(4):4-14.
20. Quinn GW. Extraction of four second molars. *Angle Orthod* 1985 Jan;55(1):58-69.
21. Aras A. Class II correction with the modified sagittal appliance and maxillary second molar extraction. *Angle Orthod* 2000 Aug;70(4):332-338.
22. Stellzig A, Basdra EK, Komposch G. Skeletal and dentoalveolar changes after extraction of the second molars in the upper jaw. *J Orofac Orthop* 1996 Oct;57(5):288-297.
23. Bishara SE, Ortho D, Burkey PS. Second molar extractions: a review. *Am J Orthod* 1986 May;89(5):415-424.
24. Graber TM. Maxillary second molar extraction in Class II malocclusion. *Am J Orthod* 1969 Oct;56(4):331-353.
25. Whitney EF, Sinclair PM. An evaluation of combination second molar extraction and functional appliance therapy. *Am J Orthod Dentofacial Orthop* 1987 Mar;91(3):183-192.
26. Mageet AO. Classification of skeletal and dental malocclusion: revisited. *Stoma Edu J* 2016 Aug;3(2):205-211.
27. Kochel J, Emmerich S, Meyer-Marcotty P, Stellzig-Eisenhauer A. New model for surgical and nonsurgical therapy in adult with class III malocclusion. *Am J Orthod Dentofacial Orthop* 2011 Feb;139(2):165-174.
28. Ruellas AC, Baratieri C, Roma MB, Izquierdo Ade M, Boaventura L, Rodrigues CS, Telles V. Angle Class III malocclusion treated with mandibular first molar extraction. *Am J Orthod Dentofacial Orthop* 2012 Sep;142(3):384-392.